



Clear aligners versus fixed orthodontic appliance on the occurrence of external root resorption in upper teeth; Cone-beam study

Ibrahim Saad Abd El-Ghafar *, **Esmail Kamal Hewy Raslan***, **Ahmed Mohamed Kilany***,
Ahmed Mahmoud Ahmed Ali*, **Mahmoud Mohamed Salah Eldin***, **Zein Abdou Shatat****
Sara Mohamed Hosny Elkabbany***, **Mohamed Mohamed Ali ******, **Ahmed Shehata**
Mohamed Ammar **** **Yasser Mohammad Elsayed Hassouna*******

*: Lecturer, Orthodontic Department, Faculty of Dental Medicine, Al-Azhar University (Assiut Branch), Assiut.

** : Lecturer of oral and maxillofacial radiology, Assiut University, Egypt.

***: Assistant Professor in Orthodontics Al-Azhar University (Cairo).

****: Lecturer, Orthodontic Department, Faculty of Dental Medicine, Al-Azhar University (Cairo).

*****Lecturer -Military Medical Academy

Corresponding author:

Lecturer, Orthodontic Department, Faculty of Dental Medicine, Al-Azhar University (Assiut Branch), Assiut, Egypt ibrahemsaad1114@azhar.edu.eg

Article History: Received: 20.06.2023 Revised:05.07.2023 Accepted: 15.07.2023

ABSTRACT

Objective: To compare with the aid of cone beam CT the effect of treatment with clear aligner versus fixed orthodontic appliances on the external root resorption in upper teeth.

Patients and Methods: Fourteen individuals, aged between 15 and 25, took part in the study. Research randomization was used to assign patients who satisfied the inclusion criteria at random to the aligner and fixed groups.

Results: There were statistical significant differences in root volume and linear measurements of both groups (Paired t-tests were used between T0 and T1). Independent t-tests were used to compare the mean changes of root volumes and linear measurements between the two groups).

Conclusion: There is a significant root resorption in both clear aligner and fixed orthodontic appliance groups. The difference between both groups was statistically insignificant.

Keywords: Clear aligner, fixed orthodontic appliances, root resorption, dentistry, cone beam computed tomography.

DOI: 10.48047/ecb/2023.12.10.995

INTRODUCTION

Clear aligner treatment is an orthodontic technique in which teeth movement differ greatly than fixed orthodontic appliances.¹

There is an increasing demand for more esthetic orthodontic treatment techniques especially among adult patients in the recent years, in addition to esthetic treatment, clear aligners provides other benefits because it's more hygienic nature and comfort than the treatment with fixed orthodontic appliances.^{2,3}

Remensnyder pioneered the use of aligners to shift teeth in 1926; Kesling popularized this technology in 1945 and coined it the tooth placement device. Sheridan later developed the Essix tooth-moving device. Mild to moderate crowding can be corrected with the Essix aligners.⁴

Align Technology was created in 1997 and was the first firm to employ old aligner techniques in conjunction with CAD/CAM technology. Advances and advancements in this technology have further improved and refined many alignment systems employing various software.⁴

Clear aligner moves teeth by the way of exerting a push force on the teeth when the aligner is worn, the elastic nature of the aligner material can deform on insertion which result in pushing teeth to the desired position.¹

One of the common side effects of orthodontic treatment is the external root resorption which leads to loss of the root tissues.^{5,6}

According to previous studies which done on the treatment with fixed appliances showed that about 90% of the teeth showed histological external apical root resorption while other radiographic studies showed a lower percentage.⁷⁻¹⁰

During fixed orthodontic treatment any tooth could be subjected to root resorption but the most frequent teeth susceptible to resorption were the central and lateral incisors.¹¹⁻¹⁵

Most of the previous studies used panoramic and periapical radiographs to detect external apical root resorption which may results in multiple detection errors because it's two dimensional nature. Cone beam computed tomography (CBCT) can provide a more accurate method of detection while measuring root length precisely.¹⁶⁻²²

The objective of this study was to compare with the aid of cone beam the effect of treatment with clear aligner versus fixed orthodontic appliances on the external root resorption in upper teeth.

PATIENTS AND METHODS

In this study, 14 patients with ages ranging from 15 to 25 were included. They were chosen from the outpatient orthodontic clinic at the Faculty of Dental Medicine, Al-Azhar University, Assiut branch.

The following inclusion criteria were used to determine the eligibility of the patients who visited the orthodontic clinic.

- Patients aged 15 to 25 (mean: 19 years).
- Care for a single or double arch
- Non-extraction therapy.
- The patient's dentition should be full, from molar to molar.
- Maintaining proper oral hygiene.
- A robust periodontium.

All of the patients completed informed consent forms after hearing about the surgery in detail.

Clinical procedure: -

Patients who met the inclusion criteria were randomly assigned to the aligner and fixed groups using research randomization. After evaluation the patient was informed with steps and details of the treatment plan and signed on written consent form.

I. Clear aligner group

1. Clear aligner fabrication

A rubber base imprint (heavy and light) was obtained for patients in the aligner group to ensure that precise details were captured. The rubber base impression, along with the data and treatment plane for each patient, was delivered to the manufacturer for aligner construction..

2. Teeth preparations

- I. Acid etch application on tooth areas which will have attachments
- II. Bond application.
- III. loading composite in the template tray for attachment building up
- IV. Set the tray intraorally and light curing

3. Aligner delivery and patient instructions:

Once the aligners have been fabricated, They give the patients their aligners and

explain how to wear them according to the instructions and protocol of each group. The patients must replace their aligner with a new one every 14 days to give their effect on tooth movement and take a new aligner set every visit.

II. Fixed braces group

1. Conventional EASYINSMILE orthodontic metal standard torque Roth (slot 0.022") braces were bonded
2. wires were changed in the following sequence every 4-6 weeks: 0.012" round nickel titanium (NiTi), 0.014" NiTi, 0.016" NiTi, 0.018" NiTi, 0.016"×0.022" rectangular NiTi, 0.017"×0.025" stainless Steel (StSt), 0.018"×0.025" stainless Steel (StSt)
3. Oral hygiene was monitored during this period. Appointment intervals were approximately 5 weeks.

Data collection:

Measurement Procedures:

For every group, cone beam CT was taken before treatment (T0) and after finishing the case (T1). Each CBCT scan was imported into Mimics software using the DICOM file format and the measurements were assessed for every group from central incisor to the upper first molar in the right side.

The closest threshold to root segmentation of teeth (from upper central incisor to upper first molar on the right side) was chosen since the same threshold values were frequently utilized in the post-operative CBCT. Further manual segmentation was performed to guarantee that the teeth were completely isolated from the surrounding bone and teeth (Fig. 1).

After isolation, each tooth was transformed to a 3D model in which each tooth was detached from its neighboring one with one hand and decapitated at its cemento-enamel junction with the other hand, resulting in an isolated root model of each tooth. The volume was then measured in mm³.

The tooth length was measured from the incisal edge to the root apex from the sagittal views for linear measurement (Fig 2), and the root volume was measured from the cemento-enamel junction to the root apex.

Little's irregularity index was used to measure the degree of crowding on the dental models at each session. The recommended scoring method involves measuring the linear distance between each tooth's anatomic point and its neighboring tooth's anatomic point, as distinguished from the clinical contact sites. These displacements' sum indicates the relative severity of dental abnormalities.

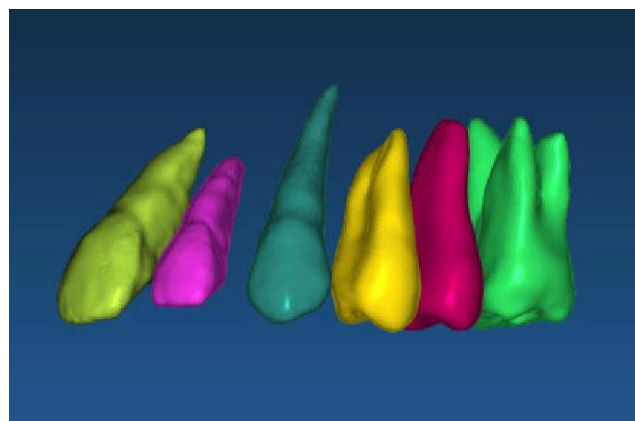


Figure 1: nearest threshold of CBCT scan for teeth segmentation and isolation of teeth root from the surrounding bone.

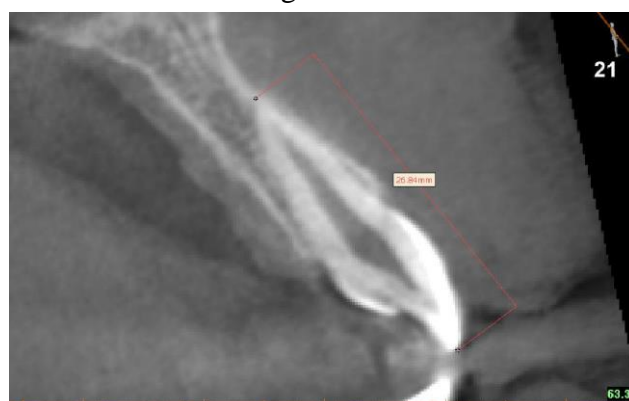

Figure 2: Sagittal view showing linear tooth length measurement from incisal edge or cusp tip to root apex.

Statistical Analysis:

The statistical analyses were done using Microsoft Excel (version 2019; Microsoft, Redmond, Wash.) and IBM SPSS Statistics (version 25.0; IBM, Armonk, N.Y.). The Bland-Altman approach was used to measure random errors, and ICCs were used to evaluate the reliabilities of intraoperator and interoperator. The descriptive statistics are presented as means and standard deviations. The Shapiro Wilk test and the Levene's test were used to check the normality and the

homogeneity of variance, respectively. The mean root volumes and linear at T0 and T1 were compared using paired t-tests. The mean

differences in root volume and linear between the two groups were compared using independent t-tests.

Results

Table (1): show root volumes in mm³ before treatment (T0) and after finishing (T1) in clear aligners group.

Tooth-Root	Root volumes (Clear Aligner group)		Test of Significance
	Before (T0)	After (T1)	
Central incisors	599.43 ±69.09	541.07 ±63.39	P=.004**
Lateral incisors	373.00 ±17.52	366.49 ±19.90	P=.005**
Canine	620.57 ±41.16	587.39 ±41.72	P=.016*
Root/s 1 st premolar	566.20 ±36.05	546.11 ±33.37	P=.009**
Root/s 2 nd premolar	565.57 ±49.33	526.29 ±31.93	P=.022*
Root/s of first molar	1220.37 ±173.66	1167.50 ±156.38	P=.040*

Data are presented as mean and SD, * P < .05, ** P < .01. , mm³ = cubic millimeter

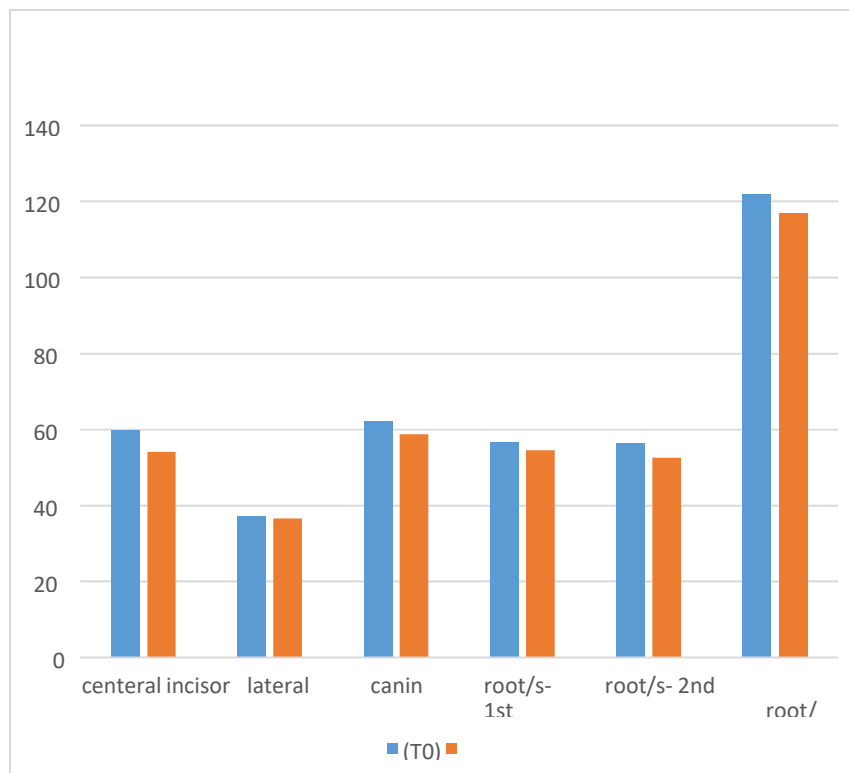


Figure 3: Root/s volume change of the teeth in clear aligner group

Table (2): show root volumes in mm³ before treatment (T0) and after finishing (T1) in fixed braces group.

Tooth-Root	Root volumes (Fixed braces group)		Test of Significance
	Before treatment(T0) mm ³	After finishing (T1) mm ³	

Central incisors	491.51 ±77.45	422.97 ±70.98	P=.002**
Lateral incisors	305.08 ±34.75	290.76 ±39.76	P=.007**
Canine	545.86 ±64.46	481.26 ±60.25	P=.003**
Root/s 1st premolar	533.30 ±62.71	486.44 ±63.10	P=.000**
Root/s 2nd premolar	438.32 ±50.52	404.70 ±56.91	P=.000**
Root/s of first molar	951.63 ±32.02	910.01 ±51.64	P=.030*

Data are presented as mean and SD.

* P < .05

** P < .01

mm³ = cubic millimeter

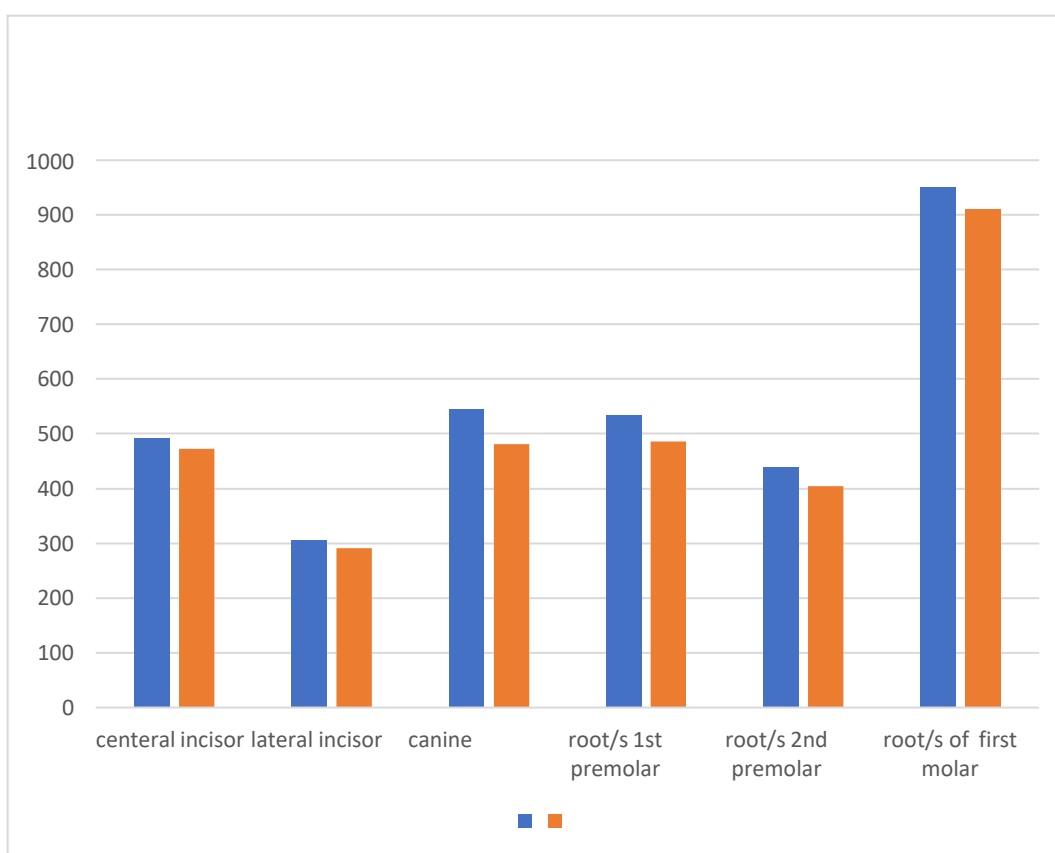


Figure 4: Root/s volume change of the teeth in fixed appliance group

Table (3): show mean changes in root volume (mm^3) of the teeth between clear aligner group and fixed braces group.

Tooth-Root	Root Volumes (Mean Changes (mm^3))		Test of Significance
	(Clear Aligner group)	(Fixed braces group)	
Central incisors	-58.35 ± 22.56	-68.54 ± 15.77	P= .042*
Lateral incisors	-6.51 ± 2.57	-14.32 ± 6.25	P= .032*
Canine	-33.17 ± 18.58	-64.60 ± 22.89	P= .044*
Root/s 1 st premolar	-20.09 ± 9.49	-46.85 ± 5.80	P= .001**
Root/s 2 nd premolar	-39.27 ± 24.17	-33.62 ± 8.74	P= .636
Root/s of first molar	-52.86 ± 39.32	-41.62 ± 28.07	P= .617

Data are presented as mean and SD. * P < .05, ** P < .01, mm^3 = cubic millimeter

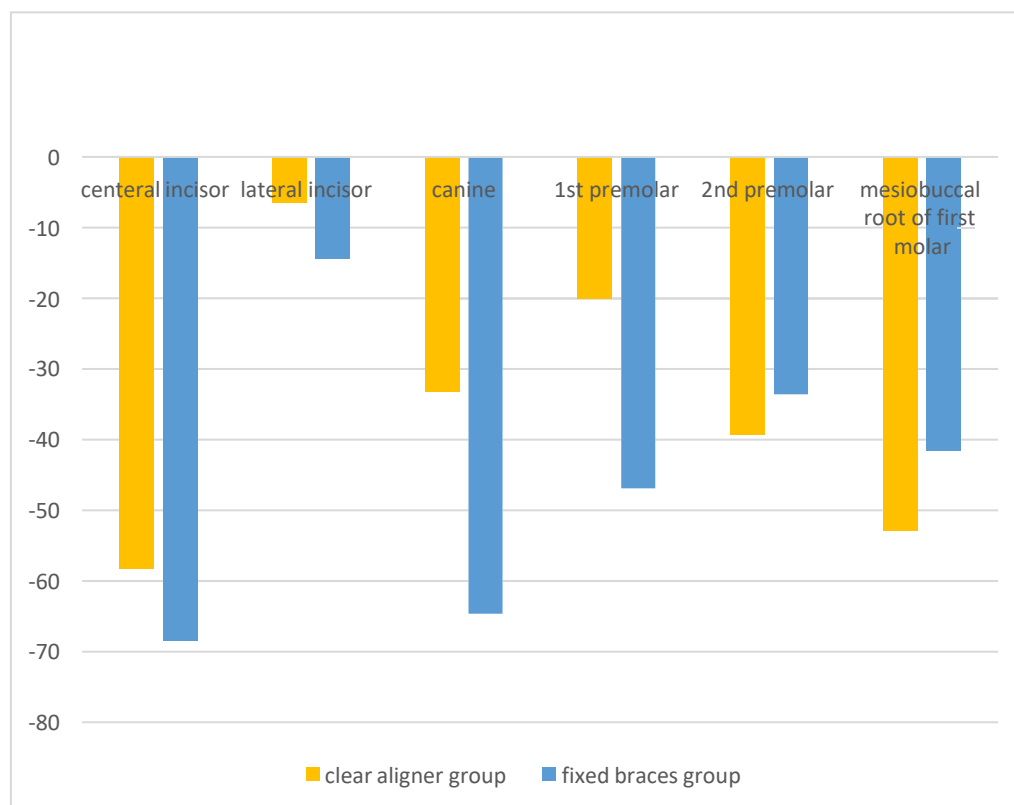


Figure 5: mean change of root volumes of the teeth between groups

Table (4): show teeth length (mm) before treatment (T0) and after finishing (T1) in clear aligner group.

Tooth-Root	Root Linear (Clear Aligner group)		Test of Significance
	Before treatment (T0)mm	After finishing (T1) mm	
Central incisors	25.57 ±1.04	24.14 ±.64	P= .004**
Lateral incisors	22.37 ±.84	21.34 ±1.10	P= .010*
Canine	27.45 ±.68	26.76 ±.57	P= .062
1 st premolar	21.99 ±1.09	21.24 ±1.10	P= .006**
2 nd premolar	20.58 ± 1.87	20.45 ±1.84	P= .013*
Mesiobuccal root of first molar	19.93 ± 1.00	19.85 ±.99	P= .000**

Data are presented as mean and SD. * P < .05, ** P <.01, mm = millimeter

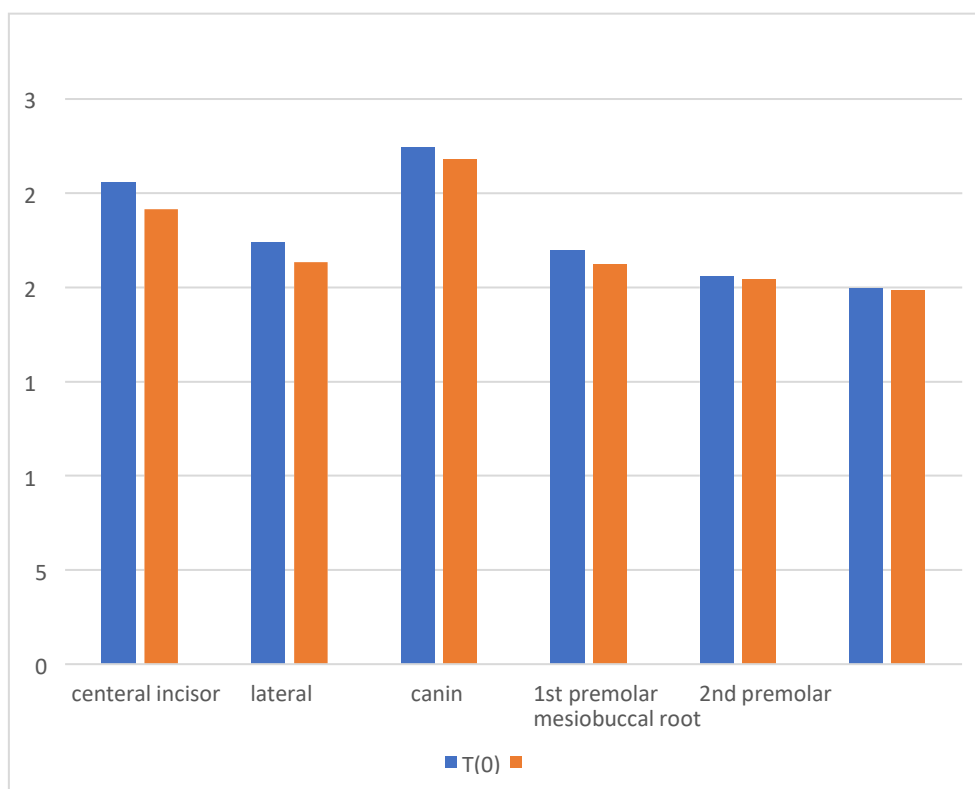


Figure 6: linear changes of teeth in clear aligner group.

Table (5): show teeth length (mm) before treatment (T0) and after finishing (T1) in fixed orthodontic appliance group.

Tooth-Root	Root Linear (fixed braces group)		Test of Significant
	Before (T0)	After (T1)	
Central incisors	23.32 ±1.36	22.93 ±1.35	P= .000**
Lateral incisors	20.38 ±.81	19.95 ±.91	P= .003**
Canine	25.73 ±1.61	25.30 ±1.58	P= .004**
1 st premolar	21.83 ±1.00	21.76 ±.99	P= .000**
2 nd premolar	20.55 ±2.00	20.46 ±2.04	P= .026*
Mesiobuccal root of first molar	19.73 ±1.29	19.68 ±1.30	P= .000**

Data are presented as mean and SD., * P < .05, ** P < .01 mm= millimeter

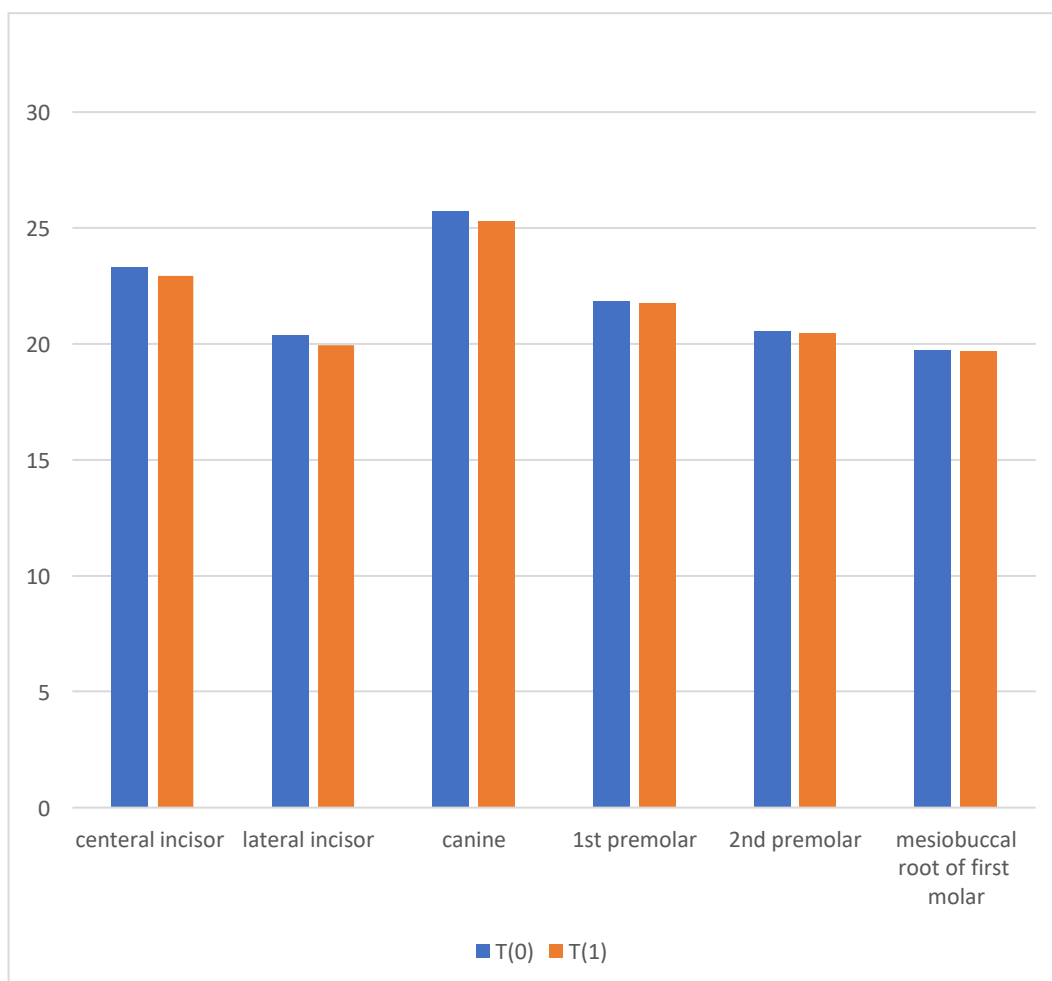


Figure 7: linear changes of teeth in fixed braces group.

Table (6): show mean changes in tooth length measurements between clear aligner group and fixed braces group.

Tooth-Root	Teeth length (Mean Changes)mm		Test of Significant
	(Clear Aligner group)	(Fixed braces group)	
Central incisors	-1.43 ±.53	-.39 ±.01	P= .003**
Lateral incisors	-1.02 ±.49	-.42 ±.14	P= .033*
Canine	-.69 ±.59	-.43 ±.16	P= .377
1 st premolar	-.74 ±.31	-.07 ±.01	P= .001**
2 nd premolar	-.12 ±.06	-.08 ±.05	P= .332
Mesiobuccal root of first molar	-.07 ±.008	-.05 ±.011	P= .008**

Data are presented as mean and SD., * P < .05, ** P < .01 mm= millimeter

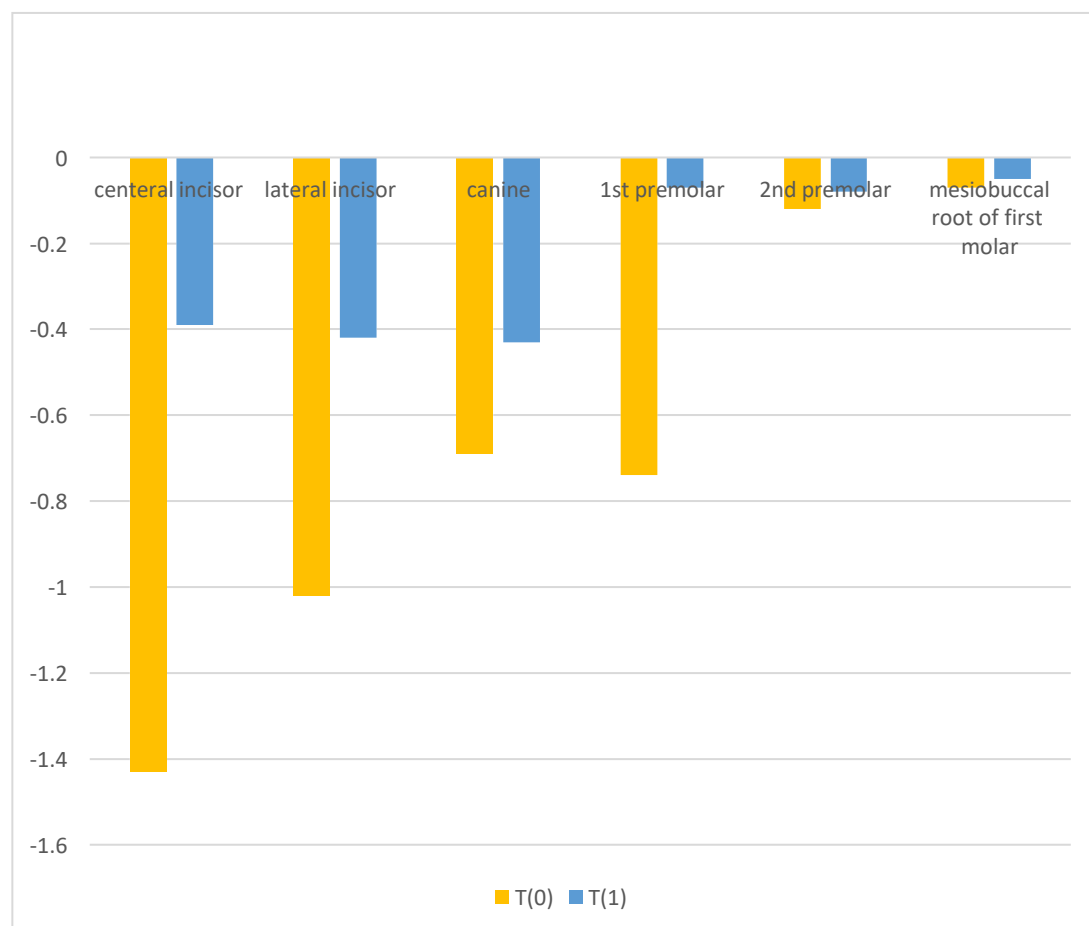


Figure 8: mean changes of teeth linear length between groups

Discussion

The purpose of this study was to investigate the difference in external root resorption risk between patients who underwent treatment with traditional fixed appliances or removable aligners.

Because external root resorption is a complex pathological occurrence, each orthodontically treated patient's investigation includes previously related clinically, radiographically, and genetically significant variables.¹⁶ Despite its increased complexity, this sort of study enabled the management and modification of factors other than appliance type on the development of root resorption.¹⁷

Orthodontic loading with either permanent or removable appliances causes a biological and molecular reaction, allowing the roots to migrate through alveolar bone.¹⁸

It is the same sort of cell response that can cause external root resorption in some situations, therefore aligner therapy is not immune to the same iatrogenic impact. According to previous research, intermittent (aligners) and continuous (fixed) appliances utilize different types of force, and the former may have more control over the degree of force than the latter.¹⁹ According to one theory, applying pressure intermittently during the interval enables the cementum at the root to repair and so prevents further resorption.²⁰ However, these forces have been associated with damaging jiggling forces, and perhaps more significantly, current aligner treatment protocols advise almost continuous use, suggesting that they can be regarded as a type of continuous force with reactivation (aligner change) in a shorter amount of time (typically 15 days, though some clinicians advise changing them in less than a week).

We could anticipate changes in the amount and degrees of force to explain disparities in the manifestation of root resorption. Nonetheless, contemporary methods for permanent appliances often require the sequential application of mild forces³⁸ at each phase, which may explain why the

proclivity for root resorption with fixed appliances is comparable to that with removable aligners.

The result of this study showed that the root resorption can occur in all cases, whether using transparent aligners or permanent orthodontic gear.

A recent longterm study of 100 consecutive Invisalign patients revealed no significant root resorption. In contrast, clinically significant root resorption of at least 3 mm occurs in 10% of patients treated with fixed appliances.⁴ Brezniak and Wasserstein²¹ provide a detailed overview of the literature.

Claimed that the use of inflammation to treat esthetic and functional issues is unique to the dental field of orthodontics. Any device, permanent or detachable, that applies force to the teeth triggers a series of biological processes. We are well aware of how and when it is provoked, but we are unable to foresee the final result. The severity of this inflammatory process is influenced by a variety of variables, including the virulence or aggressiveness of the various resorbing cells and the susceptibility and sensitivity of the tissues involved. The category of removable appliance treatment techniques includes the Invisalign treatment method. Like the majority of active removable appliances, it places intermittent stresses on the teeth. There are several articles that discuss the idea that intermittent force allows the resorbed cementum to heal and prevent further resorption.²² The effects of intermittent forces are comparable to those of damaging jiggling forces. This study's findings rely on the fact that there is no variation in the force exerted by a usual detachable device, such as an aligner or a Hawley appliance with springs or screws.

Conclusion

According to the findings of this study, the proclivity to external root resorption with clear aligners is comparable to that of permanent appliances.

REFERENCES

1. Palma Moya S, Lozano Zafra J. *Aligner Techniques in Orthodontics*, Wiley-Blackwell. 2021; 1: 21.
2. Ghafari JG. Centennial inventory: The changing face of orthodontics. *Am J Orthod Dentofacial Orthop.* 2015;148:732–739.
3. Azaripour A, Weusmann J, Mahmoodi B, et al. Braces versus Invisalign: gingival parameters and patients' satisfaction during treatment: a cross-sectional study. *BMC Oral Health.* 2015;15:69.
4. Ziuchkovski JP, Fields HW, Johnston WM, Lindsey DT. Assessment of perceived orthodontic appliance attractiveness. *Am J Orthod Dentofac Orthop.* 2008; 133:68-78.
5. Weltman B, Vig K, Fields H, Shanker S, Kaizar E. Root resorption associated with orthodontic tooth movement: a systematic review. *Am J Orthod Dentofacial Orthop.* 2010.137:462–476.
6. Aras B, Cheng LL, Turk T, Elekdag-Turk S, Jones AS, Darendeliler MA. Physical properties of root cementum: part 23. Effects of 2 or 3 weekly reactivated continuous or intermittent orthodontic forces on root resorption and tooth movement: a microcomputed tomography study. *Am J Orthod Dentofacial Orthop.* 2012;141:e29–e37.
7. Wierzbicki T, El-Bialy T, Aldaghreer S, et al. Analysis of orthodontically induced root resorption using micro-computed tomography (micro-CT). *Angle Orthod.* 2009;79:91–96.
8. Tieu LD, Saltaji H, Normando D, et al. Radiologically determined orthodontically induced external apical root resorption in incisors after non-surgical orthodontic treatment of Class II division 1 malocclusion: a systematic review. *Prog Orthod.* 2014;15:48.
9. Sondejker CFW, Lamberts AA, Beckmann SH, et al. Development of a clinical practice guideline for orthodontically induced external apical root resorption. *Eur J Orthod.* 2020;42:115–124.
10. Walker SL, Tieu LD, Flores-Mir C. Radiographic comparison of the extent of orthodontically induced external apical root resorption in vital and root-filled teeth: a systematic review. *Eur J Orthod.* 2013;35:796–802
11. Brezniak N, Wasserstein A. Orthodontically induced inflammatory root resorption. Part I: the basic science aspects. *Angle Orthod.* 2002;72:175–179.
12. Ren H, Chen J, Deng F, et al. Comparison of cone-beam computed tomography and periapical radiography for detecting simulated apical root resorption. *Angle Orthod.* 2013; 83:189–195.
13. Dudic A, Giannopoulou C, Martinez M, et al. Diagnostic accuracy of digitized periapical radiographs validated against micro-computed tomography scanning in evaluating orthodontically induced apical root resorption. *Eur J Oral Sci.* 2008;116:467–472.
14. Aman C, Azevedo B, Bednar E, et al. Apical root resorption during orthodontic treatment with clear aligners: a retrospective study using cone-beam computed tomography. *Am J Orthod Dentofacial Orthop.* 2018;153:842–851.
15. Gay G, Ravera S, Castrolforio T, et al. Root resorption during orthodontic treatment with Invisalign: a radiometric study. *Prog Orthod.* 2017;18:12
16. Pandis N, Nasika M, Polychronopoulou A, Eliades T. External apical root resorption in patients treated with conventional and self-ligating brackets. *Am J Orthod Dentofacial Orthop.* 2008;134:646–651.
17. Cepeda MS, Boston R, Farrar JT, Strom BL. Comparison of logistic regression versus propensity score when the number of events is low and there are multiple confounders. *Am J Epidemiol.* 2003;158:280–287.
18. Krishnan V, Davidovitch Z. On a path to unfolding the biological mechanisms of orthodontic tooth movement. *J Dent Res.* 2009;88:597–608.

- 19.** Simon M, Keilig L, Schwarze J, Jung BA, Bourauel C. Forces and moments generated by removable thermoplastic aligners: incisor torque, premolar derotation, and molar distalization. *Am J Orthod Dentofacial Orthop.* 2014;145:728–736
- 20.** Ballard DJ, Jones AS, Petocz P, Darendeliler MA. Physical properties of root cementum: part 11. Continuous vs intermittent controlled orthodontic forces on root resorption. A microcomputed-tomography study. *Am J Orthod Dentofacial Orthop.* 2009;136:8.e1–e8.
- 21.** Brezniak N, Wasserstein A. Orthodontically induced inflammatory root resorption. Part II: The clinical aspects. *Angle Orthod.* 2002;72:180–184
- 22.** Dougherty HL. The effects of mechanical forces upon the mandibular buccal segments during orthodontic treatment. Part II. *Am J Orthod.* 1968;54:83–103