



## EVALUATION OF MINIMAL INVASIVE PLATE OSTEOSYNTHESIS IN HUMERAL SHAFT FRACTURES

Hossam Fathi Mahmoud, Mohammed Abdallah Elsoufy, Fady Mahmoud Taha, Hany Mohamed Abdelfattah Bakr

Article History: Received: 12.06.2023

Revised: 07.07.2023

Accepted: 15.07.2023

### ABSTRACT

**Background:** Shaft fractures account for 20% and 1-3% of all humerus fractures, respectively. Open dynamic compression plate fixation (Open fixation with DCP) with absolute stability is the current gold standard for treating shaft humerus fractures. The goal of MIPO was to provide a more stable fixation, which would increase the union rate and decrease open plating side effects including infection and radial nerve palsy.

**Aim:** The purpose of this study was to assess the clinical and radiological outcomes of the MIPPO technique in the treatment of humeral shaft fractures.

**Patients and methods:** thirty cases of shaft humerus fractures were examined during the period from August 2022 to March 2023. The history, clinical examination, and radiographic (X-ray) examination were used to select cases. According to UCLA score, the result was noted and filled up.

**Results:** Union was achieved in 17 to 22 weeks with the mean  $19.4 \pm 4.1$ . Only 5% nonunion was seen in our cases. It was observed that the median UCLA score was excellent (34).

**Conclusion:** In shaft humerus fractures, results from minimally invasive plate osteosynthesis with anterior bridge plating were favorable. They offer the fracture site some support, and the fracture hematoma is not disturbed. MIPO keeps the blood vessels healthy, which lowers the danger of infection and wound disintegration.

**Keywords:** Humeral shaft fracture, minimal invasive percutaneous, plate osteosynthesis, locking compression plate.

Orthopedics Department, Faculty of Medicine, Zagazig University, Egypt

DOI: 10.31838/ecb/2023.12.9.185

### INTRODUCTION

Humeral shaft fractures account for 20% of all humeral fractures, which make up about 3% of all fractures. Traffic accidents, falls, or severe traumas are the main causes of humeral shaft fractures. Pathological fracture and stress fracture are further causes. Although conservative therapy is regarded as the benchmark, the top surgical fixation technique is still up for debate<sup>(1)</sup>. There are several conservative treatment options, each with benefits and drawbacks, such as hanging arm casts, velpau dressing, and abduction casting and splinting<sup>(2)</sup>. Due to its ease of use, flexibility in application, ability to allow movement of the elbow and shoulder, relative affordability, and history of positive outcomes, bracing has largely surpassed other conservative treatment options and has established itself as the gold standard for non-operative treatment<sup>(3)</sup>.

Only open fractures, patients with multiple traumas, flail elbow fractures, failures of conservative treatment, and fractures that are not joined or are not united well are candidates for surgery<sup>(4)</sup>.

In terms of surgical treatment, Plate and screw constructions, intramedullary nails, and external fixing all produce consistently high union rates. Despite the wide variety of surgical procedures, plate fixation is still the go-to method for treating humeral shaft fractures<sup>(5)</sup>.

Open plating permits morphological reduction of fractures without compromising elbow and shoulder function, although it does require significant soft tissue stripping and increases the risk of nonunion and radial nerve palsy<sup>(6)</sup>.

The benefits of intramedullary nailing for humeral shaft fractures include smaller incisions, preserved biology at the fracture site, and the ability to share the load. These implants haven't been utilized very frequently, though, due to concerns about nonunion, reoperation, stiffness, fracture at the start site, and pain in the adjacent joints (7).

Because of its benefits and positive clinical results, Minimal Invasive Percutaneous Plate Osteosynthesis (MIPPO) is now frequently utilized to treat lengthy bone shaft fractures. Compared to open plating, the MIPPO method has lower complication rates and can successfully repair humeral shaft

fractures. With little disruption to soft tissue, this method keeps the fracture hematoma and blood supply to the individual bone fragments <sup>(8)</sup>.

### PATIENTS AND METHODS

The study included 30 patients undergoing surgical MIPPO treatment for humeral shaft fractures. In 21 patients, the fracture shaft was on the right side, while in 9 individuals, it was on the left side.

Although they were included, patients with closed humeral diaphyseal fractures. Exclusion criteria included open fractures, pathological fractures, untreated older fractures, and revision cases.

All patients had a thorough medical history review, clinical examination, and radiological evaluation. AP, lateral views of the afflicted upper limb, showing the shoulder and elbow, and laboratory tests: Plain x-ray standard preoperative tests like the CBC, PT, INR, AST, ALT, RBS, BUN, and creatinine. For the American Shoulder and Elbow Society (ASES) and the University of California, Los Angeles, all patients submit their evaluations (UCLA) <sup>(9)</sup>.

#### Surgical Technique:

The patient wasn't wearing a tourniquet and was lying on his back. Using a hand table, maintain the arm in a neutral position with the forearm fully supinated (radiolucent table). The visibility of the shoulder and the whole humerus was tested using image control.

Mobilization of the arm on hand table can be made to take AP and lateral views for reduction. First image was taken to check the fracture site, for marking the proximal and distal incisions sites and plate position.

We started with the distal incision, palpated the lateral borders of biceps muscle where the landmark for the distal incision site is. Skin incision and subcutaneous tissue dissection were done along the lower half of the arm's lateral border of the biceps muscle.

We developed the plane between the biceps and brachialis muscle. We identified the musculocutaneous nerve where it presents on the anterior surface of the brachialis muscle. In some cases, the musculocutaneous nerve was found

adherent on the undersurface of biceps muscle. Great care to identify the nerve was done to avoid injury to it. In order to expose the bone and to protect the radial nerve on the lateral side and the musculocutaneous nerve on the medial side, the brachialis muscle is split in the middle. The delto-bicipital interval is used as a landmark for the proximal incision in order to expose the proximal shaft of the humerus and locate the anterior section of the deltoid insertion.

To reveal the bone along the lateral and medial edges of the proximal humerus, retractors are used. A tunneling device is inserted from distally to proximally in order to create an anterior extraperiosteal tunnel between the humerus and brachialis muscle. Plate can be used to create the tunnel if the tunneling device not present. Application of the narrow locked plate along the anterior surface of the shaft of the humerus and reduction is done under the image control. K-wires are used for temporary fixation for reduction adjustment; to position the plate, as a handle, a threaded drill guide is used. The distal screw was applied through the plate under image control then the proximal screw to get better reduction. Each primary fracture fragment received a minimum of three screws.

After plate and screws insertion, irrigation of the wounds was done and skin and subcutaneous tissue closed. Arm sling was applied and radial nerve functions were tested after complete recovery of the patient. X-ray was taken postoperatively for documentation and follow up of the patient.

#### ETHICS APPROVAL:

The Institutional Review Board [IRB] and the local ethics committee of the Faculty of Medicine, Zagazig University, both gave their approval to the study's protocol.

#### STATISTICAL ANALYSIS

The information was analyzed using SPSS software (USA). The mean, standard deviation, or percentage are used to represent the parametric data.

### Results:

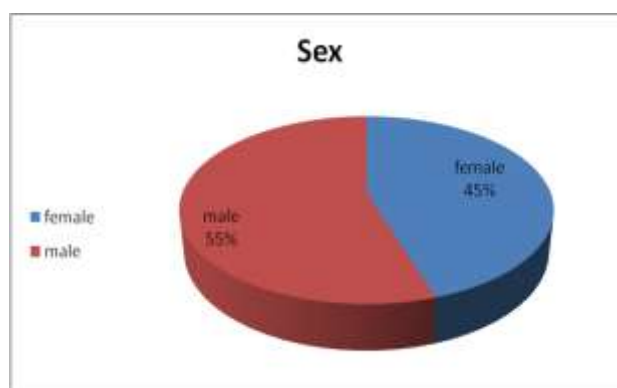
**Table (1):** Baseline data of the studied group.

Variables		
<b>Age (Years)</b>		
	39.4±5.4	22-65
<b>Sex</b>		
Male	17	55%
Female	13	45%
<b>Side</b>		
Right	21	70%
Left	9	30%
<b>Mechanism of injury</b>		
Road traffic	26	87%
Fall from height	4	13%

Associated fractures		
Fracture both bones forearm	2	5%
Intra-articular fracture distal radius right side	1	3%
Fracture medial malleolus and neck talus on the right side	1	3%
Fracture styloid process left radius	1	3%
No associated fractures	25	86%

The present study included 30 patients their age ranged from 22 to 65 years with the mean  $39.4 \pm 5.4$ , 55% of patients were male. Fracture shaft humerus on right side in 70% of patients. Mainly road traffic accidents were present in 87% of patients except 13% of cases with history of fall from height. 86%

of the cases had no associated fractures , 5% had fracture both bones forearm, 3% of cases had intra-articular fracture distal radius right side, 3% had fracture styloid process left radius, and 3% had fracture medial malleolus and neck talus on the right side (**Table 1**).

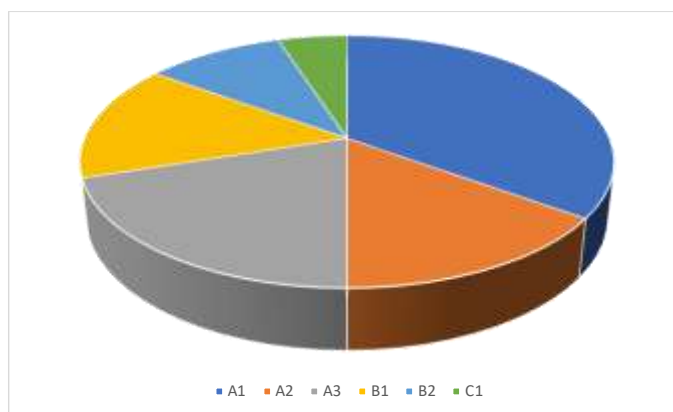


**Figure (1):** Pie chart showing sex distribution among the study population.

**Table (2):** A/O Classification system.

A/O Classification system	Number	Percentage
A1	7	35%
A2	8	15%
A3	6	20%
B1	5	15%
B2	2	10%
C1	2	5%
Total	<b>30</b>	<b>100%</b>

Fractures classified according to A/O classification system, 35% had A1 classification, 20% had A3, 15% had A2, 15% had B1, 10% had B2 and 5% had C1 (Table 2).



**Figure (2):** pie chart showing A/O Classification system.

**Table (3):** Operative and post operative data

Variables	Mean	Range
Operation time/minutes	155.2±10.9	115-190
Intraoperative bleeding/ml	194.6±15.7	170-220
Radiation time/seconds	160.1±20.4	105-250
Union time/weeks	19.4±4.1	17-22

The operative time ranged from: 115-190 minutes with an average: 155.2±10.9 minutes. Intraoperative bleeding ranged from 170-220 ml, with an average: 194.6±15.7 ml. Radiation time ranged from: 105-250 seconds with an average:

160.1±20.4 seconds. Union time: ranged from 17-22 weeks with an average: 19.4±4.1 weeks. The young age and male patients had better union than old age and female patients. (table 3).

**Table (4):** UCLA and MEPS Score.

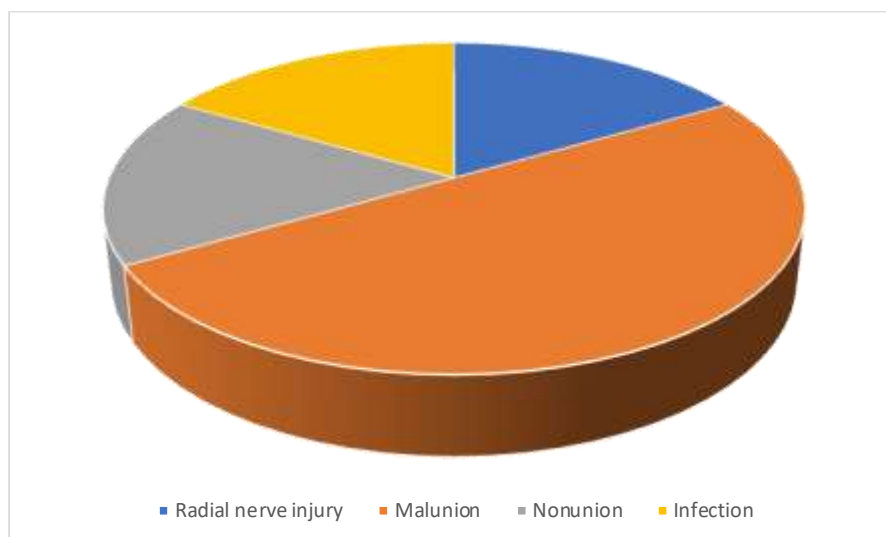
Variables	Median	Range
UCLA Score	34	30-35
MEPS Score	79	57 to 96

UCLA score ranged from 30 to 36 with median score 34. MEPS score ranged from 57 to 96 with median score 79 (Table 4).

**Table (5):** Complication.

Complication	Number	Percentage
Radial nerve injury	1	5%
Malunion	3	15%
Nonunion	1	5%
Infection	1	5%

There were some complications happened during the study : 15% had malunion and 5% had radial nerve injury, 5% had nonunion and 5% had infection. The patient who had infection was old age, diabetic and the operation took long time (table 5).



**Figure (3):** pie chart showing postoperative Complications.

**Table (6)** Correlation of demographic data with functional outcome

Parameter	Standard error	OR (95% CI)	P value
Age	0.082	0.664 (0.596–0.768)	0.0001
Sex(males)	0.49	3.023 (1.029–8/88)	0.044

This table shows that there is negative correlation between the patients age and functional outcome that mean that young age were better outcome than older patients. Also, we found a direct relation between males sex and better outcome.

## DISCUSSION

MIPPO technique for humeral shaft fractures has many advantages over the other methods used for fixation of the fractures. MIPPO usage reduces the need for significant surgery, soft tissue removal, periosteal blood supply interruption and iatrogenic radial nerve injury. With quick restoration of shoulder and elbow function and a scar that is acceptable in terms of appearance, MIPPO decreased the duration of recovery and the time for union<sup>(10)</sup>.

Most experts agree that using this technique keeps the blood supply to the fracture hematoma and bone fragments is unhampered. It stands for a more recent, beneficial, aesthetically superior (minimum surgical site scar), and acceptable mode of treatment. The outcomes are good and repeatable despite the technique's complexity and lengthy learning curve<sup>(11)</sup>.

The age range in the current study was 22–65 years, having a 39.4-5.4 year age range. Patients made up 55% men. With a mean age of 35.3 years, **Adriano et al**<sup>(12)</sup>, studied 31 patients (24 men and 7 women), 48 individuals, 36 male and 12 female, who were 33 years old on average, studied by **Mahajan et al**<sup>(13)</sup>, **Shetty et al**<sup>(14)</sup> studied 32 a group of people having a median age of 39 years (19 males and 13 females). **Elgohary et al**<sup>(10)</sup> study included 23 patients, with a

mean age of 36.2 years and 16 male and 7 female patients. The study by **Kulkarni et al**<sup>(15)</sup> consisted of 33 participants, with a mean age of 40.5 years. Ibrahim et al. evaluated 10 patients with a mean age of 38 years (7 men and 3 women).

According to the A/O classification system, fractures were categorized in the current study: 70% of patients are type A patients, 25% are type B patients, and 5% are type C patients. 15 patients with type A, 12 patients with type B, and 4 patients with type C, according to **Adriano et al**<sup>(12)</sup>. 20 patients with type A, 16 patients with type B, and 12 patients with type C, according to **Mahajan et al**<sup>(13)</sup> patients with type A, 6 patients with type B, and 13 patients with type C, according to **Shetty et al**<sup>(14)</sup>, **Elgohary et al**<sup>(10)</sup>: 16 type B patients and 7 type C individuals.

In the current study, operative time ranged from **115-190** minutes with the mean operative time: 155.2±10.9 minutes. When compared with other studies, it is found that longer time was taken in this study. **Sharma et al**<sup>(16)</sup> mean operative time: 97.5 minutes. **Adriano et al**<sup>(12)</sup> mean operative time: 89 minutes. **Mahajan et al**<sup>(13)</sup> mean operative time: 95.5 minutes. **Shetty et al**<sup>(14)</sup> mean operative time: 91.5 minutes. **Kulkarni et al**<sup>(15)</sup> mean operative time: 116 minutes. **Ibrahim et al**<sup>(11)</sup> mean operative time: 80 minutes.

Long operative time during MIPPO technique was taken during the reduction of the fracture which is the most difficult step in the operation especially in the reduction of transverse or short oblique fractures,

also during application of the plate and trial of reduction under C-arm.

In this study, union time ranged from: 17-22 weeks with mean time: 19.4±4.1 weeks that was higher than previous studies because our patients were older, percentage of DM was higher with longer time of operation. Keeping the soft tissue envelope intact, fracture hematoma and vascularity of the fragments are essentials for bone healing. **Apivatthakakul et al.**<sup>(17)</sup> union time ranged from 12-28 weeks with mean time: 14.6 weeks. **Zhiguan et al.**<sup>(18)</sup> union time ranged from 8-24 weeks with mean time: 15.29 weeks. **Esmailiejah et al.**<sup>(19)</sup> union time ranged from 12-24 weeks with mean time: 16 weeks. **Shetty et al.**<sup>(14)</sup> union time ranged from 10-20 weeks with mean time: 12.9 weeks. **Adriano et al.**<sup>(12)</sup> union time ranged from 8-28 weeks with mean time: 16.5 weeks. **Elgohary et al.**<sup>(10)</sup> union time ranged from 12-16 weeks with mean time: 12.8 weeks. **Kulkarni et al.**<sup>(15)</sup> union time ranged from 12-30 weeks with mean time: 18.3 weeks. **Ibrahim et al.**<sup>(11)</sup> union time ranged from 10-18 weeks with mean time: 11.6 weeks.

In the current study, UCLA score ranged from 30-35 points with median range: 34 points. According to UCLA scoring system that the maximum score is 35 points, excellent score ranged from 34 to 35 points that mean our results outcome were excellent. **Zhiguan et al.**<sup>(18)</sup> UCLA score ranged from 33-35 points with mean range: 34.76 points. **Esmailiejah et al.**<sup>(19)</sup> UCLA score ranged from 29-35 points with mean range: 33.1 points. **Sharma et al.**<sup>(16)</sup> UCLA score ranged from 27-35 points with mean range: 31 points. **Shetty et al.**<sup>(14)</sup> UCLA score ranged from 31-35 points with mean range: 33 points. **Ibrahim et al.**<sup>(11)</sup> UCLA scored exceptional to good in 9 cases, and fair in 1 case.

During MIPPO technique, when the decision is applying the plate anteriorly, usually radial nerve is out of the field and not seen or explored during the procedure, so caution during application of the retractors and during insertion of the distal screws. In this study, 5% of patients had radial nerve palsy after the operation that treated with cock-up splint and followed up with rehabilitation programmes. This patient was fully recovered within 2 months. **Fang et al.**<sup>(20)</sup> in a study of 22 patients, radial nerve palsy found in 1 patient. **Sanjeevaiah et al.**<sup>(21)</sup> in a study of 42 patients, radial nerve palsy found in 1 patient. **Adriano et al.**<sup>(12)</sup> in a study of 31 patients, radial nerve palsy found in 2 patients. **Elgohary et al.**<sup>(10)</sup> in a study of 23 patients, radial palsy injury found in 1 patient. **Kulkarni et al.**<sup>(15)</sup> in a study of 33 patients, radial nerve palsy found in 4 patients.

In the present study, malunion in cases of fracture shaft humerus treated with MIPPO technique usually is not a big problem if it lies within the acceptable ranges of fracture reduction alignment. In this study, malunion occurred in 3 cases (15%), 2 cases with varus malunion of about 5° (10%), 1 case with valgus malunion of about 5° (5%). **Sanjeevaiah**

**et al.**<sup>(21)</sup> in a study of 42 patients, malunion of 4° varus in 2 patients. **Adriano et al.**<sup>(12)</sup> in a study of 31 patients, malunion of 5° valgus in 2 patients. **Sharma et al.**<sup>(16)</sup> in a study of 11 patients, malunion of 5° varus in 1 patient and 5° valgus in 1 patient. **Shetty et al, 2016.**<sup>(14)</sup> in a study of 32 patients, malunion of 3° varus in 4 patients, 5° varus in 1 patient and 3° valgus in 2 patients. **Elgohary et al.**<sup>(10)</sup> in a study of 23 patients, malunion of 10° varus in 3 patients. **Kulkarni et al.**<sup>(15)</sup> in a study of 33 patients, malunion of 5° varus in 4 patients. **Ibrahim et al.**<sup>(11)</sup> in a study of 10 patients, malunion of 10° varus in 1 patient.

In a study of **Mahmoud et al.**<sup>(22)</sup> who assess the shoulder function and rate of complications among two different options of fixation, intramedullary nailing, and minimal invasive plate osteosynthesis (MIPO) in young adults. They assessed the shoulder function between the nail and MIPO groups using ASES and UCLA scores and found superior functional outcomes in the MIPO than the nail group, and the difference was significant.

In this study, nonunion developed in one patient (5%) who was old age, diabetic, had highly comminuted fracture and the operation took long time.

**Concha et al.**<sup>(23)</sup> in a study of 35 patients, nonunion with revision and bone grafting done in 3 patients. **Esmailiejah et al.**<sup>(19)</sup> in a study of 32 patients, nonunion in 1 patient. **Mahajan et al.**<sup>(13)</sup> in a study of 48 patients, nonunion with revision and bone grafting done in 2 patients.

Most cases of postoperative infection after MIPPO technique in the literature was superficial infection with short course of antibiotics and wound care. In this study, only one patient (5%) had postoperative infection. **Concha et al.**<sup>(23)</sup> in a study of 35 patients, superficial infection in 2 patients. **Huri et al.**<sup>(24)</sup> in a study of 14 patients, superficial infection in 2 patients. **Sharma et al.**<sup>(16)</sup> in a study of 11 patients, superficial infection in 1 patient. **Mahajan et al.**<sup>(13)</sup> in a study of 48 patients, superficial infection in 2 patients.

## CONCLUSION:

In shaft humerus fractures, using plate osteosynthesis with minimally invasive anterior bridge plating produced encouraging results. They offer the fracture site some support, and the fracture hematoma is not disturbed. MIPO keeps the blood vessels healthy, which lowers the danger of infection and wound disintegration.

**Sources of funding:** Funding agencies in the public, commercial, or nonprofit sectors did not provide a particular grant for this research.

**Conflicts of interest:** There are no conflicts of interest, according to the authors.

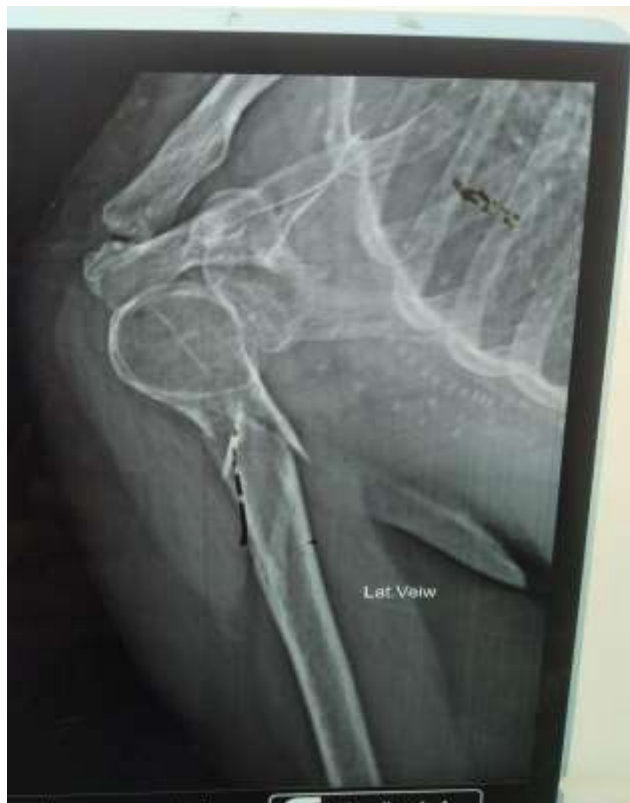## REFERENCES

1. **Igbigbi PS, Manda K.** Epidemiology of humeral fractures in Malawi. *Int Orthop* 2004; (28):38-41.

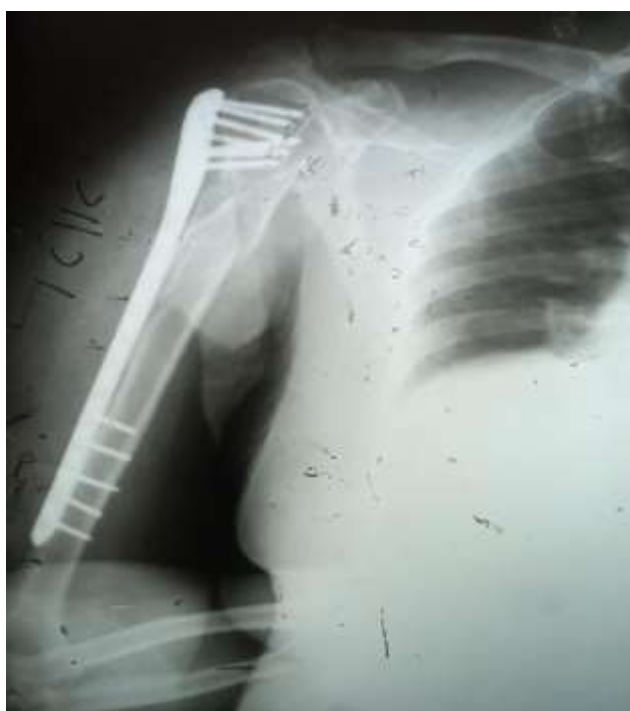2. **Gosler MW, Testroote M, Morrenhof J, Janzing HM.** Surgical versus nonsurgical interventions for treating humeral shaft fractures in adults. *Cochrane Database Syst Rev* 2012; 18:32.
3. **Rutgers M, Ring D.** Treatment of diaphyseal fractures of the humerus using a functional brace. *J Orthop Trauma* 2006, (20):597–601.
4. **Sarmiento A, Waddell JP, Latta LL.** Diaphyseal humeral fractures: treatment options. *Instr Course Lect* 2002; (51):257-69.
5. **Heineman DJ, Bhandari M, Nork SE, Ponsen KJ, Poolman RW.** Treatment of humeral shaft fractures-meta-analysis reupdated. *Acta Orthop* 2010; 81:7.
6. **An,Zeng B,He X,Chen Q,Hu S.** Plate osteosynthesis of middistal humeral shaft fracture: minimally invasive versus conventional open reduction technique. *Int Orthop* 2010; 34(1):131-7.
7. **Erwin Denis, Stefaan Nijs, An Sermon, Paul Boss.** Operative treatment of humeral shaft fractures. Comparison of plating and intramedullary nailing. *Acta Orthop Belg* 2010 ;( 76): 35-42.
8. **Ji F, Tong D, Tang H.** Minimally invasive percutaneous plate osteosynthesis (MIPPO) technique applied in the treatment of humeral shaft distal fractures through a lateral approach. *Int Orthop* 2009; 33(2): 43-7.
9. **Cantu RV, Koval KJ.** The use of locking plates in fracture care. *J Am Acad Orthop Surg* 2006; 14:183-90.
10. **Elgohary HSA, Mawla TA.** Minimally Invasive Plate Osteosynthesis (MIPO) for Treatment of Comminuted Mid- Distal Third Humeral Shaft Fractures through the Anterior Approach. *J Orthop Surg Tech* 2017; 1(2):33-41.
11. **Ibrahim, M., & Rathod, V. H.** A clinical study of minimal invasive anterior bridge plating for humerus shaft fractures. *International Journal of Orthopaedics*, 2018, 4(2), 01-05.
12. **Adriano F. Mendes Júnior, José da Mota Neto , Leandro F. De Simoni , Carlos Alberto Menezes Mariosa , Bruno G. S. e Souza, Valdeci de Oliveira , Elmano de A. Loures.** MIPO for Humeral Shaft Fractures: Correlation between Radiographic, DASH, and SF-12 results. *Acta Shoulder Elbow Surg* 2016, 35- 43.
13. **Mahajan AS, Kim YG, Kim JH, D'sa P, Lakhani A, Ok HS.** Is Anterior Bridge Plating for Mid-Shaft Humeral Fractures a Suitable Option for Patients Predominantly Involved in Overhead Activities? A Functional Outcome Study in Athletes and Manual Laborers. *Clin Orthop Surg.* 2016; 8: 358-66.
14. **M Shantharam Shetty, M Ajith Kumar, Sujay KT, Abhishek R Kini, Kanthi Kiran G.** Minimally invasive plate osteosynthesis for humerus diaphyseal fractures. *Indian J Orthop* 2016; (6):521-6.
15. **Kulkarni M, Kulkarni V, Kulkarni S.** Treatment of Humerus Diaphyseal Fractures with Minimally Invasive Plate Osteosynthesis. *J Fract Sprains* 2017; (1): 1-7.
16. **Jayant Sharma, Avinash Jain, Pooja Gupta Jain, Prashant Upadhyaya.** Anterior Bridge Plating with Mini Incision MIPO Technique for Humerus Diaphyseal Fractures. *Indian J Orthop* 2015; 1(3):171-5.
17. **Apivatthakakul, T., Phornphutkul, C., Laohapoonrungsee, A., & Sirirungruangsarn, Y. (2009).** Less invasive plate osteosynthesis in humeral shaft fractures. *Operative Orthopädie und Traumatologie*, 21(6), 602-613.
18. **Zhiquan An, Bingfang Zeng, Xiaojian He, Qi Chen, Shundong Hu.** Plating osteosynthesis of mid-distal humeral shaft fractures: minimally invasive versus conventional open reduction technique. *Int Orthop* 2010; 34:131-35.
19. **Ali Akbar Esmailiejah, Mohammad Reza Abbasian, Farshad Safdari, Keyqobad Ashoori.** Treatment of Humeral Shaft Fractures: Minimally Invasive Plate Osteosynthesis versus Open Reduction and Internal Fixation. *Trauma Mon.* 2015; 20(3):262-71.
20. **Fang Ji, Dake Tong , Hao Tang , Xiaobing Cai , Qulin Zhang , Jingfeng Li , Qiugen Wang.** Minimally invasive percutaneous plate osteosynthesis (MIPPO) technique applied in the treatment of humeral shaft distal fractures through a lateral approach. *Int Orthop* 2009; 33:543–47.
21. **Sanjeevaiah, Praneeth Reddy.** Minimally Invasive Plate Osteosynthesis (MIPO) in Humeral Shaft Fractures – Biomechanics – Design – Clinical Results. *JEMDS* 2015; (4): 9449-56.
22. **Mahmoud, H. F., Farhan, A. H., & Fahmy, F. S. (2021).** Assessment of Shoulder Function after Internal Fixation of Humeral Diaphyseal Fractures in Young Adults: A Prospective Comparative Study. *Advances in orthopedics*, 2021, 9471009. <https://doi.org/10.1155/2021/9471009>
23. **Concha JM, Sandoval A, Streubel PN.** Minimally invasive plate osteosynthesis for humeral shaft fractures: are results reproducible? *Int Orthop* 2010; 34(8):1297-305.
24. **Gazi Huri,Omer Sunar Bicer, Hakan Ozturk, Mehmet Ali Deveci, Ismet Tan.** Functional outcomes of minimal invasive percutaneous plate osteosynthesis (MIPPO) in humerus shaft fractures: a clinical study. *Acta*

Orthop Traumatol Turc 2014; 48(4):406-12.

### **Case presentation**

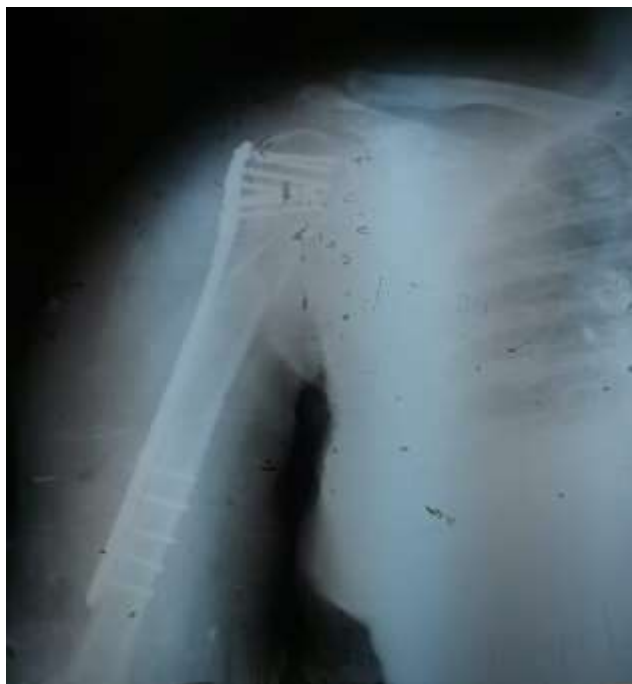

**Figure (4):** pre operative X-Ray

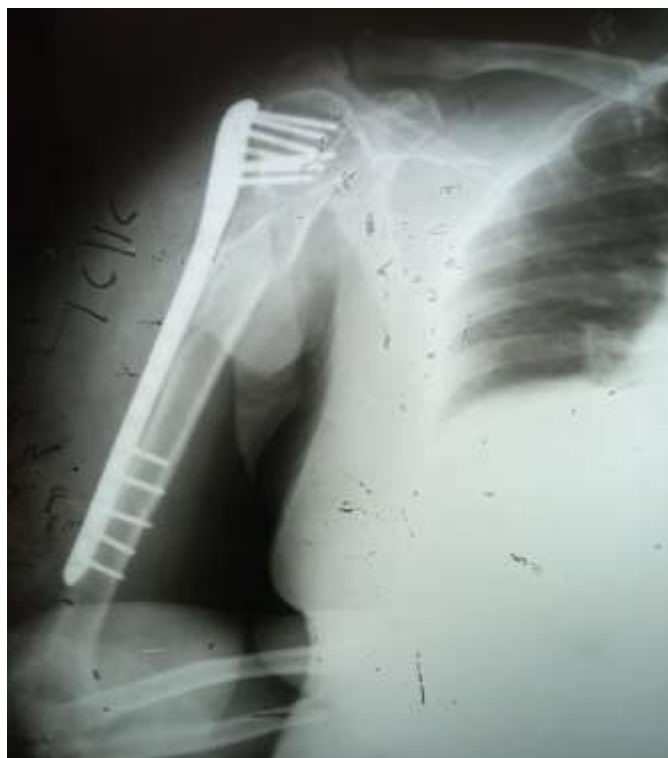

**Figure (5):** one month post operative X-Ray

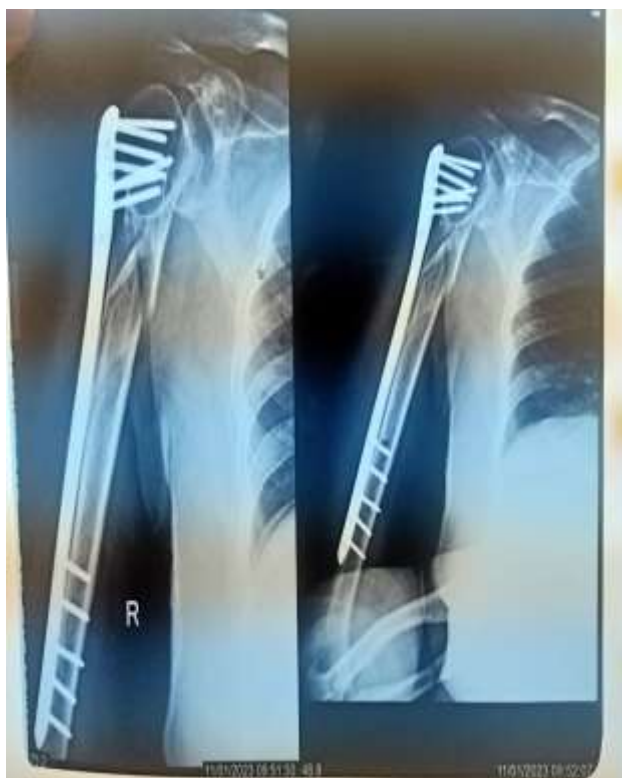



**Figure (6):** three months post operative X-Ray



**Figure (7):** six months post operative X-Ray



**Figure (8):** eight months post operative X-Ray