



Hepatocellular Carcinoma: Clinical presentation and Diagnosis: Review Article

¹Amr Samir Ibrahim, ¹Khalid Ali Muftah Abdelaziz, ²Fedaa Nabil Mohammad,

¹Internal Medicine Department, Faculty of Medicine, Zagazig University

²Medical Microbiology and Immunology Department, Faculty of Medicine, Zagazig University

Corresponding author: Khalid Ali Muftah Abdelaziz

Email: khalid.a.abdalaziz87@gmail.com, **Mobile:** 01025314362

Article History: Received: 26.06.2023 Revised:04.07.2023 Accepted: 22.07.2023

Abstract:

Hepatocellular carcinoma (HCC) is one of the leading causes of cancer-related death and is currently the main event leading to death in patients with cirrhosis. Evolving information suggests that the metabolic syndrome with non-alcoholic liver disease may be an important cause of HCC in addition to viral hepatitis and alcohol-induced liver disease. The molecular pathogenesis is extremely complex and heterogeneous. To date the molecular information has not impacted on treatment decisions. Periodic surveillance imaging of patients with cirrhosis is widely practiced, especially because diagnostic, radiographic criteria for early-stage HCC have been defined (including nodules between 1 and 2 cm) and effective treatment is available for tumours detected at an early stage.

Keywords: HCC, HCV, HBV.

Introduction:

Hepatocellular carcinoma (HCC) is a primary malignancy of the liver and mainly occurs in patients having chronic liver disease and cirrhosis. The hepatic stem cells are believed to be the cell(s) of origin. Tumor advancement takes patterns of local extension, intrahepatic metastases, and distant metastases (Cicalese, 2015).

HCC is a worldwide health problem. It is the fifth most common malignancy worldwide and the second most common cause of cancer-related death. This variance between occurrence and fatality ensures that it is an aggressive tumor with a poor prognosis. Incidence of HCC is rapidly

growing in the West due to an increased epidemic of its risk factors like alcohol, fatty liver, and viral hepatitis (Heimbach et al., 2018).

The global distribution of HCC is variable because it is most prevalent in areas with widespread chronic hepatitis B virus (HBV) infection. Additionally, the Western world is complaining of rising HCC prevalence as a result of migration from HBV-endemic regions, hepatitis C virus (HCV) infection, alcoholic cirrhosis, and non-alcoholic steatohepatitis associated with the obesity epidemics (Kim et al., 2016).

Hepatocellular carcinoma in Egypt

HCC represents a serious public health issue in Egypt. In multiple Egyptian regional registries, liver cancer is the first most frequent cancer in men and the second in women. In Egypt, liver cancer counts for 11.75% of the malignancies of the digestive organs and 1.68% of the total malignancies (Ashmawy et al., 2019).

HCC forms 70.48% of all liver tumors among Egyptians and it is considered the main complication of cirrhosis, and

represents a growing incidence in Egypt, which may be due to a shift in the relative importance of (HBV) and HCV as primary risk factors, and advancements in screening programs and diagnostic materials (Mohamed et al., 2022).

Although most HCC develop on underlying chronic liver disease, some may happen on a normal liver and usually match specific types, including fibrolamellar HCC (Holah et al., 2015).

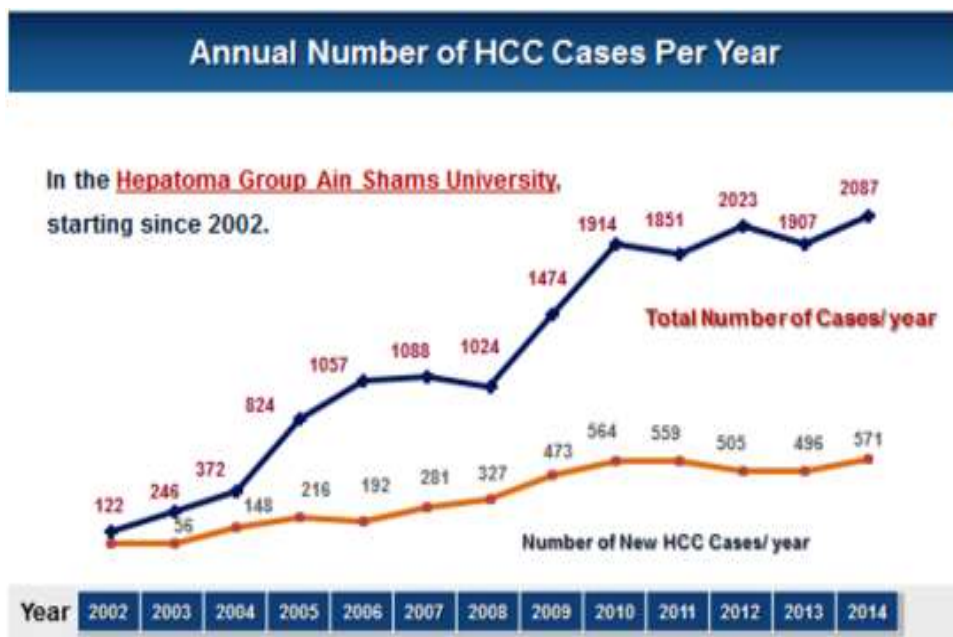


Figure (1): Annual number of HCC cases per year in Egypt (Shaker, 2016).

Risk factors of HCC

HCC is a complicated disease related to many risk factors and cofactors such as cirrhosis, viral hepatitis, schistosomiasis, diabetes mellitus, aflatoxins mainly Aflatoxin B1, alcohol, smoking, and other factors (Pascual et al., 2016).

1. Cirrhosis

Cirrhosis is a leading risk factor for the development of HCC, about 30%-35% of all cirrhotic patients will gain HCC in the course of their disease. It is evaluated that the annual risk of developing HCC in cirrhotic patients is between 1-8% based on the etiology (chronic viral hepatitis, alcohol, non-alcoholic fatty liver disease, and hereditary metabolic diseases or autoimmune) (Pascual et al., 2016).

2. Viral hepatitis (HBV and HCV)

Chronic infection is a leading risk factor for HCC. The incidence of HCV infection is higher in Egypt and Japan. There is a significant link between HCV chronic infection and the development of HCC, really, the risk of developing HCC in that patients increase between 20 and 30 times (**Ozakyol, 2017**).

Patients with high viral loads and HCV genotype 1b infection have a higher risk of HCC occurrence. Patients infected with HCV and carrying HCC have higher levels of inflammatory markers of oxidative stress, so the immune response can be another cofactor in the transformation from cirrhosis to HCC in HCV-infected patients (**Lee et al., 2014**).

3. Schistosomiasis

The infection by *Schistosoma* is endemic in tropical areas of Africa, the Caribbean, Asia, and South America. The species of *Schistosoma japonicum*, already identified as a possible human carcinogen, has been associated with the risk of developing HCC in patients infected by HBV and HCV (**Nelwan, 2020**).

It is well reported that *Schistosoma haematobium* and *mansoni* were endemic in Egypt, but there is a steady decline in the incidence of both types of schistosoma due to the strategy adopted in 1997 with Praziquantel mass treatment (**Barakat, 2012**).

4. Gender and race

Males are at higher risk than females, African males commonly pick up HBV at a younger age, and this considerably increases their risk of having liver cancer (**Kew, 2010**).

5. Age

HCC seldom occurs among adolescents and forms less than 1% of all malignant neoplasms among children who are under the age of 20 years. Inherited metabolic disorders specifically, alpha-1-antitrypsin deficiency, hereditary tyrosinemia, and glycogen storage disease type 1 are associated with cirrhosis in children and HCC. Primary liver cancer also occurs in children with bile salt export pump deficiency and biliary atresia. Prevalence rates peak in males who are older (65-75) years (**Herbst and Reddy, 2012**).

6. Diabetes mellitus (DM)

DM can increase the risk of HCC by 2–3-fold without the presence of other main HCC risk factors (**Ziada et al., 2016**).

7. Smoking

Smoking increases the risk of HCC in patients having viral hepatitis. Cigarettes are a main source of 4-aminobiphenyl polycyclic aromatic hydrocarbons (a hepatic carcinogen) which has been entangled as a causative risk factor for HCC. Tobacco smoking is associated with a decrease of tumor suppressor gene p53 and accumulation of excess iron in hepatocytes in heavy smokers, which prompts fibrosis and favors the development of HCC (**Ziada et al., 2016**).

8. Alcohol

Alcohol drinking in a heavy manner can lead to cirrhosis, which in turn enhances the development of HCC (**Huang et al., 2023**).

9. Aflatoxin

Aflatoxin is a set of fungal metabolites produced by *Aspergillus flavus* growing on badly stored food. It is popular in sub-Saharan Africa and regions of East and Southeast Asia and has been found to be a risk factor for HCC. These regions have a high rate of HBV infection, and this increases the risk of HCC (**Herbst and Reddy, 2012**).

The International Agency for Research on Cancer classified Aflatoxins B1 (AFB1) as a class 1 human carcinogen. Many studies in Egypt have exhibited the presence of AFB1-albumin adducts in human blood, and AFB1 has been revealed at moderate to high levels in food samples purchased in Egypt (**Saleh et al., 2015**).

10. Non-Alcoholic Fatty Liver Disease (NAFLD)

Hepatic disorders associated with obesity and metabolic syndrome are considered risk factors for HCC. NAFLD carries the highest risk for HCC because it can advance to cirrhosis, but there is increasing worry that NAFLD-associated HCC may also occur in non-cirrhotic liver (**Åberg et al., 2023**).

11. Genetic diseases and HCC

Some genetic diseases can be risk factors of HCC as Hemochromatosis (is a common inherited disorder of iron metabolism, characterized by excessive gastrointestinal iron absorption and by consequent increased iron storage in all organs except for the brain and nervous tissue), Glycogen storage disease (is caused by the impairment of glucose-6-phosphatase activity, with consequent excess glycogen

storage in the liver), Type 1 Tyrosinemia (is an autosomal recessive disorder caused by a deficiency of the last enzyme in the catabolic pathway of tyrosine, fumarylacetoacetate hydrolase (FAH), located on chromosome 15q23–q25), and Alpha 1 antitrypsin deficiency (is an autosomal recessive disease that results from several mutations in the SERPINA1 gene located on chromosome 14q32.1) (**Dragani, 2010, Pellicelli, 2022**).

12. Other factors

HCC may occur on underlying cholelithiasis. Some cases exhibit malignant transformation of liver adenomas in women having oral contraceptive pills, but related studies did not prove the results. Nitrogenous compounds (used in cheeses, smoked fish, sausages, and other foods) might increase the risk of liver disease and cancer (**Liu et al., 2022**).

Individuals who have a family history of first-degree liver cancer can develop liver cancer more than the general population by 4 times, proposing that certain shared genetic and environmental factors would affect the risk of developing liver cancer (**Baecker et al., 2019**).

The clinical picture of HCC

Patients who acquire HCC usually have no symptoms other than those associated with their chronic liver disease. Suspicion for HCC should be raised if patients with previously compensated cirrhosis develop decompensation such as ascites, encephalopathy, jaundice, or variceal bleeding. These complications are usually related to the expansion of the tumor into the

hepatic or portal veins, or arteriovenous shunting happened by the tumor (D'amico et al., 2014).

Some patients may complain from mild to moderate upper abdominal pain, early satiety, weight loss, or a palpable mass in the upper abdomen. These symptoms usually represent an advanced condition (Schwartz and Carithers, 2016).

Other uncommon clinical pictures include diarrhea, a paraneoplastic syndrome that can manifest as hypoglycemia, hypercalcemia, thrombocytosis, erythrocytosis, diarrhea of watery nature, and fever that might develop in relation to central tumor necrosis. The presence of any of these presentations other than erythrocytosis, is generally associated with a poor prognosis (Attwa and El-Etreby, 2015).

Surveillance strategy

Target population

Surveillance can be defined as the periodic use of very sensitive diagnostic tools to discover early disease in a certain high-risk population such as cirrhosis, HBV infection, and HCV infection. The American Association for the Study of Liver Disease (AASLD) recommends HCC surveillance for the following high-risk groups: Asian female hepatitis B carriers over age 50, Asian male hepatitis B carriers over age 40, Africans and African Americans with hepatitis B, hepatitis B carriers having a family history of HCC, cirrhotic hepatitis B carriers, people having hepatitis C cirrhosis, persons having genetic hemochromatosis and cirrhosis, individuals with primary

biliary cirrhosis (stage 4), people having alpha 1-antitrypsin deficiency and cirrhosis and persons having cirrhosis due to other causes (Yu, 2016).

Radiological tests

i. Ultrasonography (US)

It has been the radiographic technique of choice for HCC surveillance for a long time, in addition, a meta-analysis informed that US sensitivity is 94% in finding lesions and its specificity is >90% (Yu, 2016).

US shows multiple advantages because it is noninvasive, has low cost, and shows high availability and high specificity, but it represents many disadvantages like low sensitivity, and US depends upon the operator. Therefore, it is better used as a screening test rather than a diagnostic test for HCC. On the other hand, contrast-enhanced ultrasound (CEUS) can be utilized as a diagnostic test due to its high sensitivity which may be equal to that of dynamic CT or MRI in the diagnosis of HCC (Omata et al., 2010).

HCC has variable imaging presentation. Nearly, the small focal HCC seems hypoechoic as compared to a healthy liver. large lesions represent heterogeneous patterns due to fibrosis, necrosis, fatty change, and calcification. A peripheral halo of hypoechogenic might be noticed with focal fatty sparing, diffuse lesions that might be difficult to be differentiated from background cirrhosis (Kefeli et al., 2017).

ii. Multiphase computerized tomography (CT) and magnetic resonance imaging (MRI) with contrast

HCC lesions represent high arterialization and low existence of contrast substances within the portal phase of imaging (washout) on each CT and MRI scan (**Wald et al., 2013**).

CT and MRI can reveal tumors ≥ 2 cm by a sensitivity of 90%, but tumors ranging from 1 to 2 cm could be detected by a sensitivity of 65% and 80%–92% while tumors less than 1cm could be detected by a sensitivity of 10% for CT and 34%–71% for MRI. CT and MRI are recommended in patients having ambiguous results after using US as a primary technique for screening (**Balogh et al., 2016**).

To characterize the lesions in detecting HCC we need an accurate technical performance of 4-phase CT scanning with imaging in both hepatic arterial and venous–portal venous and delayed contrast images, that need is due to the presence of continuous changes in the supplying vessels and hemodynamic condition during hepatocarcinogenesis. The sensitivity of this technique in detecting tumors larger than 1 cm reaches 60–94.4%, but that sensitivity diminished by 33–45% for detecting tumors less than 1 cm (**Kefeli et al., 2017**).

The basic feature of HCC on CT is late arterial enhancement with washout compared to the liver parenchyma through the venous or delayed phases (3–5 min post-injection). That specific form of enhancement gives this technique high specificity and positive predictive value and makes it the noninvasive ideal diagnostic test for HCC (**Willatt et al., 2017**).

MRI is the best test for the assessment of HCC in patients with abnormal liver lesions detected by US. HCC representation differs on MRI due to various factors like the degree of fibrosis, degree of necrosis, histologic pattern, hemorrhage, and degree of fatty change (**Kefeli et al., 2017**).

MRI can properly show the mosaic appearance of the large HCCs more than Multi-Detector Computed Tomography MDCT due to the best soft tissue contrast. MRI diagnosis of HCC mainly depends upon the enhancement pattern on dynamic post-gadolinium-enhanced scans because the signal intensity of unenhanced images is not specific, also it overlaps with various other focal lesions (**Hennedige and Venkatesh, 2012**).

The detection and characterization of HCC by MRI has very high sensitivity and specificity. If the lesion is between two and three centimeters in size, the sensitivity of the MRI is 84%. Greater sensitivity and specificity, particularly for smaller tumors and diffuse HCC, good safety, low risk of kidney damage, and absence of ionizing radiation are only a few of the benefits that MRI has over CT (**Tiwari et al., 2014**).

Serological markers

I. Serum Alpha-Fetoprotein (AFP)

Serum AFP has been usually and traditionally utilized as a tumor marker of HCC. But 35% of patients with small HCC lesions show no increase in its levels so it may be high in patients having active hepatitis or active hepatocyte regeneration. It should be noted that AFP levels are demanded for diagnosis more than for

surveillance. If serum AFP level is added to US results, 6-8% of cases missed by US could be detected (Zong et al., 2020).

National Comprehensive Cancer Network (NCCN) guideline reported that AFP enhances the detection of HCC lesions if it is combined with US in the screening sessions for high-risk individuals. If cirrhotic patients have an elevated or rising AFP, a diagnostic examination should be done despite the absence of a liver nodule in US as recommended by American College of Gastroenterology (ACG) guidelines (Yu, 2016).

II. Lens culinaris agglutinin-reactive fraction of α -Fetoprotein (AFP-L3)

It is expressed as a proportion of AFP, and it is raised in patients having HCC. It shows high specificity for HCC diagnosis when AFP levels are >20 ng/mL. Patients who have a measured AFP-L3 by a level >10% are sorted as high-risk groups for HCC. Unfortunately, AFP-L3 may indicate a more aggressive tumor, invasive growth pattern, shorter doubling time, vascular infiltration, and intrahepatic spread (Chen et al., 2020).

III. Des-Gamma-Carboxyprothrombin (DCP)

Des-Gamma-Carboxyprothrombin is secreted by malignant hepatocytes as a result of an acquired post-translational disorder in the vitamin K-dependent carboxylase system, this system is also named prothrombin induced by vitamin K absence II (PIVKA II). The specificity of the DCP is about 91% while its sensitivity is low at 41%. DCP shows a high specificity in

comparison to AFP which shows specificity at 70%. DCP returns to normal level after successful tumor resection. DCP levels >125m (AU) anson unit /mL can distinguish HCC from cirrhosis and chronic hepatitis (Balogh et al., 2016).

IV. MicroRNAs

miRNAs are widely considered useful biomarkers and they have potent therapeutic effects on cancers. miRNAs play a crucial role in many biological processes like growth, apoptosis, cell proliferation, cell differentiation, as well as carcinogenesis. So, they are considered powerful and important biomarkers for diagnosis, staging, progression, prognosis, and response to treatment. Thus, researchers give miRNAs great attention to estimate the link between HCC and miRNA levels (Yu et al., 2016).

Previous studies mentioned that miRNA-21 acts as an onco-miR, while miRNA-29c and miRNA-155 act as tumor suppressor miRNA in HCC. The three miRNAs might be detected in HCC and could be used as minimally invasive biomarkers in HCC detection. The miRNA-155 expression levels showed significant elevation in HCC tissue with an increase of 1.5–6 times compared to normal liver tissue (Lv et al., 2020, Ratnasari et al., 2022).

V. Glypican-3

Glypican (GPC) is defined as a family of heparan sulfate proteoglycans that attaches to the surface of a cell by a lipid anchor. This family consists of six members (GPC1-6) (Sparn et al., 2022).

GPC-3 is identified to be a specific oncofetal biomarker for the diagnosis of HCC (Li, 2023, Mauro et al., 2023).

The extremely high specificity of serum GPC-3, which varies from 90% to 100% in the diagnosis of HCC. GPC-3 sensitivity is, however, not very high. When coupled with AFP, it became more sensitive (Parikh et al. 2020).

VI. Proteomic profiling

Proteomic-based biomarkers have provided modern tools to discover early transformations in protein and metabolite expression in HCC, but they currently cannot be used for surveillance or diagnosis (Kefeli et al., 2017).

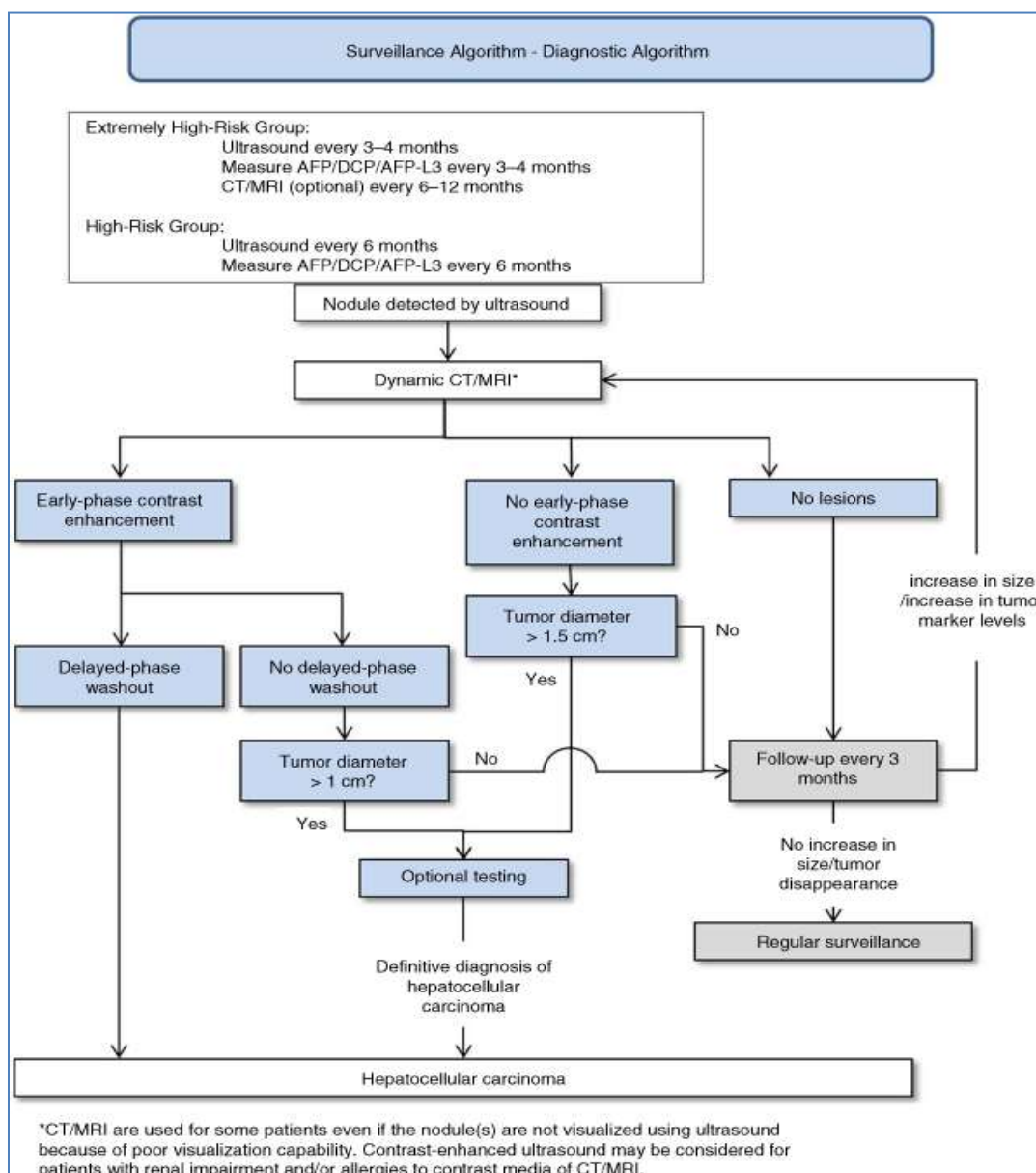


Figure (2): Algorithm for surveillance and diagnosis in the 3rd JSH-HCC Guidelines (Kokudo et al., 2015)

Diagnosis of HCC

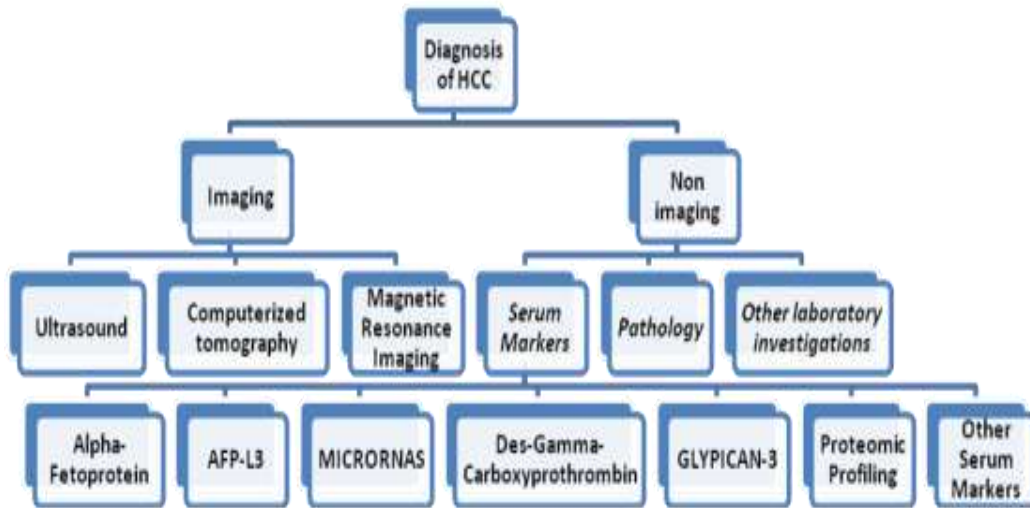


Figure (3): Diagnosis of HCC (Kokudo et al., 2015)

References:

- Cicalese L (2015).** Hepatocellular Carcinoma. Medscape, emedicine.medscape.com/article/197319-overview, 2015.
- Heimbach JK, Kulik LM, Finn RS (2018).** AASLD Guidelines for the Treatment of Hepatocellular Carcinoma. *Hepatology*; 67 (1): 358-380.
- Kim JU, Shariff MIF, Crossey MME (2016).** Hepatocellular carcinoma: Review of disease and tumor biomarkers. *World J Hepatol*; 8(10): 471–484.
- Ashmawy, M. M., Mahmoud, A., El-Masry, M. A., et al. (2019).** Risk factors of malignant portal vein thrombosis in cirrhotic patients with hepatocellular carcinoma. *Journal of Current Medical Research and Practice*, 4(2), 203.
- Mohamed, M. S., Lashin, A., Mohamed, S. A., et al. (2022).** Serum Level of Cluster of Differentiation 166 in Diagnosis of Hepatocellular Carcinoma. *Benha medical journal*, 39(2), 397-408.
- Holah NS, El-Azab DS, Aiad HA (2015).** Hepatocellular carcinoma in Egypt. epidemiological and histopathological properties. *Menoufia Medical Journal*; 28(3): 718-724.
- Shaker M (2016).** Epidemiology of HCC in Egypt. *Gastroenterol. Hepatol. Open Access*; 4(3): 97.
- Pascual S, Herrera I and Irurzun J (2016).** New advances in hepatocellular carcinoma. *World J Hepatol*; 8(9): 421–438.
- Ozakyol, A. (2017).** Global epidemiology of hepatocellular carcinoma (HCC epidemiology). *Journal of gastrointestinal cancer*, 48, 238-240.
- Lee, M. H., Yang, H. I., Yuan, Y., et al. (2014).** Epidemiology and natural history of hepatitis C virus infection. *World journal of gastroenterology: WJG*, 20(28), 9270.
- Nelwan, M. (2020).** An introduction to schistosomiasis. Available at SSRN 3692213.
- Barakat RMR (2012).** Epidemiology of Schistosomiasis in Egypt: Travel

- through Time: Review. *J Adv Res*; 4(5): 425–432.
13. **Kew MC (2010).** Hepatocellular carcinoma in African blacks: recent progress in etiology and pathogenesis. *World J Hepatol*; 2 (2): 65–73.
 14. **Herbst DA and Reddy KR (2012).** Risk factors for hepatocellular carcinoma, CLD, *Clinical Liver Disease*; 1(6): 180–182
 15. **Ziada DH, Sadany SE, Soliman H (2016).** Prevalence of hepatocellular carcinoma in chronic hepatitis C patients in Mid Delta, Egypt: A single center study. *Journal of the Egyptian National Cancer Institute*; 28 (4): 257 – 262.
 16. **Huang, Y., Xu, L., Huang, M., et al. (2023).** Repeat hepatic resection combined with intraoperative radiofrequency ablation versus repeat hepatic resection alone for recurrent and multiple hepatocellular carcinoma patients meeting the Barcelona Clinic Liver Cancer stage A: A propensity score-matched analysis. *Cancer Medicine*.
 17. **Saleh DA, Amr S, Jillson IA (2015).** Preventing hepatocellular carcinoma in Egypt: results of a Pilot Health Education Intervention Study. *BMC Res Notes*; 8: 384.
 18. **Åberg, F., Byrne, C. D., Pirola, C. J., et al. (2023).** Alcohol consumption and metabolic syndrome: Clinical and epidemiological impact on liver disease. *Journal of Hepatology*, 78(1), 191-206.
 19. **Dragani, T. A. (2010).** Risk of HCC: genetic heterogeneity and complex genetics. *Journal of hepatology*, 52(2), 252-257.
 20. **Pellicelli, A. (2022).** Underlying Liver Disease. In *Hepatocellular Carcinoma* (pp. 27-34). Cham: Springer International Publishing.
 21. **Liu, C.-H., Liu, C.-J., Su, T.-H., et al. (2022).** Serum Mac-2 Binding Protein Glycosylation Isomer to Predict the Severity of Hepatic Fibrosis in Patients with Hepatitis C Virus Infection. *Diagnostics*, 12, 2650-55.
 22. **Baecker, A., Wu, M., Zhou, J. Y., et al. (2019).** Family history of liver cancer may modify the association between HBV infection and liver cancer in a Chinese population. *Liver International*, 39(8), 1490-1503.
 23. **D'amico, G., Pasta, L., Morabito, A., et al. (2014).** Competing risks and prognostic stages of cirrhosis: a 25□ year inception cohort study of 494 patients. *Alimentary pharmacology & therapeutics*, 39(10), 1180-1193.
 24. **Schwartz JM and Carithers RL (2016).** Clinical features and diagnosis of primary hepatocellular carcinoma. www.uptodate.com/contents/epidemiology-and-etiological-associations-of-hepatocellular-carcinoma.
 25. **Attwa MH and El-Etreby SA (2015).** Guide for diagnosis and treatment of hepatocellular carcinoma. *World J Hepatol* 2015; 7(12): 1632–1651.
 26. **Yu, S. J. (2016).** A concise review of updated guidelines regarding the management of hepatocellular carcinoma around the world: 2010-2016. *Clinical and molecular hepatology*, 22(1), 7.
 27. **Omata M, Lesmana L, Tateishi R (2010).** Asian Pacific Association for the Study of the Liver consensus recommendations on hepatocellular carcinoma. *Hepatol Int*; 4: 439 -474.
 28. **Kefeli A, Basyigit S and Yeniova AO (2017).** Diagnosis of Hepatocellular Carcinoma. *Medicine » Oncology » "Updates in Liver Cancer"*, book, Edited by Hesham Abdeldayem, Menoufia

- University; Print ISBN 978-953-51-3063-5.
29. **Wald C, Russo MW, Heimbach JK (2013).** New OPTN/UNOS policy for liver transplant allocation: standardization of imaging, diagnosis, classification and reporting of hepatocellular carcinoma. *Radiology*; 266(2): 376–382.
 30. **Balogh J, Victor III D, Asham EH (2016).** Hepatocellular carcinoma: a review. *Dove Press Open Access to Scientific and Medical Research*; 3: 41-53.
 31. **Willatt J, Ruma JA, Azar SF (2017).** Imaging of hepatocellular carcinoma and image guided therapies: How we do it. *Cancer Imaging*; 17 (1): 9.
 32. **Hennedige T and Venkatesh SK (2012).** Imaging of hepatocellular carcinoma: diagnosis, staging and treatment monitoring. *Cancer Imaging*; 12(3): 530–547.
 33. **Tiwari HA, Kalb B, Chundru S (2014).** MRI of hepatocellular carcinoma: an update of current practices. *Diagn Interv Radiol*; 20(3): 209–221.
 34. **Zong, J., Fan, Z., & Zhang, Y. (2020).** Serum tumor markers for early diagnosis of primary hepatocellular carcinoma. *Journal of hepatocellular carcinoma*, 413-422.
 35. **Chen, S., Li, J., Tan, X., et al. (2020).** Clinical role of combining alpha-fetoprotein and lens culinaris agglutinin-reactive fraction of alpha-fetoprotein for hepatocellular carcinoma: evidence from literature and an original study. *Journal of Clinical Laboratory Analysis*, 34(7), e23262.
 36. **Lv, T., Jiang, L., Kong, L., et al. (2020).** MicroRNA-29c-3p acts as a tumor suppressor gene and inhibits tumor progression in hepatocellular carcinoma by targeting TRIM31. *Oncology reports*, 43(3), 953-964.
 37. **Ratnasari, N., Lestari, P., Renovaldi, D., et al. (2022).** Potential plasma biomarkers: miRNA-29c, miRNA-21, and miRNA-155 in clinical progression of Hepatocellular Carcinoma patients. *Plos one*, 17(2), e0263298.
 38. **Sparn, C., Dimou, E., Meyer, A., et al. (2022).** Glypican-1 drives unconventional secretion of fibroblast growth factor 2. *Elife*, 11, e75545.
 39. **Li, Y. (2023).** Glypican-3 (GPC-3) for early diagnosis and target therapy. *J Clin Images Med Case Rep*, 4(3), 2321.
 40. **Mauro, M., Ugo, P., Walton, Z., et al. (2023).** Glypican-3 (GPC-3) Structural Analysis and Cargo in Serum Small Extracellular Vesicles of Hepatocellular Carcinoma Patients. *International journal of molecular sciences*, 24(13), 10922.
 41. **Parikh, N. D., Mehta, A. S., Singal, A. G., et al. (2020).** Biomarkers for the early detection of hepatocellular carcinoma. *Cancer Epidemiology, Biomarkers & Prevention*, 29(12), 2495-2503.
 42. **Kokudo N, Hasegawa K, Akahane M (2015).** Evidence-based Clinical Practice Guidelines for Hepatocellular Carcinoma: *Hepatol Res*; 45 (2).