



Coblation Cordotomy in Bilateral Vocal Fold Immobility: Review Article

Mohamed Abdelmohsen Alnemr, Khaled Abdel-Shakour, *Fatma Ali Abdul-Karim, Marwa Abdelraouf Mohammed

Otorhinolaryngology, Head and Neck Surgery Department, Faculty of Medicine, Zagazig University

***Corresponding author:** Fatma Ali Abdul-Karim

Email: benzablahfatma@gmail.com, **Mobile:** +218928190883

Article History: Received: 21.06.2023

Revised:04.07.2023

Accepted: 16.07.2023

Abstract:

Bilateral vocal fold immobility (BVFI) can result in considerable voice and airway impairment. Although the carbon dioxide (CO₂) laser is commonly used in transverse cordotomy, the coblator, a minimally invasive, low-thermal technology, has been increasingly used in otolaryngology.

Keywords: Coblation Cordotomy, Vocal Fold, Immobility.

DOI: 10.53555/ecb/2023.12.1173

Introduction:

The first coblation tonsillectomy was performed in the late 1990s. Since that time, the coblator has been increasingly used in the field of otolaryngology. The coblator uses radiofrequency energy through a saline medium to create a plasma that breaks molecular bonds in the tissue, causing the tissue to dissolve at relatively low temperatures (1).

Coblation has become an increasingly useful tool for otolaryngologists in recent years. In addition to its frequent use for tonsillectomies, coblation has been used for the removal of laryngeal Teflon granulomas, treatment of recurrent respiratory papillomatosis, removal of suprastomal tracheal granulomas, neurofibromas and arteriovenous malformations. In each case, coblation has been demonstrated to be an acceptable alternative to the CO₂ laser. The coblator device tip uses radiofrequency energy through a saline medium to create a plasma. The plasma's energized

particles break molecular bonds in the tissue, causing the tissue to dissolve at relatively low temperatures. This helps to avert considerable lateral heat distribution into the tissue, while also reducing the risk of airway fire (2).

There are many advantages to use the coblator over the CO₂ laser. For instance, no laser protection is required with the coblator, thus helping to reduce operative set-up and procedure time. The coblation hand piece also offers the surgeon the ability to work tangentially, with less need to adjust the microscope as one might for a CO₂ laser mounted on a micromanipulator or pattern generator. The coblation wand also offers bipolar cautery that may be useful if bleeding is encountered. The ability to perform the procedure rapidly and often with the patient apneic is preferring (3).

Pre-Procedure

Prior to surgery, the patient will undergo evaluation by an otolaryngologist and speech pathologist. This includes videostroboscopic examination of the vocal cords in motion to identify abnormalities and tailor the procedure. Imaging or laryngoscopy may also be performed to rule out other causes of dysphonia. The risks and benefits of surgery will be reviewed. Voice rest is recommended for 1-2 weeks pre-procedure to allow any vocal cord inflammation to improve (4).

Procedure

Coblation cordotomy is typically done under general anesthesia. The surgeon will use suspension microlaryngoscopy to visualize the vocal cords. A wand delivering radiofrequency energy is inserted and applied to selectively ablate portions of the vocalis muscle on one or both cords. This weakens hyperfunctional muscle activity (4).

The procedure takes approximately 30-60 minutes. Total ablation time ranges from 2 to 10 minutes per vocal cord. (4).

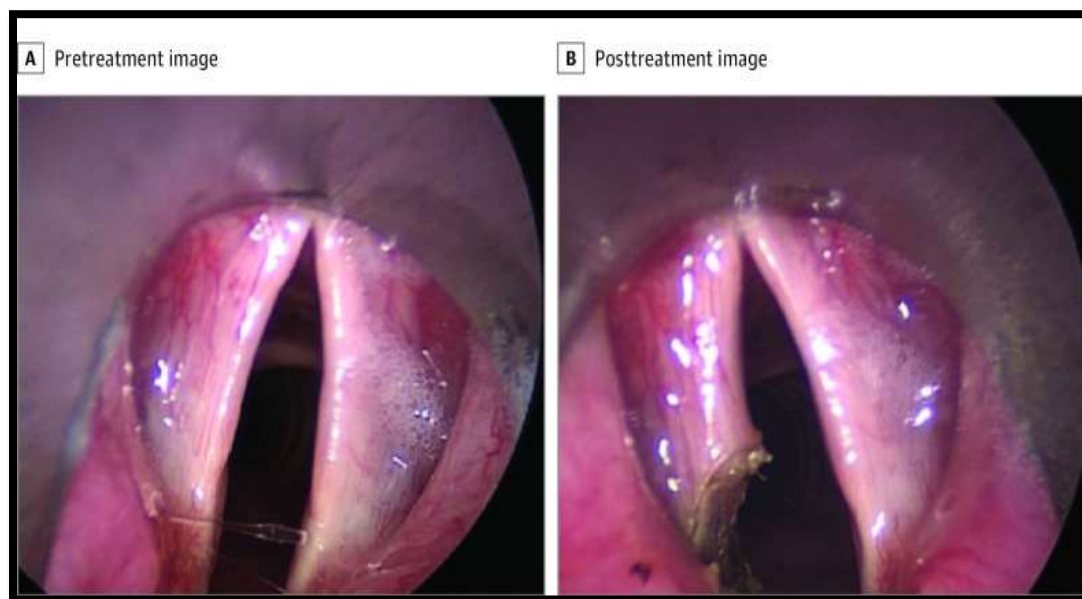


Figure (1): Vocal Folds Before and After Coblation Cordotomy A, Vocal folds before coblation cordotomy. B, Vocal folds after coblation cordotomy (3).

Post-Procedure

There will be voice rest instructions for 1-2 weeks postoperatively along with follow-up appointments to check healing. Swelling and breathiness are expected early on. Voice therapy helps retrain the vocal cords and optimize long-term voice quality. Maximum benefits may take 3-6 months as the healing process continues. While improvement is seen in over 90% of patients, some may require additional procedures to refine outcomes. Overall, coblation cordotomy offers the possibility of significant voice improvement with lower morbidity than traditional surgical options (4).

Outcome

Benninger et al., (3) who investigated outcomes associated with coblation to treat BVFI, concluded that initial outcomes of cordotomy by coblation revealed that this technique was a safe and efficient approach to treating bilateral vocal fold immobility(BVFI). Coblation was associated with significant reduction in operation room (OR) time compared with scheduled time, and patients experienced significant improvement in shortness of breath, stridor, and vocal cord function.

Benninger et al. (4) evaluated the use of unilateral coblator cordotomy for BVFI. They found that this method allowed for decannulation in 21 of 25 patients who had a tracheotomy. In their study, the initial coblator cordotomy was sufficient for the majority of patients, with 22% (20/94) requiring a revision procedure. Interestingly, their study also showed promising voice outcomes with improvements in voice handicap index (VHI) in all but four patients.

Bilateral vocal fold immobility is characterized by restricted mobility of both vocal folds leading to debilitating symptoms like dyspnea and poor voice quality. Endoscopic coblation vocal cordotomy is emerging as a promising management approach for these patients, utilizing radiofrequency energy to ablate a posterior section of the immobilized vocal fold to enlarge the airway. Compared to laser cordotomy, coblation allows more targeted removal of tissue with less thermal damage and superior healing characteristics. An initial study revealing safe and effective outcomes for coblation cordotomy with minimal granulation tissue and good airway. More patients treated with this technique demonstrated increased glottic airflow and rapid recovery of the vocal fold tissue. Long-term data can confirm these preliminary findings, but endoscopic coblation cordotomy provides a refined option for bilateral vocal fold immobility, with reduced tissue effects and swift restoration compared to previous surgical modalities (**5, 6**).

References:

1. Awad, R., Shamil, E., Aymat-Torrente, A., et al. (2019). Management of laryngeal papillomatosis using coblation: Another option of surgical intervention. *European Archives of Oto-Rhino-Laryngology*, 276, 793-800.
2. Khoueir N, Rassi J, Richa T, et al. (2021). Coblation intra-capsular tonsillectomy: A prospective tertiary center trial. *Int J Pediatr Otorhinolaryngol*. Nov; 150:110890.
3. Benninger MS, Xiao R, Osborne K, et al. (2018). Outcomes Following Cordotomy by Coblation for Bilateral Vocal Fold Immobility. *JAMA Otolaryngol Head Neck Surg*. Feb 1;144(2):149-155.
4. Benninger MS, Syamal M, Gau VL, et al. (2022). Coblation Cordotomy for the Management of Bilateral Vocal Fold Immobility. *J Voice*. 2022 Oct 18:S0892-1997(22)00274-0.
5. Osborne, K.M., Bryson, P.C. and Benninger, M.S. (2012). Cordotomy by Coblation in Bilateral Vocal Fold Immobility. *Otolaryngology–Head and Neck Surgery*, 147: P190-P190.

6. Shaikh Mohideen, A. (2020). Comparative study on Surgical Outcome for Benign Vocal Cord Lesions by Conventional Method Versus Coblation (Doctoral dissertation, Kilpauk Medical College, Chennai).