



PREVALENCE OF TOBACCO ASSOCIATED ORAL MUCOSAL LESIONS IN A PRIVATE HOSPITAL - A RETROSPECTIVE STUDY

Dr. V. Divyadharsini¹, Dr. T.N. Uma Maheswari^{2*}

Article History: Received: 12.12.2022

Revised: 29.01.2023

Accepted: 15.03.2023

Abstract

Background: Oral mucosal lesions usually present as abnormal alterations in colour, structure, surface texture, consistency, loss of integrity or as a growth in the oral mucosa. Oral potentially malignant disorders are of particular importance as they may progress into malignancy. The present study was conducted to assess the prevalence and distribution of oral mucosal lesions associated with tobacco habit in a private hospital and effect of tobacco usage on the mucosal changes.

Materials & Methods: All the patients with oral mucosal lesions seen between 2019 and 2021 were studied retrospectively. Demographic data, clinical data and tobacco habits were retrieved. IBM SPSS version 20 was used to perform the statistical analysis, and the mean, frequency, and percentage were calculated.

Results: Among 71807 outpatients who reported to the dental college, 28863 (40.19%) patients were diagnosed with oral mucosal lesions. Out of all the oral mucosal lesions, tobacco associated lesions were 28.81% (8314) and were most common in males. The most common tobacco related oral lesions in males were leukoplakia (37.29%) followed by oral submucous fibrosis (30.08%). The most common tobacco associated lesions in females were oral submucous fibrosis (3.01%).

Conclusion: We conclude that the dental practitioner should have adequate awareness and knowledge about the diagnosis and management of oral lesions. 37.85% of oral mucosal lesions were potentially malignant disorders and use of tobacco products increased the risk for oral mucosal changes.

Keywords: Chennai, Leukoplakia, Oral Cancer, OPMD, Oral Submucous Fibrosis, Precancerous lesion, Tobacco.

¹PG Student, Department Of Oral Medicine And Radiology, Saveetha Dental College And Hospitals Simats, Chennai, Tamil Nadu, India.

^{2*}Professor and Head of the Admin Department Of Oral Medicine And Radiology, Saveetha Dental College And Hospitals, Simats, Chennai, Tamil Nadu, India.

DOI: 10.31838/ecb/2023.12.s2.158

1. Introduction

Oral health plays a significant role in improving the general health and standard of living. The buccal mucosa, the palatal mucosa, alveolar mucosa, soft tissue lining the oral cavity and the gingivae forms the oral mucosa.¹ The distinct layers of oral mucosa protect it from microbial infection, modulates temperature and water equilibrium, just like the skin. The oral mucosa offers first line protection against trauma, potential pathogens, and carcinogenic agents.² The changes in the oral mucosa can be categorized by clinical presentation into normal variations and oral mucosal lesions.³ Oral potentially malignant disorders (OPMD) have significant concern as they may progress into malignancy.

Tobacco in smoke/smokeless form was one among the major risk factors for the incidence of OPMD and cancer.⁴ Over the last few years, various commercial chewable tobacco products such as pan masala and gutkha have become popular in India and in many parts of Asia. The increasing incidence of OPMD in India is due to the WHO data that says, India is the second largest consumer of tobacco products and third largest manufacturer of tobacco products.⁵ Areca nut and tobacco are present in most of the products and both of which have been associated with the occurrence of oral cancer. The investigators have also observed that smoking and chewing of tobacco and betel quid act synergistically in oral carcinogenesis and that persons with mixed habits form a substantially high-risk population.⁶

Bidi is the most popular form of tobacco product in India.⁷ Reverse smoking is a type of smoking where tobacco is smoked with the lighted end inside the mouth. Air is supplied to the burning zone through the unlighted end of the cigarette and smoke is expelled through the cigarette or through the mouth. The various forms of smoking tobacco products seen in India are Bidi, Chillum, Chutta, Cigarettes, Dhumti, Hookah and Hookli. The most common smokeless tobacco product used in India is Gutka and it has now been banned all over India.⁸ It is alkaline in nature and causes chronic alteration to the oral mucosa in habitual paan chewers because of the pH alteration, due to slaked lime usage many times a day.⁹ The buccal mucosa loses its smoothness and the rough areas retain the quid for some time which gradually shows discolouration. The various forms of smokeless tobacco used in India are Khaini, Mainpuri tobacco, Mawa, Mishri/Masheri, Paan, Snuff, Zarda, Gutka, Pan masala and Gudakhu.

Oral Potentially Malignant Disorders refers to all epithelial lesions or conditions with an increased risk for malignant transformation.¹⁰ Oral Potentially Malignant Disorders include oral leukoplakia, erythroplakia, erythroleukoplakia, oral

submucous fibrosis, palatal lesions in reverse smokers, erosive lichen planus, oral lichenoid reactions, graft-versus-host disease, oral lupus erythematosus, actinic cheilitis of the lower lip and hereditary conditions, such as dyskeratosis congenita and epidermolysis bullosa. Most of the oral potentially malignant disorders are asymptomatic in the early stages and are usually detected by practitioners on routine oral examination. It is noteworthy that many oral squamous cell carcinomas develop from potentially malignant disorders.¹¹ Correct diagnosis and timely treatment of Oral Potentially Malignant Disorders may help prevent malignant transformation in oral lesions.¹²

The prevalence, incidence, and severity of oral mucosal lesions in a particular population could be evaluated through epidemiologic studies,¹³ but the results of such studies have hardly ever been published globally. Important information from these prevalence studies will be useful in formulating plans for the administration of health services.¹⁴ They help us to learn about the pattern of local disease occurrence and subsequently contribute toward the understanding of the natural history of a disease.¹⁵

The cardinal feature of conducting a prevalence study of oral mucosal lesion in a population is to understand its extension and characteristics. These studies may make a pavement for formulating prevention programmes that improve oral health promotion. Nevertheless, epidemiological data of the changing trends of these oral mucosal lesions are lacking. Our team has extensive knowledge and research experience that has translate into high quality publications¹⁶⁻²⁵. We present the following article in accordance with the STROBE reporting checklist.

Hence, the present study was carried out to assess the prevalence of different types of OMLs in a general population in patients visiting private hospitals in Chennai, Tamil Nadu, India.

2. Materials and Methods

A retrospective analysis of dental health and clinical examination records of 71807 patients visiting a private hospital for multidisciplinary dental procedures between 2019 and 2021 was conducted. Ethical clearance was obtained from the Saveetha Institute of Medical and Technical Science (SIMATS) Scientific Review Board. Undergraduate student performs the general and clinical examination and fills the findings in an electronic database and then it is evaluated and cross checked by a faculty from the Department of Oral Medicine. All the patients were examined on a dental chair with a mouth mirror, probe and gauze under good artificial illumination.

Patient's demographic data, chief complaint, past medical history, past dental history, medications taken, habit history, extraoral and intraoral clinical examination are noted in the patient's file. Habits such as smoking, pan chewing and alcohol intake, and frequency, duration, site of placement in oral cavity, duration of contact with mucosa and discontinuation of habits were also noted. Oral mucosal lesions were categorized according to the WHO criteria. The cases which lacked written information dental examination records or if it was not assessed by a faculty, then those data were excluded from the study.

General built, age, gender, systemic illness, drug history, and habit history are the components to be evaluated in each record. Clinical examinations for all the patients were carried out according to the WHO guideline. Extraoral examination including facial symmetry, developmental abnormalities, temporomandibular joint, and lymph nodes were recorded. In intraoral examination the size of the mouth, shape, mouth opening, anatomical variation on the oral mucosa, presence of any lesions and features of the lesion, location, extension,

size, colour, consistency, etiological or related factors, and dental status were noted. The patients were classified into groups based on the forms of tobacco used smoke, smokeless or mixed categories. The patients were educated about the harmful effect of tobacco and encouraged to cease the habit.

The collected data were tabulated and frequency & distribution statistical analysis was done using IBM SPSS version 20. The chi-square test and Fisher's exact test were applied to find the significance of study parameters. P value less than 0.05 was considered statistically significant.

3. Results

Among 71807 outpatients who reported to the dental college, 28863 (40.19%) patients were diagnosed with oral mucosal lesions. Out of all the oral mucosal lesions, tobacco associated lesions were 28.81% (Figure 1). Study participants were of the age group between 17 and 90 years with an average age of 42 years.

Figure 1: Prevalence of Oral mucosal lesions with and without tobacco association

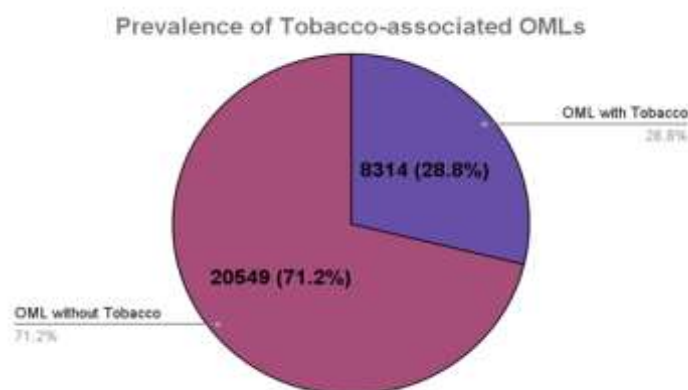


Figure 1 shows prevalence of oral mucosal lesions among patients with tobacco association or without tobacco association

Of the 28863 patients, 10972 (38.01%) consumed tobacco in one or another form of tobacco and 8314

patients (28.80%) of these clinically presented with oral mucosal lesions. Out of 10972 tobacco users, 10114 (92.18%) belonged to male population and 858 (7.8%) belonged to the female population (Figure 2).

Figure 2: Distribution of Tobacco users among males and females

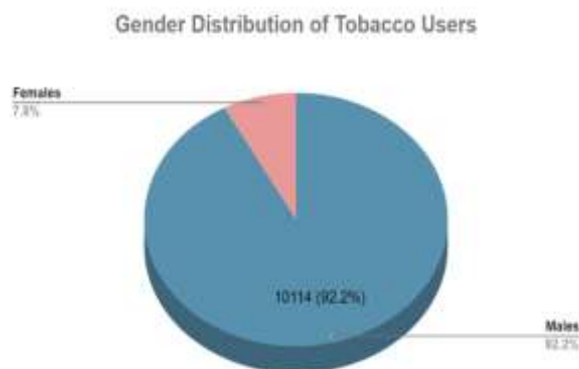


Figure 2 shows distribution of tobacco habits among males and females

The most prevalent form of tobacco used was smoking 4588 (41.81%), followed by chewing 3615 (32.94%) and mixed tobacco consumption

2769 (25.23%) shown in Figure 3. Most of the females were chewers (65.76%). The most common tobacco habit practiced among males was smoking followed by chewing.

Figure 3: Prevalence of Tobacco Habits

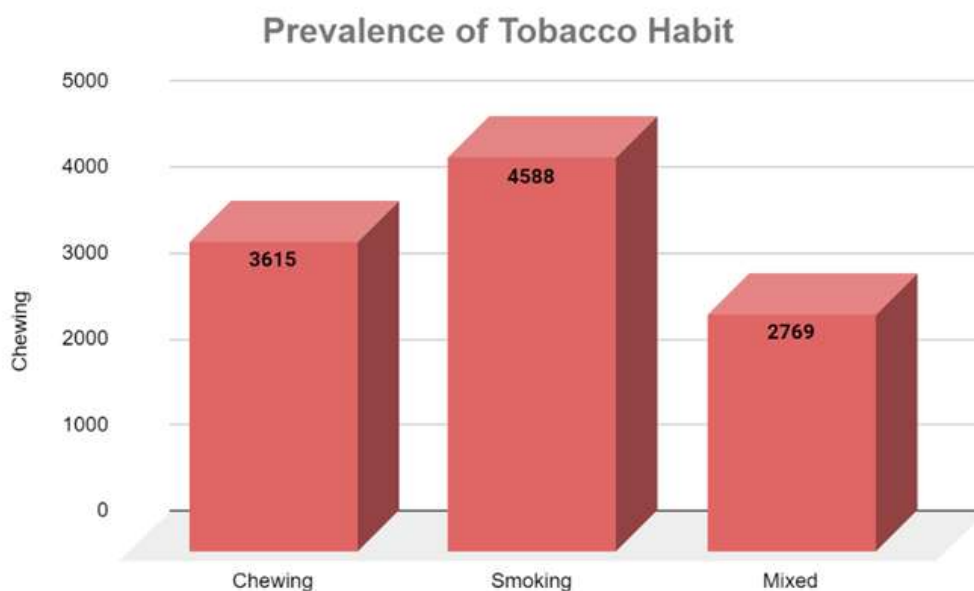


Figure 3 shows prevalence of chewing, smoking and mixed tobacco habits among study participants

The prevalence and severity of oral mucosal lesions were directly proportional to the time span and frequency of tobacco use, although there were few contradictions. The most common tobacco associated lesions were leukoplakia (39.28%), oral submucous fibrosis (33.10%), tobacco pouch

keratosis (25.87%) and smokers palate (2.46%). (Figure 4)

The most common tobacco associated lesions in males were leukoplakia (37.29%), oral submucous fibrosis (30.08%), tobacco pouch keratosis (25.07%) and smokers' palate (2.46%). The most common tobacco associated lesions in females were oral submucous fibrosis (3.01%), leukoplakia (1.98%) and tobacco pouch keratosis (0.79%).

Figure 4: Prevalence of Tobacco Habits

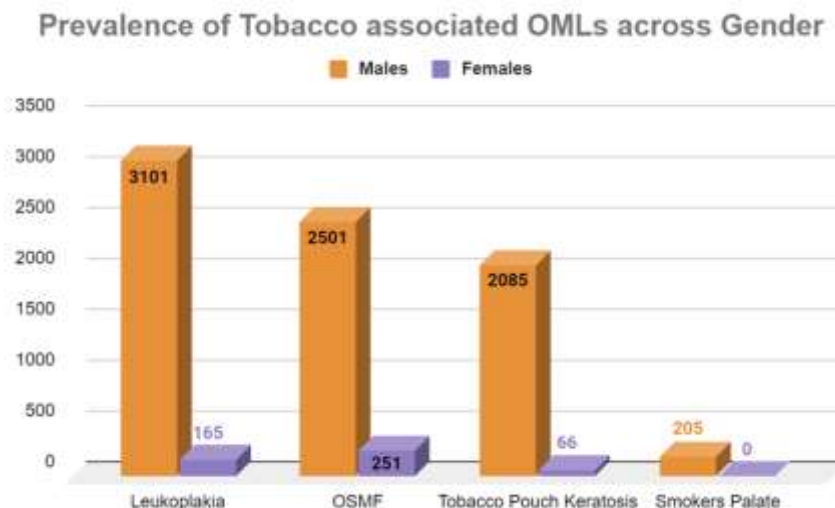


Figure 4 shows prevalence Leukoplakia, OSMF, Tobacco pouch keratosis and smokers palate among males and females

4. Discussion

Consumption of various forms of tobacco is emerging as a significant, and growing threat to health. Tobacco products consist of 7000 different chemicals and among these more than 60 are considered carcinogenic.²⁶ Bulk of tobacco products are frequently utilized in the form of cigarettes or bidis.²⁷ Among the smokeless form, commercially available pan masala are becoming more common, especially among teenagers and young adults than in the older age group. A definite association has been recorded between tobacco habit and oral potentially malignant disorders and oral cancer.

Prolonged exposure of oral mucosa to tobacco products can induce changes which could be a protective mechanism of the oral cavity or attributed to the carcinogen itself.^{28,29} Carcinoma related to tobacco usage accounts for nearly half of all malignancies in men and quarter of all cancers in women.³⁰ Analysing the data collected from our study, out of the 10972 patients with history of tobacco habit, 10114 (92.18%) were males and 858 (7.8%) were females. These variations between the distribution of oral mucosal lesions could be attributed to the higher tobacco used by male population and the easier access to tobacco products. On the contrary, due to social norms and cultural restrictions females tend to keep up a certain persona and as a consequence they are less likely to follow these deleterious habits.³¹

Smokeless tobacco products are used in forms of sucked as a quid, applied to gums, chewed or sniffed. Habitually placing tobacco in the mucobuccal fold in the mandibular anterior or posterior regions where the mucosa is in direct contact with snuff or chewing tobacco leads to Tobacco Pouch Keratosis.³² The prevalence of

tobacco pouch keratosis was 25.87% with the highest prevalence rate in males (96.93%).

Smoker's melanosis or smoker's palate or nicotine stomatitis is caused due to the effects of nicotine on melanocytes to produce excess melanosomes, which results in basilar melanosis. It is usually seen in smokers characterized by whitish mucosa with a red central dot to high temperature rather than the chemical composition of the smoke.³³

Oral submucous fibrosis is "an insidious, chronic disease affecting any part of the oral cavity and sometimes the pharynx. Although occasionally preceded by and/or associated with vesicle formation, it is always associated with juxta-epithelial inflammatory reaction followed by fibro-elastic change of the lamina propria, with epithelial atrophy leading to stiffness of the oral mucosa and causing trismus and inability to eat."³⁴ The prevalence rate of OSMF in our study was 33.10% and most commonly found in males. The malignant transformation rate of OSMF was 5.1%.

Leukoplakia are potentially malignant disorders which are associated with both forms (smoking and smokeless) of tobacco, with malignant transformation rate of 9.5%.³⁵ In our study, the prevalence of leukoplakia (39.28%) was found most commonly found associated with smokers. In our study, the results showed that tobacco in the smoking form followed by chewing and mixed form were most common.³⁶ Sujatha et al demonstrated the association of higher level of chowers mucosa and tobacco pouch keratosis among the tobacco chowers group.³⁷ Jha et al. study reported the prevalence rate of leukoplakia as 13.1% and tobacco-induced keratosis as 9.7% in smokeless tobacco users.³⁸

Patients with both smoke & smokeless tobacco habit exhibited high prevalence of leukoplakia and

tobacco associated oral mucosal lesions were higher in males when compared to females which was in accordance with studies by Patil *et al.*³⁹ And males more commonly used smokeless tobacco when compared to females which was in accordance with Sinha *et al.* study which showed the same prevalence rate in India, Myanmar, Nepal, and Sri Lanka. However, in Bangladesh, Indonesia, and Thailand, Smokeless tobacco use was higher among females as compared to males.⁴⁰ All these study results were in accordance with this study with little variation in occurrence of lesions. These discrepancies could be due to the ethnic and cultural variations and the accessibility of tobacco products in the particular regions.⁴¹

In older individuals the prevalence of oral mucosal lesions were higher when compared to younger individuals, and it can be related to different habits acquired with age.⁴² Chewing tobacco, smoking, and consumption of alcoholic beverages have become a common social habit in India.^{43,44}

The distribution pattern of oral mucosal lesions differed from one study to another as seen from our results. This may be due to the fact that with increasing age many alterations of the oral mucosa can be induced. Also, the type of participants included in the study can affect the distribution pattern of oral mucosal lesions. In order to compare prevalence rate across populations, they must have certain similarities like habits, form of tobacco used, mean age, and belong to the same age group. The limitations of this study are that it was of a retrospective nature where information and classification biases might exist and results cannot be generalized to the general population.

5. Conclusion

Cardinal information about the prevalence and distribution of oral mucosal lesions among patients seeking dental care in private hospitals has been provided in the results of this study. Based on the results from our study, we conclude that the greater prevalence of oral mucosal lesions calls for ample awareness and knowledge about the diagnosis and management of these lesions. The prevalence of oral mucosal lesions was relatively higher in older individuals when compared to younger age groups. With increase in age, habits such as smoking, chewing tobacco and alcohol consumption increases, which can also be the reason for this trend observed in our study. 37.85% of oral mucosal lesions were potentially malignant disorders and use of tobacco products increased the risk for oral mucosal changes. This emphasises the importance of routine examination of oral mucosa and the patients must be motivated to quit this deleterious habit. All the dental practitioners should be updated periodically on oral lesions which will enhance their diagnostic ability. It is important to

create awareness among the general population on deleterious effects of tobacco use and to encourage them to quit the habit for the benefit of improving their oral and general health.

Acknowledgement

Nil

Financial Support and Sponsorship

Study funded by Saveetha Dental College and Hospitals, Saveetha Institute of Medical and Technical Sciences (SIMATS), Saveetha University and Rukmani chemicals, Chennai, Tamil Nadu.

There are no con

Conflict of Interest

flicts of interest.

6. Bibliography

- Squier C, Brogden K. *Human Oral Mucosa: Development, Structure and Function*. John Wiley & Sons, 2010.
- Piemonte ED, Lazos JP, Brunotto M. Relationship between chronic trauma of the oral mucosa, oral potentially malignant disorders and oral cancer. *Journal of Oral Pathology & Medicine* 2010; no–no.
- Jin X, Zeng X, Wu L. Oral Mucosal Lesions of Systemic Diseases. *Case Based Oral Mucosal Diseases* 2018; 169–197.
- Aishwarya KM, Reddy MP, Kulkarni S, et al. Effect of Frequency and Duration of Tobacco Use on Oral Mucosal Lesions – A Cross-Sectional Study among Tobacco Users in Hyderabad, India. *Asian Pac J Cancer Prev* 2017; 18: 2233–2238.
- Maheswari TNU, Venugopal A, Sureshababu NM, et al. Salivary micro RNA as a potential biomarker in oral potentially malignant disorders: A systematic review. *Ci Ji Yi Xue Za Zhi* 2018; 30: 55–60.
- IARC Working Group on the Evaluation of Carcinogenic Risks to Humans. Conference. *A Review of Human Carcinogens*. 2012.
- Bhawna G. Burden of smoked and smokeless tobacco consumption in India - results from the Global adult Tobacco Survey India (GATS-India)- 2009-201. *Asian Pac J Cancer Prev* 2013; 14: 3323–3329.
- Muthukrishnan A, Warnakulasuriya S. Oral health consequences of smokeless tobacco use. *Indian J Med Res* 2018; 148: 35–40.
- IARC Working Group on the Evaluation of Carcinogenic Risks to Humans, International Agency for Research on Cancer. *Betel-quad and Areca-nut Chewing and Some Areca-nut-derived Nitrosamines*. IARC, 2004.
- Warnakulasuriya S. Oral potentially malignant

- disorders: A comprehensive review on clinical aspects and management. *Oral Oncol* 2020; 102: 104550.
- León JE, Almeida LY, Duarte A, et al. Cytotoxic and Regulatory T-Lymphocytes in Potentially Malignant Oral and Lip Disorders and Squamous Cell Carcinomas. *Oral Surgery, Oral Medicine, Oral Pathology and Oral Radiology* 2018; 126: e168.
- Brennan PA, Aldridge T, Dwivedi RC. *Premalignant Conditions of the Oral Cavity*. Springer, 2019.
- Rohini S, Jayanth Kumar V. Incidence of dental caries and pericoronitis associated with impacted mandibular third molar-A radiographic study. *Research Journal of Pharmacy and Technology* 2017; 10: 1081.
- Muthukrishnan A, Kumar LB, Ramalingam G. Medication-related osteonecrosis of the jaw: a dentist's nightmare. *BMJ Case Reports* 2016; bcr2016214626.
- Subha M, Arvind M. Role of Magnetic Resonance Imaging in Evaluation of Trigeminal Neuralgia with its Anatomical Correlation. *Biomedical and Pharmacology Journal* 2019; 12: 289–296.
- Ramesh A, Varghese S, Jayakumar ND, et al. Comparative estimation of sulfiredoxin levels between chronic periodontitis and healthy patients - A case-control study. *J Periodontol* 2018; 89: 1241–1248.
- Vijayashree Priyadharsini J. In silico validation of the non-antibiotic drugs acetaminophen and ibuprofen as antibacterial agents against red complex pathogens. *J Periodontol* 2019; 90: 1441–1448.
- Priyadharsini JV, Vijayashree Priyadharsini J, Smiline Girija AS, et al. In silico analysis of virulence genes in an emerging dental pathogen *A. baumannii* and related species. *Archives of Oral Biology* 2018; 94: 93–98.
- Teja KV, Ramesh S, Priya V. Regulation of matrix metalloproteinase-3 gene expression in inflammation: A molecular study. *J Conserv Dent* 2018; 21: 592–596.
- Manohar MP, Sharma S. A survey of the knowledge, attitude, and awareness about the principal choice of intracanal medicaments among the general dental practitioners and nonendodontic specialists. *Indian J Dent Res* 2018; 29: 716–720.
- Nandakumar M, Nasim I. Comparative evaluation of grape seed and cranberry extracts in preventing enamel erosion: An optical emission spectrometric analysis. *J Conserv Dent* 2018; 21: 516–520.
- Varghese SS, Ramesh A, Veeraiyan DN. Blended Module-Based Teaching in Biostatistics and Research Methodology: A Retrospective Study with Postgraduate Dental Students. *J Dent Educ* 2019; 83: 445–450.
- Panchal V, Jeevanandan G, Subramanian E. Comparison of instrumentation time and obturation quality between hand K-file, H-files, and rotary Kedo-S in root canal treatment of primary teeth: A randomized controlled trial. *J Indian Soc Pedod Prev Dent* 2019; 37: 75–79.
- Nair M, Jeevanandan G, Vignesh R. Comparative evaluation of post-operative pain after pulpectomy with k-files, kedo-s files and mtwo files in deciduous molars-a randomized clinical trial. *Braz Dent J*, <https://bds.ict.unesp.br/index.php/cob/article/view/1617> (2018).
- Felicita AS. Orthodontic extrusion of Ellis Class VIII fracture of maxillary lateral incisor - The sling shot method. *Saudi Dent J* 2018; 30: 265–269.
- Docheva M, Stoilova A, Kochev Y, et al. Determination of Polyphenols in Tobacco, Tobacco Blends, Tobacco Smoke and Butts of Different Cigarette Brands. Epub ahead of print 2018. DOI: 10.7546/crabs.2018.06.05.
- Aruna DS, Prasad KVV, Shavi GR, et al. Retrospective study on risk habits among oral cancer patients in Karnataka Cancer Therapy and Research Institute, Hubli, India. *Asian Pac J Cancer Prev* 2011; 12: 1561–1566.
- Sridharan G. Epidemiology, control and prevention of tobacco induced oral mucosal lesions in India. *Indian J Cancer* 2014; 51: 80–85.
- Venugopal A, Uma Maheswari TN. Expression of matrix metalloproteinase-9 in oral potentially malignant disorders: A systematic review. *J Oral Maxillofac Pathol* 2016; 20: 474–479.
- Misra SR, Shankar YU, Rastogi V, et al. Metastatic hepatocellular carcinoma in the maxilla and mandible, an extremely rare presentation. *Contemp Clin Dent* 2015; 6: S117–21.
- Srivastava R, Jyoti B, Pradhan D, et al. Prevalence of oral submucous fibrosis in patients visiting dental OPD of a dental college in Kanpur: A demographic study. *J Family Med Prim Care* 2019; 8: 2612–2617.
- Sellappa S, Balakrishnan M, Raman S, et al. Induction of micronuclei in buccal mucosa on chewing a mixture of betel leaf, areca nut and tobacco. *J Oral Sci* 2009; 51: 289–292.
- Reddy SS, Prashanth R, Yashodha Devi BK, et al. Prevalence of oral mucosal lesions among chewing tobacco users: A cross-sectional study. *Indian J Dent Res* 2015; 26: 537–541.
- Chaitanya NC, Muthukrishnan A, Krishnaprasad CMS, et al. An Insight and Update on the Analgesic Properties of Vitamin C. *J Pharm Bioallied Sci* 2018; 10: 119–125.

- Favia G, Capodiferro S, Limongelli L, et al. Malignant transformation of oral proliferative verrucous leukoplakia: a series of 48 patients with suggestions for management. *Int J Oral Maxillofac Surg* 2021; 50: 14–20.
- Chaitanya NC, Muthukrishnan A, Babu DBG, et al. Role of Vitamin E and Vitamin A in Oral Mucositis Induced by Cancer Chemo/Radiotherapy- A Meta-analysis. *J Clin Diagn Res* 2017; 11: ZE06–ZE09.
- Sujatha D, Hebbar PB, Pai A. Prevalence and correlation of oral lesions among tobacco smokers, tobacco chewers, areca nut and alcohol users. *Asian Pac J Cancer Prev* 2012; 13: 1633–1637.
- Jha PK, Iqbal MA, Khan M, et al. Prevalence of Oral Mucosal Lesions among Tobacco Chewers in North Indian Population. *Annals of International medical and Dental Research*; 4. Epub ahead of print 2018. DOI: 10.21276/aimdr.2018.4.4.de4.
- Patil S, Yadav N, Patil P, et al. Prevalence and the relationship of oral mucosal lesions in tobacco users and denture wearers in the North Indian population. *J Family Community Med* 2013; 20: 187–191.
- Muwonge R, Ramadas K, Sankila R, et al. Role of tobacco smoking, chewing and alcohol drinking in the risk of oral cancer in Trivandrum, India: A nested case-control design using incident cancer cases. *Oral Oncology* 2008; 44: 446–454.
- Muthukrishnan A, Bijai Kumar L. Actinic cheilosis: early intervention prevents malignant transformation. *BMJ Case Rep*; 2017. Epub ahead of print 20 March 2017. DOI: 10.1136/bcr-2016-218654.
- Dharman S, Muthukrishnan A. Oral mucous membrane pemphigoid - Two case reports with varied clinical presentation. *J Indian Soc Periodontol* 2016; 20: 630–634.
- Aslesh OP, Paul S, Paul L, et al. High Prevalence of Tobacco Use and Associated Oral Mucosal Lesion Among Interstate Male Migrant Workers in Urban Kerala, India. *Iran J Cancer Prev* 2015; 8: e3876.
- Subashri A, Uma Maheshwari TN. Knowledge and attitude of oral hygiene practice among dental students. *Research Journal of Pharmacy and Technology* 2016; 9: 1840.
- Docheva M, Stoilova A, Kochev Y, Kirkova D. Determination of Polyphenols in Tobacco, Tobacco Blends, Tobacco Smoke and Butts of Different Cigarette Brands [Internet]. 2018; Available from: <http://dx.doi.org/10.7546/crabs.2018.06.05>
- Palanivelu, J., Thanigaivel, S., Vickram, S., Dey, N., Mihaylova, D., & Desseva, I. (2022). Probiotics in functional foods: survival assessment and approaches for improved viability. *Applied Sciences*, 12(1), 455.
- Subashri A, Uma Maheshwari TN. Knowledge and attitude of oral hygiene practice among dental students [Internet]. *Research Journal of Pharmacy and Technology* 2016;9(11):1840. Available from: <http://dx.doi.org/10.5958/0974-360x.2016.00375.9>