



Complications of submucosal resection (SMR) surgery and septoplasty in symptomatic deviated nasal septum- A Comparative analysis

Dr Girish Tapadiya¹, Dr Archana Tapadiya², Aakanksha Tapadiya³

1. M S (ENT) ,Aakanksha Heart & ENT clinic ,Shrikrishnapeth, Amravati
2. D.M (Cardiology) Aakanksha Heart & ENT clinic ,Shrikrishnapeth,Amravati
3. Final MBBS ,DrVithalraoVikhePatil Foundation Medical College, Ahmednagar

Abstract:

Background: Symptomatic deviated nasal septum is a condition characterized by the most prevalent symptom of nasal blockage, which can occur unilaterally or bilaterally. Nasal obstruction is the primary challenge frequently encountered by individuals with a DNS. SMR and septoplasty are the most common techniques widely used.

Aim: To study and compare the complications of SMR and septoplasty procedure in patients with symptomatic deviated nasal septum.

Materials and Methodology: A quasi experimental study was conducted at Baheti Multispecialty hospital for period of two years. A total of 100 patients were enrolled in the study. 50 patients underwent SMR and 50 received the septoplasty. Septoplasty and SMR were then performed using standard surgical techniques

Results: Among the patients who underwent submucous resection (SMR), the occurrence rates of septal hematoma, septal perforation, synechiae, columellar retraction, and supratip deformity were 4%, 10%, 6%, 2%, and 2% respectively. In contrast, among those who underwent septoplasty, no cases of septal hematoma were reported, while septal perforation accounted for 8%. Synechiae were observed in 12% of the cases, whereas columellar retraction and supratip deformity were not observed in any of the cases. The statistical significance was observed between the comparison of symptoms in SMR and septoplasty between pre-operative and post-operative surgery.

Conclusion: The study demonstrated that both SMR and septoplasty have demonstrated efficacy in improving symptoms associated with deviated nasal septum. Deviated nasal septum has a

notable association with sinusitis. This study emphasizes the importance of recognizing the prevalence of deviated nasal septum and its accompanying symptoms when conducting clinical and radiological evaluations of patients.

Keywords: Septoplasty, Submucosal resection, Deviated nasal septum, Symptomatic

INTRODUCTION:

Deviated nasal septum (DNS) is the primary cause of nasal obstruction, resulting in mouth breathing, snoring, and external nasal deformity. Additionally, it disrupts the airflow dynamics within the nasal cavity and hampers proper aeration of the paranasal sinuses, often leading to sinusitis. The altered airflow patterns also trigger compensatory hypertrophy of the nasal mucosa on the concave side [1–4].

DNS is a frequently encountered medical condition. While various theories have been proposed to explain its origins, the most widely accepted explanation is that direct trauma to the nose, birth injury, or congenital factors contribute to its development [5]. In India, the prevalence of deviated nasal septum (DNS) ranges from 18% to 31% within the general population [6].

Epidemiological research indicates that nasal obstruction is the predominant symptom experienced by individuals with DNS, followed by anosmia (loss of sense of smell). The nasal septum, a mid-line structure, serves to divide the nasal cavity and is composed of both cartilage and bony components [7,8]. It has a dual role: providing support to the nose's aesthetic appearance and facilitating proper physiological functions, including controlling laminar nasal airflow for comfortable respiration. [5]

Moreover, the nasal turbinates plays a role in warming and humidifying the inspired air to facilitate the exchange of gases [9]. Deviations of the nasal septum occur when its cartilaginous or bony components are anatomically misaligned [7,10]. Changes such as impaired mucociliary function, lymphocytic infiltration, and squamous metaplasia are observed due to these airflow alterations. Although these changes affect both sides of the nasal mucosa, they tend to be more severe on the concave side. Surgical correction of DNS can prevent or alleviate these changes [11].

Surgical correction of septal deviation is typically necessary and is performed with the goal of enhancing the individual's quality of life. Two common surgical procedures used to correct nasal deviation are septoplasty and submucosal resection (SMR). Septoplasty and SMR of the septum aim to address the issue by removing or straightening the affected cartilage and bone within the nasal septum. These surgeries are intended to improve nasal airflow and alleviate symptoms associated with deviated septum [12]. Nasal septal deviation plays a crucial role in the development of chronic sinusitis. It can occur congenitally as an anatomical abnormality or as a result of nasal trauma. This condition is prevalent in approximately sixty-two percent of individuals with chronic sinusitis[13]. The factors contributing to chronic sinusitis include various medications, asthma, allergies, nasal polyps, as well as other associated problems such as prior surgery, trauma, and congenital anatomic abnormalities like nasal septal deviation [14]. Thus, the objective of the study was to compare the complications of septoplasty and SMR surgery in patients with symptomatic deviated nasal septum.

MATERIALS AND METHODOLOGY:

The present study was conducted at Baheti Multispecialty Hospital, Department of PDMMC, over a period of two years from 2012 to 2014. A quasi-experimental design was employed, as random assignment of participants was not feasible due to ethical and practical considerations. The study included a total of 100 patients diagnosed with symptomatic deviated nasal septum. Among them, 50 patients underwent SMR, while the remaining 50 patients underwent septoplasty.

Inclusion criteria:

- Patients presenting with significant symptoms related to deviated nasal septum, such as nasal obstruction, difficulty breathing, snoring and related nasal discomfort.
- Patients who provided informed consent to participate in the study.

Exclusion criteria:

- Patients with nasal bone and outer nasal deviation were also excluded from the study.

Methodology:

The study involved a total of 100 patients diagnosed with symptomatic deviated nasal septum. Among them, 50 patients received SMR, while the remaining 50 patients underwent septoplasty. Before the surgery, participants underwent complete blood count, clinical examination, and nasal X-ray. Diagnostic nasal endoscopy was performed to assess the severity of septal deviation, obstruction site, and other nasal pathologies. Septoplasty and SMR were then performed using standard surgical techniques. Postoperative follow-up visits were conducted to document complications and patient-reported outcomes.

Statistical analysis: The collected information was analyzed by SPSS 20.0. Frequency and percentage was calculated for qualitative variables. The frequency of pre and post operative symptoms was compared using Chi square test and p value <0.01 was deemed statistically significant.

RESULTS:

Table-1: Distribution of gender between the groups.

Gender	SMR		Septoplasty	
	No. of cases	Percentage	No. of cases	Percentage
Female	21	42.00%	34	68.00%
Male	29	58.00%	16	32.00%
Total	50	100.00%	50	100.00%

Of the 50 total cases for SMR, 42.00% (21 cases) were females, while 58.00% (29 cases) were males. When it comes to septoplasty, 68.00% (34 cases) were females, and 32.00% (16 cases) were males, out of the total of 50 cases. (Table-1)

Table-2: Comparison of complications between SMR and septoplasty N=100.

Complications	SMR N=50 (%)	Septoplasty N=50(%)
Septal hematoma	2 (4%)	0 (0)

Septal perforation	5 (10%)	4 (8)
Synechia	3 (6)	6 (12)
Columellar retraction	1 (2)	0 (0)
Supratip Deformity	1 (2)	0 (0)

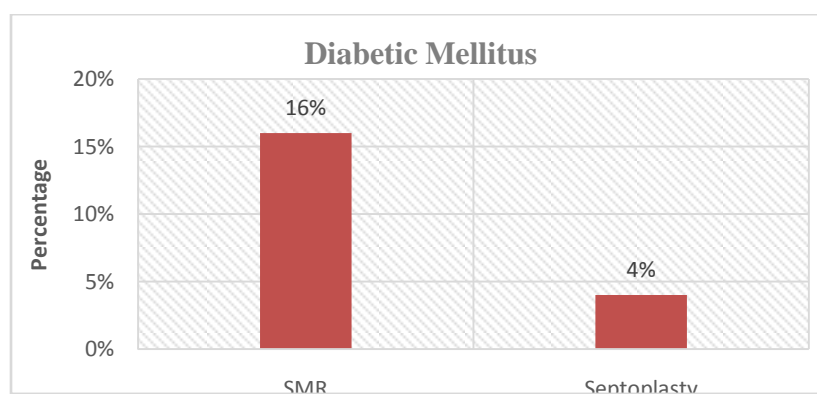
Regarding SMR:

Out of the total 50 cases, septal hematoma occurred in 2 cases, accounting for 4% of the cases. Septal perforation was observed in 5 cases, representing 10% of the total. Synechia (adhesions) were observed in 3 cases, accounting for 6% of the total. Columellar retraction occurred in 1 case, representing 2% of the cases. Supratip deformity was reported in 1 case, also representing 2% of the cases.

For septoplasty:

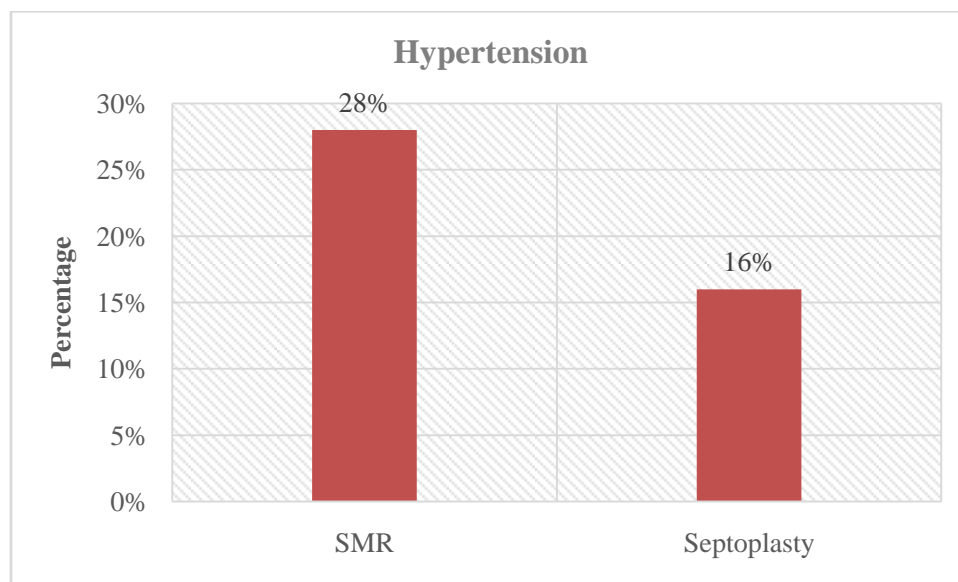
Among the 50 cases, no instances of septal hematoma were reported, thus representing 0% of the cases. Septal perforation, on the other hand, occurred in 4 cases, accounting for 8% of the total. Synechia (adhesions) were observed in 6 cases, representing 12% of the cases. Neither columellar retraction nor supratip deformity occurred in any of the 50 cases, both representing 0%.

Graph-1: Comparison of Diabetic mellitus between SMR and septoplasty.



Out of the patients who underwent SMR, 16% of them had diabetic mellitus, indicating that a proportion of the SMR cases (16%) involved individuals with this condition. Likewise, among the patients who underwent septoplasty, 4% of them had diabetic mellitus, indicating that a portion of the septoplasty cases (4%) involved individuals with this condition.

Graph-2: Comparison of Hypertension in SMR and septoplasty.



Among the patients who underwent SMR, 28% of them had hypertension, indicating that a portion of the SMR cases (28%) involved individuals with this condition. Similarly, among the patients who underwent septoplasty, 16% of them had hypertension, indicating that a proportion of the septoplasty cases (16%) involved individuals with this condition.

Table-3: Comparison of symptoms in SMR pre-operative and post-operative.

Symptoms		SMR (Pre-operative) (n=50)	SMR (Post-operative) (n=50)	Chi-square	p value
Nasal Symptoms	Present	50	11	63.93	<0.001
	Absent	0	39		
Non Nasal Symptoms	Present	37	5	42.03	<0.001

	Absent	13	45		
General Health Symptoms	Present	13	8	1.50	0.21
	Absent	37	42		
Nasal Obstruction	Present	50	10	66.66	<0.001
	Absent	0	40		

Prior to the surgery, all 50 patients reported experiencing nasal symptoms. Following the procedure, 11 patients still had nasal symptoms, while 39 patients experienced relief from nasal symptoms. Statistical analysis using the Chi-square test confirmed a significant association between the surgery and nasal symptoms, indicated by a p-value of less than 0.001.

In terms of non-nasal symptoms, 37 out of the 50 patients reported experiencing such symptoms before the surgery. Post-surgery, only 5 patients continued to experience non-nasal symptoms, while 45 patients experienced a resolution of these symptoms. The Chi-square test revealed a significant association between the surgery and non-nasal symptoms, with a p-value of less than 0.001.

For general health symptoms, 13 out of the 50 patients reported these symptoms before the surgery. Following the procedure, 8 patients still experienced general health symptoms, while 42 patients no longer had such symptoms. However, statistical analysis using the Chi-square test did not find a significant association between the surgery and general health symptoms, as the p-value was 0.21.

Regarding nasal obstruction, all 50 patients reported experiencing it before the surgery. After the symptom. The Chi-square test revealed a significant association between the surgery and nasal obstruction, with a p-value of less than 0.001.

In summary, the data demonstrates that SMR surgery had a significant impact on reducing both nasal and non-nasal symptoms, as well as relieving nasal obstruction. However, the surgery did not show a statistically significant association with general health symptoms, as indicated by the p-value of 0.21.

Table-4: Comparison of symptoms in septoplasty pre-operative and post-operative.

Symptoms		Septoplasty(Pre-operative) (n=50)	Septoplasty (Post-operative) (n=50)	Chi-square	p value
Nasal Symptoms	Present	50	4	85.18	<0.001
	Absent	0	46		
Non Nasal Symptoms	Present	14	10	0.87	0.34
	Absent	36	40		
General Health Symptoms	Present	8	0	8.69	0.003
	Absent	42	50		
Nasal Obstruction	Present	50	12	61.29	<0.001
	Absent	0	38		

In the study, all 50 patients reported nasal symptoms before undergoing the septoplasty surgery. After the procedure, only 4 patients continued to experience nasal symptoms, while 46 patients achieved relief. The statistical analysis using the Chi-square test confirmed a highly significant association between the surgery and nasal symptom improvement ($p < 0.001$). For non-nasal symptoms, 14 patients reported them before the surgery, with 10 patients still experiencing them post-surgery, while 40 patients found relief. The Chi-square test did not reveal a significant association ($p = 0.34$). Before the surgery, 8 patients had general health symptoms, but after the surgery, none reported them. The Chi-square test indicated a significant association ($p = 0.003$) with the resolution of general health symptoms. All 50 patients reported nasal obstruction before the surgery, with 12 patients still experiencing it post-surgery and 38 patients experiencing improvement. The Chi-square test revealed a highly significant association ($p < 0.001$) between the surgery and nasal obstruction improvement.

DISCUSSION:

There is currently no widely accepted non-surgical medical intervention available for a DNS. The most commonly recommended approach to address this condition and mitigate potential

complications is through surgical correction of the septal deviation. SMR and septoplasty are widely utilized techniques for addressing a deviated nasal septum worldwide. [15] Surgical correction of a deviated nasal septum is a common procedure in the United States, aimed at improving quality of life. However, the significance and technical complexities of septal surgery are often underestimated. However, further research is needed to enhance our understanding and knowledge in this area. [16,17]

The present study was conducted to compare the complications of septoplasty and SMR in patients with symptomatic DNS. The results of the present study revealed that 42.00% underwent SMR, while 68.00% underwent septoplasty.

In the present study, the incidence of complications was evaluated for both SMR and septoplasty procedures. Among the SMR cases, septal hematoma, septal perforation, synechiae, columellar retraction, and supratip deformity accounted for 4%, 10%, 6%, 2%, and 2% respectively. In contrast, for septoplasty, there were no reported cases of septal hematoma, while septal perforation accounted for 8% synechiae represented 12% of the cases, while neither columellar retraction nor supratip deformity both representing 0%. In the study conducted by Sheikh MS et al. [15] the occurrence rates of specific complications were analyzed in two groups: group B, which underwent SMR, and group A, which underwent septoplasty. The results showed that septal hematoma, septal perforation were reported to be 1.41% and 8.45% in septoplasty whereas 0% and 7.04% in SMR which were similar to present study findings.

In present study complications the septal perforation, synechiae (adhesion) and columellar retraction were found in 5, 3 and 1 cases while in septoplasty 4 cases of septal perforation 6 cases of synechiae (adhesion) were reported. In the study carried out by Padma et al. [12] the 2 cases of synechiae (adhesion) and 1 case of columellar retraction were reported in SMR while only 2 cases of synechiae (adhesion) were found in septoplasty.

In both the SMR and septoplasty groups, a notable proportion of patients had comorbidities such as diabetes mellitus and hypertension. Among the patients who underwent SMR, 16% had diabetes mellitus and 28% had hypertension. This suggests that a significant number of individuals undergoing SMR had these underlying health conditions.

Majority of patients who underwent SMR had relief of symptoms for all the categories. Relief of symptoms was maximum for non-nasal symptoms which accounted for 45 patients. However statistical analysis using the Chi-square test confirmed a significant association between the surgery and nasal symptoms, non-nasal symptoms and general health indicated by a p-value of less than 0.001. Similarly, Relief of symptoms were maximum for general health symptoms which accounted for all 50 patients. Patients who did not have any improvement following surgery were only 4 with nasal symptoms, 10 with non-nasal symptoms, and 12 with nasal obstructions. However statistical analysis using the Chi-square test confirmed a significant association between the surgery and nasal symptoms, nasal obstruction and general health indicated by a p-value of less than 0.001. The results of post operative symptoms after SMR and septoplasty were similar to the study conducted by Padma et al. [12]

Nasal obstruction is considered a key clinical parameter and a primary outcome associated with septal deviation. This condition causes a blockage in the nasal passage, resulting in difficulty breathing through the affected nostril. In another study conducted by Tahair and Siddiqui Y et al. majority of the patients relief from nasal obstruction which were concurrent to the present study findings. [18, 19]

CONCLUSION:

Based on present study findings, both surgical modalities were found to provide similar post-surgical pain relief. The SMR and septoplasty have demonstrated efficacy in improving symptoms associated with deviated nasal septum. The results of this study indicate that both surgical methods can effectively alleviate nasal obstruction and provide relief to patients. However, it is important to consider various factors such as long-term outcomes, patient preferences, and potential complications when determining the optimal surgical approach. Further research and comparative studies are warranted to gain more insights into the long-term outcomes and potential complications associated with each surgical method.

REFERENCES:

1. Illum P. Septoplasty and compensatory inferior turbinate hypertrophy: long-term results after randomized turbinoplasty. *Eur Arch Otorhinolaryngol.* 1997;254(Suppl. 1):89–92. doi: 10.1007/BF02439733.

2. Berger G, Hammel I, Berger R, Avraham S, Ophir D. Histopathology of the inferior turbinate with compensatory hypertrophy in patients with deviated nasal septum. *Laryngoscope*. 2000;110:2100–2105. doi: 10.1097/00005537-200012000-00024.
3. Berger G, Gass S, Ophir D. The histopathology of the hypertrophic inferior turbinate. *Arch Otolaryngol Head Neck Surg*. 2006;132:588–594. doi: 10.1001/archotol.132.6.588.
4. Kang JW, Yoo JB, Kim CH, Lee JG. Structural changes of inferior turbinate in patients with septal deviation: surgical implication. *J Rhinol*. 2004;11:40–43.
5. Kumar RS, Dharmagadda HS, Burugula K. Decision-making in septal deviations: Septoplasty for anterior septal deviations and submucosal resection for posterior deviations: Is it a practical method? *Adv Hum Biol* 2023;13:42-7.
6. Rudert H. From Killian's submucous septum resection and Cottle's septoplasty to modern plastic septum correction and functional septo- rhinoplasty. *HNO* 1984;32:230- 3
7. Teixeira J, Certal V, Chang ET, Camacho M. Nasal septal deviations: A systematic review of classification systems. *PlastSurgInt* 2016;2016:7089123.11.
8. Cappello ZJ, Minutello K, Dublin AB. Anatomy, head and neck, nose paranasal sinuses. In: StatPearls. Treasure Island (FL): StatPearls Publishing; 2021. Available from: <http://www.ncbi.nlm.nih.gov/books/NBK499826/>. [Last accessed on 2021 Jul 05].
9. Värendh M, Janson C, Bengtsson C, Hellgren J, Holm M, Schlünssen V, *et al*. Nasal symptoms increase the risk of snoring and snoring increases the risk of nasal symptoms. A longitudinal population study. *Sleep Breath* 2021;25:1851- 7.
10. Periyasamy V, Bhat S, Sree Ram MN. Classification of naso septal deviation angle and its clinical implications: A CT scan imaging study of Palakkad population, India. *Indian J Otolaryngol Head Neck Surg* 2019;71:2004- 10.
11. Kumar L, Belaldavar BP, Bannur H. Influence of Deviated Nasal Septum on Nasal Epithelium: An Analysis. *Head Neck Pathol*. 2017;11(4):501-505. doi:10.1007/s12105-017-0819-9
12. K. Padma, M. Prabhakar. Comparative Study of Septoplasty VS SMR International Journal of Contemporary Medical Research 2016;3(11):3251-3255.

13. Mujahid AM, Wahab MU, Bint e Saad A, Abdul Shakoor, Fatima M, Farhan M. Symptomatic septal nasal deviation and its association with sinusitis: A clinical study. *Professional Med J* 2023; 30(03):292-295. <https://doi.org/10.29309/TPMJ/2023.30.03.7342>
14. Gencer ZK, Ozkırış M, Okur A, Karacavuş S, Saydam L. The effect of nasal septal deviation on maxillary sinus volumes and development of maxillary sinusitis. *European Archives of Oto-Rhino-Laryngology*. 2013; 270(12):3069- 73.
15. Sheikh MS, Rehman AU, NASIR WAKEEL YA. Comparison of Complication in SMR vsSeptoplasty. *PAKISTAN JOURNAL OF MEDICAL & HEALTH SCIENCES*. 2017 Apr 1;11(2):537-40.
16. Finkbohner R, Johnston D, Crawford ES, Coselli J, Milewicz DM. Marfan syndrome. Long-term survival and complications after aortic aneurysm repair. *Circulation*. 1995;91(3):728–33.
17. Zoumalan RA, Morris LGT, Zeitler DM, Shah AR. Effects of various submucous resection techniques of septal cartilage on nasal tip projection. *Intl Forum AllergRhinol*. 2011;1(1):78-82.
18. Taher DG. Submucous resection of the septum versus septoplasty a comparison study. *Journal of Wasit for Science and Medicine*. 2015;8(1):82-8.
19. Siddiqui Y, Ishteyaq A, Siddiqui IA, Shaikh N. Effectiveness of Submucosal Resection and Septoplasty in Deviated Nasal Septum: A Study from Vindhya Region.