



Management of Foot Deformity in Charcot Marie Tooth Syndrome

Anwar Abdulsalam Alzarga ¹, Mohsen Mohamed Abdo Mar'ei ², Adel Abdel Azim Ahmed ²,
and Sherif Mohamed Mostafa Elaidy ²

¹Department of Orthopedic, Surgery, Faculty of Medicine, Sirt University, Libya

²Department of Orthopedic, Surgery, Faculty of Medicine, Zagazig University, Egypt

Corresponding Author : Anwar Abdulsalam Alzarga

E-Mail: Anwaralzarga51@gmail.com

Article History: Received: 26.06.2023

Revised:04.07.2023

Accepted: 22.07.2023

Abstract

Cavovarus deformity can be classified by the severity of malalignment ranging from a subtle and flexible to a severe and fixed cavovarus deformity of the foot. In the mild cavovarus foot, careful clinical assessment is required to identify the deformity. Weight-bearing radiographs are necessary to indicate the apex of the deformity and quantify the correction required. Surgery is performed when conservative measures fail and various surgical procedures have been described, including a combination of soft-tissue releases, tendon transfers and osteotomies, all with the aim of achieving a plantigrade and balanced foot. Joint-sparing surgery is the best option in flexible cavovarus foot even in Charcot-Marie-Tooth (CMT) disease (peroneal muscular atrophy). Arthrodesis is indicated in severe rigid cavus foot or in degenerative cases.

Keywords: cavus foot; Charcot-Marie-Tooth disease; tendon transfers; osteotomy; arthrodesis

DOI: 10.48047/ecb/2023.12.10.1001

Introduction

Pes cavus is an increase of normal plantar concavity, where the anterior and posterior weight-bearing areas of the foot are brought closer together. A wide spectrum of foot deformities includes a plantarflexed first ray, forefoot pronation and adduction, and hindfoot varus or high calcaneal pitch. Cavovarus deformity can be classified according to the severity of malalignment ranging from a subtle and flexible cavovarus foot to a severe and fixed cavovarus deformity. [1]

CMT disease results from defects in the genetic code for the protein of the peripheral myelin sheath and is classified into subtypes varying in progression. CMT IA is the most common form including peripheral nerve myelin degeneration and decreased motor nerve conduction. In most cases, the disease

process is progressive rather than static; therefore, the deformities worsen and surgical treatment must be considered to prevent the progression to a fixed and symptomatic deformity. [2]

Radiographic evaluation

Plain film radiographs are essential in surgical planning, not only to identify the site of the deformity but also to quantify the degree of correction that is required and to decide whether to perform an osteotomy or an arthrodesis. The apex of the deformity can vary. Usually the deformity is located in the mid-foot at the transverse tarsal articulation or at the naviculocuneiform joint.[1]

Weight-bearing radiographs of the foot include at least three views:

1. A lateral view of the weight-bearing ankle and foot allows the cavus to be demonstrated and measured.

2. A frontal view of the ankle (Meary view or Salzman view) demonstrates the frontal deformity of the hindfoot.[3]
3. A dorsoplantar view of the forefoot shows adduction of the forefoot and opening of the metatarsal plate.

Numerous geometric measurements have been proposed on lateral weight-bearing radiographs to quantify cavus deformity (Fig. 1). In France, the angle of the medial arch is widely used (Djian-Annonier angle) and in pes cavus foot it is less than 120° . A Hibb's angle (angle between the long axis of the calcaneum and first metatarsal) of more than 45° indicates cavus.[4]

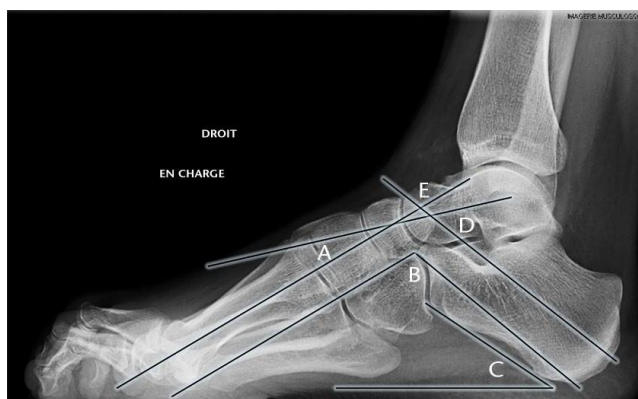


Fig. 1 Radiographic angles on lateral standing radiograph. a) Talo-first metatarsal angle (Meary's angle); b) Djian-Annonier angle less than 120° in cavus foot; c) calcaneal pitch; d) talo-calcaneal angle; e) first metatarsal-calcaneal angle (Hibb's angle).

The intersection point between the first metatarsal axis and the sagittal axis of the talus corresponds to the apex of the deformity which is important when considering osteotomies. The cavus foot is defined as a Meary's angle (the angle between the long axes of the talus and first metatarsal) greater than 5° . In posterior cavus foot, the calcaneal pitch angle is greater than 30° . An associated equinus deformity of the ankle is characterised by a tibio-talar angle greater than 105° .

On the lateral view, a stacking effect may be observed because the first and medial metatarsals tend to be at a greater inclination—the lateral metatarsals are more horizontal—while the talus appears to be flattened due to the rotation of the talus in the coronal and sagittal planes. The medial cuneiform to fifth metatarsal base distance is increased and the fibula appears in a more posterior position related to external rotation of the lower limb. Thickening or fractures of the base of the fifth metatarsal may result from mechanical overload on the lateral border of the foot.

Frontal weight-bearing views are very important to assess to the hindfoot alignment during mid-stance (Fig. 2). Evaluation of the hindfoot varus tilt is therefore essential. For this, a frontal view with a Coleman 'block test' is necessary to evaluate the correctability of this hindfoot varus and appreciate the amount of correction of hindfoot varus achieved after surgical intervention.

Stress views are a useful adjunct in radiographic evaluation to address tibio-talar instability and approach for the reducibility of this talar tilt.

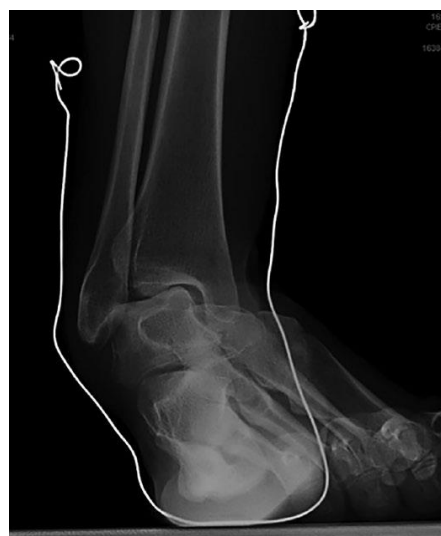

Fig. 2 Anteroposterior weight-bearing view demonstrating tilted talus and medial ankle

degenerative joint secondary to a varus hindfoot deformity.

The ankle radiographs may also show medially local-ised or generalised arthritic changes with narrowing and osteophyte formation of the tibiotalar joint.

MRI or ultrasound are rarely used except to address a severe peroneal tendinopathy when a lateral ligament reconstruction is considered. Also, CT scan or more often single photon-emission computed tomography combined with CT are helpful to assess the hindfoot joints for evidence of arthritis and to specify the site and severity of the degeneration or the presence of an associated lesion [5].

Clinical examination

Clinical examination is the key to successful management of pes cavus, especially in subtle cavovarus. The aim is to confirm the presence and rigidity of the cavovarus deformity but also to identify any underlying neurological disease. In any case, an evaluation of the entire lower limb is mandatory and calf-wasting or hypertrophy should be noted. A complete neurological examination of both the upper and the lower limbs is needed. To detect any muscular imbalance, a full examination of all muscle groups should be performed for power and graded between 1 and 5 on the Medical Research Council (MRC) scale. Neurological investigations are best performed by a neurologist and electrodiagnostic studies can be considered to confirm hereditary motor sensory neuropathies.

Patients can present with a wide range of complaints; among them, pain is the main reason for consultation. Metatarsalgia is most often observed in the anterior cavus foot and talalgias in posterior pes cavus. Local tenderness when wearing shoes and callosities

related to clawed toes are common complaints. Flat-heeled shoes are poorly tolerated and high heels are more comfortable. Walking is disturbed by cramp and dull aching in the calf by contraction of the muscle of the plantar arch during prolonged walking. Instability of the ankle leads to repeated sprains in varus.

The clinical examination of the foot should begin with the evaluation of the patterns of wear affecting the heels of the shoes, especially on the lateral side in hindfoot varus. Much information can be obtained from mere observation of the weight-bearing posture of the foot (high arch, metatarsus adductus, clawing of the toes, callosity under the first or fifth metatarsal heads, varus heel, prominence or posterior position of the lateral malleolus). In the cavovarus foot, it is not unusual to find marked callosities under the first and fifth metatarsal heads.

Passive and active range of movement of the ankle, hindfoot and forefoot should be noted and stability tested. Variations in muscle balance should be tested with resisted inversion and eversion.

Hindfoot varus is confirmed through the 'peek-a-boo' heel sign, which is the clinical condition whereby the heel is visible on the medial side when viewing the patient from the front with the feet in neutral rotation (Fig. 3).

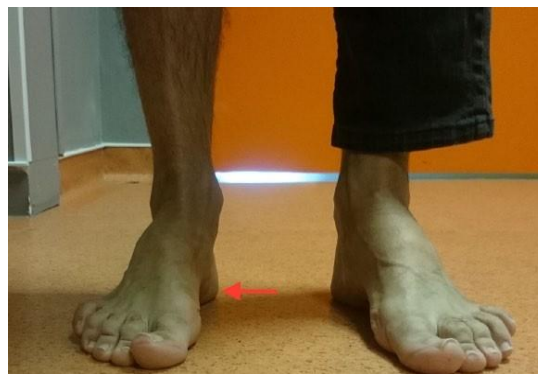

Fig. 3 Right 'peek-a-boo' heel is considered a sign of excessive heel varus (arrow).

The Coleman 'block test' should be performed to ascertain whether hindfoot varus is correctable or not.¹⁴ If the hindfoot varus remains, then the deformity is fixed. However, if the hindfoot corrects to physiologic valgus, then the deformity is flexible and driven by the forefoot deformity. Frequently, the hindfoot varus partially corrects, and it is important to see the magnitude of the heel correction beyond neutral or a varus position. Some authors have suggested manoeuvres for evaluating hind-foot flexibility by placing the patient in a prone position with the knee flexed at 90°. In this position, the foot is allowed to move freely without the influence of the first ray

and hindfoot manipulation is easily performed, allowing determination of rigidity.

To assess the presence of an isolated gastrocnemius tightness, the Silfverskiöld test is performed by comparing the range of ankle dorsiflexion with the knee in flexion and in extension (Fig. 4). [6] Knee flexion relaxes the gastrocnemius but leaves soleus tension unaffected and a large range of dorsiflexion with the knee flexed means isolated gastrocnemius tightness. Without improvement of ankle dorsiflexion with the knee flexed at 90°, gastrocnemius contracture is diagnosed. This aspect should be addressed at the time of surgery. At the end of this clinical investigation, we must separate subtle and severe cavus feet. [7]

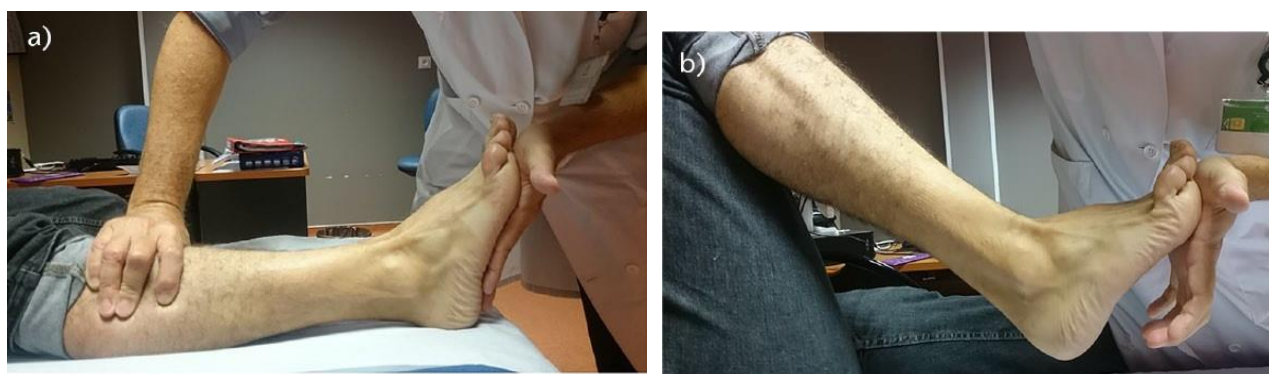

Fig. 4 a and b) Silfverskiöld test to assess the presence of an isolated gastrocnemius tightness.

The subtle cavus foot is easy to misdiagnose because patients often present with symptoms relating to forefoot overload, and most of the time they exhibit a flexible hind-foot with a subtle varus on standing frontal examination.

Examination typically reveals a high arch and lesser metatarsalgia is a common complaint. Stress fractures of the lesser metatarsals and fractures of the fifth metatarsal are common. Ankle instability, recurrent sprains and lateral pain are common presenting symptoms. This may be due to lateral overload caused by the hindfoot varus but may also be due to lax lateral ankle

ligaments.¹⁶⁻¹⁸ Excessive loading on the lateral side of the ankle may lead to peroneal tendon symptoms including tendinopathy, tears, subluxations or dislocations. Anteromedial impingement between talar and tibial spurs has been described and appears to be more common in those with subtle cavus feet. In the hindfoot, the symptoms may include Achilles tendinopathy or plantar fasciitis [8].

By contrast, a severe cavus foot is often the end-product of a longstanding deformity associated with a plantar-flexed first ray, or sometimes even severe plantarflexion through the entire midfoot, an increased calcaneal

pitch and especially neuromuscular foot imbalance (such as is seen with CMT). This typically includes a fixed heel varus that no longer corrects with Coleman block testing[9].

Treatment

Non-surgical management

A large number of patients with milder symptoms associated with a cavus deformity can be treated successfully by conservative means. In most cases, a reducible deformity can be corrected using a custom orthosis which produces reduced pain and instability. The aim of conservative treatment is to realign the hindfoot correctly to offload the lateral border of the foot and to overcome the gastrocnemius tightness. The type of orthotic chosen depends on the Coleman 'block test'. In a forefoot-driven cavus with a supple hindfoot, correction of the plantarflexed first ray will allow the hindfoot varus to correct and a first ray recess associated with a metatarsal bar and lateral forefoot post are frequent enough. Furthermore, in front of a hindfoot-driven cavus, the appropriate orthosis includes a lateral hindfoot-to- midfoot heel wedge with a first metatarsal recess and minimal or absent medial arch support. To treat equinus, a gastrocnemius-stretching programme should be initiated and the heel may be slightly elevated. In addition, ankle instability is treated with proprioception training and an ankle support brace worn during exercise [10].

Surgical treatment

Surgery is considered if conservative treatments fail to control the symptoms but operative treatment should only be considered in carefully selected patients. The aim of surgery is to achieve a foot that is plantigrade, mobile and pain-free. In any case, surgical treatment should leave the foot in a normal

position or slightly overcorrected, because an iatrogenic flat foot is better tolerated than a residual cavus deformity. A wide variety of procedures for the treatment of cavo- varus foot deformities have been described including soft- tissue release or lengthening and tendon transfers, hindfoot or midfoot osteotomy, or arthrodesis [11].

Soft-tissue procedures

Initially, the deformities are flexible and reversible but if the muscle imbalance remains the foot becomes stiffer and less adaptable. Joint preservation and decreased deterioration of the deformities can be obtained by balancing of the affected muscles; therefore, various soft-tissue procedures are preferred while the deformity is flexible and corrective arthrodesis or osteotomy must be used when the deformity becomes rigid. Soft-tissue release alone is no longer applicable in fixed deformities in adults. The surgical options to address idiopathic cavovarus and neuromuscular deformity are not significantly different, but severe rigid cavus deformities are most frequently observed in neurological diseases leading to midfoot correction or triple arthrodesis. In subtle cavovarus foot (idiopathic cavus deformity), the equinus deformity and fixed forefoot deformity are addressed first and a valgus osteotomy should be performed if required. [11]

The Achilles tendon must be carefully assessed. If a global gastrosoleus contracture is present, an Achilles tendon lengthening using a triple hemisection is performed. In some cases, an isolated gastrocnemius tightness is addressed by using a gastrocnemius recession (Strayer or Barouk technique). Achilles tendon lengthening is justified when the heel is in varus, but if the heel is in a neutral position, the increased

calcaneal pitch is secondary to Achilles weakness and tendon lengthening should be avoided [12].

To the extent that plantar fascia retraction contributes to the high medial arch, the need for a plantar fascia release is debatable. A subcutaneous plantar fascia release may benefit patients with minimal deformity. In severe fixed pes cavus a complete release as recommended by Steindler may be advised.[13]

Tendon transfers can be used when there is an identifiable muscle imbalance, especially in younger patients with a flexible deformity. It is recommended to transfer only muscle tendon units with a power of MRC 4 or MRC 5. Tendon transfers are also important after osteotomies for preventing recurrence of the deformity and should be done within the same surgery. Most authors recommend using peroneus longus (PL) to brevis (PB) tendon transfer in subtle cavovarus foot to correct forefoot pronation, reduce the first ray plantarflexion and reinforce the weak eversion of the hindfoot. Tibialis posterior tendon transfer is more commonly used in hereditary sensory motor neuropathy to weaken the deforming power and strengthen deficient functions of the anterior tibial tendon. Furthermore, this transfer reduces the recruitment of the long toe extensors in assisting in ankle dorsiflexion. Transfer onto the second cuneiform improves neutral dorsiflexion whereas insertion on the cuboid reinforces a weaker eversion of the foot [14].

Osteotomies

Dorsal wedge osteotomy of the first metatarsal may be an effective way to decrease the medial forefoot plantarflexion deformity if the pre-operative Coleman 'block test' has confirmed a forefoot-driven pes cavus.²⁷ The first metatarsal is exposed and a dorsal wedge is excised around 2 cm from the tarsometatarsal joint. For severe first ray deformity with poor correctability, a first tarso-metatarsal dorsiflexion arthrodesis is preferred, which produces a higher degree of forefoot cavus correction than metatarsal osteotomy. If the Meary's angle is markedly increased with poor passive correctability, this dorsal metatarsal osteotomy will be insufficient and a midfoot dorsal wedge osteotomy should be considered [15].

Midfoot dorsal wedge osteotomy is performed at the apex of the deformity and aims to realign the axes of the talus and first metatarsal. Anterior tarsectomy, described by Cole and Meary, is centred on the naviculocuneiform space and the cuboid and consists of a dorsomedial closing-wedge osteotomy that predominantly affects the medial rays (Fig. 5). This midfoot dorsal-wedge osteotomy allows correction in the frontal, sagittal and coronal planes without compromising the tarsal inversion/eversion and dorsoplantar motion of the foot. In our experience, one-third of patients were not satisfied with the outcome because of residual mild to moderate pain; moreover, only 20° to 25° of tarsometatarsal correction can be obtained using Cole's osteotomy leaving, in some cases, residual cavus deformity (Fig. 6).[16]

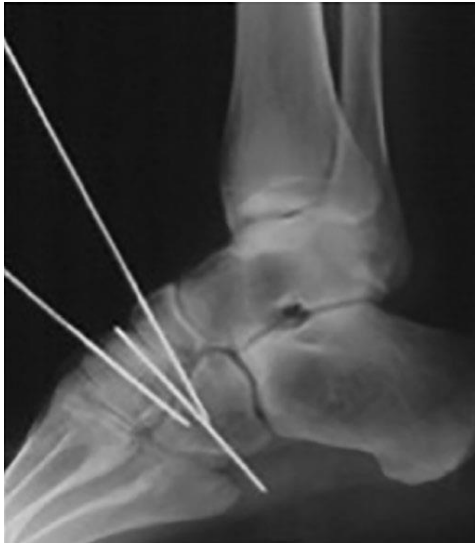

Fig. 5 Fluoroscopic control with pins before midfoot dorsal wedge osteotomy according to Cole's procedure

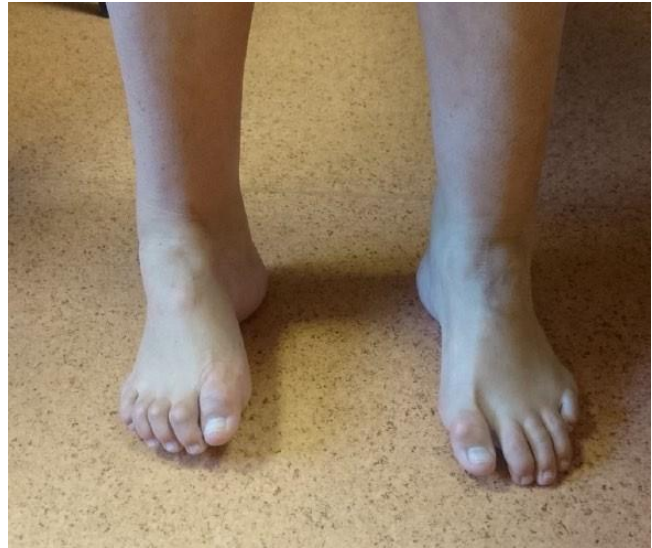

Fig. 6 Post-operative result after surgical correction of a left cavovarus deformity following midfoot osteotomy. Note the significant deformity of the left uncorrected side.

Various other types of osteotomy may be considered. Wilcox and Weiner [17] proposed intra- cuneiform osteotomy and other authors considered tarso- metatarsal resection or metatarsal osteotomy but these procedures do not allow greater corrections to be made. These metatarsal osteotomies lie distal to the apex of the cavus deformity leaving a residual dorsal bony prominence proximally in addition to an inadequate correction of the frontal plane deformity.

Hindfoot surgery

The Coleman 'block test' and hindfoot alignment view are useful to assess the need for corrective hindfoot surgery. When the hindfoot varus is reducible and forefoot-driven, a valgus calcaneal osteotomy is not required. Conversely, if the hindfoot varus is flexible or if there is residual varus after midfoot surgery, a calcaneal osteotomy must be considered. In case of any doubt, an overcorrection is better than an undercorrection [18].

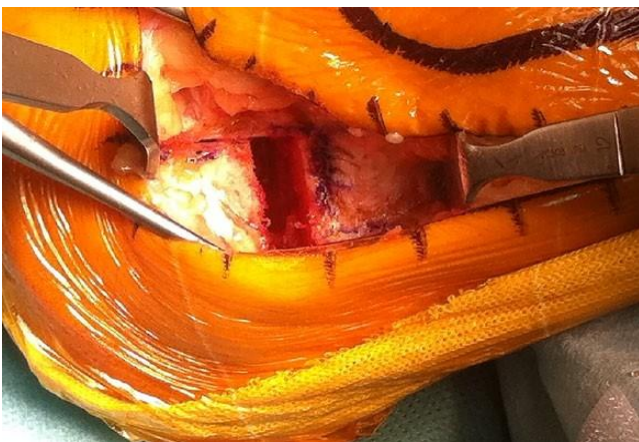

Fig. 7 Operative view showing a lateral bone wedge osteotomy described by Malerba and DiMarchi.

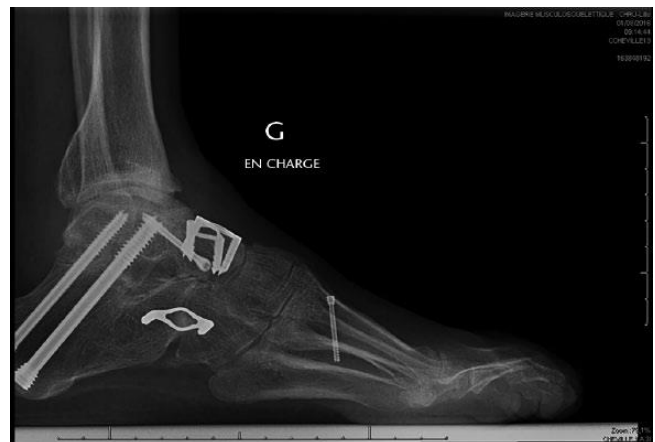

Fig. 8 Post-operative weight-bearing radiographs after surgical correction using triple arthrodesis associated with a first metatarsal osteotomy.

Also, with lateral sliding calcaneal osteotomy there is a limit to the amount of translation that can be obtained. Moderate hindfoot varus associated with subtle cavovarus is easily addressed with a Dwyer or a lateralising calcaneal osteotomy but severe deformity may require more complex osteotomies. In those cases, the authors usually perform a Z-osteotomy described by Malerba and DiMarchi which removes a lateral wedge of varying thickness that allows multiplanar correction of the calcaneal deformity.¹⁸

If the talus is tilted in the mortise on the anteroposterior (AP) ankle view, the cavovarus foot is at risk of osteoarthritis related to increased point loading. It is essential to look for a lateral ligament complex deficiency and a reciprocal deltoid ligament tightness which requires lateral ligament reconstruction associated with medial deltoid ligament release [19].

In order for these ligament reconstruction procedures to be effective and long-lasting, the hindfoot varus deformity should be realigned by bony correction before the ligament reconstruction and the patient must be aware that there is a significant rate of failure and further surgery may be required in case of progression of their arthritis^[20].

Associated toe deformities

Appropriate osteotomies of the midfoot provide some degree of correction of the claw toe deformities and flexible correctable claw toes may improve spontaneously after midfoot osteotomies. If the correction is not sufficient and the toes remain mobile, flexor to extensor tendon transfers (Girdlestone transfer) may be performed to improve the realignment of the toes. Once toe deformities have become fixed, a proximal interphalangeal joint arthrodesis or excision

arthroplasty is required. In some cases, clawing of the hallux requires a modified Jones procedure with a transfer of the extensor hallucis longus tendon through the first metatarsal neck and arthrodesis of the interphalangeal joint. Various others procedures can be performed if there is associated pathology, guided by clinical assessment and imaging. Ankle arthroscopy allows debridement and removal of a large antero-medial osteophytes or anterior ankle synovitis. Repair is recommended for peroneal tendons that have damage to more than 50% of their cross-sectional area. An occasional Jones fracture may require fixation [21].

Rigid cavovarus deformity

In adult patients presenting with rigid cavovarus deformity, the management is challenging and fusions and osteotomies represent the mainstay of treatment once the foot has lost its reducibility (Fig. 10). Severe rigid cavus foot requires complex midfoot osteotomies to correct three-dimensional multiplanar deformity. Results of a plantigrade foot obtained by an arthrodesis are better than joint-sparing surgery leading to an inadequate and hence painful correction. However, many authors consider that it is preferable to fuse the minimum number of joints possible in order to maintain as much function as possible.

In many cases, a triple arthrodesis is indicated,⁴² but soft-tissue balancing, by means of tendon transfers, must frequently be included in the correction to maintain a successful result over time. In the absence of the peroneus longus-to-brevis transfer the recurrence of first metatarsal plantarflexion deformity may occur. Likewise, saving the posterior tibial tendon leads to progression of

heel varus and causes adductus at the talonavicular level. [22]

Midtarsal tarsectomy was recommended by Imhäuser and Steinhäusser. [23] The operation centres on the midtarsal joint space and removes a dorso lateral bone wedge, which allows the cavus and adduction of the forefoot to be corrected. If the cavus is marked, the bone wedge can include removal of the whole of the navicular bone and also encroach on the cuneiform bones.

Long-term follow-up studies have shown a high incidence of osteoarthritis of the remaining foot joints after this triple arthrodesis. In order to preserve ankle motion, some authors considered that if less than one-third of the ankle joint is affected, then realignment allows a mobile joint relatively free of symptoms. If more than one-third of the ankle joint has degenerative changes the results are less predictable and a tibiotalar fusion could be advised.

Conclusion

Recent literature indicates that adult cavovarus foot deformities should be commonly addressed with joint preservation osteotomies and adjunctive soft-tissue procedures and less with triple arthrodesis, especially in subtle cavovarus foot. Many surgical options are available to achieve good results and the order in which surgery is performed is important. The fixed forefoot deformity is addressed first and a valgising osteotomy should be performed if required. Any bony correction must be in conjunction with a soft-tissue balancing procedure and residual toe deformities are corrected as a final step. Treatment strategies should be individualized but the difficulty in obtaining a plantigrade and balanced foot using conservative surgery must not be forgotten.

REFERENCES

- 1- **Nogueira MP, Farcetta F, Zuccon A.** Cavus foot. *Foot Ankle Clin* 2015;20:645-656.
- 2- **Joo SY, Choi BO, Kim DY, et al.** Foot deformity in charcot marie tooth disease according to disease severity. *Ann Rehabil Med* 2011;35:499-506.
- 3- **Saltzman CL, el-Khoury GY.** The hindfoot alignment view. *Foot Ankle Int* 1995;16:572-576.
- 4- **Rosenbaum AJ, Lisella J, Patel N, Phillips N.** The cavus foot. *Med Clin North Am* 2014;98:301-312
- 5- **Park HJ, Cha SD, Kim HS, et al.** Reliability of MRI findings of peroneal tendinopathy in patients with lateral chronic ankle instability. *Clin Orthop Surg* 2010;2:237-243
- 6- **Barouk P, Barouk LS.** Clinical diagnosis of gastrocnemius tightness. *Foot Ankle Clin* 2014;19:659-66
- 7- **Manoli A II, graham B.** The subtle cavus foot, “the underpronator”. *Foot Ankle Int* 2005;26:256-263.
- 8- **Deben SE, Pomeroy gC.** Subtle cavus foot: diagnosis and management. *J Am Acad Orthop Surg* 2014;22:512-520.
- 9- **Rose KJ, Hiller CE, Mandarakas M, et al.** Correlates of functional ankle instability in children and adolescents with Charcot-Marie-Tooth disease. *J Foot Ankle Res* 2015;8:61
- 10- **Choi JK, Cha EJ, Kim KA, Won Y, Kim JJ.** Effects of custom-made insoles on idiopathic pes cavus foot during walking. *Biomed Mater Eng* 2015;26:S705-S715.
- 11- **Maskill MP, Maskill JD, Pomeroy gC.** Surgical management and treatment

- algorithm for the subtle cavovarus foot. *Foot Ankle Int* 2010;31:1057-1063
- 12- **Hsu RY, VanValkenburg S, Tanriover A, Digiovanni CW.** Surgical techniques of gastrocnemius lengthening. *Foot Ankle Clin* 2014;19:745-765.
- 13- **Steindler A.** Stripping of the os calcis. *Am J Orthop Surg* 1920;2:8-12.
- 14- **Ortiz C, Wagner E.** Tendon transfers in cavovarus foot. *Foot Ankle Clin* 2014;19: 49-58
- 15- **Leeuwesteijn AE, de Visser E, Louwerens JW.** Flexible cavovarus feet in Charcot-Marie-Tooth disease treated with first ray proximal dorsiflexion osteotomy combined with soft tissue surgery: a short-term to mid-term outcome study. *Foot Ankle Surg* 2010;16:142-147.
- 16- **Faldini C, Traina F, Nanni M, et al.** Surgical treatment of cavus foot in Charcot- Marie-tooth disease: a review of twenty-four cases: AAOS exhibit selection. *J Bone Joint Surg [Am]* 2015;97:e30
- 17- **Wilcox Pg, Weiner DS.** The Akron midtarsal dome osteotomy in the treatment of rigid pes cavus: a preliminary review. *J Pediatr Orthop* 1985;5:333-338.
- 18- **Malerba F, De Marchi F.** Calcaneal osteotomies. *Foot Ankle Clin* 2005;10:523-540, vii
- 19- **Fortin PT, guettler J, Manoli A II.** Idiopathic cavovarus and lateral ankle instability: recognition and treatment implications relating to ankle arthritis. *Foot Ankle Int* 2002;23:1031-1037.
- 20- **Bosman HA, Robinson AH.** Treatment of ankle instability with an associated cavus deformity. *Foot Ankle Clin* 2013;18:643-657.
- 21- **Derner R, Holmes J.** Jones tendon transfer. *Clin Podiatr Med Surg* 2016;33:55-62.
- 22- **Zide JR, Myerson MS.** Arthrodesis for the cavus foot: when, where, and how? *Foot Ankle Clin* 2013;18:755-767.