



## OPTIMIZATION OF TECHNICAL ASPECTS OF STUMECTOMY IN TOXIC GOITER

Zayniev Alisher Faridunovich, Kurbaniyazov Zafar Babajanovich, Babajanov Akhmadjon Sultanbaevich, Tukhtaev Jamshid Kodirkulovich, Alimov Jurabek Ibodullaevich  
Samarkand State Medical University

---

### ABSTRACT

The results of surgical treatment of 112 patients with toxic forms of goiter were analyzed. Techniques for performing individual stages of strumectomy have been improved, which made it possible to avoid intraoperative complications. Achieved a reduction in the time period for performing complex stages from  $15.8 \pm 0.9$  to  $6.7 \pm 0.5$  minutes ( $p < 0.001$ ) and, accordingly, the total operation time from  $92.7 \pm 4.8$  to  $63.4 \pm 3.6$  minutes ( $p < 0.001$ ).

**Key words:** diffuse toxic goiter, surgical treatment.

---

**DOI:** 10.48047/ecb/2023.12.8.679

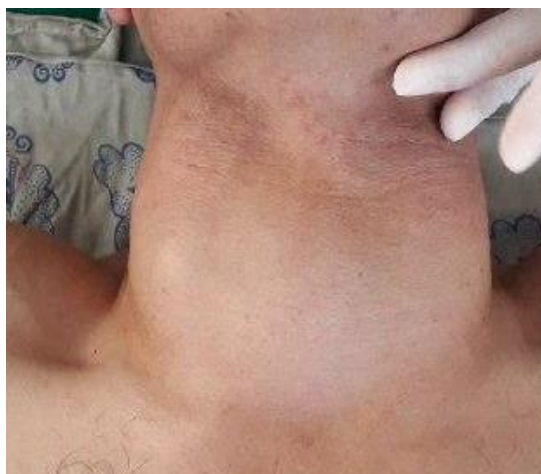### INTRODUCTION

The treatment of patients with diffuse toxic goiter (DTG) remains an unsolved problem of modern medicine, and above all, this is due to the fact that there is no single generally accepted approach to the treatment of this category of patients [5]. It is known that through conservative therapy it is not always possible to achieve a stable clinical effect, and the recurrence of the disease, according to various sources, can reach 40% [1,3,4]. In Uzbekistan, surgical methods play a leading role in the treatment of these patients [2]. At the same time, the choice of the optimal volume of surgery in a particular patient with DTG remains the subject of discussion.

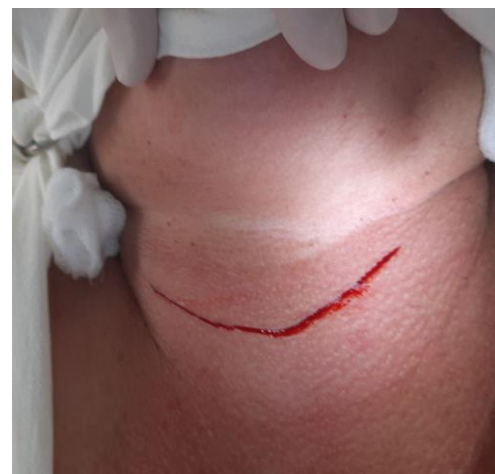**The purpose of the study.** Improve techniques for performing strumectomy in patients with toxic forms of goiter.

The study included the results of treatment of 112 patients with toxic forms of goiter admitted to the surgical departments of the multidisciplinary clinic of the Samarkand State Medical University and the city medical association No. 1 in the period from 2012 to 2021. Patients were conventionally divided into two study groups. In 2012-2016 52 (46.4%) patients who made up the comparison group were operated on from 2017 to 2021. 60 (53.6%) patients were operated, which were included in the main group. In the main group, 40 (66.7%) patients underwent subtotal resection of the thyroid gland (TG), 19 (31.7%) patients with significant thyroid tissue proliferation and recurrent toxic goiter underwent thyroidectomy, and 1 (1.7%) patient performed hemithyroidectomy.

We have improved the individual stages of performing strumectomy in toxic goiter. The patient was placed on the operating table in the supine position with the head tilted back - neck hyperextension, for which a roller was placed under the shoulder blades (Fig. 1).

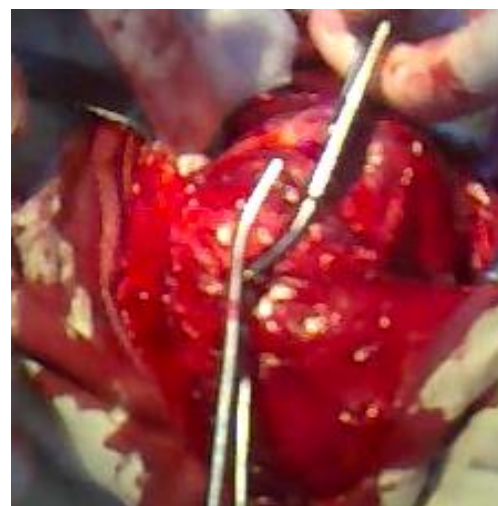
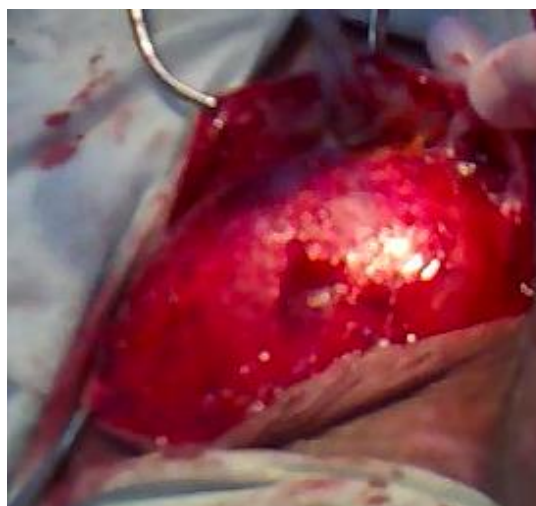
**Figure 1. Hyperextension of the neck with a “roller” placed under the shoulder blades**



**Figure 2. Skin incision line according to Kocher**

In all patients, a collar-shaped Kocher incision was used (Fig. 2). The length of the incision depended on the size of the goiter, the nature of the pathology, the anatomical features of the patient's neck and varied from 6 to 20 cm. When cutting the skin, the scalpel was placed strictly perpendicular to its surface. To prepare the upper skin-subcutaneous flap, the scalpel was placed at an angle of 20°-30° with respect to the skin plane. After hemostasis, the wound was covered with sterile material. The platysma was dissected and transected together with the superficial veins located below it within the second fascia (Fig. 3). The mobilization of the prethyroid muscle groups was mandatory (Fig. 4).



**Figure 3. Preparation of skin flaps**

The anterior and posterior layers of the third fascia of the neck were dissected along the midline of the neck at a distance of 3-4 cm up and down, after which, using a Kocher probe, the prethyroid muscles were separated from the third fascia of the neck and divided on each side into portions, crossed on clamps or with using electrocoagulation. For a wide exposure of the thyroid gland, the retractor proposed by us was installed.

In the practice of thyroid surgery, in order to provide access to the gland, the prethyroid muscles are retracted in the cranial and caudal direction using special dilators - Farabef or Vorobyov's instrument, which makes it difficult to conduct a complete examination of the gland.

In order to level the above technical difficulties, we proposed and applied a modified retractor tool (Fig. 5).

**Figure 5. Modified retractor for thyroid surgery**

The retractor provided wide access to the thyroid gland, which allowed for sufficient exposure to the thyroid gland, examination and surgical procedures without traumatizing the gland. The surgical instrument developed by us created favorable conditions for the detection of all thyroid nodes, avoiding damage to the recurrent nerves and other important elements in the vicinity of the gland. In addition, branches The retractor is equipped with a centimeter ruler along the length and depth of the wound to measure the volume of thyroid tissues.

When performing subtotal resection of the thyroid gland, the volume of residual tissue was from 1.0 to 5.3 ml, on average  $3.0 \pm 1.2$  ml. To determine the size and calculate the volume of the thyroid residue in all patients of the main group using a centimeter branch line retractor was measured and the volume of residual tissue was calculated. For this, we used the formula

proposed by J. Brunn et al. (1981):  $V = A \cdot x B \cdot x C \cdot x 0.479$  where: **A** - length, **B** - width, **C** - thickness, 0.479 - ellipsoid coefficient. At values greater than 6 ml, resection of the remaining tissue was performed and the measurement of the volume of the remainder was repeated according to the above formula.

Thus, the retractor proposed by us belongs to surgical instruments and is used to provide access to the organs of the neck by retracting and fixing the edges of the wound, keeping the position of the neurovascular bundle on the neck under visual control. The device is a structure consisting of a four-sided curved crossbar, on which two sliders are put on with curved brackets rigidly fixed to them. The sliders are equipped with clamping screws for fixing them on the crossbar in the desired position. The brackets are equipped with two semicircular hooks 1 cm wide and with a curvature radius of 1.3 cm. The hooks distal from the crossbar are rigidly fixed to the bracket. The proximal hooks on the bracket can be moved along the bracket and rotated around the axis. The clamping screws of the hooks allow you to fix them in the desired position.

After installing the retractor, they proceeded to palpation revision of the thyroid gland, assessing its size, macroscopic changes and blood supply characteristics. Isolation of the thyroid gland began with the intersection of the ligaments fixing it to the trachea above and below the isthmus.

After isolation of the pyramidal process of the thyroid gland, it was transected with clamps. Then they proceeded to isolate the upper and lower thyroid arteries, which, after crossing with clamps, were tied twice on the thyroid capsule.

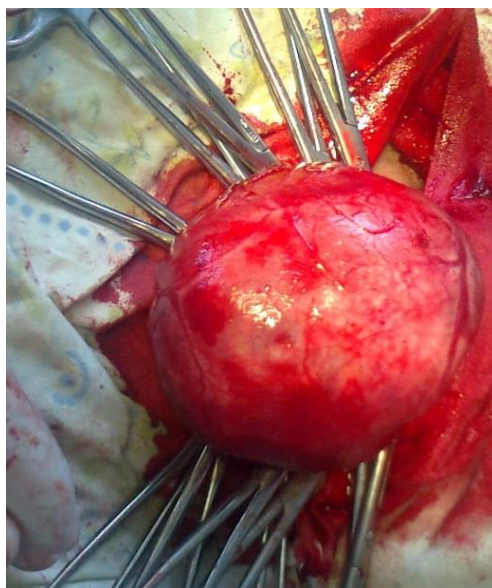
Prior to arterial ligation, any manipulation of the thyroid tissue was considered a gross technical error. Compliance with this rule made it possible to perform the stages of resection of the thyroid gland with minimal blood loss. To facilitate the isolation and ligation of the thyroid arteries, the thyroid gland was sutured with suture threads or the parenchyma was captured with claws. Dosed traction for them contributed to the removal of the thyroid gland into the wound, which facilitated manipulations during ligation of the arteries.

Resection of the thyroid gland began with the intersection of the isthmus. For this clamp Billroth formed a tunnel between the anterior surface of the trachea and the posterior isthmus surface. The isthmus was tied with two ligatures and then between them it was crossed, exposing the anterior surface of the trachea.

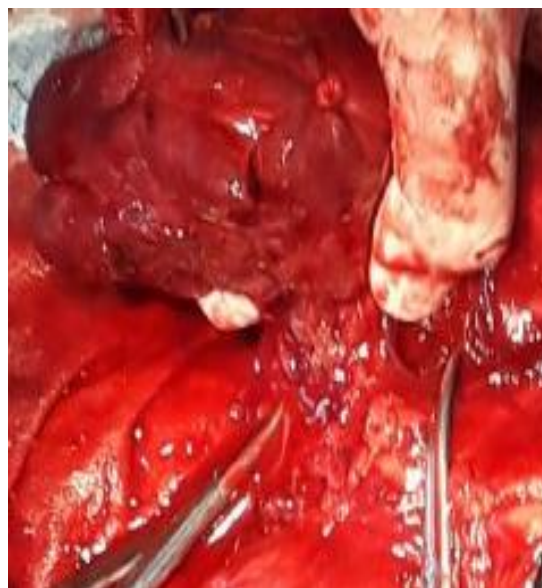Mobilization and resection of the thyroid lobes were performed subfascially within posterior leaf of the fourth fascia. To do this, outside under the back leaf of the fascia raised the index finger of the right hand.



Resection of the thyroid gland was started from the side of the transected isthmus. clamps imposed on the tissue of the gland, successively separating its back surface from the larynx and trachea (Fig. 6).



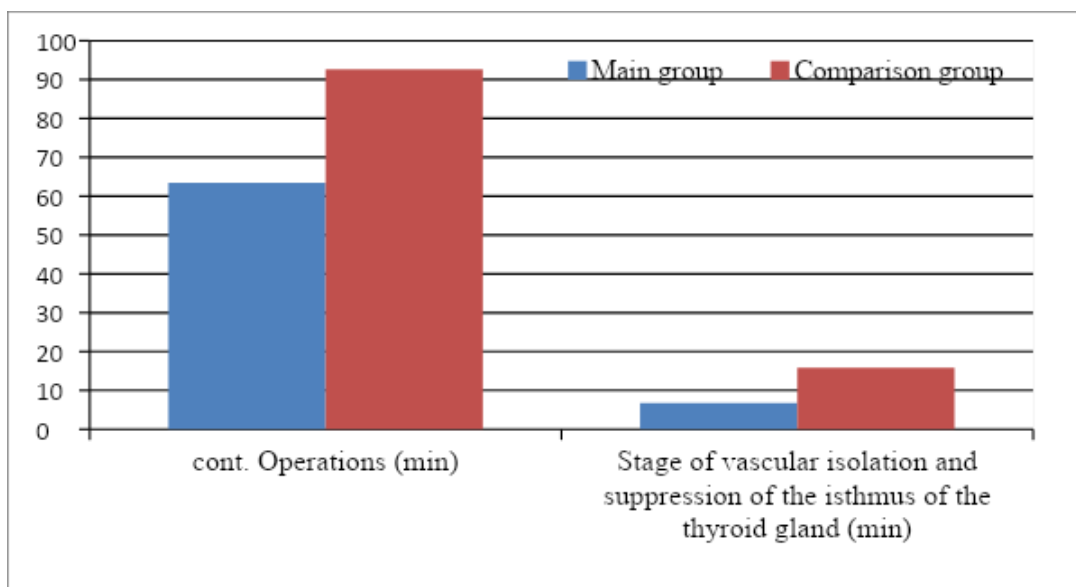
**Figure 6. Applying clamps on the tissue of the gland**



**Figure 7. Mobilization of the thyroid gland from the trachea, the intersection of small vessels**

Applying clamps to the vessels of the parenchyma of the gland, they were crossed with scissors. They tried to resect the gland wedge-shaped for in order to facilitate the formation of thyroid lobes. After resection of a part of the gland carried out hemostasis by ligation of vessels. During the mobilization clamps were applied under visual control only on a "dry" operating room. field, after which the lobe was finally resected (Fig. 7).

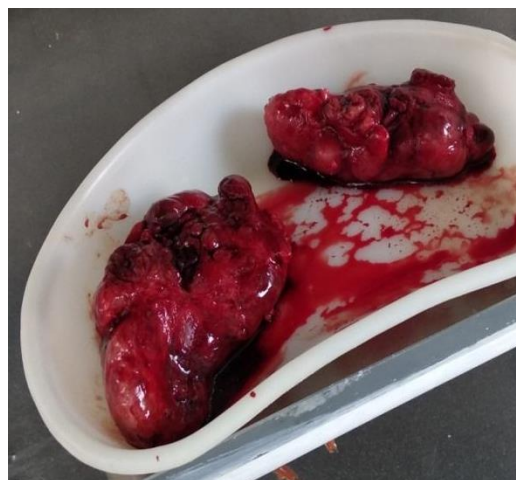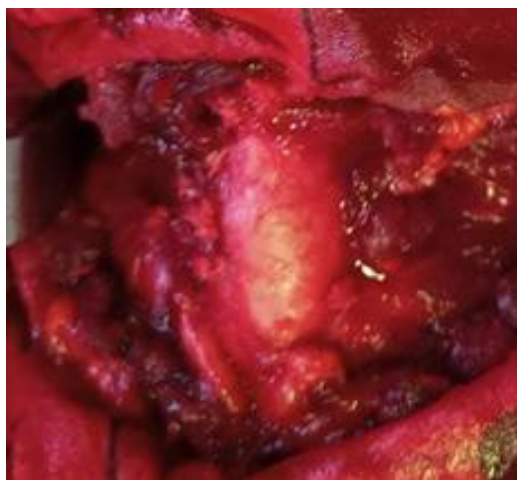
It should be noted that the stages of isolation of the thyroid vessels and ensuring a wide release of the anterior surface of the trachea are one of the difficult stages of strumectomy. However, the improvement of the performance of individual stages of the operation and the use of the proposed tool greatly simplified the course of the operation. As a result, the period of difficult stages was reduced from  $15.8 \pm 0.9$  to  $6.7 \pm 0.5$  minutes ( $p < 0.001$ ), respectively, the total operation time was reduced from  $92.7 \pm 4.8$  to  $63.4 \pm 3.6$  minutes ( $p < 0.001$ ) (Fig. 8).



**Figure 8. Comparative indicators of the duration of the operation (min.) in the compared groups**

In fact, only 11.6% of cases in surgery of toxic forms of goiter in our observations encountered nodular forms of goiter, in the remaining 88.4% of cases there were diffuse, mixed and recurrent forms of goiter, and at the same time, the improvement of techniques made it possible to level the risk of intraoperative complications, such as bleeding, damage to the trachea and recurrent laryngeal nerve.

At the beginning of work for the prevention of relapse and postoperative hypothyroidism the residual volume of the thyroid tissue varied from 3 to 10 mm (Fig. 9). After resection of the gland in it bandaged the small vessels remaining on the clamps, and then formed stump by suturing the medial and lateral leaves and fascia together with the remaining parenchyma of the gland.



**Figure 9. Bare trachea after subtotal, subfascial strumectomy****Figure 10. Removed thyroid tissue, material for intraoperative express biopsy**

The peculiarity of the operation for unilateral toxic adenoma was that in the absence, according to additional studies, nodular formations in the contralateral lobe of the thyroid gland after isolation, but prior to ligation of the SC, we performed its wedge-shaped dissection, allowing to reveal the presence or absence of nodal formations. If the pathology is not was, then after hemostasis, the capsule of the lobe of the gland was sutured. If nodules were found in the lobe, subtotal subfascial resection was also performed.

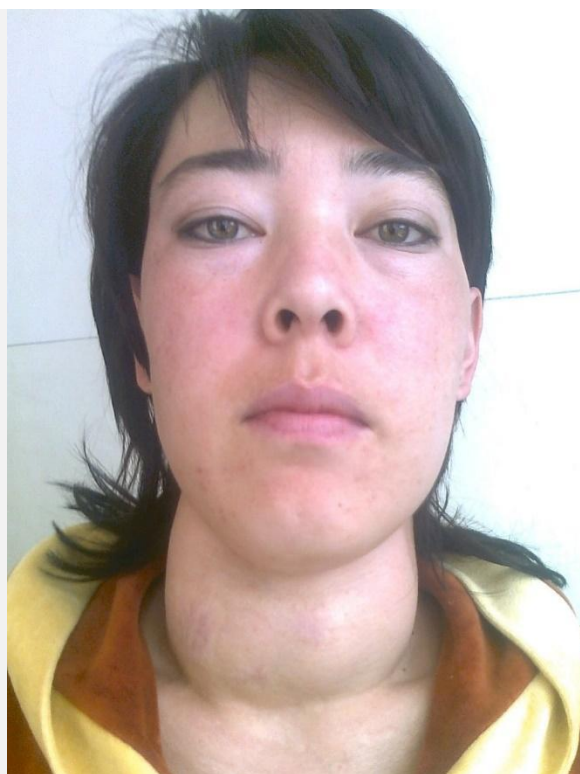Total strumectomy or total removal of the lobe was performed in case of nodular formations occupying the entire thyroid parenchyma.

After resection, the removed thyroid tissue was sent for histopathological examination (Fig. 4.10).

*Here is a clinical observation: Patient D., 23 years old, was admitted to the clinic on December 12, 2018 with complaints of a tumor-like formation in the anterior neck region, shortness of breath and swallowing disorders, palpitations, irritability. A tumor-like formation in the anterior region of the neck appeared about 8 years ago, in the last year dyspnea and palpitations intensified, she was under the control of an endocrinologist, who was prescribed thyreostatics and recommended surgical treatment.*

*The general condition of the patient at admission of moderate severity, the skin is clean, pale pink. Vesicular breathing is auscultated in the lungs on both sides, no wheezing. Heart sounds are clear, rhythmic, Ps 110 beats per minute. The tongue is wet. The abdomen is of normal shape, participates in the act of breathing, soft, painless on palpation. The liver and spleen are not palpable. Stool and urination free.*

*On local examination, the configuration of the neck was changed, a tumor-like formation was noted, on palpation of a soft-elastic consistency, sedentary, painless, 10.0 × 12.0 cm in size. The skin in this area is not hyperemic, moist (Fig. 11).*

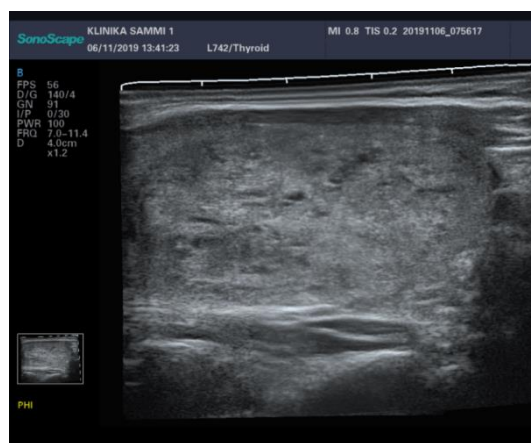

**Figure 11. Patient D., aged 23, diagnosed with diffuse toxic goiter of the 5th degree, thyrotoxicosis of the 2nd degree.**

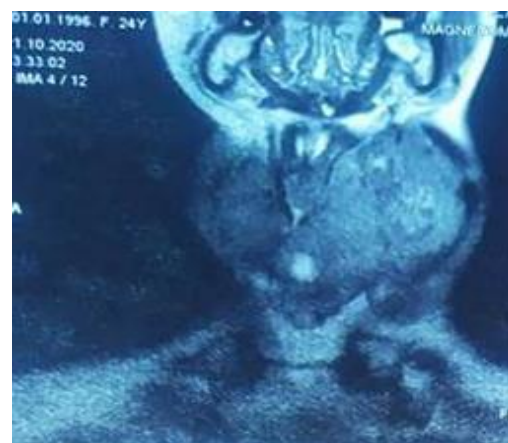*Complete blood count: Hb-106 g/l, er.- $3.4 \times 10^{12} / \mu\text{l}$ , F-0.8, thrombus-230, l.- $8.7 \times 10^9 / \mu\text{l}$ , VSK-3'50"-4' 00", p.-3%, s.-65%, eos.-3%, lymph.-20%, mon.-7, ESR-5 mm/h, Ht-24. Biochemical blood test: bil.-12.65 mmol /l, straight-4.27 mmol /l, ALT-0.46 mmol /l, AST-0.16 mmol /l, tim.pr.-2, urinary.-4.66 mmol /l, rest. azot-17 g / l, creat.-82.9  $\mu\text{mol} / \text{l}$ , total protein-60.5 g / l. Chest X-ray: no focal opacities were detected. Ultrasound: diffuse enlargement of the thyroid gland with dimensions of 117 × 148 mm of the tissue structure (Fig. 12). MSCT of the neck: diffuse enlargement of the thyroid gland in the projection of the anterior region of the neck with dimensions of 112 × 146 mm (Fig. 13). The cytological conclusion corresponds to small follicles lined with low columnar epithelium, without proliferative changes in the thyroid tissue.*

*With a clinical diagnosis: " Diffuse toxic goiter of the 5th degree. Thyrotoxicosis II degree » the patient was prescribed drug therapy in order to prepare the patient for surgery. When re-examined two months later, the patient's thyrostatic status decreased to the euthyroid state.*





**Figure 12. Ultrasound of the thyroid gland of patient D., 23 years old.**



**Figure 13. MSCT of the neck of patient D., 23 years old.**

*02/14/2019 with a diagnosis of "Diffuse-toxic goiter of the 5th degree. Thyrotoxicosis removed with medication to euthyroidism "produced" Subtotal, subfascial strumectomy." intraoperatively an express biopsy of the resulting thyroid tissue was performed, which revealed an overgrowth of connective tissue, without proliferation of thyroid tissue. The course of the postoperative period is smooth, wound healing by primary intention. The patient was discharged home in a satisfactory condition on February 19, 2019 under the supervision of an endocrinologist at the place of residence.*

## Conclusion

Improving the techniques for performing strumectomy with the proposed surgical instrument makes it possible to simplify the technique of performing the operation and determining the size and calculation of the volume of the thyroid residue, leveling the risk of intraoperative complications. Reduction of the time period for performing complex stages was achieved from  $15.8 \pm 0.9$  to  $6.7 \pm 0.5$  minutes ( $p < 0.001$ ) and, accordingly, the total operation time from  $92.7 \pm 4.8$  to  $63.4 \pm 3.6$  minutes ( $p < 0.001$ ).

## REFERENCES

1. Belokonev, V.I. Influence of operation technique on the immediate results of treatment of patients with toxic forms of goiter / V.I. Belokonev, A.A. Starostina // Surgeon. - 2018. - No. 1. - S. 42-47.
2. Zayniyev, A. F., Kurbaniyazov, Z. B., Davlatov, S. S., & Rakhmanov, K. E. (2021). Results of differentiated surgical treatment of benign origin thyroid nodules. Annals of the Romanian Society for Cell Biology, 25(4), 1962-1969. Retrieved from [www.scopus.com](http://www.scopus.com)

3. Ismailov, S.I. Quality of life of patients during therapy with thyroxine and a combination of thyroxine and triiodothyronine after total thyroidectomy due to Graves' disease / S.I. Ismailov, A.M. Akbutaev, A.A. Elov // International Journal of Endocrinology. - 2017. - T. 61, No. 5. -S. 52-55.
4. Bartalena, L. Management of hyperthyroidism due to Graves' disease: frequently asked questions and answers (if any) / L. Bartalena, L. Chiovato, P. Vitti // Journal of Endocrinological Investigation. - 2016. - Vol. 39. - P. 1105-1114.
5. Shin YW. et al. Diminished Quality of Life and Increased Brain Functional Connectivity. Patients with Hypothyroidism After Total Thyroidectomy // Thyroid. -2020. - Vol. 26, No. 5. - P. 641-649.
6. Schneider DF et al. Thyroidectomy as primary treatment optimizes body mass index in patients with hyperthyroidism // Ann Surg oncol. - 2021. - Vol. 21, No. 7. - P. 2303-2309.