



## Alopecia Areata Epidemiology and Clinical Features

Ahmed Mohamed Metwally Ahmed<sup>1</sup>, Sahar Mohamed Abd El Fattah Al Mokadem<sup>1</sup>, Abdullah Mohamed Essawy<sup>1</sup>, Amal Ahmed Zidan<sup>2</sup>

<sup>1</sup> Dermatology, Venereology and Andrology Department, Faculty of Medicine, Zagazig University, Egypt

<sup>2</sup> Clinical Pathology Department, Faculty of Medicine, Zagazig University, Egypt

Email: [metwallya755@gmail.com](mailto:metwallya755@gmail.com)

---

### Abstract

Alopecia areata (AA) is an autoimmune disorder characterized by non-scarring hair loss on the scalp or any hair-bearing surface. The clinical manifestations of AA vary from small well-defined patches of hair loss to the diffuse involvement of the scalp or the entire body. The majority of AA patients experience unpredictable episode of relapsing and remitting. In a number of patients, it can be persistent, especially when the hair loss is extensive. Alopecia areata is an autoimmune disease in which hair follicles in the growth phase (anagen) prematurely undergo transition to the non-proliferative involution (catagen) and resting (telogen) phases, leading to sudden hair shedding and inhibition of hair regrowth. Unlike cicatricial alopecia, the inflammatory process in alopecia areata does not lead to permanent destruction of the hair follicle. The clinical manifestations of Alopecia areata are characterized by sudden patchy hair loss. The affected skin appears normal without signs of inflammation or scarring. Although a number of AA patients may slightly feel itching or tingling before the hair shedding, the majority of AA patients are asymptomatic. The scalp skin is the most effected, while other hairy body areas could be involved, such as eyebrows, eyelashes, beard and pubic hair.

**Keywords:** Alopecia Areata

---

### Introduction

Alopecia areata (AA) is an autoimmune disorder characterized by non-scarring hair loss on the scalp or any hair-bearing surface. The clinical manifestations of AA vary from small well-defined patches of hair loss to the diffuse involvement of the scalp or the entire body. The majority of AA patients experience unpredictable episode of relapsing and remitting. In a number of patients, it can be persistent, especially when the hair loss is extensive. AA has a significant influence on patients' quality of life and may induce psychological disorders (e.g., anxiety and depression) (1)

### Epidemiology:

Alopecia areata affects 1-2% of the general population with an estimated lifetime risk of 1.7%. However, prevalence can vary between 0.1 and 6.9% depending on the population studied (2).

Whether there is a seasonal pattern for flares of alopecia areata is unclear. A retrospective study of approximately 450 children with alopecia areata suggested a predilection for disease flares during cold months of the year. Another study is necessary to confirm this finding (3).

### Etiopathology:

Alopecia areata is an autoimmune disease in which hair follicles in the growth phase (anagen) prematurely undergo transition to the non-proliferative involution (catagen) and resting (telogen) phases, leading to sudden hair shedding and inhibition of hair regrowth. Unlike cicatricial alopecia, the inflammatory process in alopecia areata does not lead to permanent destruction of the hair follicle (4)

The mechanisms leading to alopecia areata are not fully understood. Key events may include the loss of follicular immune privilege and the development of an associated T cell-mediated immune attack on cells within the hair bulb. Genetic susceptibility to alopecia areata also plays a role (5).

### **I. Genetic Factors:**

Genetic factors play important role in alopecia areata Studies on genetic epidemiology demonstrated an increased risk of AA in first-degree relatives. Estimated lifetime risks in siblings, parents, and offspring of AA patients were 7.1%, 7.8%, and 5.7%, respectively, while the estimated lifetime risk in the general population was 2%. Other studies found that the concordance rates of AA in identical twins were 42–55% in dizygotic twins and 0 - 10% in dizygotic twins (5).

### **II. Immunological Factors:**

Hair Follicle is an immune privileged (IP) site relatively preventing autoimmune responses against autoantigens expressed in the bulge throughout the hair cycle and in the bulb during the anagen phase is mainly achieved by downregulation of the expressions of major histocompatibility complex (MHC) class I molecules in anagen hair bulbs, which could sequester autoantigens from being presented to CD8 + T cells. In addition, secretion of local immunosuppressant molecules (“IP guardians”), such as transforming growth factor- $\beta$ 1 (TGF- $\beta$ 1), interleukin-10 (IL-10),  $\alpha$ -melanocyte- stimulating hormone ( $\alpha$ -MSH), indoleamine-2,3-dioxyge- nase (IDO), and vasoactive intestinal peptide (VIP) could contribute to the formation of a local immunoinhibitory milieu and preservation of the IP. It has been widely accepted that the collapse of the HF-IP is a major precondition for the development of AA. Increasing secretion of IFN- $\gamma$  in HF, upregulation of NKG2D ligands (e.g., MICA and ULBP3/6), MHC I and MHC II molecules, and chemokines (e.g., IL-15, IL-2, and CXCLs), as well as decreasing local “IP guardians” could increase exposure of anagen HF-associated autoantigens and loss of HF-IP (5).

#### **1- Cellular Immunity**

There is increasing evidence that AA is a tissue-specific autoimmune disease. The most characteristic histological feature of AA is lymphatic infiltration around and within the hair follicles. Loss of hair during active disease is coincidental with an infiltrate of activated CD4+ cells around the hair follicles, along with a CD8+ cells intrafollicular infiltrate. Due to the cytotoxic nature of most CD8+ T cells, their presence inside hair follicles could easily disrupt the growth of hair. Various molecules are produced by activated cytotoxic T lymphocytes in AA such as tumor necrosis factors, and granzymes, these molecules may trigger apoptosis in AA affected hair follicle cells and generally disrupt normal functioning (6).

#### **2-Humoral immunity:**

The presence of hair follicle specific autoantibodies in AA patients suggests that AA is an autoimmune disease. Hair follicle specific IgG antibody concentration is increased in the peripheral blood of AA patients and it can be found localized around the periphery of hair follicles, especially near the border of the active lesions. It was found that the antigens bound by some of these serum antibodies are keratin 16 and hair follicle specific trichohyalin. However, the specificity of hair follicle autoantibody targets can be very variable between AA affected individuals (7).

#### **3-Cytokines**

Within the cascade of pathogenesis of alopecia areata, cytokines and other molecules that coordinate cyclical hair growth play a crucial role. Interferon- $\gamma$  (IFN- $\gamma$ ) is the main cytokine known to be aberrantly expressed in alopecia areata through a CD4+ Th1 mediated response. It is produced by perifollicular or follicular antigen presenting cells and among several actions it also deprives dermal papilla cells of their ability to maintain anagen hair growth, as shown in human studies. It has been shown that serum levels of IFN- $\gamma$  are significantly higher in patients with alopecia totalis or alopecia universalis compared to controls, but no significant difference has been found in levels of IFN- $\gamma$  between patients with localized alopecia areata and those with more extensive forms (8).

### **III. Infections:**

Alopecia areata associated with many infectious foci as dental origin may be explained by the presence of common immune mediators (systemically circulating immune complexes and lymphocyte populations) in the pathogenesis of both dental infection and AA (9).

It has been suggested that infection with *helicobacter pylori* can be involved in various extra-digestive autoimmune disorders including sjögren's syndrome, autoimmune thyroiditis and AA (10).

#### IV. Oxidative Stress:

Oxidative stress may induce upregulation of NKG2D ligands, such as MICA and ULBP, leading to the disruption of IP and promotion of autoimmunity in AA patients (4)

Reduced activities of erythrocyte superoxide dismutase (SOD) and glutathione peroxidase (GSH-Px), as well as increased malondialdehyde (MDA) levels have been identified in blood cells and lesions of patients with AA(11)

Genetic studies have reported the involvement of an antioxidant enzyme PRDX5 in AA. More recently, a meta-analysis found that AA is associated with the increased oxidative stress (12)

#### Allergy:

The association between AA and atopic diseases, especially atopic dermatitis, has been reported (12)

Atopy increases the risk of developing AA. Eosinophils and mast cells were detected in lesions of AA patients. The increased serum IgE level in AA patients has been reported in several studies (12)

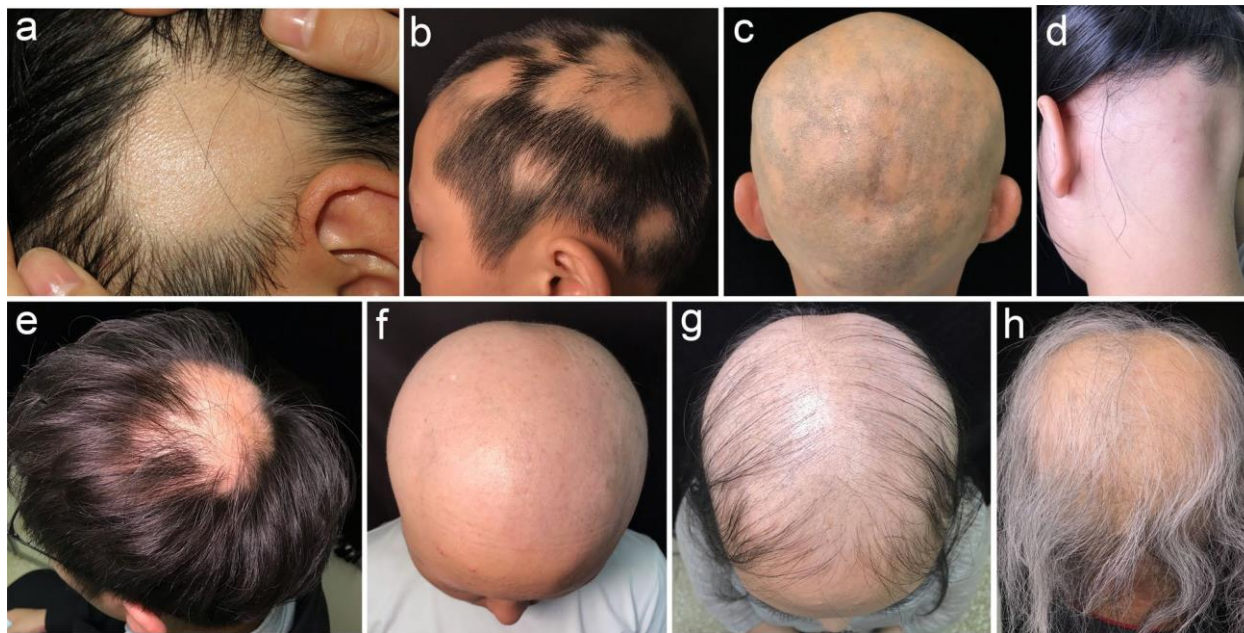#### Clinical Features:

- Hair loss:

The clinical manifestations of Alopecia areata are characterized by sudden patchy hair loss. The affected skin appears normal without signs of inflammation or scarring. Although a number of AA patients may slightly feel itching or tingling before the hair shedding, the majority of AA patients are asymptomatic. The scalp skin is the most affected, while other hairy body areas could be involved, such as eyebrows, eyelashes, beard and pubic hair (13).

Several subtypes of AA have been previously described, including the following:

1. Patchy alopecia: the most common type, single or multiple patches of hair loss, in which the patches could be separate or interconnect to form a reticulate pattern;
2. Alopecia totalis (AT): total or almost total loss of scalp hairs .
3. Alopecia universalis (AU): total or almost total loss of hair on all scalp hairs and body hairs;
4. Ophiasis: a symmetric band-like hair loss along the hair-line of the temporal, parietal, and occipital scalp, and it is typically refractory to treatments;
5. Saisiph: an extensive hair loss in the central scalp, while the periphery of the scalp is not significantly involved;
6. Acute diffuse and total alopecia (ADTA): an abrupt diffuse hair loss with a rapid progression to total hair loss, mostly in women's scalp, which is associated with a favorable prognosis and may spontaneously recover even without treatment;
7. Marie Antoinette and Thomas More syndrome: a sudden "overnight" whitening of the hair, as pigmented hairs are selectively attacked and white hairs are spared and remain on the scalp, which named Marie Antoinette syndrome in women and Thomas More syndrome in men (13)
8. Alopecia areata incognita (AAI): It is a diffuse hair thinning without typical patches, mimicking a very severe telogen effluvium in a patient with apparently normal hair density (14)



**Fig.( 1 )** Clinical manifestations of alopecia areata (AA). After permission of (14)

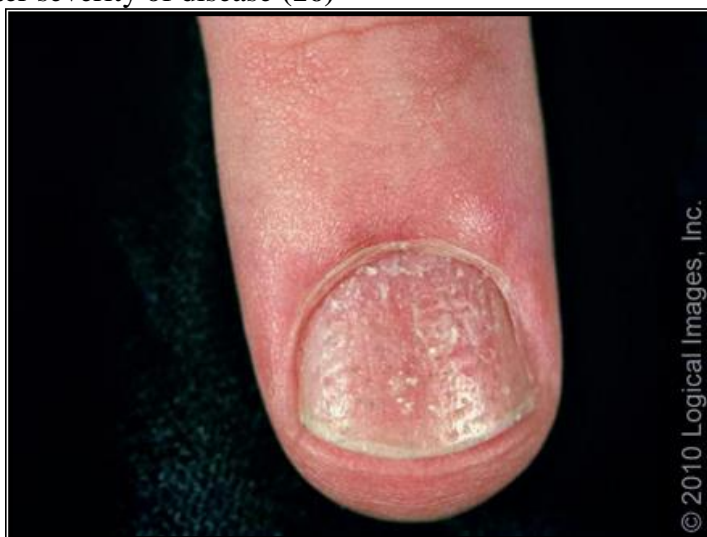### **Exclamation point hairs**

Exclamation point hairs, short broken hairs for which the proximal end of the hair is narrower than the distal end, are a common and pathognomonic finding in alopecia areata. Exclamation point hairs are typically found at the edges of expanding patches and can be extracted with minimal traction (13).

### **Nail abnormalities**

Nail involvement is estimated to occur in 10 to 20 % of patients with alopecia areata, with the potential for more frequent nail involvement in patients with severe disease. Nail disease may precede, follow, or coexist with active hair loss (15).

Pitting of the nail plate is most common; however, a variety of other disorders, including trachyonychia (roughening of the nail plate), onychorrhexis (longitudinal fissuring of the nail plate), red spotting on the lunulae, onycholysis (separation of the distal nail plate from the nail bed), and onychomadesis (detachment of the proximal nail plate from the nail bed), may also accompany alopecia areata. Nail involvement has been associated with greater severity of disease (16)



**Fig. (2):** Nail pitting; Numerous pits are present in this nail from a patient with alopecia areata. Reproduced with permission (16)

**Associated Abnormalities:**

Alopecia areata frequently occurs in association with other autoimmune disorders such as vitiligo, lichen planus, morphea, lichen sclerosus et atrophicus, pemphigus foliaceus, atopic dermatitis, Hashimoto's thyroiditis, hypothyroidism, endemic goiter, Addison's disease, pernicious anemia, lupus erythematosus, diabetes mellitus, and others (16).

**Thyroid autoimmunity** may be associated with AA, with an incidence between 8% and 28% of patients. The presence of thyroid autoantibodies has no clinical correlation with AA severity. Vitiligo may be another important association, with a 3% to 8% incidence in AA patients (17).

- ◆ **Ophthalmic abnormalities detected in patients with AA included:** punctuate opacities, cataract, increased intraocular tension and retinal changes in the form of degenerative changes, pigments clumping and abnormal vascular changes (18).

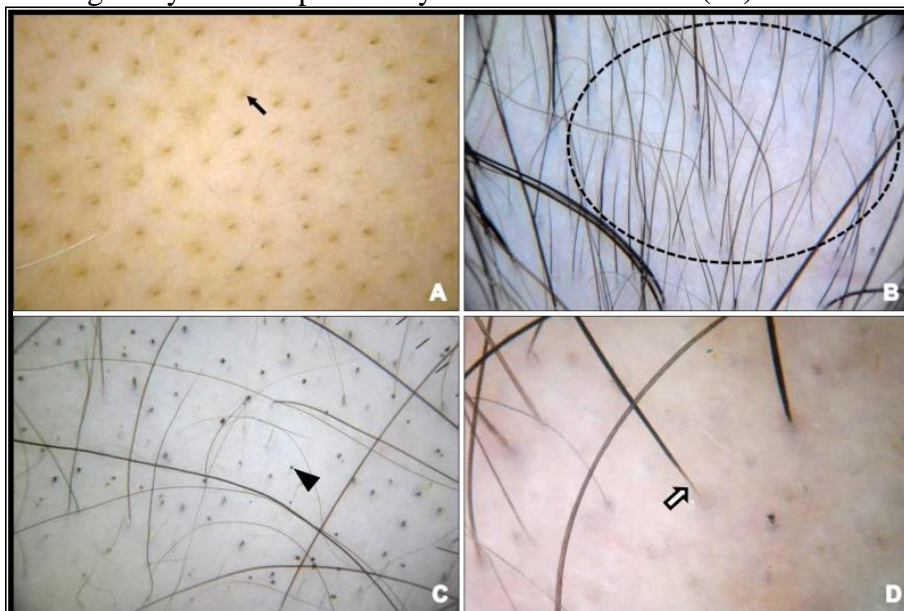
**Emotional stress and psychiatric disease:** Anxiety, personality disorders, depression, and paranoid disorders are seen with increased incidence varying from 17-22% of patients, and the lifetime prevalence of psychiatric disorders was estimated to be 74% in patients with AA. Psychiatric problems are seen in both children and adults. association has been made between the severity of the psychiatric disorder and that of AA (19).

**Diagnosis:**

The patient history and physical examination are usually sufficient for diagnosis. Clinical features that should raise suspicion for alopecia areata include smooth, discrete areas of rapid hair loss with absent or minimal erythema (19).

**Trichoscopy :**

The common trichoscopic features of AA include yellow dots, short vellus hairs, black dots, tapered hairs, broken hairs, exclamation mark hairs, upright regrowing hairs, and pig-tail hairs (19). Although the yellow dots and short vellus hairs are more sensitive, they are not specific for AA. Exclamation mark hairs, which are broken hairs that are thicker and darker at the distal end and thin and hypopigmented at the proximal end, are believed to be a pathognomonic indicator of AA. Dystrophic, broken hairs are indicative of active diseases, although they are not specifically associated with AA (18).



**Fig. (3):** Dermoscopic features of alopecia areata; yellow dots (A; arrow), clustered vellus hairs (B; dotted circle), black dots (C; triangle), and tapering hairs (D; white arrow). (17).

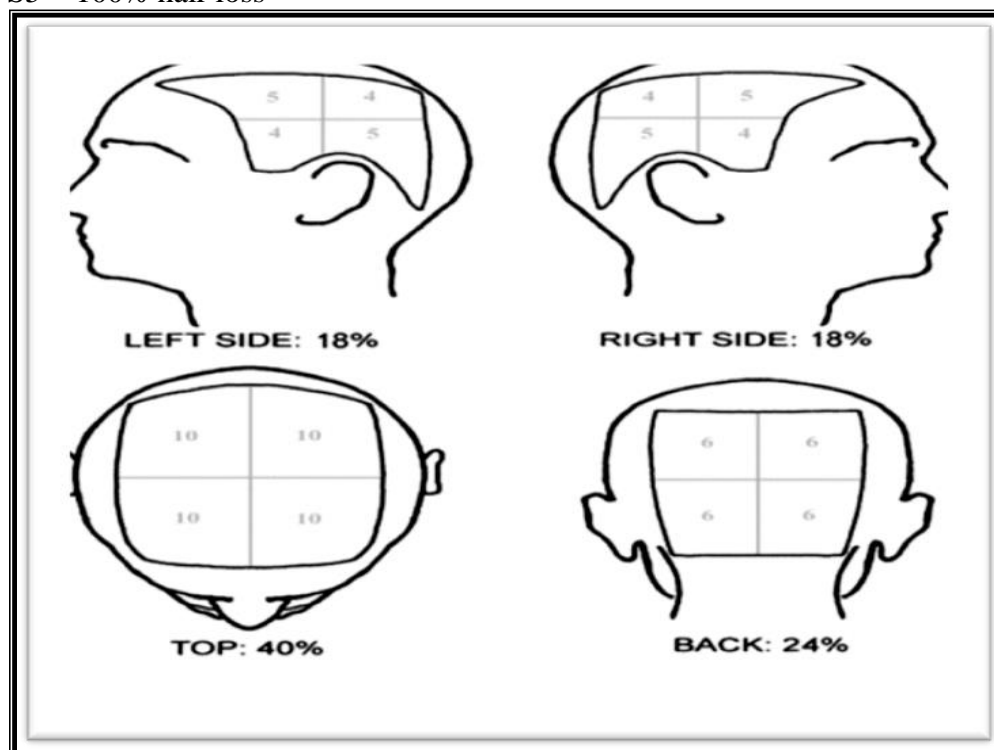
**Scoring of AA :**

National Alopecia Areata Foundation working committee has devised "Severity of Alopecia Tool score" (SALT score). Scalp is divided into 4 areas namely, Vertex - 40% (0.4) of scalp surface area; right profile of scalp - 18% (0.18) of scalp surface area; left profile of scalp - 18% (0.18) of scalp surface area; Posterior

aspect of scalp - 24% (0.24) of scalp surface area. Percentage of hair loss in any of these areas is percentage hair loss multiplied by percent surface area of the scalp in that area. SALT score is the sum of percentage of hair loss in all above-mentioned areas. For e.g., if the percentage hair loss in vertex, right profile, left profile and posterior aspect is 20, 30, 40 and 50% respectively; then, SALT score =  $(20 \times 0.4) + (30 \times 0.18) + (40 \times 0.18) + (50 \times 0.24) = 8 + 5.4 + 7.2 + 12 = 32.6$  (20).

**The extent of scalp hair loss was determined by Alopecia SALT score as follow:**

- S: Scalp hair loss
- S0 = no hair loss
- S1 = <25% hair loss.
- S2 = 25-49% hair loss.
- S3 = 50-74% hair loss.
- S4 = 75-99% hair loss.
- S4a = 75-95% hair loss.
- S4b = 96-99% hair loss.
- S5 = 100% hair loss



**Fig. (4): Alopecia Areata scoring system (20).**

#### **Scoring of the upper face:**

Each eyebrow: 15 multiplied by percentage involvement.

eyelashes: 10 multiplied by percentage involvement of each eye.

#### **Scoring of beard area:**

Beard of each cheek: 20 multiplied by percentage involvement.

Beard of each side of the neck: 25 multiplied by percentage involvement.

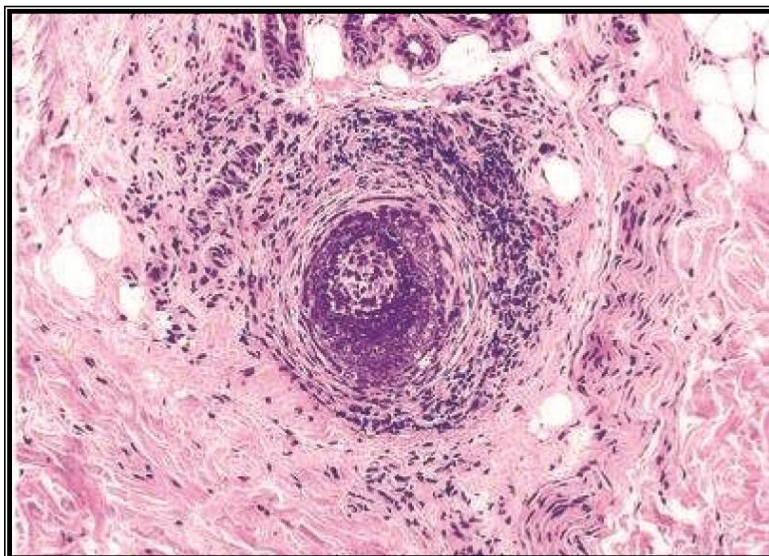
Moustache area: 10 multiplied by percentage involvement. (21)

#### ◆ **Histopathology:**

- ◆ The histopathologic features vary depending on the stage of the disease, classified as early active (acute and subacute) and chronic phases. The earliest and most important feature in the acute phase is the peribulbar lymphocytic infiltrate, which may also extend into the epithelium and hair matrix (22).

### ◆ Acute Stage:

In the acute stage, peribulbar lymphocytic infiltrate “swarm of bees” preferentially targets anagen stage follicles. The infiltrate is composed of both CD4+andCD8+cells with theCD4+/CD8+ ratio being higher in clinically active disease. As a consequence, edema, microvesiculation, apoptosis, necrosis, macrophages, and foreign body giant cells can be seen in and around the affected hair follicles. Anagen arrest, shortly followed by catagen, weakens the hair shaft and causes breakage at the surface of the skin. As the follicle goes into telogen, the fractured widened tip will further extrude, resulting in the typical exclamation point hair (17).



**Fig (5):** Sub-isthmic region: a hair bulb with peribulbar lymphoid cell infiltrate (‘swarm of bees’) (23)

### Subacute Stage:

In the subacute stage, large numbers of catagen hairs, followed by telogen hairs, can be observed. Some remnant inflammation may persist in or around fibrous streamers as the follicles ascend to telogen level. The percentage of catagen/telogen is markedly increased and often exceeds 50% of the total follicles (24).

### Chronic Stages:

In the chronic stages of AA, most affected hair follicles are forced into prolonged telogen and no attempt at reentering anagen or new growth of hair is observed. The number of terminal scalp hair follicles will decrease to about the same number of vellus hair follicles. At this point, any inflammation present will typically be localized in the papillary dermis around miniaturized hair follicles. From these observations, AA is circumstantially an inflammation driven disease where changes to the hair follicle are closely correlated with changes in the peri- and intrafollicular inflammatory infiltrate (7).

### Recovery Stage:

In the recovery stage, the terminal to vellus ratio change to normal ratio, the percentage of anagen hairs increases, and there is little or no inflammation. The total number of follicles are normal or decreased in AA compared to normal scalp (17).

### Differential Diagnosis:

Clinically, alopecia areata is characterized by sudden onset of patches of nonscarring hair loss, with ‘exclamation-point’ hairs. Other causes of nonscarring alopecias as (androgenic alopecia, telogen effluvium, trichotillomania, traction alopecia) should be kept in mind (23)

In children, we must exclude tinea capitis and trichotillomania.

Tinea capitis can be differentiated by the presence of inflammation or mild scaling.

Trichotillomania may involve irregular or bizarrely shaped lesions. The presence of broken hairs with varying lengths gives lesions a rough texture, unlike the smooth surface of AA (17).

The differentiation of diffuse AA from telogen effluvium (TE) can be challenging. The patient’s history may reveal a triggering factor that may point towards a diagnosis of TE. In diffuse AA, the hair pull test

may show some dystrophic anagen hairs compared to the pure telogen hairs found in TE. Ultimately, a scalp biopsy may be required to correctly differentiate diffuse AA and TE (17).

**Table (1): Differential diagnoses of alopecia areata: (23).**

<b>Tinea capitis</b>	Especially in children, should be differentiated by Signs of inflammation, scaling, and cervical lymphadenopathy are present in tinea capitis, in contrast to smooth, non-scaly surface of AA.
<b>Trichotillomania</b>	Presents with broken hair of varying lengths with wire brush feel compared to smooth hair loss of AA.
<b>Cicatricial alopecia</b>	Characterized by patchy hair loss with loss of follicular orifices. Erythema, scaling, pustulation, and plugging may occur based on the underlying cause.
<b>Androgenetic alopecia</b>	Gradual hair loss with patterned distribution. Diffuse AA may resemble androgenetic alopecia and telogen effluvium. The progression is rapid and widespread in diffuse AA. In doubtful cases, a scalp biopsy may be of help.
<b>Secondary syphilis</b>	Produces moth-eaten alopecia rather than smooth surface of AA.
<b>Congenital triangular alopecia</b>	Closely mimics AA. It is not congenital as the name suggests, appear usually after 2 years of age, rarely in adulthood also. Scalp biopsy is needed to identify, which shows normal number of hair follicles, but all are vellus or indeterminate.
<b>Side pins</b>	Which are used by women to keep the hair in place, may cause pressure alopecia, resembling AA.

## References

1. **Toussi A, Barton VR, Le ST, Agbai ON and Kiuru M (2020):** Psycho- social and psychiatric comorbidities and health-related quality of life in alopecia areata: a systematic review. *J Am Acad Dermatol*.
2. **Salinas-Santander M, Sánchez-Domínguez C, Cantú-Salinas C, Gonzalez-Cárdenas H, Cepeda-Nieto AC, Cerda-Flores RM and Ocampo-Candiani J (2015):** Association between PTPN22 C1858T polymorphism and alopecia areata risk. *Experimental and Therapeutic Medicine*; 10 (5): 1953-1958.
3. **Putterman E, Castelo-Soccio L, Senna M, et al. (2018):** Seasonal patterns in alopecia areata, totalis, and universalis. *JAAD*; 15 (79): 970-974.
4. **Rajabi F, Drake LA, Senna MM, et al. (2018):** Alopecia areata: a review of disease pathogenesis. *Br J Dermatol*; 4 (179): 1031-1033.
5. **Bertolini M, McElwee K, Gilhar A, Bulfone-Paus S and Paus R (2020):** Hair follicle immune privilege and its collapse in alopecia areata. *Exp Dermatol*; 29(8):703-725.
6. **Gilhar A and Kalish RS (2006):** Alopecia areata a tissue specific autoimmune disease of the hair follicle. *Autoimmun Rev*; 5(1): 64-69.
7. **Wang E and McElwee KJ (2011):** Etiopathogenesis of alopecia areata: Why do our patients get it? *Dermatol Ther*; 24(3): 337-347.
8. **Gregoriou S, Papafragkaki D, Kontochristopoulos G, et al., (2010):** Cytokines and other mediators in alopecia areata. *Mediators Inflamm*; Article ID 928030.
9. **Lipoff J (2016):** Alopecia. In *Dermatology Simplified* (pp. 237-247). Springer, Cham.
10. **Campuzano-Maya G (2017):** Alopecia areata y *Helicobacter pylori*: una nueva asociación. *Medicina y Laboratorio*; 23(3-4), 149-158.
11. **Yenin JZ, Serarslan G, Yonden Z and Ulutas KT (2015):** Investigation of oxidative stress in patients with alopecia areata and its relationship with disease severity, duration, recurrence and pattern. *Clin Exp Dermatol*; 40(6): 617-621.
12. **Acharya P and Mathur MC (2020):** Oxidative stress in alopecia areata: a systematic review and meta-



- analysis. *Int J Dermatol*; 59(4):434–440.
13. **Strazzulla LC, Wang EHC, Avila L, Lo Sicco K, Brinster N, Christiano AM and Shapiro J (2018):** Alopecia areata disease characteristics, clinical evaluation, and new perspectives on pathogenesis. *J Am Acad Dermatol*; 78(1):1–12.
  14. **Rebora A (2011):** Alopecia areata incognita. *J Am Acad Dermatol*; 65(6):1228.
  15. **Wyrwich KW, Kitchen H, Knight S, et al. (2020):** Development of clinician-reported outcome (ClinRO) and patient-reported outcome (PRO) measures for eyebrow, eyelash and nail assessment in alopecia areata. *AJCD*; 21 (5): 725-732.
  16. **Kasumagic-Halilovic E and Prohic A (2017):** Nail changes in alopecia areata: frequency and clinical presentation. *JEADV*; 23 (2): 240-241..
  17. **Alkhalifah A (2011):** Topical and intralesional therapies for alopecia areata. *Dermatol Ther*; 24(3): 355-63.
  18. **Fierro-Arias L, la Fuente-García D, Cortés-Rodrigo MD, Baños-Segura C and Ponce-Olivera RM (2016):** Ocular alterations in patients with alopecia areata. *Dermatología Revista Mexicana*; 60(3): 203-209.
  19. **Brajac I, Tkalčić M, Dragojević DM, et al. (2003):** Role of stress, stress perception and trait-anxiety in the onset and course of alopecia areata. *J Dermatol*; 30 (12): 871-8.
  20. **Bhat YJ, Manzoor S, Khan AR, et al. (2009):** Trace element levels in alopecia areata. *Indian J Dermatol Venereol Leprol*; 75 (1): 29–31.
  21. **Imran Majid, Farah Sameem, Javeed Sultan, Smia Aleem (2021):** Alopecia areata severity index (AASI): A reliable scoring system to assess the severity of alopecia areata of face and scalp 2021 ;2565-2570.
  22. **Chaitra V, Rajalakshmi T and Kavdia R (2010):** Histopathologic Profile of Alopecia Areata in Indian Patients. *Int J Trichology*; 2(1): 14-7.
  23. **Stefanato CM (2010):** Histopathology of alopecia: a clinicopathological approach to diagnosis. *Histopathology*; 56: 24-38.
  24. **Whiting DA (2003):** Histopathologic features of alopecia areata: a new look. *Arch. Dermatol*; 139: 1555–1559.