



## Surgical Options of Management of Rectal Cancer

Mohamed Elsayed Elsayed Mohamed, Wael Elsayed Loffy Mokhtar, Taha Abdel-wahab Bayoumi Mohamed, Hassan Rabiaa Galal Ashour

Department of General Surgery and Oncosurgery, Zagazig University, Egypt.

Email: [bigboss3032015@gmail.com](mailto:bigboss3032015@gmail.com), [meelsayed@medicine.zu.edu.eg](mailto:meelsayed@medicine.zu.edu.eg)

**Article History:** Received 10<sup>th</sup> June, Accepted 5<sup>th</sup> July, published online 10<sup>th</sup> July 2023

### Abstract

**Background:** Colorectal cancer is a major malignant disease of the gastrointestinal tract, which is the third most common cancer and the second leading cause of death from cancer worldwide. The global burden of colorectal cancer is expected to increase by 60% to more than 2.2 million new cases and 1.1 million deaths by 2030. A multidisciplinary approach that includes surgery, medical oncology, and radiation oncology is required for optimal treatment of patients with rectal cancer. The local transanal excision of rectal cancer is reserved for early-stage cancers in a select group of patients. The lesions amenable for local excision are small (< 3cm in size), occupying less than a third of a circumference of the rectum, preferably exophytic/polypoid, superficial and mobile (T1 and T2 lesions), low-grade tumors (well or moderately differentiated) that are located in low in the rectum (within 8 cm of the anal verge). There should also be no palpable or radiologic evidence of enlarged mesenteric lymph nodes. The likelihood of lymph node involvement in this type of lesion ranges from 0-12%. The choice of a low anterior resection (LAR) with colorectal stapled anastomosis, ultralow coloanal anastomosis, or abdominoperineal resection (APR) depends on tumor height, the extent of its local invasion, and the surgeon's skills. Decision-making regarding those procedures takes place during multimodal treatment, or even at the time of the surgery. APR is performed in patients with lower-third rectal cancers. APR should be performed in patients in whom negative margin resection. The term total mesorectal excision (TME) was first introduced in a report by Heald in 1982. He described the "holy plane," an avascular interface between the mesorectal fascia and the parietal dorsolateral pelvic fascia. He also stated that the rectum and mesorectum are an embryologically distinct lymphovascular entity. In TME surgery, dissection is along this "holy plane" through sharp dissection, in contrast to the more conventional blunt approach. Heald reported local recurrence rates well below 10% and survival rates of up to 87%. TME is the gold standard for the surgical treatment of rectal cancer involving the middle and lower third of the rectum. For the upper third of the rectum, TME is not considered obligatory (removal of the mesorectum to the level of the levator muscles); rather a more conservative resection called tumor-specific TME is preferred (removal of the mesorectum 5cm distal of the tumor).

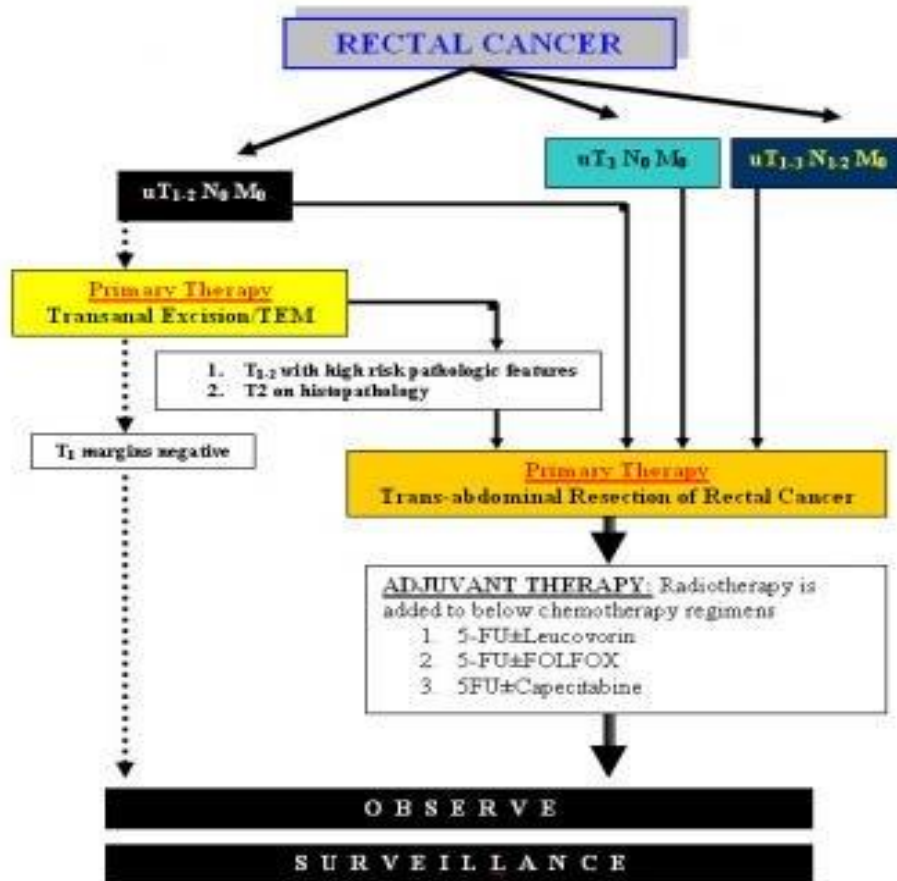
**Keywords:** Management, Rectal Cancer

**DOI:** 10.53555/ecb/2023.12.Si12.322

Colorectal cancer is a major malignant disease of the gastrointestinal tract, which is the third most common cancer and the second leading cause of death from cancer worldwide. The global burden of colorectal cancer is expected to increase by 60% to more than 2.2 million new cases and 1.1 million deaths by 2030 (1).

There are many risk factors associated with the incidence of CRC. Some non-modifiable factors include genetic factors, ethnicity, age, gender, body height, and family history of CRC (2).

A multidisciplinary approach that includes surgery, medical oncology, and radiation oncology is required for optimal treatment of patients with rectal cancer (3).



**Fig. (1):** Approach to rectal cancer (3).

#### ► Adjuvant and Neoadjuvant Therapy:

Neoadjuvant long-course radiation therapy (RT) plus radiation sensitization with a fluoropyrimidine (eg, capecitabine, fluorouracil), followed by a treatment break of approximately 8 weeks before surgical excision and concluding with adjuvant chemotherapy, has been a standard of care in rectal cancer. Other options for neoadjuvant treatment include short-course RT, chemotherapy (eg, with FOLFOX or CAPOX) alone, or short-course RT followed by chemotherapy (4).

The randomized RAPIDO trial found that at 3 year–follow up, patients receiving short-course RT (5x5Gy), then chemotherapy with CAPOX or FOLFOX4 followed by total mesorectal excision (TME) had a disease-related treatment failure rate of 23.7%, compared with 30.4% in patients who received neoadjuvant capecitabine-based chemoradiotherapy followed by TME and optional adjuvant chemotherapy (5).

In Europe, the short course of radiation (25Gy) only, followed by extirpative surgery (low anterior resection or abdominal perineal resection), is the most common approach. In the United States, stage II or higher rectal cancers are more commonly treated with preoperative long course CRT consisting of 4500 to 5040 cGy of radiation in conjunction with infusional 5-FUbased chemotherapy or oral capecitabine. The radiation is delivered during a period of 5 to 6 weeks, and surgery (low anterior resection or abdominal perineal resection, laparoscopic or open) is done 6 to 10 weeks after completion of the radiation therapy. A diverting stoma (ileostomy) is usually fashioned to protect the anastomosis, and the stoma is then closed 10 weeks later, when studies show satisfactory healing of the anastomosis (6).

For locally advanced rectal cancer, a newer standard of care is total neoadjuvant therapy (TNT), which consists of induction chemotherapy (eg, with CAPOX or mFOLFOX6) followed by chemoradiation therapy

and then TME. In a retrospective cohort analysis of patients with locally advanced (T3/4 or node-positive) rectal cancer, the cohort that received TNT ( $n = 308$ ) had higher rates of complete response and were more likely to have temporary ileostomy reversed within 15 weeks of proctectomy, compared with the cohort that received the standard regimen of neoadjuvant chemoradiation therapy, surgery, and planned adjuvant chemotherapy ( $n = 320$ ) (7).

Patients with locally advanced rectal cancer (T3-4, N0, M0 or any T, N1-2, M0) should receive primary chemotherapy and radiotherapy. The combination of preoperative radiation therapy and chemotherapy with fluorouracil improves local control, distant spread, and survival. The basis of this improvement is believed to be the activity of fluorouracil as a radiosensitizer. Surgical resection can be done 4 to 10 weeks after completion of chemotherapy and radiotherapy (8).

A meta-analysis of neoadjuvant long-course chemoradiotherapy followed by total mesorectal excision for locally advanced rectal cancer concluded that waiting for a minimum of 8 weeks from the end of chemoradiotherapy to surgical excision increases pathological complete response (pCR) and downstaging rates, and improves recurrence-free survival without compromising surgical morbidity. With longer intervals, the odds ratio (OR) for pCR was 1.41 (95% confidence interval [CI] 1.30-1.52;  $P < 0.001$ ) and the OR for tumor downstaging was 1.18 (95% CI 1.05-1.32;  $P = 0.004$ ). The increased rate of pCR translated to reduced distant metastasis and overall recurrence but not local recurrence (8).

#### **A) Transanal Excision:**

The local transanal excision of rectal cancer is reserved for early-stage cancers in a select group of patients. The lesions amenable for local excision are small ( $< 3$ cm in size), occupying less than a third of a circumference of the rectum, preferably exophytic/polypoid, superficial and mobile (T1 and T2 lesions), low-grade tumors (well or moderately differentiated) that are located in low in the rectum (within 8 cm of the anal verge). There should also be no palpable or radiologic evidence of enlarged mesenteric lymph nodes. The likelihood of lymph node involvement in this type of lesion ranges from 0-12% (4).

#### **B) Endocavitary Radiation:**

This radiotherapy method differs from external-beam radiation therapy in that a larger dose of radiation can be delivered to a smaller area over a shorter period. Selection criteria for this procedure are similar to those for transanal excision. The lesion can be as far as 10 cm from the anal verge and no larger than 3cm. Endocavitary radiation is delivered via a special proctoscope and is performed in an operating room with sedation. The patient can be discharged on the same day (9).

#### **► Carcinologic principles of rectal surgery:**

##### **- Radical Surgery:**

The choice of a low anterior resection (LAR) with colorectal stapled anastomosis, ultralow coloanal anastomosis, or abdominoperineal resection (APR) depends on tumor height, the extent of its local invasion, and the surgeon's skills. Decision-making regarding those procedures takes place during multimodal treatment, or even at the time of the surgery (10).

Modern oncologic surgery concepts aim to achieve more than just curative resection of the rectal tumor mass. The quality of life of patients with rectal cancer has become a factor in primary treatment and has been equally assessed along with surgical outcomes (11).

Increasing consideration for quality of life in rectal cancer treatment, technical advances in surgery, and multimodal treatments with NCRT have recently led to the common application of sphincter preservation techniques (12).

APR is therefore considered only when sphincter-preserving anterior resection is not feasible. Furthermore, recent reports have indicated that APR may be associated with local recurrence and inferior oncologic outcomes (10). However, the indications for APR among extraperitoneal rectal cancer patients remain high, ranging from 12 to 47% (13).

However, in the present study, the patients that underwent LAR or APR had similar T and N stages, but the outcomes still favored LAR surgery over APR. LAR with TME was previously demonstrated as safe for distal margin resection, allowing the sphincter to be spared, while achieving oncologic results similar to those of APR in terms of local recurrence and survival (10).

### **C) Low anterior resection (LAR):**

LAR is generally performed for lesions in the middle and upper third of the rectum and, occasionally, for lesions in the lower third. Because this is a major operation, patients who undergo LAR should be in good health. They should not have any preexisting sphincter problems or evidence of extensive local disease in the pelvis (9).

The operation entails full mobilization of the rectum, sigmoid colon, and, usually, the splenic flexure. Mobilization of the rectum requires a technique called total mesorectal excision (TME). TME involves sharp dissection in the avascular plane that is created by the envelope that separates the entire mesorectum from the surrounding structures. This includes the anterior peritoneal reflection and Denonvilliers fascia anteriorly and preserves the inferior hypogastric plexus posteriorly and laterally. TME is performed under direct visualization. Mesorectal spread can occur by direct tumor spread, tumor extension into lymph nodes, or perineural invasion of tumor (14).

TME yields a lower local recurrence rate (4%) than transanal excision (20%), but it is associated with a higher rate of anastomotic leak (11%). For this reason, TME may not be necessary for lesions in the upper third of the rectum. The distal resection margin varies depending on the site of the lesion. A 2-cm margin distal to the lesion must be achieved. For the tumors of the distal rectum, less than 5 cm from the anal verge, the minimally accepted distal margin is 1cm in the fresh specimen. Distal intra-mural spread beyond 1 cm occurs rarely. Distal spread beyond 1cm is associated with aggressive tumor behavior or advanced tumor stage (15).

According to a study by *Maurer et al.*, the introduction of TME has resulted in an impressive reduction of local recurrence rate. TME appears to have improved survival in patients without systemic disease (16). The anastomotic leak rate with this technique ranges from 3-11% for middle-third and upper-third anastomosis and to 20% for lower-third anastomosis. For this reason, some surgeons choose to protect the lower-third anastomosis by creating a temporary diverting stoma. This is especially important when patients have received preoperative radiation therapy. The rate of stenosis is approximately 5-20%. A hand-sewn anastomosis may be performed; if preferred, the anastomosis is performed as a single-layer technique. The leak and stenosis rates are the same (9).

In R0 resection, the inferior mesenteric artery (IMA) should be excised at its origin, but this rule is not mandated by available supportive evidence. Patients with non-en-bloc resection, positive radial margins, positive proximal and distal margin, residual lymph node disease, and incomplete preoperative and intra-operative staging would not be considered to have complete resection of cancer (R0 resection). Patients with R1 and R2 resection are considered to have an incomplete resection for cure. Incomplete R1 and R2 resection does not change the TNM stage but affects the curability (15).

### **D) Colo-anal anastomosis (CAA):**

Very distal rectal cancers that are located just above the sphincter occasionally can be resected without the need for a permanent colostomy. The procedure is as already described; however, the pelvic dissection is

carried down to below the level of the levator ani muscles from within the abdomen. A straight-tube coloanal anastomosis (CAA) can be performed using the double-stapled technique, or a hand-sewn anastomosis can be performed transanally.

The functional results of this procedure have been poor in some patients, who experience increased frequency and urgency of bowel movements, as well as some incontinence to flatus and stool. An alternative to the straight-tube CAA is creation of a colonic J pouch. The advantages of the J pouch include decreased frequency and urgency of bowel movements because of the increased capacity of the pouch. A temporary diverting stoma is performed routinely with any coloanal anastomosis. (14).

Fluorescence imaging with indocyanine green (ICG) has been increasingly considered a potential intraoperative tool that could be used in routine practice to ensure adequate perfusion at the time of anastomosis formation. It allows surgeons to visualize bowel microperfusion in real time, being fast and easy to perform. Recent literature shows the potential benefit of fluorescence imaging with ICG in lowering anastomotic leak (AL) rates by changing the surgical plan. Moreover, it has already been proven to be safe and feasible in colorectal surgery. However, further research is needed to validate its efficacy in reducing the AL rate (17).

### **E) Abdominal perineal resection (APR):**

APR is performed in patients with lower-third rectal cancers. APR should be performed in patients in whom negative margin resection will result in loss of anal sphincter function. This includes patients with involvement of the sphincters, preexisting significant sphincter dysfunction, or pelvic fixation, and sometimes is a matter of patient preference.

**Table (1):** Acceptable Minimal Distal and Proximal Resectional Margins for Rectal Cancer (18).

Resection Margins	Proximal Resection Margin	Distal Resection Margin
Ideal Margins	5 cm or more	2 cm or more
Minimally acceptable margins	5 cm or more	0.5-1 cm

A 2-team approach is often used, with the patient in modified lithotomy position. The abdominal team mobilizes the colon and rectum, transects the colon proximally, and creates an end-sigmoid colostomy. The perineal team begins by closing the anus with a purse-string suture and making a generous elliptical incision. The incision is carried through the fat using electrocautery. The inferior rectal vessels are ligated and the anococcygeal ligament is divided. The dissection plane continues posteriorly, anterior to the coccyx to the level of the levator ani muscles (18).

In patients who have rectal cancer with adjacent organ invasion, en bloc resection should be performed in order to not compromise cure. This situation is encountered in 15% of rectal cancer patients. The urinary bladder is the organ most commonly involved in locally advanced rectal carcinoma. Extended, en bloc resection may involve partial or complete cystectomy. In women, rectal carcinoma also commonly invades the uterus, adnexa, and posterior vaginal wall.

Treatment of colorectal cancer with liver metastasis. Chemotherapeutic regimens for liver metastasis including systemic and intrahepatic administration have only had limited benefit. Systemic chemotherapy

had 18-28% response rates. However, one meta-analysis found that carefully selected patients with metastatic colorectal cancer may benefit from preoperative chemotherapy with curative intent (19).

It is well accepted that liver resections in selected patients are beneficial. Overall, 5-year survival rates following surgical resection of liver metastasis vary from 20-40%. It was found that among patients undergoing hepatic resection for colorectal metastasis, a negative margin of 1 cm or more had a survival advantage (20).

### **F) Sphincter-Sparing Procedures:**

Procedures are described that use the traditional open technique. All of these procedures, except the perineal portions, can also be performed using laparoscopic techniques, with excellent results. Laparoscopic surgery offers the advantages of faster recovery time and less pain, compared with open surgery.

It was found that laparoscopic and open surgery for middle and lower rectal cancer are associated with similar long-term outcomes. The study shows the value of technical experience when performing laparoscopic surgery and encourages the use of this surgery by experienced teams. Long-term results from the UK Medical Research Council trial of laparoscopically assisted versus open surgery for colorectal cancer showed no differences between groups in overall or disease-free survival or recurrence rates (21).

In an international randomized, open-label trial (COlorectal cancer, Laparoscopic or Open Resection II [COLOR II]) involving 1044 patients with localized solitary rectal cancer located within 15 cm from the anal verge, comparison of the locoregional recurrence rate at 3 years showed no significant differences between the laparoscopic and open-surgery groups (5% in both). Disease-free-survival (74.8% and 70.8%, respectively), overall survival (86.7% and 83.6%), and rate of complications also showed no significant differences (22).

### **► Biologic therapy**

Pembrolizumab, which is a monoclonal antibody to programmed cell death-1 protein (PD-1) gained accelerated approval from the FDA in May 2017 for unresectable or metastatic colorectal cancer that has tested positive for microsatellite instability-high (MSI-H) or deficient mismatch repair (dMMR), and has progressed following treatment with a fluoropyrimidine, oxaliplatin, and irinotecan. In June 2020, the FDA extended the indications for pembrolizumab to include first-line treatment of patients with unresectable or metastatic MSI-H or dMMR colorectal cancer (15).

### **► Prevention**

As of October 2016, the only HPV vaccine available in the United States is Gardasil 9 (Merck, Whitehouse Station, NJ). It provides coverage of coverage of HPV types 6, 11, 16, 18, 31, 33, 45, 52, and 58. Gardasil 9 is approved for prevention of HPV-associated anal cancer and genital warts (condyloma acuminata) in males and females 9 to 26 years of age (23).

### **► Long-Term Monitoring**

US Multi-Society Task Force on Colorectal Cancer guidelines recommend local surveillance with flexible sigmoidoscopy or endoscopic ultrasound (EUS) every 3–6 months for the first 2–3 y after surgery in patients at increased risk for local recurrence. This includes the following:

- Patients with localized rectal cancer who have undergone surgery without total mesorectal excision
- Patients who have undergone transanal local excision (ie, transanal excision or transanal endoscopic microsurgery) or endoscopic submucosal dissection

- Patients with locally advanced rectal cancer who did not receive neoadjuvant chemoradiation and then surgery using total mesorectal excision techniques.

The task force also advises that all patients who have undergone curative resection of rectal cancer should receive their first surveillance colonoscopy 1 y after surgery (or 1 y after clearing perioperative colonoscopy) (23).

The National Comprehensive Cancer Network recommends the following surveillance measures:

- History and physical examination every 3–6mo for 2 y, then every 6mo for a total of 5y
- Carcinoembryonic antigen (CEA) assays every 3–6 mo for 2y, then every 6mo for a total of 5y for T2 or greater lesions.
- Chest/abdominal/pelvic CT: every 6–12mo for a total of 5y for stage II and III; every 3–6mo for 2 y, then every 6–12mo for a total of 5y for stage IV
- Colonoscopy in 1y; if no preoperative colonoscopy was performed, due to obstructing lesion, colonoscopy in 3–6mo; if advanced adenoma is found, repeat in 1y; if no advanced adenoma, repeat in 3y, then every 5y.
- Proctoscopy (with EUS or MRI) every 3–6mo for the first 2y, then every 6mo for a total of 5y (for patients treated with transanal excision only)
- PET-CT scan is not routinely recommended (4).

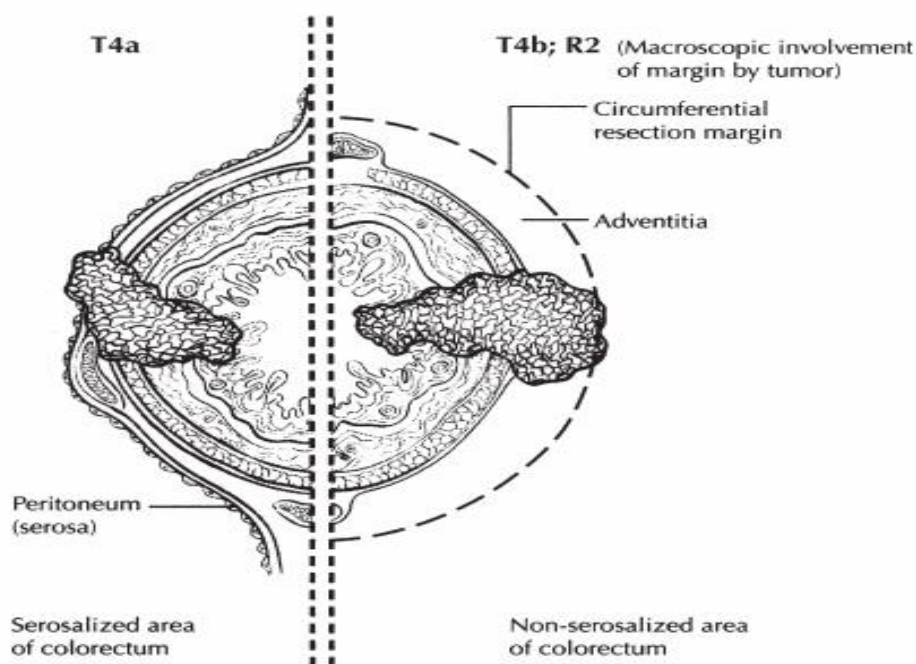
#### **A circumferential resection margin (CRM):**

The CRM was measured by the pathologist during histopathological examination, and was defined as the minimal margin between the tumour, extramural vascular invasion, tumour deposits or positive lymph nodes and the resection plane. A resection was described as macroscopically non-radical at the surgeon's discretion, where visible tumour tissue was left behind during surgery. LR was defined as local extraperitoneal tumour recurrence, tumour growth in local lymph nodes, intraluminal tumour recurrence or peritoneal tumour growth below the promontory occurring more than 90 days after the index operation (24).

The CRM was defined as histopathologically positive if the tumor was less than or equal to 1 mm from the inked non-peritonealized surface, and negative if greater than 1 mm. Resection margins were evaluated by the protocols of the College of American Pathologists (25).

Finally, the unopened segment of the fixed specimen will be transversely sliced into thin sections (3–5mm). All the cross-sectional rings should be laid out to assess the mesorectal quality and macro-CRM further. These thin sections will also lay the foundation for the subsequent microscopic examination. Photographic documents are necessary, especially in cases of a poor TME or positive macro-CRM. After the macroscopic assessment, the slices showing the closest relationship of tumor or a positive node to the circumferential margin should be further made into microscopic slices to examine the pCRM (26).

It's believed that if the distance between the tumor and resection margin under visual inspection was over 1 cm as per the macroscopic pathological assessment, MAME would be enough to support the judgement of a negative pCRM. In sum, both the whole specimen (fresh) and cross-sectional slices (after fixing) should be examined for an adequate assessment (26).



**Fig. (2):** Circumferential resection margin (27).

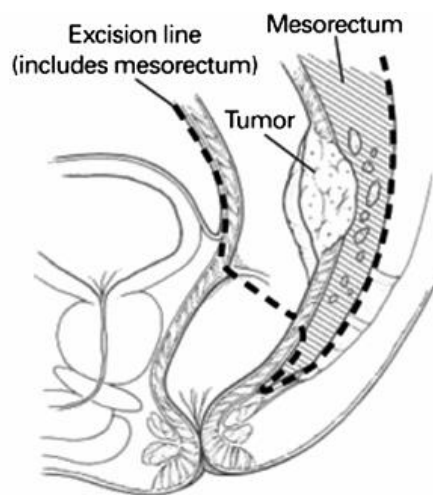
The term total mesorectal excision (TME) was first introduced in a report by *Heald* in 1982. He described the “holy plane,” an avascular interface between the mesorectal fascia and the parietal dorsolateral pelvic fascia. He also stated that the rectum and mesorectum are an embryologically distinct lymphovascular entity. In TME surgery, dissection is along this “holy plane” through sharp dissection, in contrast to the more conventional blunt approach. *Heald* reported local recurrence rates well below 10% and survival rates of up to 87% (28).

TME is based on the concept that cancer spread will stay confined within the embryologic mesorectal envelope at least during the early stages of the disease. Straying into the mesorectal envelope during rectal surgery is a major cause of residual disease and LR. Straying outward may damage the autonomic nerves and is a major factor for sexual and urinary disturbances (29).

TME is the gold standard for the surgical treatment of rectal cancer involving the middle and lower third of the rectum. For the upper third of the rectum, TME is not considered obligatory (removal of the mesorectum to the level of the levator muscles); rather a more conservative resection called tumor-specific TME is preferred (removal of the mesorectum 5cm distal of the tumor) (29).

The technique of TME requires precise, sharp dissection under direct vision in the plane of areolar tissue between the fascia propria of the rectum and the parietal endopelvic fascia extending down to the levator muscles of the pelvic floor. It allows for a characteristic bilobed specimen with complete extirpation of the surrounding perirectal lymph nodes along with visualized avoidance of the autonomic plexus innervating the pelvis. This technique also improves the ability to obtain an adequate circumferential margin. Sharp, adequate mesorectal excision extending to the endopelvic fascia achieves negative circumferential margins in up to 93% of cases (30).





**Fig. (3):** Total mesorectal excision: Dissection planes are shown by the dashed lines (31).

*García-Granero et al.* suggested that the TME quality could be assessed in terms of two aspects: (1) involvement of the circumferential resection margin (CRM) and (2) integrity of the TME specimen (32).

Although the importance of CRM involvement on the prognosis requires no more emphasis, it is very easy for CRM to be affected by the depth of tumor invasion or tumor-node-metastasis (TNM) stage when used for reflecting the surgical quality (33).

Furthermore, if the integrity of the mesorectum cannot be guaranteed even if the CRM was negative for tumor cells, there still may be some micro tumor deposits or positive lymph nodes in the residual mesorectum, which might increase the risk of cancer recurrence. Numerous studies have confirmed the correlation between the prognosis of patients with tumors and the integrity of mesorectal specimens evaluated macroscopically (34).

Therefore, some researchers put forward the “macroscopic assessment of mesorectal excision (MAME)” as a suitable assessment tool for the integrity of mesorectum, which could reflect the quality of TME (32).

*Nagtegaal et al.* found that in the subgroup of patients with a negative resection margin, patients with incomplete mesorectum resection had a higher overall recurrence rate (ORR) than those with complete mesorectum resection (28.6% vs. 14.9%,  $P = 0.03$ ); further, the overall survival (OS) rate was lower in the group of patients with incomplete mesorectum resection (76.9% vs. 90.5%,  $P < 0.05$ ) (33).

*Quirke et al.* also conducted an analysis on a subgroup of patients with negative CRMs and found that the LRR remarkably increased in the group of patients with incomplete mesorectum compared with that in the group of patients with complete mesorectum resection (12% vs. 4%) (35).

Therefore, the integrity of the mesorectal specimen can be regarded as an independent prognostic factor for patients who received rectal cancer resection. Moreover, MAME is not affected by the T stage, N stage, TNM stage, or Dukes stage, making MAME a better tool than the CRM for TME quality assessment (36).

### ► Relevant definitions

#### a) MAME (macroscopic Assessment of Mesorectal Excision)

MAME is a method of assessment, by which we can describe the integrity of the mesorectal specimen and assess the quality of TME via visual inspection and use of cross-sectional slices of the segment with tumor (3–5 mm in thick) (35).

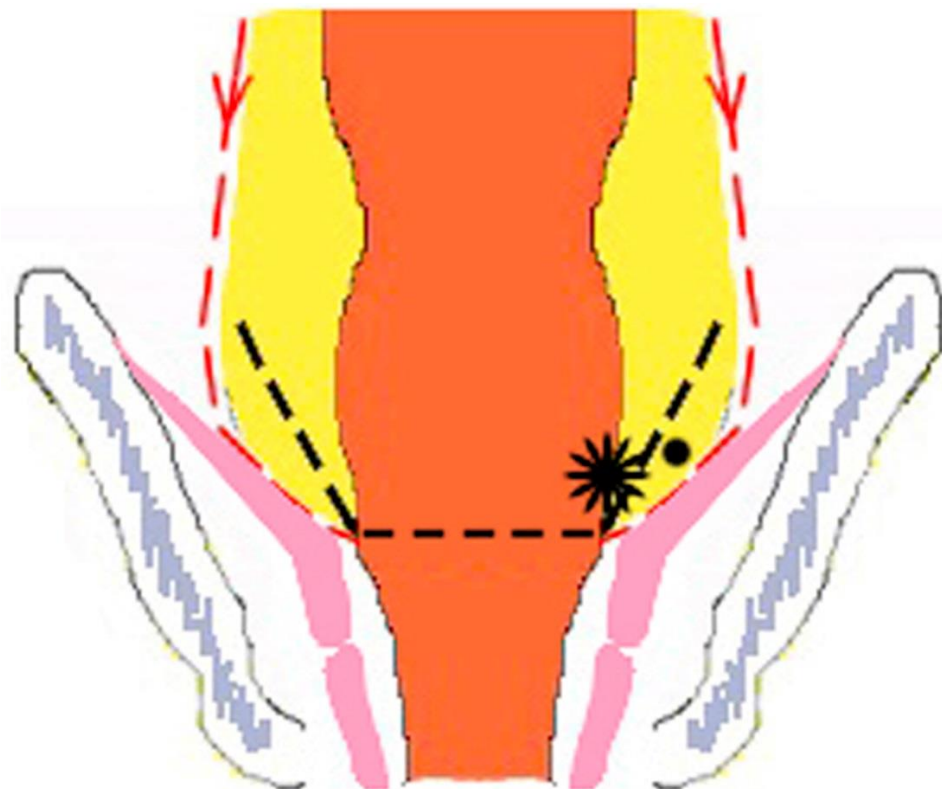
The visual inspection can provide a very clear indication of the quality of the mesorectal specimens, and the cross-sectional slices of the segment with tumor can provide further assessment of the regularity of the CRM, an indicator of the adequacy of the resection (26).

According to the definitions by the CR07 protocol, the quality of mesorectal specimens can be described as follows. Mesorectal resection (MRR)/good/complete: intact mesorectum and smooth mesorectal surface with only minor irregularities; no defects deeper than 5 mm; no coning of the specimen towards the distal margin; and smooth macro-CRM on slicing. Intramesorectal resection (IMR) / intermediate / nearly complete: intermediate bulk of the mesorectum with an irregular surface; a defect deeper than 5 mm, and no visible muscularis propria other than inserted levator; intermediate coning; intermediate irregularity of macro-CRM on slicing. Muscularis propria resection (MPR)/poor/incomplete: small bulk of the mesorectum with a very irregular surface; defect down to the muscularis propria; severe coning; severe irregularity of macro-CRM on slicing (34).

A meta-analysis by *Bosch and Nagtegaal* including over 2174 patients, found that patients with an MPR had a significantly higher LRR than patients with the other two grades (either IMR or MRR) ( $P=0.005$ ); moreover, the LRR in patients with either an MPR or an IMR was significantly higher than that in patients with an MRR ( $P=0.04$ ). Therefore, it could be practical to employ the grades of the mesorectum as an indicator for the risk of local recurrence among patients who received rectal cancer resection (37).

### ► **Coning**

A “coning” would form if a surgeon cuts towards the tubular rectum during distal dissection instead of operating outside the visceral mesorectal fascia, leaving the specimen with a tapered, conical appearance. In the clinical practice, such a tendency during operation is not rare, and consequently, the surgical quality is undoubtedly suboptimal. Meanwhile, it is also unacceptable if the surgeon removes the distal mesorectum excessively, i.e., far beyond 5 cm from the distal tumor margin, which would not only have little help in improving the prognosis of patients, but also increase the incidence rate of postoperative complications. Therefore, only when the “coning” is located within 5 cm from the distal tumor margin will the clinical benefits become significant (38).



- |   |                       |       |                 |
|---|-----------------------|-------|-----------------|
| ★ | Primary tumor         | —>    | Resection lines |
| ● | Lymph node or deposit | - - - | Coning          |

### Lymphadenectomy:

Many studies have shown an improved prognosis in CRC patients who had an adequate number of LNs removed. Current guidelines by several institutions, such as the *Union Internationale Contre le Cancer* or the American Joint Conference on Cancer, recommend at least 12 lymph nodes to be harvested with the tumour specimen. However, according to the literature even in high-volume colorectal centres the rate of adequacy never reaches 100%. Due to the important practical consequences, over the last decades, factors affecting node harvesting have been widely investigated, but evidence is still lacking and sometimes discordant (39).

Since adjuvant chemotherapy is usually indicated in node-positive disease, inadequate lymphadenectomy can result in pathologically under- or over-staging with the risk of post-operatively under- or over-treatment. adequacy of lymph-node retrieval in emergency and elective surgery is comparable, as well as in laparoscopic and open surgery. On the other hand, Age  $\geq 80$ , ASA score  $\geq 3$  and Hartmann's or rectal resection seem to be risk factors for inadequate lymph node retrieval (40).

### Extended lymphadenectomy:

Eastern countries, especially Japan, consider negative lateral pelvic lymph nodes (LPLN) involvement as locoregional disease for which the standard of care is TME with Lateral Pelvic Lymph Node Dissection (LPLND) (41).

This is different from the current practice in western countries, where LPLNM is considered as distant metastasis that is treated with neoadjuvant chemoradiotherapy (nCRT) followed by TME. There is an ongoing debate about the role of LPLND in the management of low rectal cancer, and whether nCRT or post-operative chemotherapy can replace its role (42).

There is no high evidence to recommend routine LPLND for patients with no clinically suspected lateral pelvic lymph node metastasis on staging imaging. Thus, prophylactic LPLND hasn't been recommended and is controversial even in Japan (43).

Therefore, the indications for LPLND are still debatable with variation between guidance from different societies, as some recommend routine LPLND for patients with locally advanced low rectal cancer, while others advise LPLND to be performed in selected cases (44).

## References

1. Arnold M, Sierra MS, Laversanne M, Soerjomataram I, Jemal A, Bray F (2017): Global patterns and trends in colorectal cancer incidence and mortality. *Gut*;66: 683-91.
2. Wong MC, Ding H, Wang J, Chan PS, Huang J (2019): Prevalence and risk factors of colorectal cancer in Asia. *Intest Res.*;17(3):317-329.
3. Keller DS, Berho M, Perez RO, Wexner SD, Chand M (2020): The multidisciplinary management of rectal cancer. *Nat Rev Gastroenterol Hepatol.*; 17(7):414-429.
4. National Comprehensive Cancer Network (2020): NCCN Clinical Practice Guidelines in Oncology. Rectal Cancer. Available at [http://www.nccn.org/professionals/physician\\_gls/PDF/rectal.pdf](http://www.nccn.org/professionals/physician_gls/PDF/rectal.pdf). Version 6.2020 — June 25, 2020; Accessed: September 4, 2020.
5. Hospers G, Bahadoer RR, Dijkstra EA, et al. (2020): Short-course radiotherapy followed by chemotherapy before TME in locally advanced rectal cancer: The randomized RAPIDO trial. *J Clin Oncol.*; 38(suppl; abstr 4006).
6. Fry RD, Mahmoud N, Maron DJ et al., (2017): Colon and rectum. In: Sabiston textbook of surgery: the biological basis of modern surgical practice, Townsend C.M., Beauuchamp Jr.R.D., Evers B.M., et al. (Eds), 20th edn. Elsevier, section x; Ch. 51: 1312-1394.
7. Cercek A, Roxburgh CSD, Strombom P, Smith JJ, Temple LKF, Nash GM, et al. (2018): Adoption of Total Neoadjuvant Therapy for Locally Advanced Rectal Cancer. *JAMA Oncol.*; 4 (6):e180071.
8. Ryan ÉJ, O'Sullivan DP, Kelly ME, Syed AZ, Neary PC, O'Connell PR, et al. (2019): Meta-analysis of the effect of extending the interval after long-course chemoradiotherapy before surgery in locally advanced rectal cancer. *Br J Surg.*; 10(9):e0138720.
9. Cagir B (2020): Rectal Cancer Clinical Presentation. *Emedicine*; updated Sep 04, 2020. Available at: <https://emedicine.medscape.com/article/281237-clinical#b4>
10. Nahas SC, Nahas C, Bustamante-Lopez LA, Pinto RA, Marques C & Ceconello I (2020): Outcomes of surgical treatment for patients with distal rectal cancer: A retrospective review from a single university hospital. *Desenlaces de tratamiento quirúrgico para pacientes con cáncer de recto distal: Una revisión retrospectiva en un hospital universitario. Revista de gastroenterología de Mexico*; 85(2): 180–189.
11. Herrle F, Sandra-Petrescu F, Weiss C et al. (2016): Quality of life and timing of stoma closure in patients with rectal cancer undergoing low anterior resection with diverting stoma: a multicenter longitudinal observational study. *Dis Colon Rectum*, 59: 281-290.
12. Martin ST, Heneghan HM, Winter DC (2012): Systematic review of outcomes after intersphincteric resection for low rectal cancer. *Br J Surg*, 99: 603-612.
13. Hanly AM, Ryan EM, Rogers AC, McNamara DA, Madoff RD, Winter DC et al. (2014): Multicenter Evaluation of Rectal cancer ReImaging pOst Neoadjuvant (MERRION) therapy. *Ann Surg*, 259(4): 723-727.
14. van Helmond J and Beart RW (2005): *Cancer of the rectum: Operative management and adjuvant therapy. Current Therapy in Colon and Rectal Surgery*. 2nd ed. Philadelphia, Pa: Mosby; 2005.

15. Nelson H, Petrelli N, Carlin A, Couture J, Fleshman J, Guillem J, et al. (2001): Guidelines 2000 for colon and rectal cancer surgery. *J Natl Cancer Inst.*; 93(8):583-96.
16. Maurer CA, Renzulli P, Kull C, Käser SA, Mazzucchelli L, Ulrich A et al. (2011): The impact of the introduction of total mesorectal excision on local recurrence rate and survival in rectal cancer: long-term results. *Ann Surg Oncol.*; 18(7):1899-906.
17. Blanco-Colino R and Espin-Basany E (2018): Intraoperative use of ICG fluorescence imaging to reduce the risk of anastomotic leakage in colorectal surgery: a systematic review and meta-analysis. *Tech Coloproctol*; 22: 15–23.
18. Bujko K, Rutkowski A, Chang GJ, Michalski W, Chmielik E & Kusnierz J (2012): Is the 1-cm rule of distal bowel resection margin in rectal cancer based on clinical evidence? A systematic review. *Annals of surgical oncology*; 19(3): 801–808.
19. Quan D, Gallinger S, Nhan C, Auer RA, Biagi JJ, Fletcher GG, et al. (2012): The role of liver resection for colorectal cancer metastases in an era of multimodality treatment: A systematic review. *Surgery*; 151(6):860-70.
20. Dhir M, Lyden ER, Wang A, Smith LM, Ullrich F, Are C (2011): Influence of margins on overall survival after hepatic resection for colorectal metastasis: a meta-analysis. *Ann Surg.*; 254(2): 234-42.
21. Green BL, Marshall HC, Collinson F, Quirke P, Guillou P, Jayne DG, et al. (2012): Long-term follow-up of the Medical Research Council CLASICC trial of conventional versus laparoscopically assisted resection in colorectal cancer. *Br J Surg.*; 100(1):75-82.
22. Bonjer HJ, Deijen CL, Abis GA, Cuesta MA, van der Pas MH, de Lange-de Klerk ES, et al. (2015): A randomized trial of laparoscopic versus open surgery for rectal cancer. *N Engl J Med.*; 372(14):1324-32.
23. Mulcahy N (2017): GSK's HPV Vaccine, Cervarix, No Longer Available in US. *Medscape Medical News*. Available at <https://www.medscape.com/viewarticle/870853>. October 24, 2016; Accessed: November 8, 2017.
24. Agger EA, Jörgren FH, Lydrup MLA and Buchwald PL (2020): Risk of local recurrence of rectal cancer and circumferential resection margin: population-based cohort study. *Br J Surg*, 107: 580-585.
25. Lawrence J. Burgart, Sanjay Kakar, Chanjuan Shi; Mariana E. Berho, David K. Driman, Patrick Fitzgibbons; Wendy L. Frankel; Kalisha A. Hill; John Jessup; Alyssa M. Krasinskas; Mary K Washington (2019): Protocol for the Examination of Resection Specimens From Patients With Primary Carcinoma of the Colon and Rectum. *Coll Am Pathol*. Available at: <https://documents.cap.org/protocols/cp-gilower-colonrectum-resection-protocol-19-4020-PreHOD.pdf>
26. Song SB, Wu GJ, Pan HD, Yang H, Hu ML, Li Q et al. (2018): The quality of total mesorectal excision specimen: A review of its macroscopic assessment and prognostic significance. *Chronic diseases and translational medicine*; 4(1): 51–58.
27. American Cancer Society (2020): *Cancer Facts & Figures 2020*. American Cancer Society. Available at <https://www.cancer.org/content/dam/cancer-org/research/cancer-facts-and-statistics/annual-cancer-facts-and-figures/2020/cancer-facts-and-figures-2020.pdf>. Accessed: March 11, 2020.
28. Kusters M, Moriya Y, Rutten HJT et al., (2010): Total Mesorectal Excision and Lateral Pelvic Lymph Node Dissection. *Rectal Cancer, International Perspectives on Multimodality Management*. Czito B.G. and Willett C.G. (eds), Humana Press, a part of Springer Science+Business Media; ch (4):53-78.
29. Taflampas P, Christodoulakis M, de Bree E, Melissas J, Tsiftsis DD (2010): Preoperative decision making for rectal cancer. *Am J Surg.*; 200(3):426-32.
30. Alves P, Rama N, Brásio R, Malaquias R, Gil I, Sales I et al. (2014): Laparoscopic total mesorectal excision: Step-by-step technique. *European Journal of Surgical Oncology*; 40(11): S31-S32.
31. Galler AS, Petrelli NJ and Shakamuri SP (2011): Rectal cancer surgery: A brief history. *Surgical Oncology*. 20: 223–230.
32. García-Granero E, Faiz O, Muñoz E, Flor B, Navarro S, Faus C et al. (2009): Macroscopic assessment of mesorectal excision in rectal cancer: a useful tool for improving quality control in a multidisciplinary team. *Cancer*, 115: 3400-3411
33. Nagtegaal ID and Quirke P (2008): What is the role for the circumferential margin in the modern treatment of rectal cancer?. *J Clin Oncol*; 26:303-312.
34. Leonard D, F. Penninckx, A. Laenen, A. Kartheuser (2015): PROCARE Scoring the quality of total mesorectal

excision for the prediction of cancer-specific outcome. *Colorectal Dis*, 17: O115-O122

35. Quirke P, Steele R, Monson J, Grieve R, Khanna S, Couture J et al. (2009): Effect of the plane of surgery achieved on local recurrence in patients with operable rectal cancer: a prospective study using data from the MRC CR07 and NCIC-CTG CO16 randomised clinical trial. *Lancet*, 373(9666):821-8.
36. Leite JS, Martins SC, Oliveira J, Cunha MF, Castro-Sousa F (2011): Clinical significance of macroscopic completeness of mesorectal resection in rectal cancer. *Colorectal Dis*, 3(4):381-6.
37. Bosch SL and Nagtegaal ID (2012): The importance of the pathologist's role in assessment of the quality of the mesorectum. *Curr Colorectal Cancer Rep*, 8: 90-98
38. Kanso F, Lefevre JH, Svrcek M, Chafai N, Parc Y, Tired E (2016): Partial mesorectal excision for rectal adenocarcinoma: morbidity and oncological outcome. *Clin Colorectal Canc*, 15 (1): 82-90.e1.
39. Huang B, Feng Y, Ni M, Chen C, Cai G (2018): Heterogeneous survival between stage IIA and stage IIIA colon cancer when different numbers of lymph nodes are harvested. *ANZ J Surg*, 88 (4): 316-321.
40. Tonini V, Birindelli A, Bianchini S, Cervellera M, Bacchi Reggiani ML, Wheeler J et al. (2020): Factors affecting the number of lymph nodes retrieved after colo-rectal cancer surgery: A prospective single-centre study. *The Surgeon: Journal of the Royal Colleges of Surgeons of Edinburgh and Ireland.*;18(1):31-36.
41. Watanabe T, Itabashi M, Shimada Y, Tanaka S, Ito Y, Ajioka Y et al. (2015): Japanese society for cancer of the colon and rectum (JSCCR) guidelines 2014 for treatment of colorectal cancer. *Int. J. Clin. Oncol.*; 20(2): 207-239
42. Malakorn S, Yang Y, Bednarski BK, Kaur H, You YN, Holliday EB et al. (2019): Who should get lateral pelvic lymph node dissection after neoadjuvant chemoradiation? *Dis. Colon Rectum*, 62(10):1158-1166.
43. Chan DKH, Tan KK, Akiyoshi T (2019): Diagnostic and management strategies for lateral pelvic lymph nodes in low rectal cancer—a review of the evidence. *J. Gastrointest. Oncol.*, 10: 1200-1206.
44. Kim HJ, Choi GS, Park JS, Park SY, Cho SH, Lee SJ et al. (2017): Optimal treatment strategies for clinically suspicious lateral pelvic lymph node metastasis in rectal cancer. *Oncotarget*;8(59):100724-100733.