



Clinical Evaluation of Single versus Two Implants Retaining Mandibular Complete Overdentures (Randomized Clinical Trial)

Hany Mohamed Sobaih ⁽¹⁾, Ahmed Emad Fayyad ⁽²⁾, Magda Ismail Ramzy ⁽³⁾,
Amal Ali Swelem⁽⁴⁾

⁽¹⁾ Ph.D. candidate at the Department of Prosthodontics, Faculty of Dentistry, Cairo University, Egypt.
Email: hsobaih@gmail.com

⁽²⁾ Professor of Prosthodontics - Faculty of Dentistry - Cairo University, Egypt.
Email: ahmed.fayyad@dentistry.cu.edu.eg

⁽³⁾ Professor of Prosthodontics, National Research Centre, Egypt.
Email: magdaramzy@hotmail.com

⁽⁴⁾ Professor of Prosthodontics - Faculty of Dentistry - Cairo University, Egypt.
Email: amalswelem@gmail.com

Corresponding author: Hany Mohamed Sobaih
hsobaih@gmail.com

Abstract

Purpose: The aim of this study was to compare clinically between single and two implants retaining mandibular complete overdentures as regards bleeding on probing and the depth of peri-implant sulcus.

Methodology: Twelve completely edentulous males were enrolled in the study and were randomly divided into two equal groups. First group received two implants at the canine areas. Second group received a single implant at the midline. The degree of peri-implant inflammation was assessed using the modified Bleeding on Probing Index and by measuring the depth of the peri-implant sulcus (probing depth). Assessments were carried out two weeks after overdenture delivery, then one, two and three months later to evaluate the soft tissue changes around the implants. Mann Whitney test was used for between-group comparison, and Friedman test was used for within group comparison. The significance level was set at $P \leq 0.05$.

Results: There was a gradual decrease in bleeding on probing and probing depth within each group. However, this decrease was not statistically significant. Similarly, for both parameters, there was no statistically significant difference between both groups at all follow-up periods.

Conclusion: One implant retained overdentures showed comparable results to two implant retained overdentures as regards bleeding on probing and probing depth.

Keywords: single implant retained overdentures, two implant retained overdentures, bleeding on probing, probing depth.

DOI: [10.48047/ecb/2023.12.8.761](https://doi.org/10.48047/ecb/2023.12.8.761)

Introduction

The use of two un-splinted implants has been reported to be the minimal acceptable standard of care for the edentulous mandible. Unfortunately, even this seemingly cheap treatment modality is outside the financial scope of many edentulous patients. As a result, there is a need of a treatment modality that is less expensive, less invasive, less complex, but equally effective to the two implants retained overdenture treatment (**Feine et al. 2002, Turkyilmaz et al. 2006**). The use of a single implant at the midline of the mandible to retain a complete overdenture is a promising alternative for edentulous patients. This treatment modality has been proposed to be a feasible option with the advantages of simplicity and less cost (**Liddelow and Henry 2010, Schneider and Synan 2011**). Although most studies have considered implant survival to be the only measure of success, a better definition however includes the long-term stability of all the restorative components, and the long-term stability of the hard as well as the soft tissues around the implant(s) (**Bahat and Sullivan 2010**). A variety of periodontal parameters could be used to evaluate peri-implant tissue, including plaque index, bleeding on probing, probing depth and attachment level (**Kim et al. 2014**).

Bleeding on probing and increasing probing depth are always present with peri-implant disease (**Pranskunas et al. 2016**). Hence, bleeding on probing plays an essential role in detecting early changes of the soft tissues around implants. However, although the absence of bleeding on probing strongly indicates health, its presence does not necessarily denote disease progression. That is why it should be used in addition to other parameters, such as progressive bone loss or pocket depth before establishing a peri-implant diagnosis (**Hashim et al. 2018, Dukka et al. 2021**).

Most of the researchers that compared between single and two-implant retained overdentures investigated parameters such as bone loss, patient satisfaction, implant failure and prosthetic complications. Few published researches however compared between these two modalities as regards the health of the soft tissues around the implant(s) (**Cordioli et al. 1997, Krennmair and Ulm 2001, Policastro et al 2019**).

The aim of this study was to compare clinically between single and two implants retaining mandibular complete overdentures as regards bleeding on probing and the depth of peri-implant sulcus (probing depth). The null hypothesis was that no significant difference would be observed between single and two implants retaining mandibular complete overdentures as regards bleeding on probing and probing depth.

Methodology

Twelve completely edentulous males, reporting to the Outpatient Clinic of the Prosthodontics Department, Faculty of Dentistry, Cairo University, were included. Their ages were between 45 to 60 years. Inclusion criteria included being edentulous for a minimum period of 6 months and maximum period of 1 year, had 12 mm or more residual bone height in the anterior region, and had Class I jaw relationship. Subjects with any history of metabolic or systemic disease that may affect implant osseointegration, those with logistic or physical reasons that may affect follow-up, those with history of radiation therapy to head and neck region, drug or alcohol abuse history, or those with long term and heavy smoking history were excluded. Complete history, including clinical and radiographic examinations was recorded for each participant. The entire treatment procedure, its benefits, and complications were explained to obtain informed consent before the procedure was started. Conventional dentures were constructed according to the standard protocol followed by the school and the lingualized occlusion concept was applied. The mandibular denture of each participant was then duplicated into self cured acrylic resin (Acrostone, Dental Factory – Industrial zone, Salam city A.R.E.- WHW Plastic England.) with 1.5mm round gutta-percha radiopaque markers placed into holes drilled at the proposed implant sites. Preoperative cone beam computed tomography (CBCT) was carried out with the maxillary dentures on. Using computer generated randomization (random.org), selected participants were randomly divided into two equal groups. First group of six participants were to receive two implants at the canine areas. Second group of six participants were to receive a single implant at the midline. The radiographic stent was modified to be used as a surgical template. U-shaped notches were made at the proposed implant site(s). Root form internally hexed pure titanium implants (Dentis™ implant, Korea) of 3.7 mm in diameter and 10 mm in length were used. After flap reflection and bone preparation, implant(s) were placed in the prepared osteotomy site(s), threaded in a clockwise direction, and covered by covering screws (**Figs. 1 and 2**).

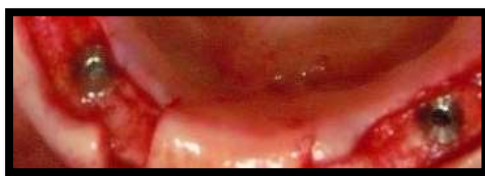

Figure 1: Two implants installed at canine regions (Group 1)

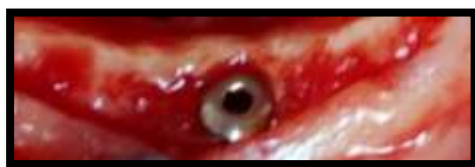

Figure 2: Single implant installed at midline (Group 2)

Suturing of the flap was done and removed after seven days. After three months, patients were recalled. Crestal incisions were made and cover screws were unthreaded. Locator abutments (KERATOR® Overdenture Attachment System) were tightened (**Figs. 3 and 4**).

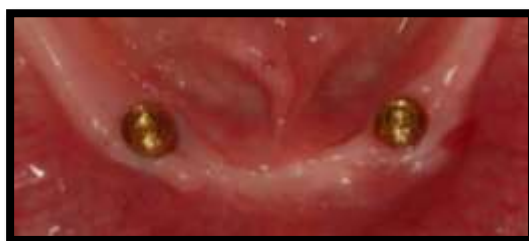

Figure 3: Locator abutments in Group 1 (Two-implant Group)

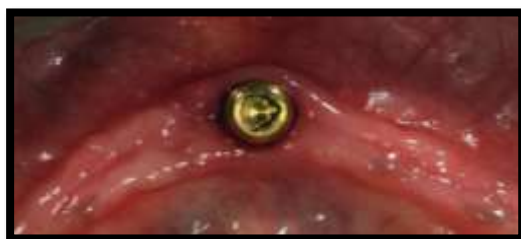

Figure 4: Locator abutment in Group 2 (One-implant group)

Rubber rings were placed on locator abutments to prevent setting of acrylic resin in undercuts below metal housings. Blue nylon male cap (extra light retention 1.5lbs) was placed inside the metal housing using the insertion tool. Both were placed on the locators. Holes were made lingually in the acrylic resin below the artificial teeth opposing the locator abutments for the escape of excess acrylic resin. Auto-polymerised acrylic resin was mixed and added. The denture was seated intraorally. The participant was instructed to close in centric occluding relation till complete polymerization. The overdenture was then removed and excess material was trimmed out (**Figs. 5 and 6**). Overdenture was re-polished and delivered to the participant.

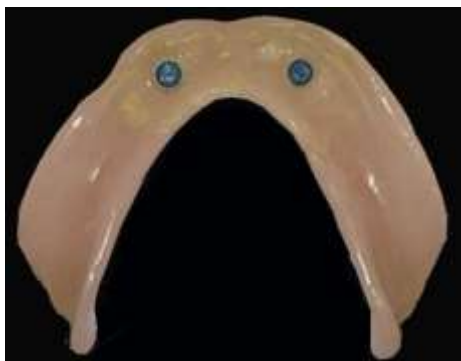

Figure 5: Fitting surface of overdenture in group 1 (Two-implant Group)

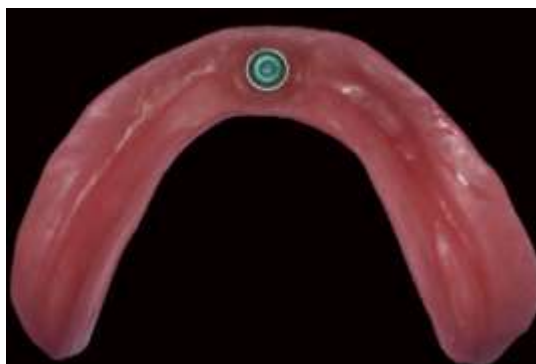

Figure 6: Fitting surface of overdenture in group 2 (One-implant group)

Participants were given strict oral hygiene instructions and recalled after two weeks, then one, two and three months to evaluate the soft tissue changes around each implant. The depth of peri-implant sulcus (probing depth) was measured, in millimeters, as the distance between marginal border of the peri-implant mucosa and the tip of the probe using a calibrated pressure-controlled plastic periodontal probe (Kerr, Rastatt, Germany) (**Fig.7**). It was measured on the labial, mesial, distal, and lingual sites of each implant. Then the average of all sites was calculated for each implant. Bleeding on probing was assessed using the modified Bleeding on Probing Index (**Mombelli et al. 1987**) as follows: score 0: no bleeding; score 1: bleeding on probing without redness and swelling; score 2: bleeding on probing, redness and swelling; score 3: spontaneous bleeding. It was assessed on the labial, mesial, distal, and lingual sites of each implant. Then the average of all sites was calculated for each implant.

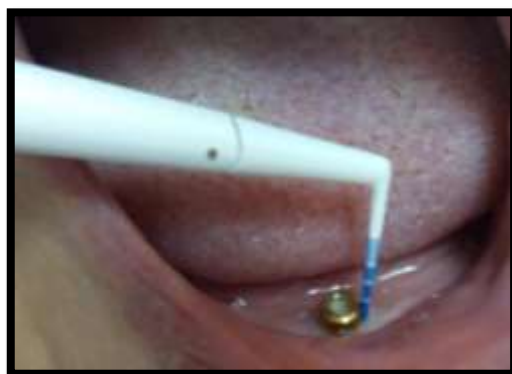

Figure 7: Probing depth assessment

Statistical analysis was performed with SPSS 17.0 (Statistical Package for Scientific Studies for Windows, SPSS Ltd, Chicago, IL, USA). Data were explored for normality using Kolmogorov-Smirnov and Shapiro-Wilk tests. Data for bleeding on probing and probing depth were not normally distributed. Hence, Mann Whitney test was used for between-group comparison, and Friedman test was used for within group comparison. The significance level was set at $P \leq 0.05$.

Results

All participants attended all follow up periods. There were no drop-outs. None of the implants failed and they all showed successful osseointegration.

I) Bleeding on Probing: For both groups, no statistically significant difference was found among all follow-up periods ($p > 0.05$). At the same time, no statistically significant difference was found between the two groups at all follow-up periods ($p > 0.05$) (Table 1 and Fig. 8).

Table (1): Mean and Standard Deviation (SD) values of Bleeding on probing scores in both groups

Variables	Bleeding on probing				<i>p-value</i>
	Two Implants Group		One Implant group		
	Mean	SD	Mean	SD	
After 2 weeks	1.83	0.41	1.75	0.75	0.87ns
After 1 month	1.50	0.55	1.33	0.49	0.41ns

After 2 months	1.33	0.52	1.25	0.45	0.66 ns
After 3 months	1.17	0.41	1.00	0.43	0.32 ns
p-value	0.20 ns		0.30ns		

ns; non-significant ($p>0.05$)

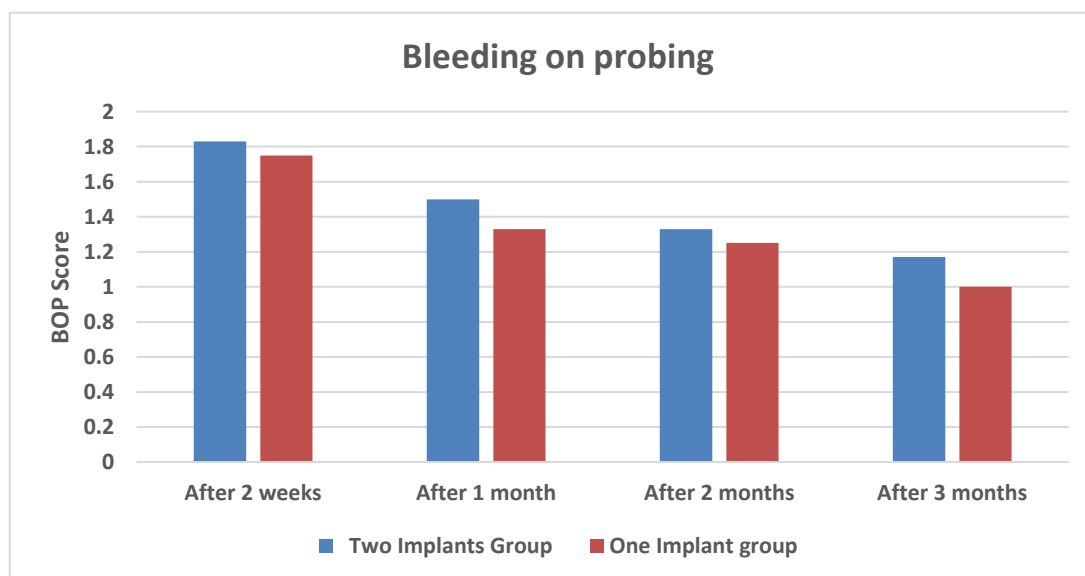


Figure 8: Bar chart representing scores of Bleeding on probing of the two groups at all follow-up periods

II) Probing Depth: For both groups, no statistically significant difference was found among all follow-up periods ($p>0.05$). Similarly, no statistically significant difference was found between the two groups at all follow-up periods ($p>0.05$) (Table 2 and Fig. 9).

Table (2): Mean and Standard Deviation (SD) values of Probing Depth in both groups

Variables	Probing Depth				p-value
	Two Implants Group		One Implant group		
	Mean	SD	Mean	SD	
After 2 weeks	2.83	0.41	2.83	0.41	1 ns
After 1 month	2.71	0.41	2.50	0.55	0.39 ns

After 2 months	2.67	0.52	2.33	0.52	0.39 ns
After 3 months	2.33	0.52	2.17	0.41	0.69 ns
p-value	0.06 ns		0.05 ns		

ns; non-significant ($p > 0.05$)

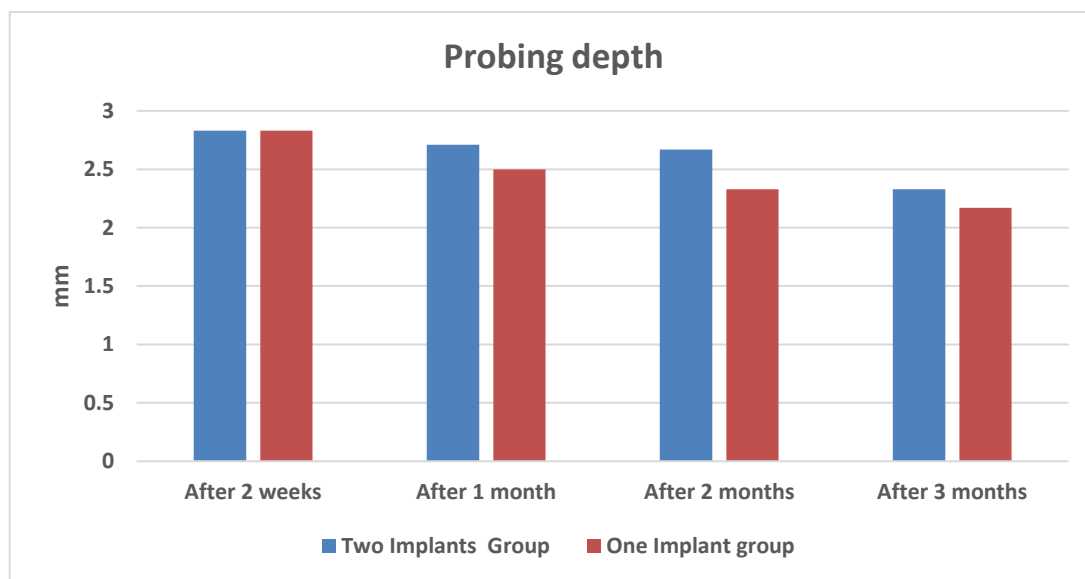


Figure 9: Bar chart representing values of Probing Depth of the two groups at all follow-up periods.

Discussion

Results of the current study revealed insignificant differences between both groups as regards the two parameters tested (bleeding on probing and probing depth). Hence the null hypothesis could be accepted.

The decrease in probing depth, observed in both groups, may be explained by the healing mechanism. The space between implant neck and soft tissue is filled by coagulum. Then, it is infiltrated and degraded by neutrophils during the first 2 weeks after surgery. At this stage, no complete formation of epithelial or connective tissue seal could be found. The formation of a mature barrier epithelium occurs after 6–8 weeks (**Berglundh et al. 2007**).

A decrease in bleeding on probing was also observed in both groups throughout the study period. This could be partially due to the improved ability of the participants to perform effective oral hygiene measures. However, it could also be related to the decreased probing depth measurements. It has been

reported recently that there is a direct correlation and association between probing depth and bleeding on probing around dental implants (**Nettemu et al. 2021**).

Results of the current study are in agreement with the findings of previous clinical studies that investigated the same clinical outcomes in single or two-implant retained overdentures (**Cordioli et al. 1997, Krennmair and Ulm 2001, Policastro et al 2019**). **Cordioli et al. 1997** reported an average pocket depth of 2.41 ± 0.17 mm in single-implant retained overdentures. Similarly, **Krennmair and Ulm 2001** reported an average of 2.6 ± 0.7 mm with no statistically significant differences in pocket depth measurements throughout their 18 months follow-up period.

In another study, **Policastro et al 2019** reported pocket depths that ranged from 2.72 - 3.20 mm in single-implant retained overdentures and 1.98-2.55 mm in two-implant retained overdentures. These values are still comparable to those recorded in the current study. However, their bleeding on probing (BOP) values were different and ranged from 0.45- 0.54 for single-implant retained overdentures and 0.56-0.72 in two-implant retained overdentures. Their scores were much lower than the BOP scores recorded in the current study. This could be attributed to the difference in BOP scale they used, which was simply 0 (absence of bleeding) and 1 (presence of bleeding).

Results of the current study are promising and suggest that using single implants to retain overdentures could be justified especially when used in well-developed ridges. However, more clinical studies with different ridge morphologies, larger sample sizes and longer follow-up periods are recommended to provide more insightful evidence on the viability of these findings.

Conclusions

Within the limitations and the time frame of this study, it could be concluded that bleeding on probing and probing depth decreased in both groups however this decrease was insignificant throughout the study period. One implant retained overdentures showed comparable results to two implant retained overdentures as regards bleeding on probing and probing depth.

References

- Bahat O, Sullivan RM. Parameters for successful implant integration revisited part I: immediate loading considered in light of the original prerequisites for osseointegration. *Clin Implant Dent Relat Res.* 2010; 12 (s1):e2-12 .
- Berglundh T, Abrahamsson I, Welander M, Lang NP, Lindhe J. Morphogenesis of the peri-implant mucosa: an experimental study in dogs. *Clinical Oral Implants Research.* 2007 Feb; 18(1):1-8 .

- Cordioli G, Majzoub Z and Castagna S. Mandibular overdentures anchored to single implants: a five-year prospective study. *J Prosthet Dent.* 1997; 78(2):159-65
- Dukka H, Saleh MHA, Ravidà A, Greenwell H, Wang HL. Is bleeding on probing a reliable clinical indicator of peri-implant diseases? *J Periodontol.* 2021; 92(12):1669-1674.
- Feine JS, Carlsson GE, Awad MA, Chehade A, Duncan WJ, Gizani S, Head T, Lund JP, MacEntee M, Mericske-Stern R, Mojon P, Morais J, Naert I, Payne AG, Penrod J, Stoker GT, Tawse-Smith A, Taylor TD, Thomason JM, Thomson WM and Wismeijer D. The McGill consensus statement on overdentures. Mandibular two-implant overdentures as first choice standard of care for edentulous patients. Montreal, Quebec. *Int J Oral Maxillofac Implants.* 2002; 17(4): 601-602.
- Hashim D, Cionca N, Combescure C, Mombelli A. The diagnosis of peri-implantitis: A systematic review on the predictive value of bleeding on probing. *Clin Oral Implants Res.* 2018;29 Suppl 16:276-293.
- Kim HY, Shin SW, Lee JY. Standardizing the evaluation criteria on treatment outcomes of mandibular implant overdentures: a systematic review. *J Adv Prosthodont.* 2014; 6(5):325-32 .
- Krennmair G and Ulm C: The symphyseal single-tooth implant for anchorage of a mandibular complete denture in geriatric patients: A clinical report. *Int. J. Oral Maxillofac Implants.* 2001; 16(1):98-104.
- Liddel G and Henry P. The immediately loaded single implant-retained mandibular overdenture: a 36-month prospective study. *Int J Prosthodont.* 2010; 23(1): 13-21.
- Mombelli A, van Oosten MA, Schurch E Jr, Land NP. The microbiota associated with successful or failing osseointegrated titanium implants. *Oral Microbiol Immunol.* 1987; 2: 145-151.
- Nettemu SK, Nettem S, Singh VP, William SS, Gunasekaran SS, Krisnan M, Abas AL. Multilevel analysis of site, implant, and patient-level factors with peri-implant bleeding on probing: a cross sectional study. *Int J Implant Dent.* 2021 ;10;7(1):77.
- Policastro VB, Paleari AG, Leite ARP, Mendoza-Marin DO, Cassiano AFB, Shaddox LM, Compagnoni MA, Pero AC. A Randomized Clinical Trial of Oral Health-Related Quality of Life, Peri-Implant and Kinesiograph Parameters in Wearers of One-or Two-Implant Mandibular Overdentures. *J Prosthodont.* 2019; 28(7):757-765.
- Pranskunas M, Poskevicius L, Juodzbalys G, Kubilius R, Jimbo R. Influence of Peri-Implant Soft Tissue Condition and Plaque Accumulation on Peri-Implantitis: a Systematic Review. *Journal of Oral & Maxillofacial Research.* 2016; 7(3):e2 .

- Schneider GB and Synan WJ. Use of a single implant to retain a mandibular complete overdenture on the compromised atrophic alveolar ridge: a case report. *Spec Care Dentist*. 2011; 31(4): 138-42 .
- Turkyilmaz I, Sennerby L, Tumer C, Yenigul M and Avci M. Stability and marginal bone level measurements of unsplinted implants used for mandibular overdentures: a 1-year randomized prospective clinical study comparing early and conventional loading protocols. *Clin. Oral Impl. Res.* 2006; 17(5): 501–505