



## **A comparative study of distal end radius fracture managed by external fixator with k-wire and volar locking plate**

**<sup>1</sup>Dr. Musheer Ahmed, <sup>2</sup>Dr. Kanak Arora, <sup>3</sup>Dr. Prabhu M M**

<sup>1</sup>Senior Resident, Department of Orthopaedics, Dhanalakshmi Srinivasan Medical College and Hospital, Siruvachur, Tamil Nadu, India

<sup>2</sup>Senior Resident, Department of Orthopaedics, ESIC Medical College and Hospital, Faridabad, Haryana, India

<sup>3</sup>Fellow in Limb Lengthening and Reconstruction, Bangalore Medical College and Research Institute, Bengaluru, Karnataka, India

**Corresponding Author: Dr. Musheer Ahmed**

---

### **Abstract**

The distal radial fractures account for about 15 to 20% of total fractures managed by an Orthopaedic surgeon [1]. Many studies on this topic have been done earlier with reverence to the association between various management modalities of fractures of distal radius and functional outcomes [2]. The findings of these studies have most often presented no correlation between the two factors. Distal radial fracture is common in females above 50 years of age [3]. Two of the most frequently used were the AO (Arbeitsgemeinschaft für Osteosynthesefragen) Classification which had nine chief subgroups and the Frykman classification which had 8 subgroups [4]. The prognostic and outcome worth of these classifications, to assess the consequence of a fracture of distal radius may not be precise [5], particularly concerning inter- and intra-observer level of agreement [6]. This is a descriptive study dealing with the association of the functional outcomes in AO type of fractures at the distal end of radius which are managed by various treatment modalities.

**Objectives:** To compare the clinical, functional and Radiological outcome of Distal End Radius Fracture managed by closed reduction and bridging external fixator augmented with k-wires and volar-locking plating.

**Methodology:** This study was conducted in Department of Orthopaedics, Navodaya Medical College Hospital and Research Centre, Raichur, From July 2020 to June 2021, 27 patients treated with either modality of treatment were analysed, of which 15 were treated with external fixator augmented with k-wire and 12 were treated with 2-column fixed angle volar LCP.

**Results:** The mean passive wrist ROM at the final follow-up evaluation in ext fixation patients was 55 degrees extension and 67 degrees flexion, compared with 69 degrees extension and 77 degrees flexion in patients treated with volar LCP group.

Final radiographic measurements for the Ext fixation group averaged 2.9 degrees volar tilt and 14.2 mm degrees radial inclination, with 5mm radial length. The Volar LCP group averaged 7.3 degrees volar tilt, 16.9 degrees radial inclination, with

9.75mm radial length. Radial length and volar tilt were significantly greater for the ORIF group when compared with the radial length. There was significant difference in the radiological and functional outcome of AO Muller type C fractures treated by volar LCP with respect to the external fixator group (p-value 0.009 and 0.026 respectively). There was no significant difference in the radiological and functional outcome of AO Muller type B fractures treated by volar LCP with respect to the external fixator group (p value 0.706 and 0.707 respectively).

**Conclusion:** The use of ORIF with a volar fixed-angle implant resulted in stable fixation, especially in type C is a superior method to maintain the reduction till union and prevent the collapse of the fracture fragments, even in grossly comminuted, unstable and osteoporotic bones as compared with external fixator augmented with K-wires. However in type B fractures, Volar LCP and K- wire augmented External fixator provide equivocal result.

Ligamentotaxis by external fixation provided favourable results in younger age group and in partial intra-articular type of distal radius fractures and requires at-least 4 cortical purchases on each side for effective stability.

**Keywords:** Distal end radius fracture, external fixator, volar plate, lindstorm's criteria, mayo wrist score

---

## **Introduction**

### **Materials and Methods**

This study was designed to analyze and compare the functional and radiographic outcome in distal radius articular fractures of 27 patients treated by closed reduction and external fixator augmented with K-wires and volar-locking plate done in in Department of Orthopaedics, Navodaya Medical College Hospital and Research Centre, Raichur, From July 2020 to June 2021.

### **Inclusion Criteria**

1. Age more than 18 years.
2. Muller's type B (partial intra-articular) and type C (complete intra articular).
3. Intra-articular fractures extending less than 5 cm from joint line.
4. Closed fractures.
5. Patients of either sex.

### **Exclusion Criteria**

1. Age less than 18 years.
2. Undisplaced fracture.
3. All open fractures.
4. Neglected fractures more than 4 weeks.
5. Severe co-morbidities.
6. H/O previous wrist pathology or malunited distal radius fracture.

### **Patient Evaluation**

Patients presenting in the Emergency department and the Outpatient department were admitted for thorough evaluation. Detailed history was taken to rule out other

systemic injury, ascertain the duration of injury, mode of injury, co morbid illness, and history of previous surgeries and for ruling out other major system involvement as a part of trauma screening.

The involved limb is evaluated for the injuries pertaining to skin in the form of abrasions, contusion, lacerations, punctured wounds etc. Diagnosis of fracture was done clinically with the help of tenderness, swelling, deformity and abnormal mobility.

Vascular examination of the distal forearm, hand and palpation of radial artery and ulnar artery pulses (by Allen test) in particular were done. Allen test is used to detect patency of radial, ulnar and digital arteries.

Neurological examination of all peripheral nerves is done. Careful evaluation of the features of impending or established compartment syndrome was done for ruling out those fractures from the study. All eligible patients fulfilling our inclusion criteria were subjected to further radiological evaluation.

### **Preoperative Assessment**

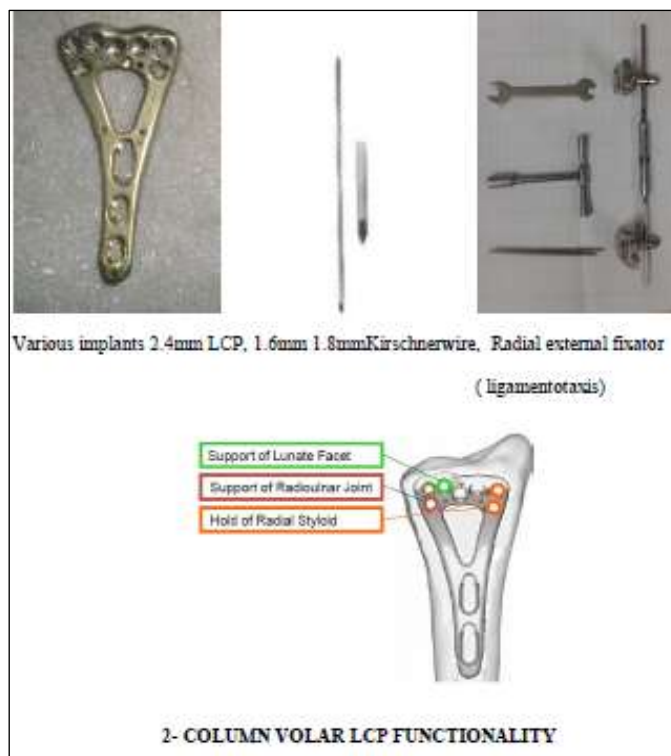The limb was stabilized in a below-Elbow slab temporarily and limb elevated to reduce the pain and swelling. Further investigations were done for anaesthetist opinion and assessment obtained. All patients included in the study were subjected to the described surgical procedure, after surgical fitness was obtained.

### **Surgical Procedure**

The fractures were treated with internal fixation or external fixation for the distal radius intraarticular fractures. The patients were randomized alternatively into 2 groups and were operated by internal or external fixation.

### **Preoperative Planning**

The choice of a particular procedure for each case depended on the Fracture pattern, reducibility and stability and quality of bone.



### Patient Positioning

Patient was positioned supine on the radiolucent table with side arm-board. Image intensifier was positioned under the arm-board so as to visualize the distal radius, distal ulna and the articular surface in AP and lateral views.

### Surgical Technique

All procedures were performed under general or regional anaesthesia (supraclavicular or interscalene block). Our standard practice was performed under sterile aseptic precautions of local parts preparation and draping. Routinely preoperative prophylactic intravenous cefotaxime was administered for all patients.

Tourniquet was used in 7 patients and hemostasis was achieved in all patients before closing the surgical wound. All the patients were approached by standard volar approach for distal radius except for three, where closed reduction was done and external fixator was applied and augmented with Kirschner wire or screws.

The standard modified Henry's volar approach was undertaken to fix the fragments of the distal radius. In cases where the radial column fragment was initially approached, the plane between the radial artery and the flexor carpi radialis was used. For the intermediate column fragment under the lunate facet, plane between the flexor carpi radialis tendon and the median nerve was used. The distal and lateral borders of pronator quadratus were erased and retracted ulnarward.

### Intra Operative Pictures of the Exposure of the Distal Radius

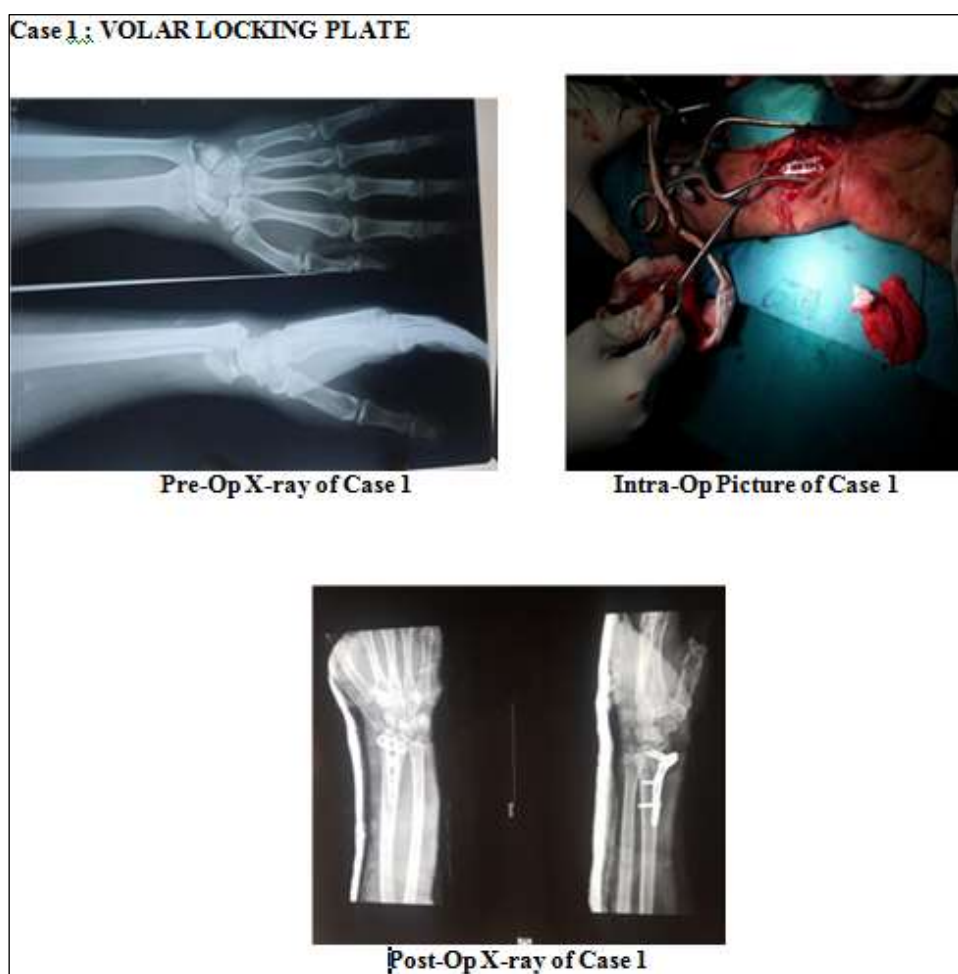
Closed reduction and external fixation was done for those with skin conditions not permitting for open reduction. Open reduction was performed using intrafocal

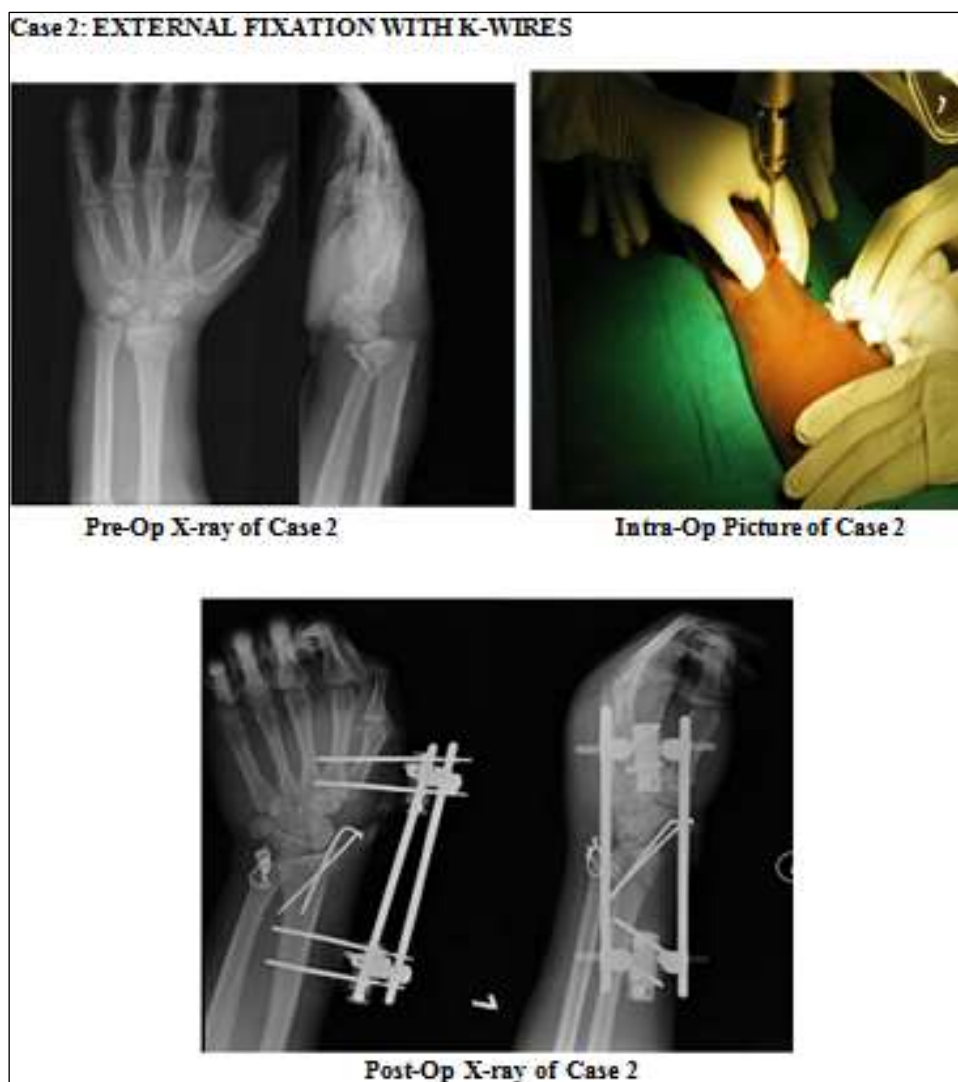leverage, traction, and temporary fixation with Kirschner wires followed by definitive fixation with the implants of choice.

In cases which had a displaced radial styloid or fragments too small for other means of fixation, was fixed with Kirschner wires augmented with external fixator. Locking compression plates with 2.4 mm were used for comminuted fractures with relatively poor bone quality.

Bone grafting was not done in any of the cases in spite of the higher degree of comminution in high number of patients as all of them had good bone in the volar intermediate column [7].

The reduction of both the distal radius were confirmed with the image intensifier during the fixation and ensured before closure of the surgical site. Drain was used in all of our Volar LCP internally fixed patients.





### Postop Protocol

All patients were given I.V third generation cephalosporin during Induction which was continued for 3-5 days post operatively. The hand and Forearm was initially placed in a compressive dressing extending from hand to below elbow and elevated for forty-eight to seventy-two hours to reduce swelling.

Drain was removed on the 2nd postoperative day. All patients operated with Volar LCP were encouraged to begin an early active range of motion of the wrist and hand as tolerated. The patients fixed with Kirschner wire augmented External fixator were immobilized for four to six weeks based on the fracture pattern, reduction and stability, with active finger mobilization. Thereafter gradual wrist mobilization was done.

Sutures were removed on the twelfth post-operative day. Patients were not allowed to lift heavy weight for twelve to sixteen weeks. Mobilization of the wrist and the hand were initiated from the 2<sup>nd</sup> postoperative day as tolerated by the patient except for those fixed with External fixator or Kirschner wires alone. Those patients fixed with K wires were initially given below elbow cast and was mobilized by 3-6 weeks, after the removal of the cast.

### Observation and Results

The following observations were made in the study.

#### Age and Sex Incidence

Patients' age ranged from 18 to 70 years. Average: 47.18 years.

In our series, Males predominated with the ratio of 2.3:1.

AGE - DISTRIBUTION		SEX - DISTRIBUTION	
AGE IN YEARS	NO OF PATIENTS	SEX	NO OF PATIENTS
0-20	2	MALE	19
21 - 40	7	FEMALE	8
41 - 60	13		
61 - 80	5		

#### Side and Mode of Injury

In our study 15 patients had Left sided injury accounting for 55.5% of the total patients and RTA was the predominant mode of injury.

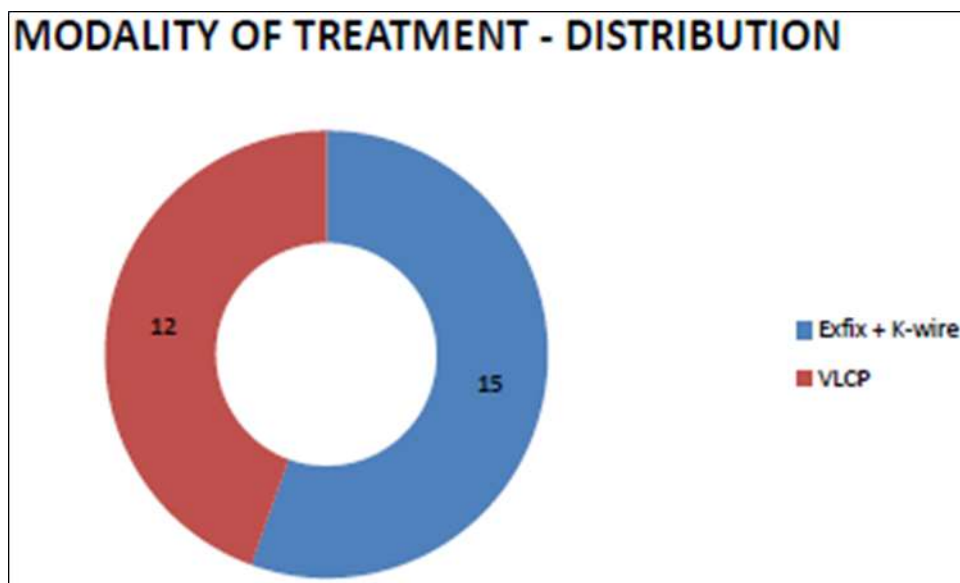
SIDE - DISTRIBUTION		Type of trauma	AO Type B	AO Type c	Total
SIDE	NO OF PATIENTS				
RIGHT	12	RTA	6	9	15
LEFT	15	FOOSH	8	4	12
		Total	14	13	

#### Modality of Treatment and Fracture Classification

In the modality of treatment, 12 patients were treated with volar locking compression plate and 15 patients were treated with external fixation augmented by K-wires.

FRACTURE CLASSIFICATION		
MULLER AO TYPE	EXT FIXATOR WITH K-WIRE GROUP	VOLAR LCP GROUP
B1	1	0
B2	4	5
B3	1	3
C1	3	2
C2	3	1
C3	3	1





### Results

The mean follow up was 8.9 months, ranging from 3 months to 24 months. All 27 patients had regular follow-up.

### Union

All the patients had good union. The mean time of union was 14 weeks with a range of 10 to 18 weeks with a 16 cases healing by 12 weeks. Rest of the 11 cases took a longer duration. 1 case of delayed union was reported in the external fixator group when the external fixator was removed and a cast was applied for a further 2 months till union was complete. Longer duration to union is noted in patients of older age with relatively poor bone quality.

### Malunion

3 patients of the 15 treated with kirschner wire augmented External fixator had malunion with significant dorsal angulation with negative palmar tilt.

### Radiological outcome

Sarmiento's modification of Lindstorm's criteria:

EXTERNAL FIXATOR GROUP IN AO TYPE C ( COMPLETE INTRAARTICULAR ) FRACTURES					
RESULT	DEFORMITY	PALMAR TILT	RADIAL SHORTENING	RADIAL INCLINATION	MEAN
EXCELLENT	0	0	0	0	0
GOOD	2	1	3	2	2( 22%)
FAIR	4	4	3	5	4( 45%)
POOR	3	4	3	2	3 (33%)



EXTERNAL FIXATOR GROUP IN AO TYPE B (PARTIAL INTRAARTICULAR) FRACTURES					
RESULT	DEFORMITY	PALMAR TILT	RADIAL SHORTENING	RADIAL INCLINATION	MEAN
EXCELLENT	3	3	4	2	3 ( 50%)
GOOD	2	2	1	3	2( 34 %)
FAIR	1	1	1	1	1( 17%)
POOR	0	0	0	0	0

VOLAR LCP GROUP IN AO TYPE B (PARTIAL INTRAARTICULAR) FRACTURES					
RESULT	DEFORMITY	PALMAR TILT	RADIAL SHORTENING	RADIAL INCLINATION	MEAN
EXCELLENT	4	2	2	4	3( 37.5%)
GOOD	3	4	2	3	3 (37.5%)
FAIR	1	2	4	1	2 (25%)
POOR	0	0	0	0	0

VOLAR LCP GROUP IN AO TYPE C ( COMPLETE INTRAARTICULAR ) FRACTURES					
RESULT	DEFORMITY	PALMAR TILT	RADIAL SHORTENING	RADIAL INCLINATION	MEAN
EXCELLENT	2	2	1	3	2( 50%)
GOOD	1	1	3	1	1.5 ( 37.5%)
FAIR	0	0	0	0	0
POOR	1	1	0	0	0.5 ( 12.5%)

FUNCTIONAL SCORE FOR AO TYPE B (PARTIAL INTRAARTICULAR) FRACTURES		
	Ext fixator with K-wire group	Volar LCP group
Excellent	3	3
Good	2	3
Fair	1	2
Poor	0	0

	V & G	S & B	Marginal/Row Totals
EXFIX	5 (4.71) [0.02]	1 (1.29) [0.06]	6
VOLAR LCP	6 (6.29) [0.01]	2 (1.71) [0.05]	8
Marginal/Column Totals	11	3	14 (Grand Total)

The Chi-square statistic is 0.1414. The P value is 0.706879. This result is not significant at  $p < 0.05$ .

### Calculation of significance values

This denotes that there is no significant difference in the radiological outcome of modality of fixation of distal radius partial intraarticular fractures by Volar LCP and External Fixator.

FUNCTIONAL SCORE FOR AO TYPE C ( COMPLETE INTRAARTICULAR) FRACTURES		
	Ext fixator with K-wire group	Volar LCP group
Excellent	0	2
Good	2	2
Fair	4	0
Poor	3	0

	E & G	F & P	Marginal/Row Totals
EXFIX	2 (4.15) [1.12]	7 (4.85) [0.96]	9
VOLAR LCP	4 (1.85) [2.51]	0 (2.15) [2.15]	4
Marginal/Column Totals	6	7	13 (Grand Total)

The Chi-square statistic is 4.7497. The P value is 0.02924. This result is significant at  $p < 0.05$ .

### Calculation of significance values

This denotes that there is significant difference in the radiological outcome of modality of fixation of distal radius complete intraarticular fractures by Volar LCP and External Fixator.

### Complications

Two of our patients had malunion. Four of our patients had prominent wires that were felt subcutaneously on the ulnar side. None of the four had any functional disturbance or pain because of the same.

One of our patients had superficial infection which warranted early removal of K-wire leading to malunion. The infection was controlled by removal of K-wire and antibiotics.

Stiffness of the wrist joint and the hand was noted in four patients who were reluctant in mobilizing and attending physiotherapy sessions.

In the Volar LCP group, two patients who were immobilized in cast postoperatively had transient stiffness which was overcome with aggressive physiotherapy resulting in good range of motion thereafter. None of the patients in the present study presented with iatrogenic neurovascular injury or implant breakage during the period of follow-up.

COMPLICATIONS ASSOCIATED WITH THE STUDY		
COMPLICATIONS	EXT FIXATOR GROUP	VOLAR LCP GROUP
Reflex sympathetic dystrophy	NIL	NIL
Paraesthesia in distribution of radial nerve	3	NIL
Impingement of tendons	NIL	NIL
Median nerve complications	NIL	NIL
Residual pain	2	NIL
Dorsal angulation	3	NIL
Pin tract & wound infection	3	3
Pin loosening	2	NIL
Restricted wrist movements	3	2
Finger stiffness	1	NIL
Arthritis	4	1
Malunion	3	1

### Functional Outcome

This denotes that there is no significant difference in the functional outcome of modality of fixation of distal radius partial intraarticular fractures by Volar LCP and External Fixator.

### SUBJECTIVE EVALUATION OF PATIENTS BY MAYO SCORE

MAYO SCORE FOR AO TYPE B (PARTIAL INTRAARTICULAR) FRACTURES		
	Ext fixator with K-wire group	Volar LCP group
Very Good ( 90 – 100 )	4	4
Good ( 80- 89 )	1	2
Satisfactory ( 65 – 79 )	1	2
Bad ( less than 65 )	0	0

MAYO SCORE FOR AO TYPE C (COMPLETE INTRAARTICULAR) FRACTURES		
	Ext fixator with K-wire group	Volar LCP group
Very Good ( 90 – 100 )	0	1
Good ( 80- 89 )	3	3
Satisfactory ( 65 – 79 )	3	0
Bad ( less than 65 )	3	0

	E & G	F & P	Marginal Row Totals
EXFIX	5 (4.71) [0.02]	1 (1.29) [0.06]	6
VOLAR LCP	6 (6.29) [0.01]	2 (1.71) [0.05]	8
Marginal Column Totals	11	3	14 (Grand Total)

The Chi-square statistic is 0.1434. The P value is 0.706879. This result is not significant at  $p < 0.05$ .

	V & G	S & B	Marginal Row Totals
EXFIX	3 (4.85) [0.7]	5 (4.15) [0.02]	8
VOLAR LCP	4 (2.15) [1.58]	0 (1.85) [1.85]	4
Marginal Column Totals	7	5	12 (Grand Total)

The Chi-square statistic is 4.9524. The P value is 0.026055. This result is significant at  $p < 0.05$ .

This denotes that there is no significant difference in the functional outcome of modality of fixation of distal radius complete intraarticular fractures by Volar LCP and External fixator.

## Conclusion

From our study, we conclude that Conservative management or internal fixation with Kirschner wires alone for partial and complete intra-articular fractures of distal radius is not sufficient.

Early Primary fixation of the distal radius fractures by volar LCP is essential for good functional outcome and to avoid complication of prolonged immobilization, which facilitates early return to regular activities.

Patients with unstable, either a dorsally or volarly displaced intraarticular radius fracture had excellent to good radiological outcome when treated with fixed angle volar locking plate. The fracture fixation with volar plate and screw system in the management of distal radius articular fractures, especially in type C (Complete intraarticular fractures) is a superior method to maintain the reduction till union and prevent the collapse of the fracture fragments, even in grossly comminuted, unstable and osteoporotic bones as compared with external fixator augmented with K-wires.

However in type B (partial intraarticular fractures) fractures, Volar LCP and K-wire augmented External fixator provide equivocal results and none is proved superior.

Ligamentotaxis by external fixation provided favourable results in younger age group and in partial intra-articular type of distal radius fractures and requires atleast 4 cortical purchases on each side for effective stability.

### **References**

1. Rockwood Charles A, David P Green, Robert W Bucholz. Rockwood and Green's Fractures in Adults. (7th edn), Wolters Kluwer Health/Lippincott Williams & Wilkins, Philadelphia, PA, USA, 2010.
2. Chen NC, Jupiter JB. Management of distal radial fractures. *J Bone Joint Surg. Am.*, 89(9), 2051-2062.
3. Chung KC, Watt AJ, Kotsis SV, Margaliot Z, Haase SC, *et al.* Treatment of unstable distal radial fractures with the volar locking plating system. *J Bone Joint Surg. Am.* 2006;88(12):2687-2694.
4. Frykman G. Fracture of the distal radius including sequelae-shoulder-hand-finger syndrome, disturbance in the distal radio-ulnar joint and impairment of nerve function. A clinical and experimental study. *Acta Orthop Scand Suppl.* 1967;108:3+.
5. Flinkkilä T, Raatikainen T, Hämäläinen M. AO and Frykman's classifications of Colles' fracture. No prognostic value in 652 patients evaluated after 5 years. *Acta Orthop Scand.* 1998;69(1):77-81.
6. Kreder HJ, Hanel DP, McKee M, Jupiter J, McGillivray G, *et al.* Consistency of AO fracture classification for the distal radius. *J Bone Joint Surg Br.* 1996;78(5):726-731.
7. Dupuytren G. On the injuries and diseases of bones, selections from the collected edition of the clinical lectures. Translation F LeGros Clark, Sydenham Society, London, 1847.