



MORPHOMETRIC STUDY OF FETAL LUNGS AT VARIOUS GESTATIONAL AGES

Vivek Gupta^{1*}, Manisha Nakhate², Sunita Bharti³,
Dipin Kumar Yadav⁴

Article History: Received: 04.06.2023

Revised: 04.07.2023

Accepted: 01.08.2023

Abstract

Background: The lungs are the key organs of the respiratory system, whose most basic function is to facilitate gas exchange from the environment into the bloodstream. Oxygen gets transported through the alveoli into the capillary network, and there arterial system, ultimately perfuses tissue. Lungs have an anterior, posterior, and inferior border, and it has medial, costal, and diaphragmatic surfaces. The oblique and horizontal fissures of the right lung separate it into superior, middle, and inferior lobes. The oblique fissure of the left lung, which runs superiorly and inferiorly from the costal to the medial pulmonary surfaces, divides it into superior and inferior lobes.

Objective: The objective of the study is to correlate the various parameters of the lung such as length of the lung at the anterior border, length of the lungs at the posterior border, and the base circumference of fetal lungs with the gestational age (GA) of the fetus.

Methods: This study was conducted on 30 human fetuses (13 females and 17 males) formalin-fixed with the gestational age ranging from 13 to 30 weeks in the Department of Anatomy D Y Patil medical college in the collaboration with OBGY Department of D Y Patil Hospital, Nerul Navi Mumbai. The study was carried out for a period of two and a half years (from July 2022 to June 2023).

Results: To ensure no data entry error, the data were organized in an Excel spreadsheet. In this study, the GA of the fetuses are ranging from 13 to 30 weeks. All the received fetuses were divided into 4 Groups, Group A (13-16 weeks), Group B (17-20 weeks), Group C (21-24 weeks), and Group D (25-30 weeks).

Conclusion: Length of the lung at anterior border, length of the lung at posterior border and base circumference of the fetal lung do not demonstrate any sex differences with respect to parameters.

Keywords: Fetus, Lungs, Gestational Age, Base Circumference, Anterior Border, Posterior Border.

^{1*}Junior Resident, Department of Anatomy, D.Y. Patil Medical College, Nerul, Navi Mumbai, Maharashtra, India

²Professor & Head, Department of Anatomy, D.Y. Patil Medical College, Nerul, Navi Mumbai, Maharashtra, India

³Associate Professor, Department of Anatomy, D.Y. Patil Medical College, Nerul, Navi Mumbai, Maharashtra, India

⁴Tutor, Department of Anatomy, D.Y. Patil Medical College, Nerul, Navi Mumbai, Maharashtra, India

*Corresponding Author:

Vivek Gupta^{1*}

^{1*}Junior Resident, Department of Anatomy, D.Y. Patil Medical College, Nerul, Navi Mumbai, Maharashtra, India

Email: ^{1*}dr.vivek155@gmail.com

DOI: 10.31838/ecb/2023.12.6.256

1. Introduction

The lungs are the foundational organs of the respiratory system, whose most basic function is to facilitate the gas exchange from the environment into the bloodstream. Oxygen gets transported through the alveoli into the capillary network, where it can enter the arterial system, and ultimately perfuses tissues. The lungs are divided into lobes by the oblique and horizontal fissure. The right lung is separated into superior, middle and inferior lobes by horizontal and oblique fissures whereas the left lung is divided into superior and inferior lobes by an oblique fissure. The trachea splits into two primary principal bronchi, one on each side, at level of the lower border of the 4th thoracic vertebra. Each primary bronchus passes through the hilum to enter the lung, where it splits into secondary lobar bronchus, one for each lung lobe. As a result, there are 3 lobar bronchi on the right side and only 2 on the left. Each lobar bronchus is divided into tertiary or segmental bronchi, one for each of the 20 bronchopulmonary segments, 10 on the right side and 10 on the left. The segmental bronchi continually divide to produce terminal bronchioles, which are incredibly small branches, which lose cartilages to become respiratory bronchioles about 0.2 cm in diameter. Each respiratory bronchiole aerates a small part of the lung known as 'pulmonary unit'. One unit is made up of (i) a respiratory bronchiole, (ii) alveolar duct, (iii) atria and (iv) air saccules, with (v) pulmonary alveoli projecting from the alveolar duct, atria and air saccules. Gaseous exchange take place in the alveoli¹⁻².

The development of the lungs begins in the early stages of embryonic life (fourth week of gestation) and continues until adulthood. It is developed from a primitive lung bud, which arises from the ventral surface of the foregut endoderm. Over the next few weeks, the lung bud divides into two lobes, which will later form the right and left lungs³.

The first stage of lung development is called the embryonic stage, which lasts from the third to the eighth week of gestation. During this stage, the lung buds emerge from the foregut endoderm, a layer of cells that forms the lining

of the digestive and respiratory tracts. The lung buds branch into two primary bronchi, one for each lung, and then into secondary and tertiary bronchi. The bronchi further divide into bronchopulmonary segments, which are the functional units of the lungs.

The second stage of lung development is called the pseudo-glandular stage, which lasts from the ninth to the sixteenth week of gestation. During this stage, the bronchial tree continues to grow and differentiate into terminal bronchioles, which are the smallest airways in the lungs. The lung tissue also develops blood vessels, nerves, and lymphatic vessels. However, the lungs are not yet capable of gas exchange, as they lack alveoli, which are tiny air sacs where oxygen and carbon dioxide are exchanged.

The third stage of lung development is called the canalicular stage, which lasts from the seventeenth to the twenty-sixth week of gestation. During this stage, the terminal bronchioles branch into respiratory bronchioles, which give rise to alveolar ducts and alveolar sacs. The alveolar sacs are lined with primitive alveoli, which are surrounded by capillaries. The alveoli begin to secrete surfactant, a substance that reduces surface tension and prevents them from collapsing⁴. The lungs become capable of gas exchange, but only at a limited capacity.

The fourth stage of lung development is called the saccular stage, which lasts from the twenty-seventh week of gestation to birth. During this stage, the alveolar sacs expand and increase in number, forming mature alveoli. The alveoli also develop more surfactant and interstitial tissue, which provides structural support. The lungs become more compliant and elastic and can adapt to changes in pressure and volume. The lungs are ready for extrauterine life by the thirty-sixth week of gestation.

The fifth stage of lung development is called the alveolar stage, which lasts from birth to adulthood. During this stage, the alveoli continue to grow in size and number, reaching about 300 million by the age of eight years. The alveoli also develop more type II pneumocytes, which are cells that produce

surfactant. The lungs reach their full functional capacity by adolescence.⁵⁻⁶

Abnormalities in lung development can result in various congenital or acquired lung diseases that affect neonatal survival and long-term pulmonary function. Some examples of congenital lung malformations are pulmonary agenesis, pulmonary hypoplasia, congenital diaphragmatic hernia, pulmonary sequestration, bronchogenic cysts, and congenital lobar emphysema. Some examples of acquired lung diseases related to inadequate lung development are bronchopulmonary dysplasia, respiratory distress syndrome, asthma, chronic obstructive pulmonary disease, and pulmonary fibrosis⁷⁻⁸.

2. Materials and Methods:

This study was conducted on 30 human fetuses (13 females and 17 males) formalin-fixed fetuses with the gestational age ranging from 13 to 30 weeks in the Department of Anatomy D Y Patil medical college in collaboration with OBGY Department of D Y Patil Hospital, Nerul, Navi Mumbai. The study was carried out for a period of two and a half years (from July 2022 to June 2023). The fetuses were collected soon after delivery of spontaneous miscarriages & therapeutic legal abortions with the families' consent. The history of the fetus was collected from the labor ward of the OBGY Department of D Y Patil Hospital. After that, the fetus was preserved in 10% formalin for 10 days in the research lab of the Department of Anatomy. After approval from the institutional Ethics Committee for

Biomedical and health research D. Y. Patil School of Medicine, Navi Mumbai, fetuses were separated into 4 groups, Group A (13-16 weeks), Group B (17-20 weeks), Group C (21-24 weeks) and Group D (25-30 weeks) of GA. Vernier caliper was used to measure the morphometric parameters in this study. The thorax was dissected through a midline incision that went from the Jugular notch to the tip of the symphysis pubis. Transverse incision pass from the jugular notch along the clavicle to the acromion process. horizontal incision passes from the costal margin to the midaxillary line obliquely. The pleura, pericardium, and surrounding structures were visible. The lung along with the pleura was pulled out after cutting the content of the hilum of the lungs.

Cases having a deformity or anomaly were excluded from the study. The length of the lung anterior border, length of the lung posterior border, and base circumference of the lungs were dissected and measurements of all diameters were taken with the help of Vernier Caliper. Length of the lung anterior border in mm, measured from the lung apex to its base in its sternocostal projection. The length of posterior border of lung was measured from the apex to its base of the lung along sternocostal projection. Base circumference, measured in its diaphragmatic projection. Using the SPSS statistical tool, the means of the parameters concerning gestational age, sex, and groups were calculated. All parameters were statistically significant (p-value <0.05).

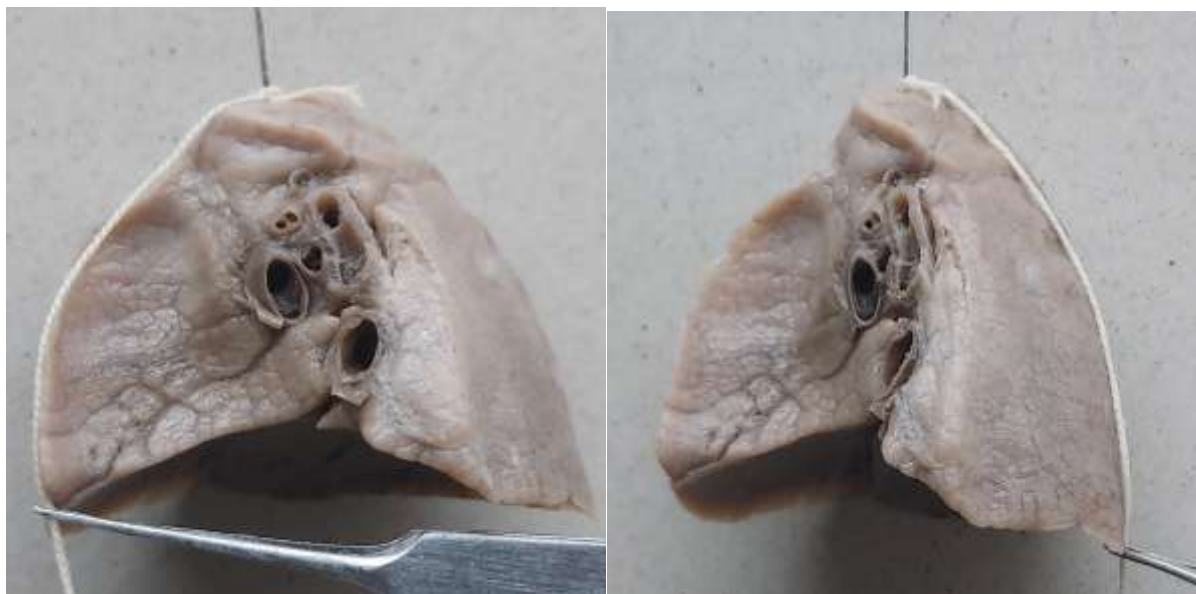


Fig No:01: - Length of the Anterior Border (measure by keeping thread from apex to base at anterior sharp border of lung)

Fig No:02: - Length of the Posterior Border (measure by keeping thread from apex to base at posterior blunt border of lung)

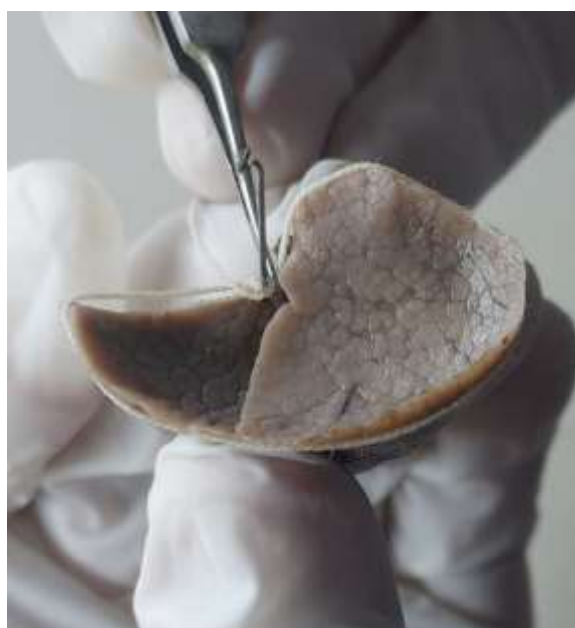

Fig No:03: - Basal circumference (measure by keeping thread around the border of inferior surface)

Observation & Results:

Table 1: Descriptive statistics of the measured parameters at different age groups (MI-minimum value, MA-maximum value)

Parameters	13-16 weeks		17-20 weeks		21-24 weeks		25-30 weeks		Total	
	MI. & MA.	Mean & SD	MI. & MA.	Mean & SD	MI. & MA.	Mean & SD	MI. & MA.	Mean & SD	MI. & MA.	Mean & SD
length of the anterior border	13.56 & 28.58	19.71 ± 5.57	17.44 & 29.62	23.43 ± 3.08	19.3 & 33.07	27.77 ± 4.11	22.61 & 35.62	30.62 ± 5.00	13.56 & 33.05	25.16 ± 35.62

length of the posterior border	12.88&30.68	21.45±5.63	18.58&3.23	23.72208±3.216	20.6&37.2	29.96±4.47	21.95&39.1	31.09±5.64	12.88&39.1	26.23±5.74
circumference of the base	33.42&74.88	55.529±14.196	44.79&88.37	61.519±12.82	34.49&99.16	76.98±16.74	54.82&108.15	84.71±18.96	33.42&108.21	68.62±18.31

Table 2: Pearson's correlation coefficients (r) and p values show statistically significant correlation for all the measured parameters.

Parameters	R-value	P-value
length of the anterior border(mm)	0.8639	<0.0001
length of the posterior border(mm)	0.9042	<0.0001
circumference of the base(mm)	0.80655	<0.0001

Table 3: Descriptive statistics of the measured parameters of males and females in different age groups (SD-Standard deviation).

Parameters	13-16 weeks		17-20 weeks		21-24 weeks		25-30 weeks	
	Male	Female	Male	Female	Male	Female	Male	Female
	Mean & SD	Mean & SD	Mean & SD	Mean & SD	Mean & SD	Mean & SD	Mean & SD	Mean & SD
length of the anterior border(mm)	20.455±6.070	18.62±3.53	23.139±3.22	23.052±2.86	27.791±4.4	26.92±4.4632	28.38±5.38	33.98±1.381
length of the posterior border(mm)	22.02±6.198	21.325±2.483	23.77±3.19	23.41±3.121	29.97±4.75	28.9275±4.46	29.55±7.08	33.39±0.407
circumference of the base(mm)	57.95±14.98	55.111±10.89	61.5±13.24	60.63±0.875	77.75±17.8	72.51±16.95	73.59±15.5	101.41±7.44

Table 4: The best-fit regression formulas for caudate and quadrate lobe of fetal liver

Parameter	Regression Formula
length of the anterior border(mm)	Y= 7.11+(0.89×GA in Weeks)
length of the posterior border (mm)	Y=8.844+(0.86×GA in Weeks)
circumference of the base (mm)	Y=15.36+(2.64×GA in weeks)

To ensure no data entry error, the data were organized in an Excel spreadsheet. In this study, the GA of the fetuses are ranging from 13 to 30 weeks. All received fetuses were divided into 4 Groups, Group A (13-16 weeks), Group B (17-20 weeks), Group C (21-24 weeks), and Group D (25-30 weeks). The values of each group were expressed as mean ±standard deviation. Descriptive statistics of the measured parameters at different age groups are shown in Table 1. Pearson's correlation was applied to assess the

correlation of the parameters measured with GA is given in Table 2. Descriptive statistics of the measured parameters of males and females in different age groups are shown in Table 3. There was a highly significant link showing that Lung parameters correlated with GA. The best-fit regression formulas for the length of the anterior border length of the posterior border and the circumference of the base of the fetal lungs are given in Table 4. The CRL ranged from 130.3 mm to 248.4mm. The size of the Length of the anterior border,

length of posterior border, and circumference of the base of fetal lungs increased with advancing gestational age and there were significant correlations between the gestational age of the fetus and the lungs parameters ($p < 0.001$).

During prenatal development, the mean length of the anterior border of the lungs ranged from 19.71 ± 5.57 mm in Group A to 28.38 ± 5.381 mm in Group D. This dimension increased respectively, length of the anterior border of lungs can be calculated by regression equation: $y = 7.11 + (0.89 \times \text{GA in weeks})$. During prenatal development, the mean length of the posterior border of the lungs ranged from 22.02 ± 6.198 mm in Group A to 29.55 ± 7.08 mm in Group D. This dimension increased respectively, length of the posterior border of lungs can be calculated by regression equation: $y = 8.844 + (0.86 \times \text{GA in weeks})$. During prenatal development, the mean circumference of the base of the lungs ranged from 57.95 ± 14.98 in Group A to 73.59 ± 15.57 mm in Group D. This dimension increased respectively, length of anterior border of lungs can be calculated by regression equation: $y = 15.36 + (2.64 \times \text{GA in weeks})$.

3. Discussion

Assessing the Normal lung growth is essential for tracking healthy fetal development. A study by Michal Szpinda *et al.* observed the length of the lung at the anterior border, posterior border, and the base circumference of lungs at 16-25 weeks GA. The fetuses that were retrieved were divided into three groups based on gestational ages: group A (16-18 weeks), group B (19-21 weeks), and group C (22-25 weeks). According to them, the mean and standard deviation of the length of the lung at the anterior border was (24.03 ± 3.61 mm, 30.53 ± 2.24 mm, and 38.19 ± 3.63 mm) in the right lungs and (26.64 ± 4.05 mm, 33.09 ± 4.26 mm, and 39.75 ± 6.67 cm) in the left lung at groups A, B, C respectively. They observed the length of the lung at the posterior border (25.17 ± 2.59 mm, 32.06 ± 3.79 mm, and 38.40 ± 2.69 mm) in right lungs and (26.77 ± 6.26 mm, 31.71 ± 2.83 mm, and 38.86 ± 4.49 mm) in left lungs at groups A, B, C respectively. The base circumference of the lungs was (59.97 ± 12.86 mm, 82.21 ± 10.49

mm, and 102.97 ± 14.78 mm) in the right lungs and (51.71 ± 10.40 mm, 68.29 ± 8.72 mm, and 82.25 ± 16.40 mm) in left lungs at groups A, B, C respectively. In the present study, we observe that the length of the fetal lung at the anterior border was (19.71 ± 5.57 , 23.432 ± 3.08 , 27.77 ± 4.11 , 30.62 ± 5.00 and 25.16 ± 35.62) in both lungs at groups A (13-16), B (17-20), C (21-24), D (25-30) and total samples respectively. The length of lungs at the posterior border was (21.45 ± 5.63 , 23.72208 ± 3.216 , 29.96 ± 4.47 , 31.09 ± 5.64 and 26.23 ± 5.74) in both lungs at groups A (13-16), B (17-20), C (21-24), D (25-30) and total samples respectively. Base circumference of fetal lungs were (55.529 ± 14.196 , 61.519 ± 12.82 , 76.98 ± 16.74 , 84.71 ± 18.96 and 68.62 ± 18.31) in both lungs at groups A (13-16), B (17-20), C (21-24), D (25-30) and total samples respectively. So, our study is similar to the study done by Michal Szpinda *et al.*⁹.

The early detection and timely implementation of remedial operations in the fetus with life-threatening congenital abnormalities of the respiratory system are the outcomes of advancements in perinatal medicine¹⁰.

To establish both normative and pathological criteria specific to fetal and neonatal respiratory structures, a thorough grasp of fetal quantitative anatomy is unquestionably necessary as a precursor¹¹⁻¹².

F. A. Gerards *et al.* observed that there was no evidence of a substantial gender difference in lung dimensions. In our study, we didn't get evidence to differentiate the gender of the fetus based on fetal lung dimensions¹³.

It is interesting that we discovered disparities between the right and left lungs for each of the three pulmonary parameters under consideration. As evidenced, the right lung's base circumference was larger while the length of anterior and posterior borders were larger in those of the left lung. The lengths of the anterior and posterior borders of the lung were significantly smaller on the right, likely due to the liver's limitations.

This project might benefit from our quantitative data from this study, which will serve as appropriate foetal age-specific benchmarks for pulmonary measurements. We

are optimistic that the normative data for the dimensions of the foetal lung gathered in this study will serve as the essential context for upcoming foetal autopsy and in-utero research.

The current article is the one of the very few in the field of medical literature to quantitatively assess the subject matters of lung measurements. The innovative growth patterns enable us to calculate the mean of the lung parameters according to the gestational age, which enhances our understanding of pulmonary quantitative morphology.

This could be particularly relevant for fetuses with pulmonary hypoplasia brought on by the conditions like renal malformations, oligohydramnios, fetal hydrops, skeletal dysplasia, congenital diaphragmatic hernia, intrathoracic masses, congenital adenomatoid malformation, bronchopulmonary sequestration, and cervical and sacrococcygeal teratomas¹⁴⁻¹⁵

Limitations

The morphometric study of the fetal lungs about their gestational age was carried out solely based on gross morphological aspects. In further studies, the research can be broadened by observing the histological appearance of cells by using modern technology.

4. Conclusion

Length of anterior border, length of posterior border and base circumference of the fetal lungs does not divulge sex difference. This study concludes that there is significant correlation between the length of anterior border, length of posterior border and base circumference of fetal lungs with gestational age. The outcome of this study will be valuable for the ultrasound examinations of the lung and evaluating fetal autopsy evidence. Anatomical dissection of fetal lungs provides more precise and reliable measurements data than the radiological methods.

5. References

1. Lung. Gray's Anatomy: The Anatomical Basis of Clinical Practice (E-Book), 41st edition. Standring S (edn.): Elsevier Limited, Amsterdam, The Netherlands, 2021, p. 927-929.
2. Dutta AK. Essentials of Human Embryology. 3rd edn. Calcutta (Current Books International), 2005, p. 51-57.
3. Keith L Moore. The Developing Human Clinical Oriented Embryology 11th Edition.
4. Dirksen U, Nishinakamura R, Groneck P, Hattenhorst U, Noguee L, Murray R, Burdach S. Human pulmonary alveolar proteinosis associated with a defect in GM-CSF/ IL-3/IL-5 receptor common beta chain expression. *J ClinInvest* 1997;**100**:2211-17.
5. Johannes C. Schittny . Development of the lung. DOI 10.1007/s00441-016-2545-0
6. Carla L. Avena-Zampieri, MRes; Jana Hutter, PhD; Mary Rutherford, MD, MRCPCH; Anna Milan, MD, PhD; Megan Hall, BSc(Hons), MRCOG; Alexia Egloff, MD; David F.A. Lloyd, MBChB, MRCPCH, PhD; Surabhi Nanda, MD, MDRes; Anne Greenough, MD, FRCP; Lisa Story, BMCh, MRCOG, PhD Assessment of the fetal lungs in utero doi.org/10.1016/j.ajogmf.2022.100693
7. Katharine Pike, J. Jane Pillow, Jane S. Lucas -Long term respiratory consequences of intrauterine growth restriction. [doi:10.1016/j.siny.2012.01.003](https://doi.org/10.1016/j.siny.2012.01.003)
8. Cox P, Marton T. Pathological assessment of intrauterine growth restriction. Best practice & research. *Baillière's Clin Obstet Gynaecol* 2009;**23**:751e64.
9. Michal Szpinda, Waldemar Siedlaczek , Anna Szpinda, Alina Wofniak, Celestyna Mila-Kierzenkowska, and Mateusz Badura-Quantitative Anatomy of the Growing Lungs in the Human Fetus. <http://dx.doi.org/10.1155/2015/362781>
10. Wolfgang Wagner, Michael R. Harrison-Fetal operation in the Head and Neck area DOI: 10.1002/hed.10083.
11. Michal Szpinda- Volumetric growth of the lungs in human fetuses: an anatomical, hydrostatic and statistical study DOI: [10.1007/s00276-014-1269-7](https://doi.org/10.1007/s00276-014-1269-7)
12. Michał Szpinda, Marcin Daroszewski, Alina Wozniak , Anna Szpinda ,Piotr

- Flisinski, Małgorzata Dombek, Celestyna Mila-Kierzenkowska, Waldemar Siedlaczek- Novel patterns for the growing main bronchi in the human fetus: an anatomical, digital and statistical study. DOI 10.1007/s00276-013-1145-x.
13. F. A. GERARDS, M. A. J. ENGELS, J. W. R. TWISK and J.M.G.VAN VUGT- Normal fetal lung volume measured with three-dimensional ultrasound
 14. E. A. Junior, P. S. de Oliveira, L. M. M. Nardoza et al., "Fetal lung volume in fetuses with urinary tract malformations: comparison by 2D-, 3D-sonography and magnetic resonance imaging," *The Journal of Maternal-Fetal&NeonatalMedicine*, vol. 23,no. 1, pp. 60–68, 2010.
 15. M. Cannie, J. C. Jani, F. de Keyzer et al., "Fetal body volume: use at MR imaging to quantify relative lung volume in fetuses suspected of having pulmonary hypoplasia," *Radiology*, vol. 241, no.3, pp. 847–853, 2006.