



Hematologic and cytogenic effects of induced aplastic anemia in female rats

Ghanem Taher Abdulrazzaq and Huda F. Hasan

College of Veterinary Medicine, University of Baghdad, Baghdad-Iraq

Department of Physiology, Biochemistry and Pharmacology

Abstract

The present study was aimed to estimate the hematologic and cytogenic effects of aplastic anemia induced by benzene. The study was performed on 90 female rats which divided into 2 groups, the 1st group was treated with benzene at dose of 1940 mg/kg orally for 15 days, while as 2nd group served as control (Placebo). Five male rats were taken randomly from each group and the complete blood picture, serum, serum IL-2 and cytogenic parameters were measured. The results revealed a significant decrease ($P \geq 0.05$) in the complete blood picture with significant increase ($P \leq 0.05$) in the serum IL-2 and all cytogenic parameters in treated group when compared with control group.

Keywords--- Aplastic anemia, cytogenic, bone marrow, benzene and female rats.

Introduction

Aplastic anemia is a condition characterized by progressive loss of hematopoietic progenitor stem cells (HPSC) causes pancytopenia and hypocellular bone marrow (BM), a trilineage bone marrow failure (BMF) that can be fatal (Meyers and Lachowiez, 2019). It was hypothesized that aplastic anemia entailed both a quantitative loss of stem cell numbers and a qualitative abnormality in stem cell function and was characterized by a loss or malfunction of HSPCs (Li and Hong, 2019).

Surprisingly, the three lineages descended from hematopoietic cells dramatically decreased in aplastic anemia, but adipocytes and non-hematopoietic cells proliferated more, resulting in hypocellular BM (Wang and Liu, 2019; Sweeney *et al.*, 2021). Furthermore, extensive research suggested that excessive adipogenesis harms aplastic anemia. In this respect, adipose tissue can be produced a variety of myelosuppressive cytokines, including TNF- α , IL-6, and IFN- γ , all of which are important hematological suppressors. In animal studies, excessive adipogenesis can actually prevent hematopoiesis from happening (Lu *et al.*, 2014).

Additionally, aplastic anemia has been reported with cytogenic abnormalities of several types (Aldarwish *et al.*, 2023). Clonal illnesses such as MDS, AML, and PNH may be developed from aplastic anemia. Cytogenic anomalies are common in aplastic anemia (Aldarwish *et al.*, 2023). In aplastic anemia, monosomy 7 is a karyotypic defect that frequently linked to leukomogenic transformation (Dumitriu *et al.*, 2015). Trisomy 8, 7q deletion, monosomy 7, trisomy 6, and 13q deletion revealed common cytogenic anomalies in aplastic anemia (Maciejewski *et al.*, 2004; Kim *et al.*, 2010; Kulasekararaj *et al.*, 2014). Notably, data

revealed that clones with a history of genomic instability were present in aplastic anemia instances that subsequently acquired MDS (Gonzaga *et al.*, 2017). According to some theories, aplastic anemia was generated by an autoimmune reaction against HSCs or progenitors in the BM, which can also cause a genetic mutation in the HSCs and lead to clonal expansion (Karauzum *et al.*, 2008; Mian and Bonnet, 2021). Trisomy, on the other hand, was discovered to be the most prevalent chromosomal anomaly (Gupta *et al.*, 2013; Aldarwish *et al.*, 2023). Obviously, in animal models, shorter telomeres and quicker telomere attrition in aplastic anemia led to an increase in chromosomal instability, aneuploidy, trisomy, nonreciprocal translocations and the development of malignancy (Dumitriu *et al.*, 2015; Young, 2018).

Materials and Methods

Experimental animals

This study was carried out at the animal house/ College of Veterinary Medicine/University of Baghdad. Thirty adult female rats (average weight 220g). Rats were reared in plastic cages in an air-conditioned area under appropriate environmental conditions of ($22 \pm 3^\circ\text{C}$) and relative humidity ($60 \pm 5\%$). The animals were given freshly prepared food and free use of the water supply.

Experimental design

The study was performed on 90 female rats which divided into 2 groups, the 1st group was treated with benzene at dose of 1940 mg/kg orally for 15 days, while as 2nd group served as control (Placebo) (Ata, 2015 and 2016; Hasan *et al.*, 2017). Five male rats were taken randomly from each group and the complete blood picture, serum, serum IL-2 and cytogenic parameters were measured.

Blood Sampling

At the end of the experimental period, the animals were anaesthetized with chloroform inhalation, and then euthanized, blood samples were obtained from the heart using disposable syringes (5 mL capacity). In addition, the required amount of blood was collected in two tubes, one of them contained EDTA-anticoagulant for hematological studies, and the second was a serum separator tube, which was centrifuged at 4000 rpm for ten minutes, and then isolated serum samples were stored in the freezer at -18°C until use in biochemical studies.

Detection of Blood picture

RBCs, Hb, HCT%, WBCs, PLT counts were estimated by using an automated hematology analyzer.

Biochemical Assessment

Serum IL-2 concentration was measured quantitatively by using Abcam's IL-2 rat ELISA kit (ab100769) (Kadasa *et al.*, 2015; AL-Samarrae, 2017).

Cytogenetic Study Assessment

The cytogenetic study was carried out by following parameters: Mitotic index (MI) in bone marrow performed according to method described by Shubber and Juma (1999), Al-Ani and Hasan, (2022). As well as, chromosomal aberration according to method of Lamberti, *et al.*

(1983), whereas micronucleus assay was conducted according to the method described by (Heddle and Salamone, 1981; Altaee *et al.*, 2013), .

Statistical analysis

The statistical analysis of the data was performed using SAS (Statistical Analysis System, version 9.1). A one-way ANOVA and least significant differences (LSD) post hoc test were performed to assess significant differences among means. $P \leq 0.05$ was considered statistically significant (Taher Abdulrazzaq and Hasan, 2019).

Results

Complete blood picture

The mean values of a complete blood count after induction of aplastic anemia are shown in table (1). The RBC, Hb, HCT%, WBC, and Plt were all significantly ($P \leq 0.05$) reduced with mean values of (4.13±0.35, 8.26±0.28, 29.10±2.55, 4.92±0.57, 409.24±68.8), respectively in comparison with control group.

Table (1): Complete blood picture of female rats with aplastic anemia after induction with benzene.

Parameters	Mean ± SE		
	Control	Induction	P-value
RBC ×10 ⁶ /ul	7.18±0.26	4.13±0.35	0.01**
Hb g/dl	13.42±0.59	8.26±0.28	0.01**
HCT %	39.74±1.83	29.10±2.55	0.01**
WBC ×10 ³ /ul	8.36±1.22	4.92±0.57	0.03*
Plt ×10 ³ /ul	890.24±111.68	409.24±68.81	0.01**

*Significant, **High significant, the benzene dose was 1940 mg/kg

Biochemical Assessment

Interleukin-2 concentration:

The IL-2 data are shown in table (2). When compared to the negative control group, the IL-2 in the positive control group had a significantly ($P \leq 0.05$) higher mean value (84.81±4.38).

Table (2): Effect of benzene on Interleukin-2 of female rats with induced aplastic anemia

Parameter Group	Mean ± SE
	IL-2 (pg./ml)
C-	26.22±1.67d
C+	84.81±4.38a
LSD	8.66

*Means with a small letter in the same column are significantly different ($P \leq 0.05$).

*C-: control negative; C+: control positive

Cytogenetic Study Assessment

The results of cytogenetic study (micronuclei %, mitotic Index%, and chromosomal aberration%) showed a highest significant increase in the positive group in comparison with negative control group as showed in table (3) and figure of (1 and 2).

Table (3): Effect of benzene on cytogenetic parameters (micronuclei %, mitotic Index, and chromosomal aberrations) in female rats with induced aplastic anemia.

Group Parameter		Mean ± SE		
		C-	C+	LSD
Mitotic Index%		2.07±0.27d	6.96±0.70a	1.44
Micronuclei %		3.12±0.49d	9.34±0.53a	1.01
chro mos omal aber ratio ns %	Dicentric	0.31±0.01c	0.74±0.01a	0.08
	Acentric	0.40±0.02c	0.66±0.02a	0.10
	Deletion	0.19±0.01c	0.69±0.03a	0.09
	Ring	0.22±0.02c	0.71±0.02a	0.08
	Aneuploidy	0.27±0.01e	0.80±0.03a	0.07

*Means with a small letter in the same column are significantly different ($P \leq 0.05$).

*C-: control negative; C+: control positive

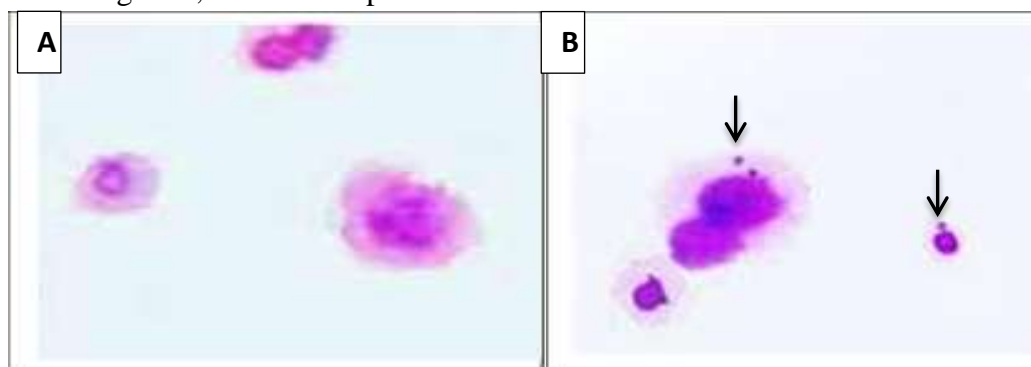


Figure (1): A) Normal micronuclei in negative control group rat BM cells; B) abnormally micronucleated positive control group rat BM cells (Giemsa, 100x).

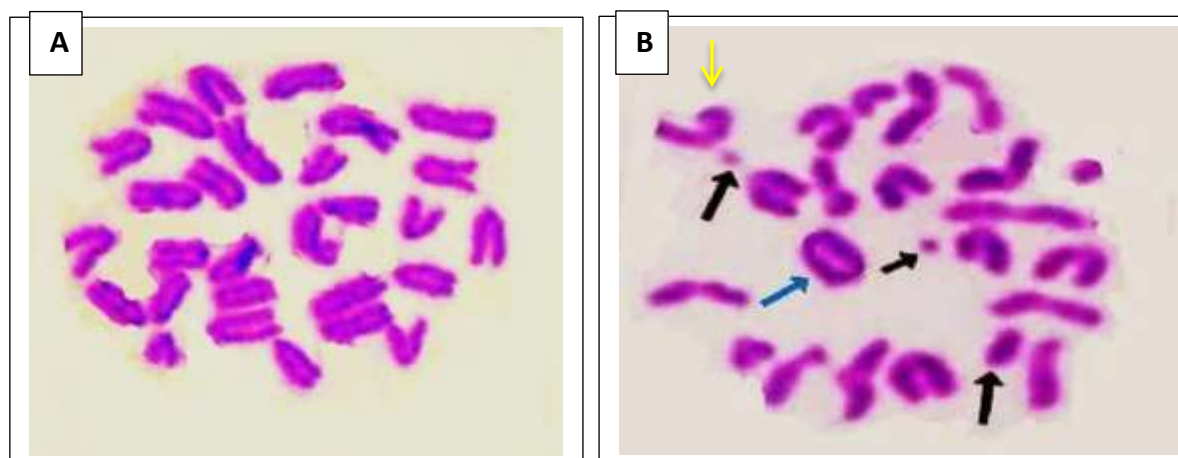


Figure (2): A) Normal metaphase chromosomes in negative control group rat BM cells; B) Multiple chromosome breaks (black arrow), ring chromosome (blue arrow) and

deletion chromosome (yellow arrow) in positive control group rat BM cells (Giemsa, 100x).

Discussion

The reduction in the blood profile of the positive control group was originally thought to indicate that plastic anemia associated with hematopoiesis-damaging effects, leading to the loss or destruction of HSCs, and that this resulted from the bone marrow's inability to replenish blood cells. As a result, the numbers of RBCs, WBCs, and platelets reduced to far below normal levels, as well as a profound hypocellular BM composed of fat cells and stroma (Rana *et al.*, 2010; De Bruin *et al.*, 2014).

In addition, immune deregulation has been found to be closely associated with the pathogenesis of aplastic anemia. deregulation of T cell response and its activation mediated BM suppression through increasing expression of the first apoptosis signal (Fas) receptor and through secretion of hematopoietic suppressing cytokine like IFN- γ TNF- α and IL-2, resulting in HSC immune-mediated destruction and can induce BM inhibition (Li *et al.*, 2004; Kakiuchi *et al.*, 2022). Interestingly, IL-2 stimulated the differentiation of T cells, leading to the destruction of HSC, which is the basis of acquired aplastic anemia (De *et al.*, 2019). It is worth mentioning that T-regulatory cells play a role in immune homeostasis, and there was also evidence that a dysfunction and/or deficiency of these cells can lead to the immune destruction of HSCs (Smith *et al.*, 2016; Skartsis *et al.*, 2023).

Also, cytokine-induced anemia may be due to the desensitization of erythroid progenitor cells to respond to Epo stimulation, postulated that failure of Epo utilization by the red cell-forming elements in the BM (Tsopra *et al.*, 2009). According to a study, IFN- γ disrupted hematopoiesis in aplastic anemia by competing with thrombopoietin for interaction with its receptor, myeloproliferative leukemia protein (c-MPL) (Shallis *et al.*, 2018; Alvarado *et al.*, 2019). IFN- γ also inhibited erythropoiesis by inhibiting HPSC differentiation and inducing IL-15 production, as well as by up-regulating Fas receptors on progenitor cells and increasing the production of reactive oxygen free radicals, which are harmful to progenitor cells (Schultz and Shahidi, 1994; de Bruin *et al.*, 2014).

Strikingly, Over-activated T-cells were linked to an increase in the adipogenic differentiation of MSCs, resulting in over-adipogenesis, which could be the primary cause of fatty BM, thereby negatively affecting hematopoiesis (Qu *et al.*, 2022). Obviously, aplastic anemia, characterized by a hypoproliferative reticulocyte count in the presence of a hypocellular BM, may result in ineffective erythropoiesis because reticulocytes provide a unique view of BM function and their level of production frequently associated with a BM condition (Carden *et al.*, 2020; Shimano *et al.*, 2021; Kulasekararaj *et al.*, 2023).

The elevation in IL-2 serum level in the positive control group was clearly attributed to immune dysfunction, which has been hypothesized to result from abnormal activation of T-helper 1 (Th1) cells and excessive production of hematopoietic negative regulatory cytokines such as IL-2 (Zhang *et al.*, 2017). In addition, it was reported that IL-2 could stimulate the activation, proliferation, and differentiation of many immune cells, including natural killer

(NK), B and T cells (Malek, 2008). So, IL-2 mainly produced by active T-cells and in turn affected the proliferation of T-cells and levels of IL-2 significantly increased in the blood of animals with aplastic anemia when compared to healthy control animals (Al-Hamadany, 2012; Dutta *et al.*, 2019; Javan *et al.*, 2021). Furthermore, when stimulated and differentiated, Th1 cells can produce IL-2 and IFN- γ and activate macrophages and CTLs, and their activity linked to the immune response in the BM compartment of the body, with the higher the level of IL-2, the stronger the immune response in both the BM and peripheral blood (De *et al.*, 2019).

The increment of micronuclei % and all other cytogenic parameters of the current study in the positive control group may have resulted from the fact that, in the presence of aplastic anemia, the higher production of ROS led to an increase in DNA damage, membrane lipid peroxidation, which were accompanied by a concurrent decline in antioxidants like glutathione (Qian *et al.*, 2012). As such, an accumulation of DNA damage in HSPC, this considered a factor responsible for the ageing and degeneration of the hematopoietic system and may be contributed to transformation and cancer development (Azawei *et al.*, 2009). Surprisingly, excess ROS has been proposed to play a role not only in DNA, protein, and lipid oxidative damage, but also in pathogenesis, drug resistance, and cytokine imbalance (Jamaluddin *et al.*, 2007). Promptly, in aplastic anemia, an autoimmune reaction against HSCs or progenitors in the BM was generated and could induce a genetic mutation that resulted in clonal expansion (Karauzum *et al.*, 2008; Mian and Bonnet, 2021). Furthermore, reactive oxygen free radical formation could accelerate telomere shortening by damaging not only the DNA that makes up telomeres but also the DNA building blocks used to extend them (Al-Zeiny *et al.*, 2020). Moreover, shorter telomere length and accelerated telomere attrition in cause increased chromosomal instability, aneuploidy, trisomy, nonreciprocal translocations, and progression to malignant evolution in mouse models (Dumitriu *et al.*, 2015; Young, 2018). Indeed, micronuclei are extra nuclear bodies that contain damaged chromosome fragments and/or whole chromosomes that were not incorporated into the nucleus after cell division, which could be caused primarily by defects in the cell repair machinery, the accumulation of DNA damage, and chromosomal aberrations (Al-Qaisi, 2000).

As well, many inflammatory cytokines, such as IL-8, IL-12, IL-17, IL-23, IL-27, and IL-2, were found to be significantly higher in aplastic anemia (Javan *et al.*, 2021). These cytokines affected the mitotic cycle, induced nitric oxide synthase and nitric oxide production by BM cells, which contributed to immune mediated cytotoxicity (Hirano *et al.*, 2003; Rodriguez *et al.*, 2019). Of note, nitric oxide has been shown to be a potent oxidant that can cause DNA damage and tissue injury, especially in BM tissue and DNA. Nitric oxide may also activate reactive oxygen intermediates such as superoxide anion, resulting in the formation of more toxic peroxynitrite and hydroxyl radicals that cause tissue injury, direct DNA damage, or telomere shortening, as well as contributing to genomic instability (Punjabi *et al.*, 1994; Jaiswal *et al.*, 2000; Vodenkova *et al.*, 2020).

Conclusion

Induction of aplastic anemia in the female rats with benzene demonstrated a significant reduction in the complete blood parameters with a statistical elevation in the IL-2 levels as well as all cytogenic parameters such as chromosomal aberration% and micronuclei %.

References

- Meyers, G., & Lachowicz, C. (2019). Aplastic anemia: diagnosis and treatment. *JCOM*, 26(5).
- Wang, L., & Liu, H. (2019). Pathogenesis of aplastic anemia. *Hematology*, 24(1), 559-566.
- Sweeney, R., Esmail, F., Mirza, K. M., & Nand, S. (2021). Hypercellular bone marrow in aplastic anemia: A case report of two patients. *Clinical Case Reports*, 9(11), e04845.
- Lu, X. C., Bo, Y. A. N. G., CHI, X. H., & YU, R. L. (2014). A novel etiology of aplastic anemia: the uncontrolled adipogenic differentiation of mesenchymal stem cells in bone marrow induced by an abnormal immunological reaction. *Medical Journal of Chinese People's Liberation Army*, 39(3), 173-179.
- Aldarwish, M., Alaithan, I., & Alawami, F. (2023). Aplastic Anemia in Triple X Syndrome. *Children*, 10(1), 100.
- Dumitriu, B., Feng, X., Townsley, D. M., Ueda, Y., Yoshizato, T., Calado, R. T., ... and Young, N. S. (2015). Telomere attrition and candidate gene mutations preceding monosomy 7 in aplastic anemia. *Blood, The Journal of the American Society of Hematology*, 125(4), 706-709.
- Al-Qaisi, B. I. (2000). STUDY THE EFFECT OF ADENOSINE DEAMINASE ENZYME IN INDUCES CYTOGENETIC AND HISTOPATHOLOGICAL CHANGES IN RATS SKIN AND EYES TREATED WITH SUMICIDIN. *The Iraqi Journal of Veterinary Medicine*, 24(2), 88-111.
- Risitano, A. M., Maciejewski, J. P., Green, S., Plasilova, M., Zeng, W., & Young, N. S. (2004). In-vivo dominant immune responses in aplastic anaemia: molecular tracking of putatively pathogenetic T-cell clones by TCR β -CDR3 sequencing. *The Lancet*, 364(9431), 355-364.
- Kim, S. Y., Lee, J. W., Lee, S. E., Cho, B. S., Kim, M., Eom, K. S., ... & Min, W. S. (2010). The characteristics and clinical outcome of adult patients with aplastic anemia and abnormal cytogenetics at diagnosis. *Genes, Chromosomes and Cancer*, 49(9), 844-850.
- Kulasekararaj, A. G., Jiang, J., Smith, A. E., Mohamedali, A. M., Mian, S., Gandhi, S., ... & Mufti, G. J. (2014). Somatic mutations identify a subgroup of aplastic anemia patients who progress to myelodysplastic syndrome. *Blood, The Journal of the American Society of Hematology*, 124(17), 2698-2704.
- Gonzaga, V. F., Wenceslau, C. V., Lisboa, G. S., Frare, E. O., and Kerkis, I. (2017). Mesenchymal stem cell benefits observed in bone marrow failure and acquired aplastic anemia. *Stem Cells Int*, 2017(8076529), 8076529.
- Karauzum, M. O., Arat, M., Ündar, L., & İlhan, O. (2008). Clonal evolution of monosomy 7 in acquired severe aplastic anemia: Two cases treated with allogeneic hematopoietic stem cell transplantation. *Turk J Hematol*, 25, 94-7.

- Mian, S. A., and Bonnet, D. (2021). Nature or nurture? Role of the bone marrow microenvironment in the genesis and maintenance of myelodysplastic syndromes. *Cancers*, 13(16), 4116.
- Al-Zeiny, S. S., AL-Rekabi, F. M., & Abbas, D. A. (2020). The Role of Oily and Methanolic Extracts of Phoenix Dactylifera Leaves in Ameliorating CCl₄ Cytotoxicity in Male Rats. *The Iraqi Journal of Veterinary Medicine*, 44(E0), 88-93.
- Gupta, V., Kumar, A., Saini, I., & Saxena, A. K. (2013). Cytogenetic profile of aplastic anaemia in Indian children. *The Indian Journal of Medical Research*, 137(3), 502.
- Young, N.S, (2018). Aplastic anemia. *N Engl J Med*. 379(17):1643-1656.
- Ata, S. I. E. (2015).Hematotoxicity and oxidative stress caused by benzene.Pyrex Journal of Biomedical Research, Vol.1, No.6, PP.074-080.
- Ata, S. I. E. (2016).Induction of aplastic anemia in experimental model.Coden IJABFP-CAS-USA. No.7, PP. 1
- Hasan, H. F., Krair, E. M. and Al-Halbosy, M. F. (2017). Evaluating Anti-Anemic Effect of Mesenchymal Stem Cells and Oxymetholone on Aplastic Anemia Induced in Mice. *Indian Journal of Natural Science*, 8(44):12714-12729.
- Kadasa, N. M., Abdallah, H., Afifi, M., & Gowayed, S. (2015). Hepatoprotective effects of curcumin against diethyl nitrosamine induced hepatotoxicity in albino rats. *Asian Pacific Journal of Cancer Prevention*, 16(1), 103-108.
- AL-Samarrae, I. A. (2017). Evaluation of interleukins (2, 6 and 8) in immunized white rats by Salmonella enterica subspecies typhimurium and Cryptococcus neoformans antigens: Ikram AA AL-Samarrae and Roaa NA AL-Maadhidi. *The Iraqi Journal of Veterinary Medicine*, 41(2), 72-6.
- Shubber, E. K., and Juma, A. S. M. (1999). Cytogenetic effects of plant extract of Urtica dioica on mouse somatic cells. *Nucleus-Calcutta-International Journal of Cytology*, 42(3), 182-187.
- Al-Ani, M. M., & Hasan, H. F. (2022). Cardiovascular and Cytogenetics Complications of Obesity Induced by Monosodium Glutamate in New Born Male Albino Rats. *NeuroQuantology*, 20(4), 104-112.
- Lamberti, L., Ponzetto, P. B., and Ardito, G. (1983). Cell kinetics and sister-chromatid-exchange frequency in human lymphocytes. *Mutation Research Letters*, 120(2-3), 193-199.
- Heddle, J. A., and Salamone, M. F. (1981). The micronucleus assay. I. In vivo. Short-term tests for chemical carcinogens. Springer, New York, NY, 243-249.
- Altaee, M. F., Nafee, S. K., & Hamza, S. J. (2013). Evaluation for the cytotoxic Effect of exotoxin a produced by Pseudomonas aeruginosa on mice by using cytogenetic parameters. *Curr. Microbiol*, 1, 257-261.
- Taherabdulrazzaq, G., & Hasan, H. F. (2019). Antagonistic effect of Avena sativa seeds crude extract to chlorambucil effect on fertility of female rats. *Biochemical and Cellular Archives*, 19(2), 3363-3370.

- Rana, C., Sharma, S., Agrawal, V., & Singh, U. (2010). Bone marrow angiogenesis in multiple myeloma and its correlation with clinicopathological factors. *Annals of hematology*, 89, 789-794
- De Bruin, A. M., Voermans, C., & Nolte, M. A. (2014). Impact of interferon- γ on hematopoiesis. *Blood, The Journal of the American Society of Hematology*, 124(16), 2479-2486.
- Li, W., Fu, J., Wang, F., Yu, G., Wang, Y., & Zhang, X. (2004). Distinct overexpression of Fas ligand on T lymphocytes in aplastic anemia. *Cellular & Molecular Immunology*, 1(2), 142–147.
- Kakiuchi, T., Eguchi, K., Koga, D., Eguchi, H., Nishi, M., Sonoda, M., ... & Matsuo, M. (2022). Changes in bone marrow and peripheral blood lymphocyte subset findings with onset of hepatitis-associated aplastic anemia. *Medicine*, 101(8): 1-7.
- Al-Hamadany, W. S. (2012). Radiation pollution in cancer and other diseases using some immunological and clinical parameters. *The Iraqi Journal of Veterinary Medicine*, 36(0E), 33-40.
- Javan, M. R., Saki, N., and Moghimian-Boroujeni, B. (2021). Aplastic anemia, cellular and molecular aspects. *Cell Biology International*, 45(12), 2395-2402.
- De, R., Dutta, A., Dolai, T. K., Ghosh, K., & Halder, A. (2019). Comparative study of bone marrow and blood plasma levels of IL-2 in aplastic anaemia and their relationship with disease severity. *Hematology*, 24(1), 84-88.
- Qian, L., Shen, J., and Cai, J. (2012). Hydrogen therapy may be an effective and specific novel treatment for aplastic anemia. *Medical Science Monitor: International Medical Journal of Experimental and Clinical Research*, 18(6), HY19.
- Azawei, B. I., Yassein, N. Y., Al-Khafaji, Z. M., & Hamed, S. N. (2009). Cytogenetic Studies on Groups Exposed to Pesticides in Baghdad. *Journal of Biotechnology Research Center*, 3(1), 44-49.
- Smith, M. T., Zhang, L., McHale, C. M., Skibola, C. F., and Rappaport, S. M. (2011). Benzene, the exposome and future investigations of leukemia etiology. *Chemico-biological interactions*, 192(1-2), 155-159.
- Skartsis, N., Muller, Y. D., & Ferreira, L. M. (2023). Regulatory T cell homeostasis: Requisite signals and implications for clinical development of biologics. *Clinical Immunology*, 246, 109201.