



EVALUATING THE EFFICACY OF *RANUNCULUS BULBOSUS* IN TREATING WARTS: A COMPREHENSIVE CASE STUDY

Ginu D Mohan^{1*}, Elavarasan S², Rejin R³, Flavia Annet George G⁴, Jeba Nesa Prabha⁵

Abstract

This study presents a case study of a girl suffering from warts on her right thumb finger and middle finger, highlighting the effectiveness of *Ranunculus bulbosus*, a single individualized homeopathic medicine, in her treatment. Warts are a common dermatological condition caused by the human papillomavirus (HPV), and their effective management is crucial to alleviate symptoms and enhance patient well-being. The case study describes the application of *Ranunculus bulbosus* 200c, administered with a repetition frequency adjusted according to the patient's specific requirements. The objective of this study is to appraise homeopathic professionals about the efficacy of individualized homeopathic treatment in wart management. Over the course of successive follow-ups, the girl exhibited noticeable improvement in her condition. The warts on her right thumb finger and middle finger showed signs of regression, indicating a positive response to the prescribed treatment with *Ranunculus bulbosus*. The therapy not only targeted the physical manifestations of warts but also aimed to address the underlying susceptibility of the individual. This case study serves as an instructive example, demonstrating the potential effectiveness of single individualized homeopathic medicines in the treatment of warts. The findings of this case study emphasize the importance of a holistic and patient-centered approach in wart management. By evaluating the specific symptoms, individual characteristics, and response patterns, homeopathic professionals can effectively determine the appropriate remedy and optimize treatment outcomes. Furthermore, the use of *Ranunculus bulbosus* as a potential therapeutic option for warts warrants further investigation and validation through larger-scale studies. This case study contributes to the existing knowledge base in homeopathic medicine and highlights the potential benefits of individualized treatment approaches for warts.

Keywords: Homeopathic, Individualized, Papillomavirus, *Ranunculus bulbosus*, Warts.

¹*Department of Repertory, Maria Homeopathic Medical College, Thiruvattar, Kanniyakumari District, Tamilnadu, E-mail: dr.ginu@gmail.com

²Department of Community Medicine, Sri Sairam Homoeopathy Medical College and Research Center, Chennai, Tamilnadu.

³Department of Practice of Medicine, Maria Homeopathic Medical College, Thiruvattar, Kanniyakumari District, Tamilnadu.

⁴Department of Human Anatomy, Maria Homeopathic Medical College, Thiruvattar, Kanniyakumari District, Tamilnadu.

⁵Department of Organon of Medicine, Maria Homeopathic Medical College, Thiruvattar, Kanniyakumari District, Tamilnadu.

***Corresponding Author:** - Ginu D Mohan

*Department of Repertory, Maria Homeopathic Medical College, Thiruvattar, Kanniyakumari District, Tamilnadu, E-mail: dr.ginu@gmail.com

DOI: - 10.48047/ecb/2023.12.si5a.0364

INTRODUCTION

Warts are a common dermatological condition that affects people of all ages and backgrounds. These small, benign skin growths are caused by the human papillomavirus (HPV), which can enter the body through cuts or breaks in the skin. Warts often appear on the hands, fingers, feet, and other areas of the body, taking various forms such as flat warts, common warts, plantar warts, or genital warts. While warts are generally harmless and painless, they can be unsightly and cause discomfort, especially when they appear in highly visible or sensitive areas. Conventional treatments for warts typically involve the use of over-the-counter medications, cryotherapy, or surgical procedures. However, an alternative approach to managing warts is gaining popularity—homeopathy¹.

Homeopathy is a system of medicine that originated in the late 18th century and is based on the principle of "like cures like." According to this principle, a substance that causes symptoms in a healthy individual can be used in a highly diluted form to stimulate the body's natural healing response and alleviate similar symptoms in a diseased individual. In the context of warts, homeopathic remedies are selected based on the specific characteristics of the individual's warts, as well as their overall health and constitutional makeup. These remedies are often derived from plant, animal, or mineral sources and are prepared through a process of potentization, which involves dilution and succussion (vigorous shaking). Homeopathic treatments for warts aim to strengthen the body's immune system and stimulate the body's innate ability to heal itself².

While scientific evidence on the efficacy of homeopathic treatments for warts is limited and conflicting, many individuals report positive experiences with these remedies. Homeopathy is considered a holistic approach to healthcare, focusing on the individual as a whole rather than solely targeting the symptom. It takes into account the individual's physical, emotional, and mental aspects, aiming to restore balance and promote overall well-being³.

It is important to note that homeopathic treatments should be pursued under the guidance of a qualified homeopath or healthcare professional experienced in homeopathy⁴. They can assess the individual's specific case, prescribe

appropriate remedies, and monitor progress over time. The various homeopathic remedies commonly used for managing warts. It might delve into the characteristics of different types of warts, discuss the underlying principles of homeopathy, and provide insights into how homeopathic treatments may support the body's natural healing process⁵. However, it is essential to consult with a healthcare professional before initiating any treatment and to consider a holistic approach that combines homeopathy with conventional medical care when necessary⁶.

MATERIALS AND METHODS

Case Presentation

A 23 year old girl presented with marked rough black pinpoint on the fingers of both hand since 3 months. They appear to be blackish like eruptions. These pinpoint eruptions are blackish in colour. She had itching around the area of eruptions on fingers which got aggravated on touch. After itching there was a burning sensation. On observation, there was no discharges from the eruption. She had taken allopathic treatment for this; but there was only temporary relief, and symptoms begin to reappear.

Past History

Nothing relevant

Family History

Nothing relevant

Homoeopathic Analysis

The common symptoms are scanty perspiration in the morning, Eruptions – hard, blackish on upper extremities, Itching eruption, Eruption without discharge and Painless eruption on fingers. The uncommon symptoms are Fear of dark, ghost, Wakes up in midnight due to fear, Dares not to be alone, Thirst increased in Afternoon, Blackish eruption on fingers of both hands, Itching <touch, and Burning sensation <scratching.

Homoeopathic Intervention

Homeopathic treatment of warts is largely through constitutional medicine, i.e., medicine selected based on comprehensive understanding of the patient by both generals and particular characteristic symptoms. As there are very few or no symptoms, morphology and location of the lesion can be consider in the selection of the medicine.

Table 1. Symptoms Evaluation and Totality Based on First Day for the First Prescription

| Mental Generals | Physical Generals | Particular |
|---|--|---|
| Fear of dark, ghost. Woke up in midnight due to fear. Dares not to be alone | Thirst increased in Afternoon. Scanty perspiration in the morning | Blackish eruption on fingers of both hands. Itching <touch. Burning sensation <scratching |

Table 2. Rearranging totality for the final selected remedy

| S. No | Repertorial totality |
|-------|---|
| 1. | Mind – Fear- Dark |
| 2. | Mind – Fear- Ghosts, of- Night |
| 3. | Mind- Company- Desire For |
| 4. | Stomach – Thirst- Afternoon |
| 5. | Extremities – Warts, Upper limbs, Fingers |
| 6. | Extremities – Eruption- Fingers-Itching |
| 7. | Extremities – Eruption- Fingers- Burning |

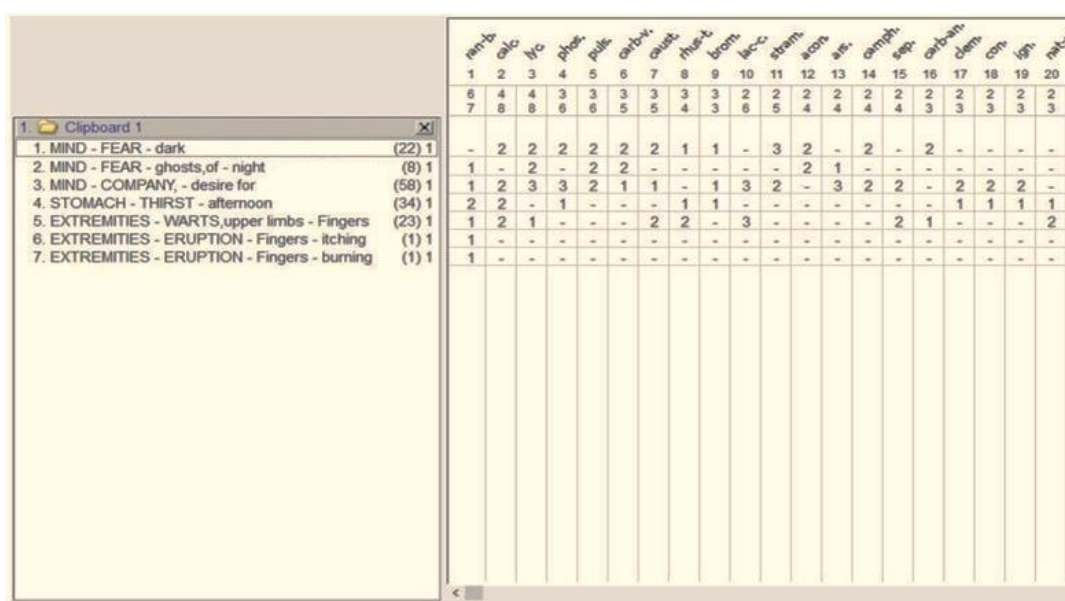


Fig 1: Repertorial Chart

Table 3: Repertorial Results

| S. No | Repertorial results |
|-------|---------------------------|
| 1 | Ranunculus bulbosus – 7/6 |
| 2 | Calcaria carbonica – 8/4 |
| 3 | Lycopodium clavatum- 8/4 |
| 4 | Phosphorus – 6/3 |
| 5 | Pulsatilla – 6/3 |
| 6 | Carbo veg – 5/3 |
| 7 | Causticum - 5/3 |
| 8 | Rhustox – 4/3 |
| 9 | Bromium -3/3 |
| 10 | Baryta carb -6/2 |

RESULTS AND DISCUSSION

After analysis and treatment of 2 weeks, based on the checklist and evaluation, each visit recorded improvement in symptoms of the patients and patient were too happy and satisfied, so the patient was kept on placebo for 1 more week and then stopped and till date, there had been no recurrence of symptoms.

Philosophy of prescription

Ranunculus bulbosus seems to be suitable for this case because after cross reference with Material Medica and Repertorization (Fig 1) it is the only remedy covers both generals and particular and Ranunculus bulbosus prescribed.

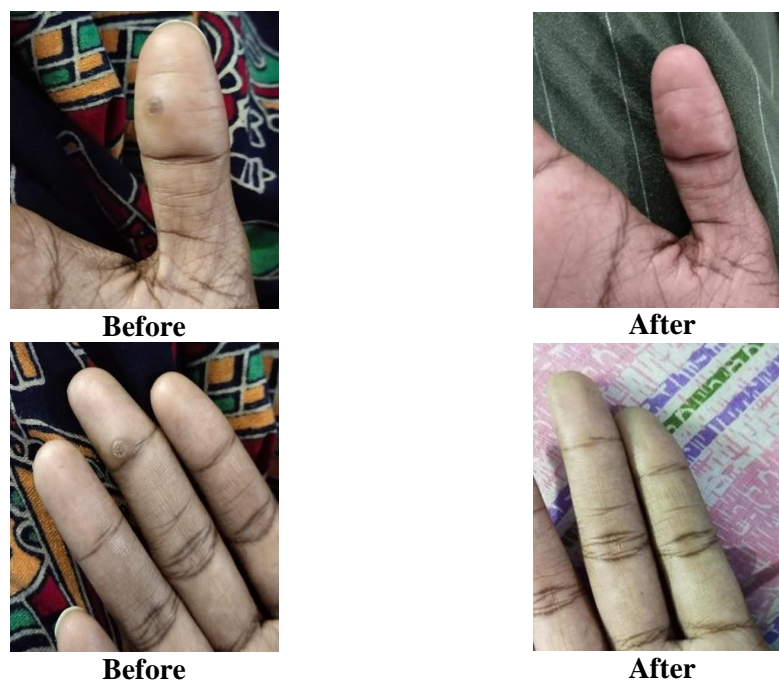

Fig 2: Before and After Treatment

Table 3: Chart of Medicines Prescribed and Regular Follow-up

| Follow-up | Date of prescription | Observation | Prescription |
|-----------|----------------------|--|-----------------------|
| Day 1 | 24/02/2022 | Fear of dark Wartson palms Itching<touch Burning<scratching Increased thirst in afternoon. | Rananculus200/1Dose |
| Day 2 | 3/03/2022 | Not much improved but slight differences is observed. Size of warts remain same. | Rananculus200/1Dose |
| Day 3 | 12/03/2022 | Eruption is completely gone. No itching at site of eruption. | Sacchrum Lachcum1dose |

In this case study the homoeopathic medicine were selected on the basis of individualization and this medicine was successful in the treatment of warts causing removal/dissolution of the warts and relief of associated symptoms of the patients. The selection of *Ranunculus bulbosus* depends upon the presenting totality including other general complaints present in the person and overall constitution. The patient continued the follow-ups for the next 2 months with no recurrence. The patient never complained about the side effects or any negative consequences. On comparing duration of illness with improvement outcome, it has been observed (**Fig 2**) that in case treated with 200 potency, the response to treatment was faster. It is therefore suggested that study can be undertaken to ascertain the efficiency of 200 potency in treatment of warts.

CONCLUSION

In conclusion, this case study highlights the effectiveness of individualized homeopathic

treatment in addressing the issue of warts in a young girl's right thumb finger and middle finger. The patient received treatment with *Ranunculus bulbosus* 200C, and the subsequent follow-ups revealed noticeable improvements. This case serves as an important reminder to homeopathic professionals about the potential of a single, well-selected homeopathic remedy in treating warts.

By tailoring the treatment to the specific symptoms and characteristics of the patient, homeopathy aims to stimulate the body's innate healing response. In this particular case, the use of *Ranunculus bulbosus* 200c proved to be beneficial, leading to positive outcomes and visible progress in the patient's condition. It is crucial for homeopathic professionals to consider the individuality of each patient, taking into account their unique symptoms, constitution, and overall health. This case study serves as an encouraging example, demonstrating the potential of homeopathy as a holistic and individualized

approach in treating various dermatological conditions such as warts.

Further research and case studies are warranted to deepen our understanding of the effectiveness of homeopathy in the treatment of warts and other similar conditions⁷. By sharing experiences and outcomes, we can continue to enhance our knowledge and provide better care to patients seeking alternative therapeutic options^{8, 9}.

REFERENCES

1. Shaikh M. Case studies for treatment of warts with Homoeopathy. *Indian Journal of Research in Homoeopathy*. 2016;10(4):272-8.
2. Vlahovic TC, Khan MT. The human papillomavirus and its role in plantar warts: a comprehensive review of diagnosis and management. *Clinics in Podiatric Medicine and Surgery*. 2016 Jul 1; 33(3):337-53.
3. Ruiz R, Silva GR, Menchaca HR. Focal epithelial hyperplasia. *The Lancet*. 2014 Jul 12; 384(9938):173.
4. Agrawal PG, Mahajan SA, Khopkar US, Kharkar VD. Epidermodysplasia verruciformis: an unusual malignant transformation. *Indian Journal of Dermatology, Venereology and Leprology*. 2013 Jan 1; 79:97.
5. Conrad EU. *Orthopaedic oncology: diagnosis and treatment*. Thieme; 2009.
6. Themes, U.F.O. (2017) Overview of epithelial barriers, *Basicmedical Key*. Available at: <https://basicmedicalkey.com/overview-of-epithelial-barriers/> (Accessed: October 20, 2022).
7. Boericke W. *Pocket manual of homoeopathic materia medica*. Motilal Banarsidass Publ.; 1993.
8. Hahnemann S. *Materia medica pura*. B. Jain Publishers; 1996.
9. Guernsey HN. *Key-notes to the Materia Medica*. FE Boericke; 1886.