



## **The Role of Nasal Sill Correction in Secondary Cleft Rhinoplasty**

**Dr. Aravind A. Vijayan, Dr Neethu Suresh,  
Dr Aswathy Susan Alexander**

Asst.Professor Dept of Dentistry Mount Zion Medical College Chayalode Adoor India

Reader, Dept of Periodontology PMS College of Dental Science & Research. Vattappara.  
Thiruvananthapuram

Junior Resident Dept of Dentistry Mount Zion Medical College

[draravindavijayan@gmail.com](mailto:draravindavijayan@gmail.com), [neethusuresh@ymail.com](mailto:neethusuresh@ymail.com) , [dr.aswathysalexander@gmail.com](mailto:dr.aswathysalexander@gmail.com)

### **Abstract**

**Background and Objective-** Evaluating outcomes after cleft rhinoplasty can be challenging because of the lack of objective measures that would lead to a more desirable outcome.

**Methods -** It was a retrospective record based study in which the data of age group between 12 to 21 years was considered for a period of 3 years from 2020 to 2022. The medical records of 35 patients having 90% complete and 10% incomplete unilateral cleft lip who underwent secondary cleft rhinoplasty conducted by single surgeon. Technique variations recorded from the operative reports where incision shape (stair step, v-shaped or closed incision) tip sutures, osteotomy technique, cephalic reduction technique additional excisions like (nasal web lateral vestibule or soft triangle excision) spread and the non spreader cartilage graft crushed nasal dorsum fraft in alloderm, type of septoplasty (extensive versus limited) and history of rhinoplasty.

**Results-** There were 30 patients who met our inclusion criteria: 10 males (66.7%) and 20 females (66.7%). Of these patients, 26 (86.7%) had a complete cleft lip and 4 (13.3%) had an incomplete cleft lip. The patients' average age at time of surgery was 16.2 years with a mean follow-up of 17.9 months. Subjective scores in both nasal and overall. Of all the objective measures, nasal sill ratio and cleft height to width ratio correlated with improved subjective ratings across multiple time points. It was seen that more than 90% of patients has very good experience in terms of nasal tip complex, symmetry of nose, shape of nose and airway obstruction and it was statistically significant ( $p < 0.05$ ).

**Conclusions -** Nasal sill correction in secondary cleft rhinoplasty is crucial for addressing functional and aesthetic concerns related to cleft lip and palate deformities. The nasal sill is an often overlooked, yet essential, part of creating an aesthetically pleasing nose during cleft rhinoplasty.

**Keywords-**Nasal sill, rhinoplasty, cleft lip, nasal deformities.

## **Introduction-**

In secondary cleft rhinoplasty, nasal sill correction plays an important role in achieving optimal functional and aesthetic outcomes. The nasal sill refers to the junction between the alar base (the sidewall of the nose) and the upper lip. It is commonly affected in patients with a cleft lip and palate, which can lead to asymmetry, nasal obstruction, and aesthetic concerns.<sup>1</sup> During secondary cleft rhinoplasty, the nasal sill may require correction for several reasons<sup>2</sup>:

**Alar base asymmetry:** Cleft lip and palate patients often have asymmetry in the nasal sill region, with one side being higher or wider than the other. Nasal sill correction aims to achieve symmetry by adjusting the shape, position, or volume of the alar base.

**Alar retraction:** Alar retraction is a common complication in cleft lip and palate patients. It refers to the elevation or retraction of the alar base, causing a notched or concave appearance. Nasal sill correction can address this issue by releasing the scar tissue, repositioning the alar base, and restoring a natural contour.

**Nasal obstruction:** The cleft lip and palate deformity can result in nasal airway obstruction due to abnormal anatomy, such as collapse of the nasal valve area or nasal vestibular stenosis. Nasal sill correction can help improve the nasal airflow by addressing these anatomical issues and widening the nasal passages.

**Aesthetic enhancement:** Nasal sill correction contributes to the overall aesthetic improvement in secondary cleft rhinoplasty. It helps refine the nasal shape, improve symmetry, and create a more harmonious nasal appearance. By addressing the nasal sill, the surgeon can achieve a balanced and natural-looking nose that complements the patient's facial features.

The specific techniques used for nasal sill correction may vary depending on the individual patient's needs and the surgeon's preferences. Common surgical approaches include alar base repositioning, scar tissue release, cartilage grafting, and soft tissue reconstruction. The surgeon will evaluate the patient's unique anatomy and consider their functional and aesthetic goals to develop a personalized surgical plan.<sup>3,4</sup>

It is essential for patients considering secondary cleft rhinoplasty, including nasal sill correction, to consult with a skilled and experienced plastic surgeon that specializes in cleft lip and palate reconstruction. They will assess the patient's condition, discuss the available options, and recommend the most appropriate approach to achieve the desired outcomes.<sup>5</sup>

## **Materials and Methods-**

It was a retrospective record based study in which the data of age group between 12 to 21 years was considered for a period of 3 years from 2020 to 2022. The medical records of 35 patients having 90% complete and 10% incomplete unilateral cleft lip who underwent secondary cleft rhinoplasty conducted by single surgeon.

### **Inclusion criteria-**

Age group between 12-21 years  
Written informed consent

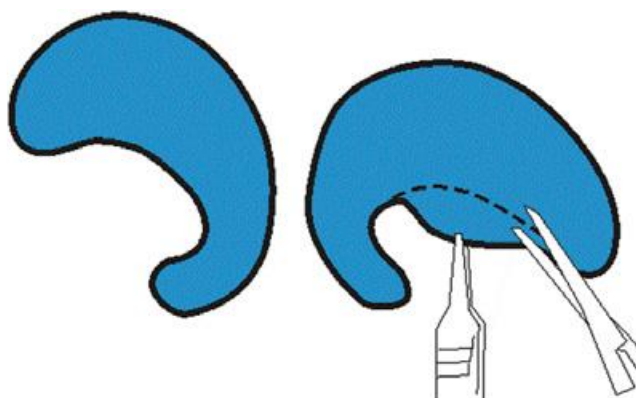
### **Exclusion criteria-**

<12 years and >21 years  
Not willing to give consent.

### **Methodology-**

Technique variations recorded from the operative reports where incision shape (stair step, v-shaped or closed incision) tip sutures, osteotomy technique, cephalic reduction technique additional excisions like (nasal web lateral vestibule or soft triangle excision) spread and the non spreader cartilage graft crushed nasal dorsum fraft in alloderm, type of septoplasty (extensive versus limited) and history of rhinoplasty.

Depending on the type and degree of the cleft nose deformity, the surgical procedure varies from patient to patient. When the columella can be advanced using the V transcolumellar incision, open rhinoplasty is frequently performed instead of using a stair-step transcolumellar incision. Through a marginal rim incision or an infra-cartilaginous incision, the lower lateral and upper lateral cartilages are revealed. The septum is exposed to the anterior nasal spine as a result of the separation of the lower lateral cartilages. While a thorough septoplasty involves operations on the bony septum, a limited septoplasty just required sub-mucus excision and caudal septum realignment. The tip defining sutures and tip craft when necessary enabled nasal tip refining. Alar base excisions were performed as appropriate.<sup>6</sup>



**Figure 1-** Diagrammatic representation of the noncleft (left) and cleft (right) alar cartilages in a patient with unilateral cleft lip nose deformity. The markings show the technique of semilunar caudal resection of the cleft alar cartilage.

Any residual asymmetries or cartilage sculpturing work was also carried out so as to restore a symmetrical nasal cartilaginous skeleton. Closure was commenced by suturing back the columellar flap. The area of the alar web was now addressed in terms of achieving symmetry by cartilage and skin work. First, the excess caudal border of the cleft lateral crus is excised according to the markings. Next, the amount of excess overlying skin of the web is assessed by in-rolling, and then the extent of horizontal and vertical resections is marked. This skin is then in-rolled after performing adequate resections in both the planes so that the folds in the skin are eliminated. Closure was then completed for the rest of the incision on both the sides. Bolster sutures were used to stabilize the new alar rim in the region of the alar web.<sup>7</sup>

### **Statistical Analysis-**

The statistical analysis was performed using SPSS for windows version 25.0. The findings were present in number and percentage analyzed by frequency, percent. Chi-square test was used to find the association among variables. The critical value of P indicating the probability of significant difference was taken as <0.05 for comparison.

## Results-

**Table 1- Demographic and Clinical details of subjects**

Parameters	Number (%)
Gender	Male
	Female
Complete lip	30
Incomplete lip	5
Average age at time of surgery	15.2 years
Follow up time	6.9 months

As per table 1 the study was female preponderance with 55%, males were 45%. 86% subjects had complete lip while 14% had incomplete lip. The age group in the study was 12-21 years. Average age at the time of surgery was 15.2 years and follow up time was 6.9 months.

**Table 2- Comparative dimensions of Cleft and Non-cleft alar cartilages**

Parameters	Non-cleft		Cleft		p-value
	Medial	Lateral	Medial	Lateral	
Length	17±5	18±3	15±5	18±4	0.11
Width	4±3	11±4	5±3	14±4	0.22
Angle	78±5		68±8		
Nasal sill ratio	1.5		1.8		0.32
Height to width ratio	2.5		2.7		0.10

As per table 2 all the patients underwent external transcolumellar rhinoplasty followed by uncovering of the nasal cartilaginous skeleton. There was increased fibromuscular tissue directly overlying the area of the cleft nasal cartilage. Comparative dimension between cleft and non-cleft alar cartilages were not significant ( $p>0.05$ ) in any parameters of length and width. Angle of non-cleft was higher than cleft.

**Table 3- Comparison between Pre-operative and Post-operative nasal deformities**

Parameters	Pre-operative	Post-operative	p-value
Nose length	2.6	2.4	0.01*
Columella height	2.8	2.6	0.01*
Nostril height	9.7	7.2	0.01*
Nostril width	8.2	6.4	0.02*
Nose width	11.5	8.5	0.01*

As per table 3 it was seen that all the parameters are statistically significant ( $p<0.05$ ) when comparison between pre-operative and post-operative nasal deformities was done. There was a decrease in all parameters in post-operative measurements which was significant.

**Table 4- Functional Outcomes of surgery**

Outcomes	Poor	Satisfactory	Good	Very good	p-value
Nasal tip complex	1	5	10	19	0.01*
Shape of nose	1	5	9	20	0.01*
Symmetry of nose	2	6	8	19	0.01*
Airway obstruction	1	2	2	30	0.01*

As per table 4 functional outcomes post-operative was evaluated. It was seen that more than 90% of patients has very good experience in terms of nasal tip complex, symmetry of nose, shape of nose and airway obstruction and it was statistically significant ( $p < 0.05$ ).

### Discussion-

Nasal sill correction in secondary cleft rhinoplasty plays a significant role in addressing both functional and aesthetic concerns associated with cleft lip and palate deformities. The nasal sill, which is the junction between the nostril and upper lip, can be affected by the primary cleft lip repair and subsequent growth and development.<sup>8</sup>

A consistent, frequent, and pervasive secondary nasal malformation is the alar web. The most challenging issue with correcting cleft lip and nose deformities has been recognized is the successfully achieved realignment of the alar cartilage to produce a symmetric nose. This is primarily caused by unilateral cleft lip and nose patients' cleft alar cartilage migrating caudally over the course of growth.

#### Functional Considerations<sup>9</sup>:

**Nasal Airway Obstruction:** Cleft lip and palate deformities can result in nasal airway obstruction due to inadequate growth and alignment of the nasal structures. Nasal sill correction aims to improve nasal airflow by addressing any obstruction caused by the nasal sill deformity.

**Alar Base Support:** The nasal sill provides support to the alar base, which is important for maintaining the proper position and shape of the nostrils. Nasal sill correction helps restore the alar base support, which in turn contributes to improved nasal function.

#### Aesthetic Considerations:

**Nostril Symmetry:** Cleft lip and palate deformities can lead to asymmetry and malpositioning of the nostrils. Nasal sill correction techniques can help achieve better symmetry by repositioning and reshaping the nostrils to create a more balanced and aesthetically pleasing appearance.

**Nasal Base Width:** The nasal sill influences the width of the nasal base. In secondary cleft rhinoplasty, nasal sill correction can address excessive or inadequate width, ensuring a proportional and harmonious nasal appearance.

**Scar Revision:** Secondary cleft rhinoplasty often involves scar revision, particularly at the nasal sill. Correcting any visible or palpable scars in the nasal sill area can improve the overall aesthetic outcome.

The compressor and dilator nares from the lateral and medial sides exercise differential pull resulting in the overgrowth and prolapse of the alar cartilage into the soft triangle area, an area where the cartilage meets with minimal resistance.<sup>10</sup> Besides the lateral and medial muscular pulls, the alar cartilage is also pulled down by the depressor septi through the septospinal ligament and the medial crus of the alar cartilage. Hypertrophy of the dilator naris anterior has been observed in the present series intraoperatively as evidenced by increased fibromuscular tissue overlying the cleft alar cartilage.<sup>11</sup>

These findings have been corroborated by elaborate cadaver study of Asian noses where the role of dilator naris in controlling alar lobule and shape is described. It is important to note that the specific techniques and approaches for nasal sill correction in secondary cleft rhinoplasty can vary depending on the individual patient's needs and the surgeon's expertise.<sup>12</sup> The choice of surgical techniques may involve procedures such as nasal sill excision, repositioning, or reconstruction using autologous grafts or other materials.<sup>13</sup>

Interesting observations have been made regarding the dimensions of the alar cartilage in secondary unilateral cleft lip nose deformity in the present study. A review of literature did not reveal any comparative report of the dimensions of the alar cartilages in cleft lip nose deformity. The cleft alar cartilage, besides being caudally dislocated, was found to be wider in the area of the lateral crus when compared with the opposite noncleft side.<sup>14</sup> The reason for this hypertrophy seems to be the influence of local muscles and abnormal growth in the area. It has been observed and demonstrated in cadaver noses that the dilator naris muscle originates from the upper lateral cartilage and inserts into the caudal margin of the lateral crus and alar lobule skin.<sup>15</sup> This muscle has been found to be hypertrophied, especially over the cleft alar cartilage in adult unilateral cleft lip nose deformity. This is evident by the fact that intraoperatively there has been a finding of excess of fibromuscular and fatty tissue directly over the surface of the lateral crus.

### **Conclusion-**

In conclusion, nasal sill correction in secondary cleft rhinoplasty is crucial for addressing functional and aesthetic concerns related to cleft lip and palate deformities. By improving nasal airflow, restoring alar base support, and enhancing nostril symmetry and nasal base aesthetics, nasal sill correction contributes to the overall success of the secondary rhinoplasty procedure and the patient's satisfaction with the final outcome.

**Conflict of Interest-** None declared

### **References-**

1. Stal S, Hollier LH Jr. Secondary deformities of the cleft lip, nose and palate. In: Mathes SJ, ed. *Plastic Surgery*, 2nd ed, Vol 4, Pediatric Plastic Surgery. Philadelphia: Saunders, 2016:339-364.
2. Agarwal R, Chandra R. The septospinal ligament in the cause of cleft lip nose deformity: study in adult unilateral clefts. *Plast Reconstr Surg* 2017;120:1633-1640

3. Agarwal R, Chandra R. The unrecognized skeletal components of the cleft lip nose deformity. *Plast Reconstr Surg* 2018;122:313-315
4. Agarwal R, Bhatnagar SK, Pandey SD. Nasal sill augmentation in adult incomplete cleft lip nose deformity using superiorly based turn over orbicularis oris muscle flap. An anatomical approach. *Plast Reconstr Surg* 2018;102:1350-1359
5. Bardach J, Salyer KE. Correction of secondary unilateral cleft lip deformities. In: Bardach J, Salyer KE, eds. *Surgical Techniques in Cleft Lip and Palate*. Chicago: Year Book 2017;225-246
6. Huffman W, Lierle D. Studies on the pathologic anatomy of the unilateral harelip nose. *Plast Reconstr Surg* 1949;4:225-234.
7. Davis PKB. Cleft lip nose tip deformity: a tutorial dissertation. *Br J Plast Surg* 2013;36:200-203
8. Holt GR. Management of cleft lip nasal deformity. *Facial Plast Surg* 2016;3:161
9. Straith CL. Reconstruction of the harelip nose. *Plast Reconstr Surg* 2016;20:455-465
10. Tajima S, Maruyama M. Reverse-U incision for secondary repair of cleft lip nose. *Plast Reconstr Surg* 2017;60:256-261
11. Cho BC. Correction of unilateral cleft lip nasal deformity in preschool and school-aged children with refined reverse-U incision and V-Y plasty: long term follow-up results. *Plast Reconstr Surg* 2017;119:267-275
12. Mulliken JB, Martinez-Perez D. The principle of rotation advancement for repair of unilateral complete cleft lip and nasal deformity: technical variations and analysis of results. *Plast Reconstr Surg* 2019;104:1247-1260
13. Noordhoff MS, Chen PK. Unilateral cheiloplasty. In: Mathes SJ, ed. *Plastic Surgery*, 2nd ed, Vol 4, *Pediatric Plastic Surgery*. Philadelphia: Saunders, 2001;165-216
14. Ducut EG, Han S-K, Kim S-B. Factors affecting nostril shape in Asian noses. *Plast Reconstr Surg* 2016;118:1613-1621
15. Reynolds J, Horton C. An alar lift in cleft lip rhinoplasty. *Plast Reconstr Surg* 2015;35:377-384