



Assessment of the Use of Injectable Calcium Phosphate Bone Cement as a Sinus Lifting Material with Simultaneous Implant Placement in comparison with Autogenous Bone Graft.

Short Running Title: Assessment of the Use of Injectable Calcium Phosphate Bone

Hassan TA¹, Aly TM², Bayoumi AM³, El-hawary HE⁴, and Ettish SM⁵

¹Professor of Oral and Maxillofacial Surgery, Faculty of Oral and Dental Medicine, Cairo University, Egypt.

²Professor of Oral and Maxillofacial Surgery, Dean of Faculty of Dentistry, AASTMT Al-Alamein University, Egypt.

³Professor of Oral and Maxillofacial Surgery, Faculty of Dentistry, Alexandria University, Egypt and King Abdul-Aziz University, Jeddah, KSA.

⁴Associate professor of Oral and Maxillofacial Surgery, Faculty of Oral and Dental Medicine, Cairo University, Egypt.

⁵ Specialist of Oral and Maxillofacial Surgery, King Abdul-Aziz University Hospital, Jeddah, KSA

Corresponding author e-mail: Sobhy_mohamed8@yahoo.com

Abstract

Objective of the present study was to evaluate the effect of calcium phosphate bone cement (calcibon) on bone formation in patients undergoing maxillary sinus lifting with simultaneous dental implant application. Twelve patients with partial posterior maxillary edentulism who needed sinus lift and bone augmentation were included in the study. The selected patients were randomly classified into two groups, each group had a total of 6 cases undergone sinus augmentation using lateral sinus lifting approach with simultaneous dental implant placement, where group A underwent sinus lifting simultaneous with implant placement, then an autogenous corticocancellous bone graft harvested from the chin was applied to the new sinus floor area around the implants, and group B undergone sinus lifting simultaneous with implant placement, then the injectable calcium phosphate bone cement was applied to the new sinus floor area around the implant. (Calcibon, Biomet Company, Berlin Germany). Group A showed better results than Group B according to the bone density results. Increase in the bone density at all the postoperative intervals. Autogenous bone graft enhances bone regeneration in sinus augmentation with simultaneous dental implant placement.

Keywords: Dental implant; calcibon; maxillary sinus augmentation; radiographic evaluation.

INTRODUCTION

The atrophied maxilla commonly presents with defects in alveolar bone volume for implant insertion. Missing of maxillary molars leads to fastening the rate of loss of alveolar bone and increases the maxillary sinus diameter causing a phenomenon known as sinus pneumatization. This may affect the alveolar bone height and width thereby decreasing the possibilities of future implant insertion in those sites (1-5).

Most surgical approaches include sinus graft material to increase available bone height, block graft to increase bone width, and other surgical methods to insert implants in areas with poor bone volume. Many studies have tried different types of bone graft material used in sinus bone grafting procedures. Current approaches in reconstructive surgery use autogenous, allografts, or biomaterials, although the restriction on all these techniques exists. These restrictions include donor site morbidity and storage for autografts, immunologic barrier for allografts, and the risk of transmitting infection (6-18).

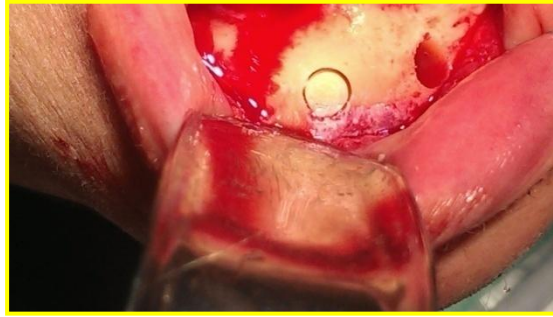
Seung -Lok Lee et al stated that insertion of implants in a correct 3-dimensional position is a guide to an esthetic result regardless of the implant system used. Long outcomes stability with beautiful gingival margins around implants and adjacent teeth can be done by facial bone with sufficient volume. This could be accomplished by using cone-beam CT in implant surgery. Cone beam machines can provide better resolution in images of high quality for diagnosis, with short times for scanning (10-70 seconds) and radiation hazards up to 15 times lower than those of medical and conventional scans(19-22).

MATERIAL AND METHODS

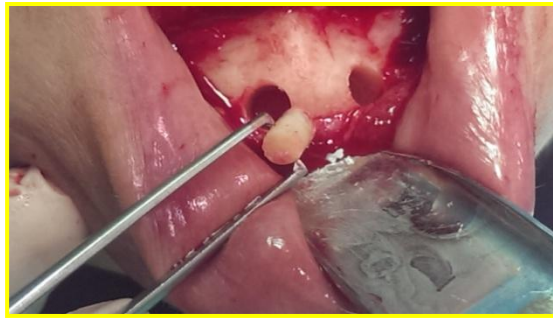Twelve patients with missing posterior maxillary who needed sinus membrane elevation , their ages ranged from 20-55 years old (2 males and 10 females),the patients were classified into two groups, each group had a total of 6 cases undergone sinus augmentation using open sinus lifting approach with coincident dental implant insertion where group A undergone sinus lifting simultaneous with implant placement, then an autogenous corticocancellous bone graft was taken from the chin was applied to the new sinus floor area around the implants , and group B undergone sinus lifting simultaneous with implant placement, then the injectable calcium phosphate bone cement was applied to the new sinus floor area around the implant. (Calcibon, Biomet Company, Berlin Germany).

Preoperative orthopantomogram and postoperative serial radiographs were taken using cone beam CT.

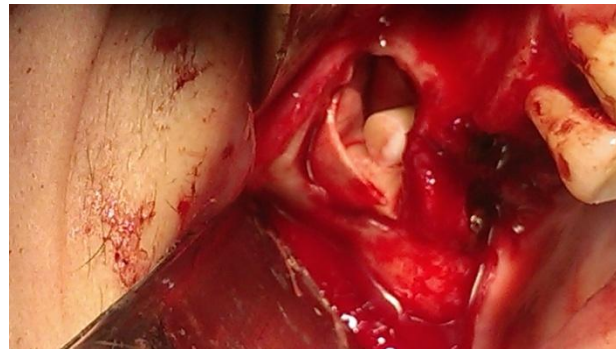Group A case:



The trephine bur cutting.

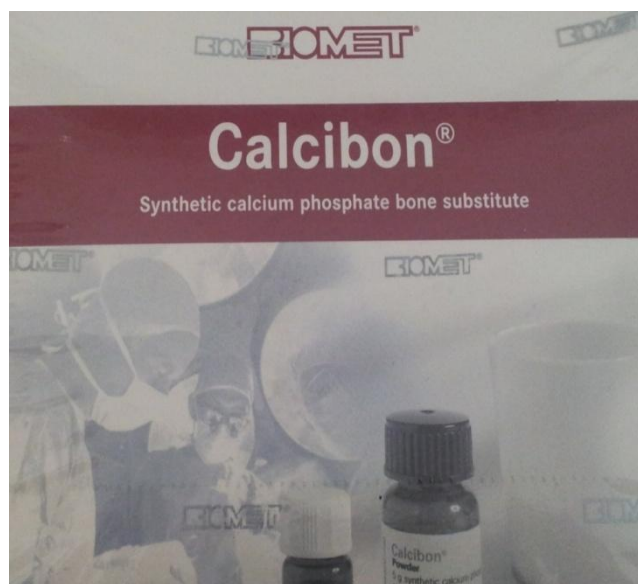


The pick-up of the autogenous bone.

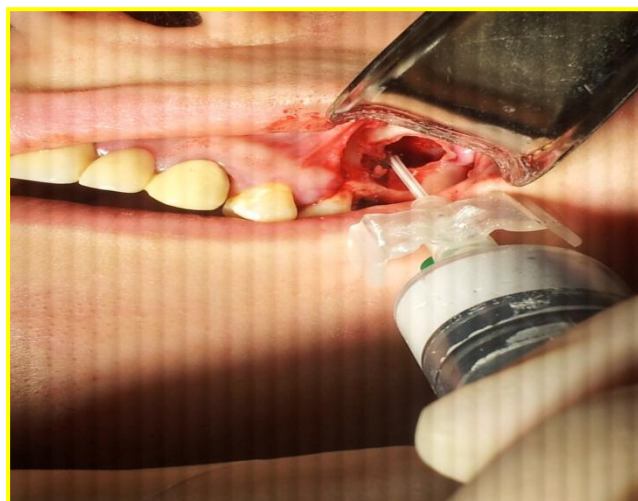

The application of autogenous bone in the sinus cavity after implant insertion.

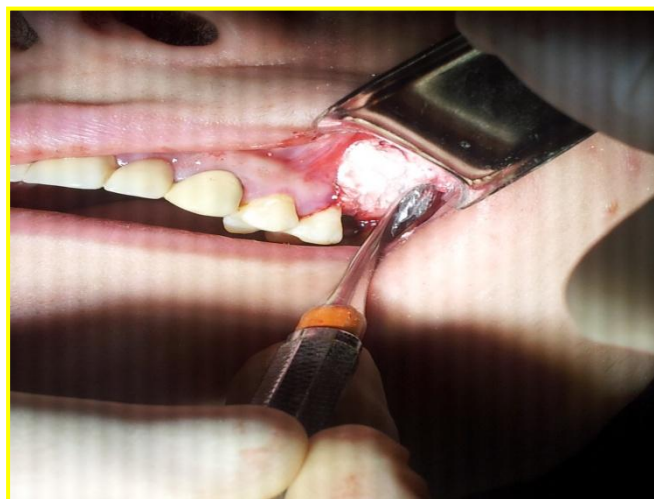Group B case:



Synthetic calcium phosphate bone cement.



The injection of calcibon in the sinus cavity.



The application of calcibon in the sinus cavity after implant insertion.

Postoperative cone beam CT radiographs were carried out for each patient at 3, 6 & 9 months. Bone density analysis was performed using a digital computerized program ranged from (0 to 250 degrees), where the numerical value 0 degree was the darkest and the numerical value 250 degree was the lightest, digital density results were obtained. The density of the bone formed was measured by a computerized technique as we chose five points at definite locations on the CBCT radiograph that were in close proximity to implant threads (namely P1, P2, P3, P4, and P5). Two of these points (P1, P5) were selected at a more coronal level near to the crest of the alveolar ridges one mesially and one distally.

The other three points (P2, P3, P4) were usually chosen in the lower half of the implant one mesial (P2), one distal (P4), and the (P3) was apical to the fixture. The computer translates the degree of lightness (luminance) at each chosen point into a numerical value. This value was compared to one of the two reference points namely the "Rb", which is the reference point that shows the numerical value of the neighboring normal bone. The second reference point is the center of the implant "Rc". This point is especially valuable in assisting to avoid any discrepancies in the radiograph films regarding their diagnostic quality.

RESULTS:

In this study, 12 patients who had missing maxillary posterior tooth with a low bone height below the floor of the maxillary sinus secondary to sinus pneumatization were selected. Their ages ranged from 20-55 years old (2 males and 10 females). The mean height of the alveolar ridge from the marginal crest to the inferior border of the maxillary sinus was ranged from 3-6.5mm.

In all 12 patient's implants placed immediately after the open approach procedure to create a maxillary sinus lift, no patients developed sinus inflammation or other complications leading to an implant failure after the sinus lifting-combined implant insertion in group A. While 3 implant fixtures with mobility were observed at 6-9 months before loading started from the prosthetic part in group B.

Clinical Results:

Table (1): summarizes the clinical results obtained in group A during the postoperative follow-up period.

Patient Parameter	Group A					
	C1	C2	C3	C4	C5	C6
Pain index in the first week	Slight	Slight	Slight	Slight	Slight	Slight

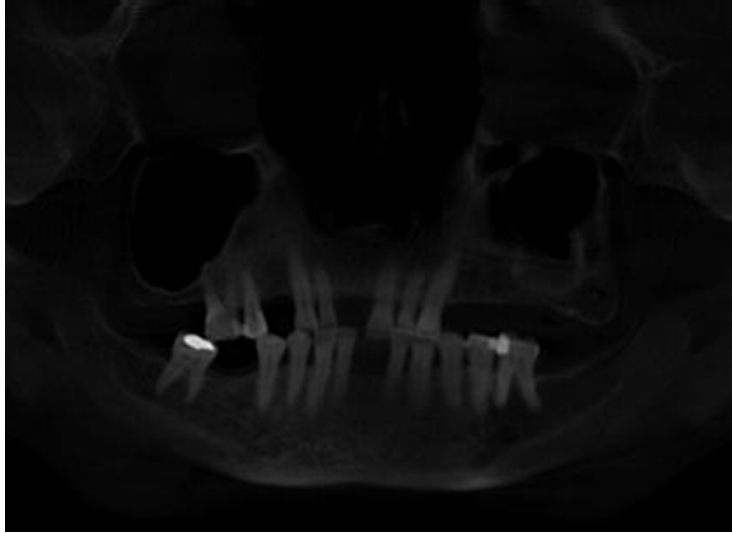Presence of tenderness or swelling in 1 st week	Accepted	Accepted	Accepted	Accepted	Accepted	Accepted
Presence of sinusitis	Non	Non	Non	Non	Non	Non
Pus and/or bad odour	Non	Non	Non	Non	Non	Non
Dehiscence of the wound	Non	Non	Non	Non	Non	Non

Table (2): summarizes the clinical results obtained in group B during the postoperative follow-up period.

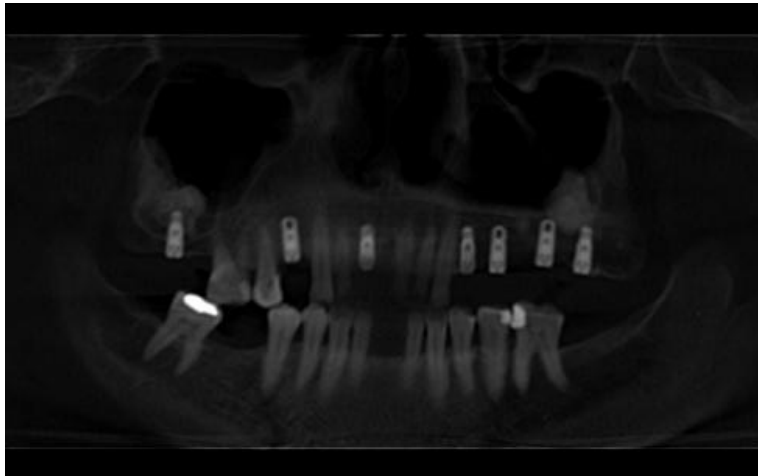
Patient Parameter	Group B					
	C1	C2	C3	C4	C5	C6
Pain index in the first week	moderate	moderate	moderate	Slight	Slight	Slight
Presence of tenderness or swelling in 1 st week	presented	presented	exaggerated	Accepted	Accepted	Accepted
Presence of sinusitis	Non	Non	Non	Non	Non	Non
Pus and/or bad odour	Non	Non	Presented	Non	Non	Non
Dehiscence of the wound	Non	Non	Presented	Non	Non	Non

Radiographic Results:

GROUP B



Preoperative panoramic radiograph showing bilateral maxillary atrophy.



Nine months postoperative CBCT showing a panoramic view

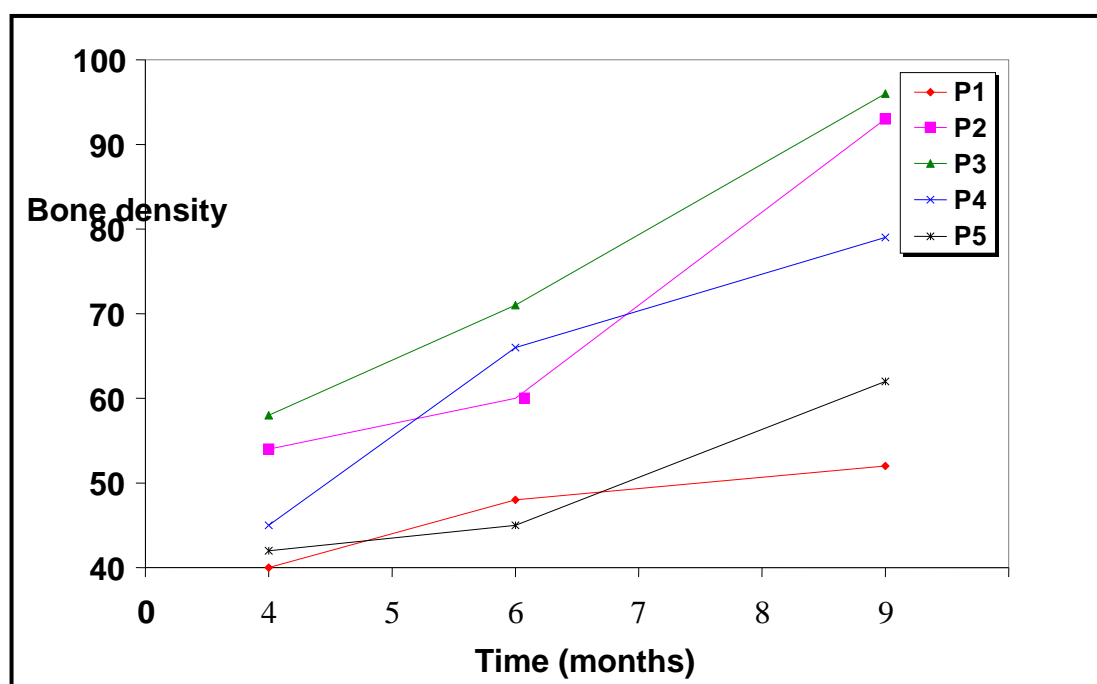
Case (1) Group A

Table (3) summarizes the radiographic results of the bone density obtained during the 9 months postoperative follow-up period in group A.

Case 1
Table (3)

(Group A)

Month \ Density	3	6	9
P ₁	40	48	52
P ₂	54	60	93
P ₃	58	71	96
P ₄	45	66	79
P ₅	42	45	62



Graph 1

Figure 1: summarizes the increasing of the bone density obtained during the 9 months postoperative follow-up period in group A.

Case (2) Group B

Table (4)

Summarizes the radiographic results of the bone density obtained during the 9 months postoperative follow-up period in group B.

Months Density	3	6	9
P ₁	54	55	55
P ₂	56	53	50
P ₃	63	60	56
P ₄	61	59	52
P ₅	45	42	40

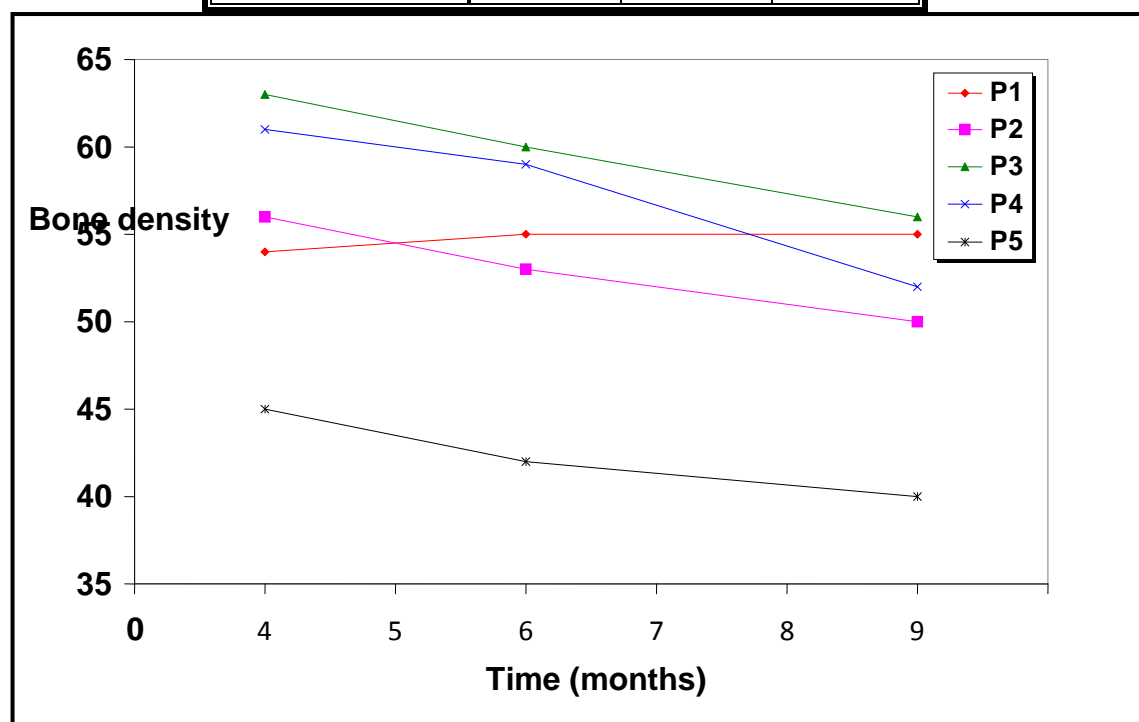


Figure 2: summarizes the decreasing of the bone density obtained during the 9 months postoperative period in group B.

DISCUSSION

This study was conducted to assess the use of calcium phosphate bone as a sinus grafting material in sinus lift operations with simultaneous implant placement in comparison to the autogenous bone graft.

The autogenous bone graft as a grafting material had shown a good result regarding the healing and volumetric changes of the graft in comparison with calcium phosphate bone cement.

Answering important questions regarding the sinus augmentation material procedures, however the predictable nature of sinus augmentation operation with coincident implant insertion, with having a variety of autogenous/artificial bone materials, and the ability of success over time is the main goal for all the clinicians.

CONCLUSION

It is confirmed that different materials can be used safely as a sinus augmentation material, the choice should be directed to the use of the autogenous bone if possible as it is still the gold standard bone graft material.

The placement of the implant using the lateral window technique was a predictable and safe procedure for both patients and surgeons in comparison with other techniques.

The autogenous bone graft had shown good results with the new bone morphogenetic protein.

REFERENCES

- 1-Rosen MD, Sarnat BG. (1955). Change of volume of the maxillary sinus of the dog after extraction of adjacent teeth. *Oral Sur Oral Med Oral Pathology*; 8: 420–9.
- 2-Tatum H Jr. (1986). Maxillary and sinus implant reconstructions. *Dent Clinical North Am*; 30:207-29.
- 3-Chanavaz M. (1990). Maxillary sinus: anatomy, physiology, surgery, and bone grafting related to Implantology – eleven years of surgical experience (1979–1990). *J Oral Implant*; 16: 199–209.
- 4-Al-omar A, Alqahtani S, Alsheraimi A, Alshareef A, Alsaban R, Almagran M, Eldesouky M Maxillary sinus pneumatization following Extraction in Riyadh, Saudi Arabia: *Cureus*. 2020 Jan 9; 12(1):e6611.
- 5-Shin SI, Lim HC, Kim DH, Herr Y, Chung JH .Factors affecting maxillary sinus pneumatization following posterior maxillary tooth extraction *J Periodontal Implant Sci* 2021 Aug;51(4):285-295.

- 6-Misch CE. (1987). Maxillary implants: organized alternative treatment plans. *J Oral Implantology*; 449-58.
- 7-Block MS, Kent JN. (1997). Sinus augmentation for dental implants: the use of autogenous bone. *J Oral Maxillofacial Surgery*; 55:1281-6.
- 8-Imbronito AV, Scarano A, Orsini G, Piattelli A, Arana-Chavez VE. (2005). Ultrastructure of bone healing in defects grafted with a copolymer of polylactic/polyglycolic acids. *J Biomed Mater Res A*; 74:215-21.
- 9-Wheeler SL, Holmes RE, Calhoun CJ. (1996). Six-year clinical and histologic study of sinus lift grafts. *International J Oral Maxillofacial Implants*; 11:26-34.
- 10-Szabo G, Huys L, Coulthard P, Maiorana C, Garagiola U, Barabas J, Nemeth Z, Hrabak K, Suba Z. (2005). A prospective multicenter randomized clinical trial of autogenous bone versus beta-tricalcium phosphate graft alone for bilateral sinus elevation: histologic and histomorphometric evaluation. *International J Oral Maxillofacial Implants*; 20:371-81.
- 11-Tadjoedin E, de Lange G, Layruu Luit Kuiper D, Burger E. (2002). High concentrations of bioactive glass material (BioGran®) vs. autogenous bone for sinus floor elevation. *Clinical Oral Implantology Res*; 13: 428-36
- 12-Nishibori M, Betts NJ, Salama H, Listgarten MA. (1994). Short-term healing of autogenous and allogeneic bone grafts after sinus augmentation: a report of two cases. *J Periodontal*; 65:958-66.
- 13-Wetzel AC, Stich H, Caffesse RG. (1955). Bone apposition onto oral implants in the sinus area filled with different grafting materials. A histological study in beagle dogs. *Clinical Oral Implantology Res*; 6:155-63.
- 14-Kent JN Blocks MS. (1989). Simultaneous maxillary sinus floor bone grafting and placement of hydroxyapatite-coated implants. *J Oral Maxillofacial Surgery*; 47:238-242.
- 15- Lustmann J, Lewinstein L. (1995). Interpositional bone grafting technique to widen narrow maxillary ridge. *International Oral Maxillofacial Implants*; 10: 568-577.
- 16-Natash Bhalla and Harry Dym. Update in Maxillary Sinus Augmentation. *Den Clinic North America*. 2021 Jan; 65(1):197-210 doi: 10-1016)
- 17-Salgar N. Osseodensified Crestal Sinus Window Augmentation an Alternative Procedure to the Lateral Window Technique. *J Oral Implantol*. 2021Feb.1; 47(1):45-55.doi:10.1563.

18-Haider ZS, Damsaz M, Castagnoli CZ et al Evidence Based Clinical Efficacy of Leukocyte and Platelet Rich Fibrin in Maxillary Sinus Floor Lift .Front Surg. 2020 Nov 24; 7: 537138.)

19-Seung-Lok Lee; Hee-Jung Kim; Mee-Kyoung Son and Chae-Heon Chung (2010). Anthropometric analysis of maxillary anterior buccal bone of Korean adults using cone-beam CT. J Adv. Prosthodont. 2; 92-96.

20-Scarfe, W.C; Farman, A.G. and Sukovic, P. (2006). Clinical applications of cone-beam computed tomography in dental practice. J Can Dent Assoc. 72; 75-80, 2006.

21-Attansio F et al. Flapless Cone Beam Computed Tomography-Guided Implant Surgery with Contextual Transcrestal Sinus Lift Augmentation Using New Bone Compactor Tools. Case Rep Dent.2020 Dec 7; 2020: 8873234.

22-Jacops R et al .Cone beam computed tomography in dento-maxillofacial radiology: a two-decade overview. Dento-maxillofacial Radiology .2020 Dec; 49(8):20200145.