



Ultrasonographic evaluation of morphometry of spleen in adult north Indian population

¹Dr. Anamika Gaharwar, ²Dr. Vineeta Tewari, ³Jay Tewari, ⁴Dr. Shema Nair,
⁵Dr. Prince Kapoor

¹Associate Professor, Department of Anatomy, Ram Manohar Lohia Institute of
Medical Sciences, Gomti nagar, Lucknow, Uttar Pradesh, India

²Professor, Department of Anatomy, Era's Lucknow Medical College, Lucknow, Uttar
Pradesh, India

³MBBS Student, Final Year, King George Medical University, Lucknow, Uttar
Pradesh, India

⁴Professor, Department of Anatomy, L.N. Medical College and Research Center,
Bhopal, Madhya Pradesh, India

⁵Assistant Professor, Department of Anatomy, Era's Lucknow Medical College,
Lucknow, Uttar Pradesh, India

Corresponding Author: Dr. Anamika Gaharwar

Email: dranamikagaharwar@gmail.com.

Article History : Received: 14.12.2022 Revised: 27.01.2023 Accepted: 16.03.2023

Abstract

Background: The spleen is the lymphoid organ which is intraperitoneal and situated in left upper quadrant of abdominal cavity between the fundus of the stomach and the diaphragm where it is entirely covered by the inferior thoracic rib cage. The present study was conducted to assess morphometry of spleen in normal adult population as changes in splenic size and volume, splenomegaly is related to many clinical and pathological conditions.

Materials & Methods: 124 adult subjects between 25-60 years of age of both genders were included in our study. Dimension of spleen-length, width and thickness and volume were calculated using ultrasonography.

Results: Out of 124 subjects, 70 were males and 54 were females. The mean length of spleen in males was 10.4 cm and in females was 10.1 cm, width was 6.2 cm and 5.8 cm, thickness was 4.5 cm and 4.2 cm and volume was 112.6 cm³ and 110.4 cm³ in males and females respectively.

Conclusion: Our present study concluded that splenic dimensions including length, width, thickness and volume were more in males than females.

Keywords: Spleen, splenomegaly, ultrasonography

Introduction

The spleen is the largest lymphoid organ located in the left hypochondrium between the fundus of the stomach and the diaphragm where it is entirely covered by the inferior thoracic rib cage. It extends from the 9th–11th ribs on the left side with its long axis runs parallel to the 10th rib.¹ Its shape is ovoid-like with a convex outer diaphragmatic surface and an indented inner visceral surface related to the stomach, left kidney, pancreatic tail, left suprarenal gland and left colic flexure. The apex lies in line with the spine of the 10th thoracic vertebra about 4 cm from the midline and the base does not descend beyond the mid axillary line.²

The average dimensions of the spleen are 12.5 cm, 7.5 cm and 2.5 cm in length, width and thickness respectively and 150-200 g in weight, but its dimensions vary considerably.³ The literature revealed that spleen dimensions are affected by geographical differences, races, nutritional status and anthropometric measurements.⁴ There are many modes of investigation to identify the enlarged spleen e.g.-plane radiograph, ultrasonography, computed tomography, MRI and radionuclide scan.⁵ Out of these modalities sonography and computed tomography are most reliable for intraabdominal organs. Various studies were done by sonography to study the linear dimension of spleen-length, width and thickness.⁶ The present study was conducted to assess morphometry of spleen in adult population.

Materials & Methods

The present study consisted of 124 adult subjects of both genders. Our study was conducted in the Department of Anatomy and Radiology Era medical college, Lucknow, UP, India, from Jan 2022 to December 2022. All gave their written consent to participate in the study.

Data such as name, age, gender etc. was recorded. During examinations, history and physical examination of individuals were taken. All linear dimension of spleen-length, width and thickness and volume were calculated and they were analysed with body habitus-Age, height, weight, BSA (body surface area) and BMI (body mass index) was calculated by linear and non-linear regression model to know exact pattern of correlation. Data thus obtained were subjected to statistical analysis. P value < 0.05 was considered significant.

Results

Table I: Distribution of patients

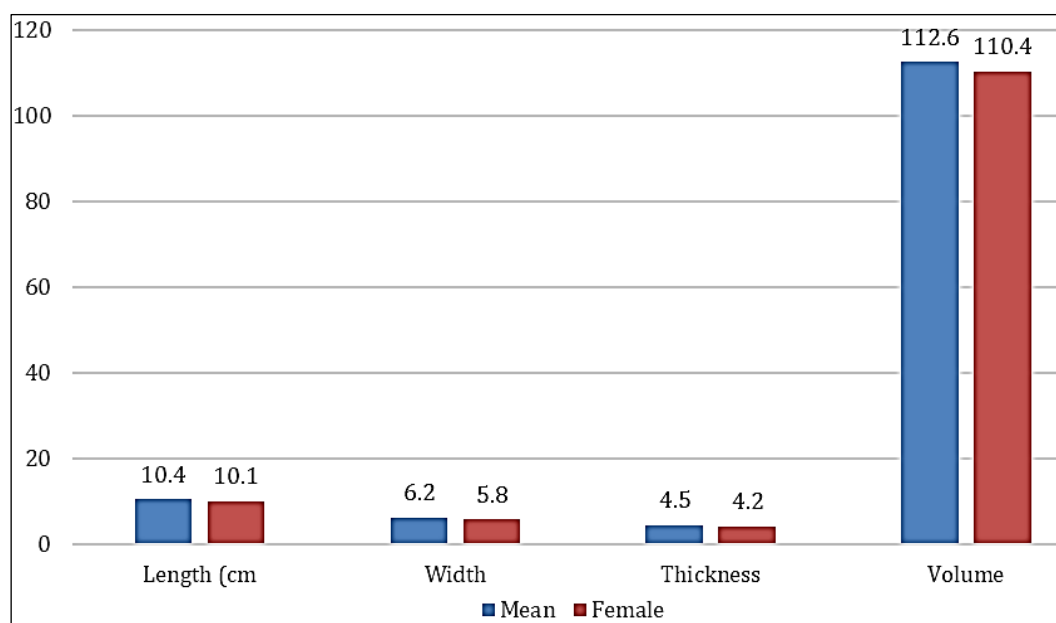
Total-124		
Gender	Male	Female
Number	70	54

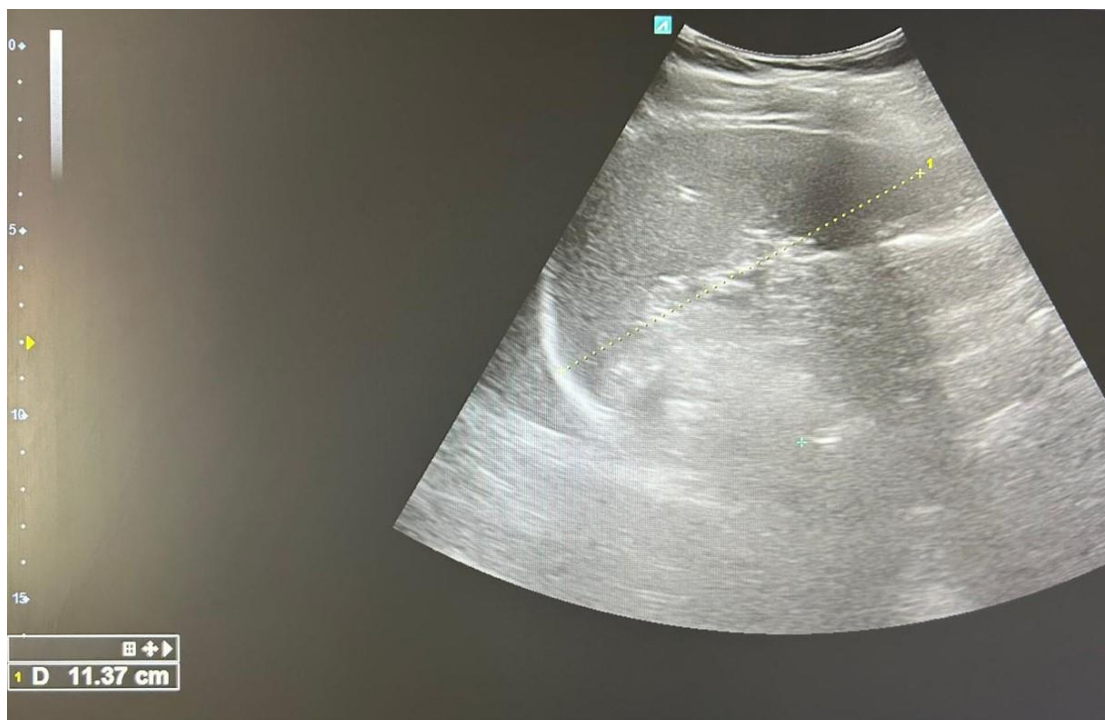Table I shows that out of 124 patients, males were 70 and females were 54.

Table II: Measurement of spleen

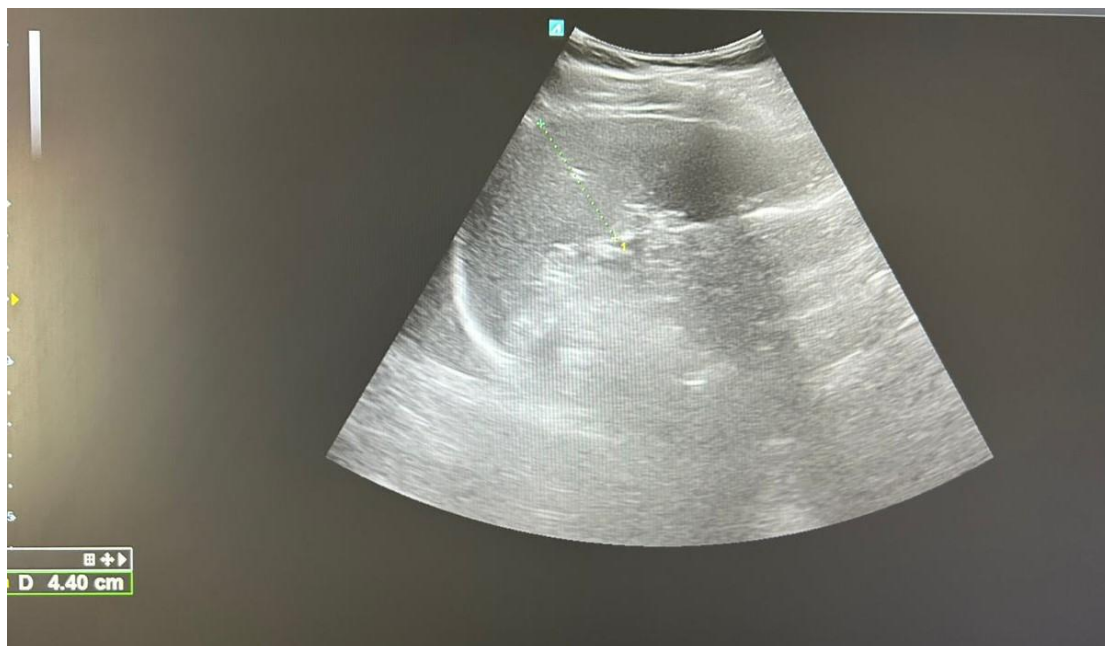Parameters	Mean	Female	P value
Length (cm)	10.4	10.1	0.92
Width	6.2	5.8	0.81
Thickness	4.5	4.2	0.97
Volume	112.6	110.4	0.94

Table II, graph I shows that mean length of spleen in males was 10.4 cm and in females was 10.1 cm, width was 6.2 cm and 5.8 cm, thickness was 4.5 cm and 4.2 cm and volume was 112.6 cm³ and 110.4 cm³ in males and females respectively. The difference was non-significant (P> 0.05).

**Graph I:** Measurement of spleen



Measurement of length of spleen



Measurement of width of spleen

Discussion

Spleen is a reticulo-endothelial and lymphoid organ and sometimes works as hematopoietic organ. Otherwise, this organ is graveyard of RBC. Spleen is enlarged in various clinical disorders e.g. infection, metabolism or storage disorder and haematological abnormalities.⁷ Spleen is never palpable till it is enlarged two-three times of its own size. In diseases condition spleen enlarges at different rates in its all dimensions. A variety of diseases condition alters spleen dimensions, where splenomegaly and its consequence becomes a primary clinical concern in developing countries.⁸ It is commonly seen in about 63% of patients with Pulmonary arterial hypertension, infectious mononucleosis, malaria, lymphoma, kala-azar, typhoid fever, liver disease (hepatitis and cirrhosis), haematological diseases, metabolism diseases and cancer.⁹ The altered splenic dimensions and structure during these diseases result in asymptomatic enlargement and complications such as hematoma formation, rupture, hypersplenism, ectopic spleen, and torsion that affect other adjacent organs.¹⁰ The present study was conducted to assess morphometry of spleen in adult population.

We found that out of 124 patients, males were 70 and females were 54. Demissie *et al.*¹¹ assessed the morphometry of spleen dimensions and its determinants among individuals by sonographic examinations. Seven hundred and eight study participants were selected using a multi-stage systematic random sampling technique. The mean splenic length, width, thickness and volume were 10.24 cm, 4.79 cm, 3.93 cm, and 109.34 cm³, respectively. The mean spleen length, width, thickness and volumes among Males were 10.64 cm, 4.92 cm, 4.05 cm and 119.81 cm³ and among Females were 9.75 cm, 4.63 cm, 3.78 cm and 96.50 cm³ respectively. As age increased by one year the mean spleen length, width, thickness and volume was decreased by 0.032 cm, 0.018 cm 0.004 cm and 0.012 cm respectively. As height increased by 1 cm the mean spleen width and volume were increased by 0.096 cm and 0.052 cm respectively. As we go from male to female the mean spleen length decreased by 0.294 cm.

We found that mean length of spleen in males was 10.4 cm and in females was 10.1 cm, width was 6.2 cm and 5.8 cm, thickness was 4.5 cm and 4.2 cm and volume was 112.6 cm³ and 110.4 cm³ in males and females respectively. Asghar *et al.*¹² did a prospective study on 126 patients (72 male and 54 female) whose abdominal CT scan was found normal and no disorder was diagnosed which alters the size of spleen to estimate normal linear dimensions of spleen in North Indian adult population. All linear dimension of spleen-length, width and thickness were calculated and they were analysed with body habitus-Age, height, weight, BSA (body surface area) and BMI (body mass index) was calculated by linear and non-linear regression model to know exact pattern of correlation. The mean length, width and thickness of spleen were 10.67±1.62 cm, 6.26±1.66 cm and 4.86±1.22 cm respectively. Tekle *et al.*¹³ determined the standard range of spleen size among different adult age groups. A total of 380 adults comprising 180 (47%) males and 200 (53%) females were recruited. Of the subjects, 186 (49%) and 194 (51%) were urban and rural residents, respectively.

The mean splenic length, width and thickness were 9.95 cm (± 1.24), 4.3 ($\pm .73$), and 3.8 ($\pm .87$), respectively.

Chakrabortiet *al.*¹⁴ found out the reference values of spleen length in different age groups in adults of Tripura, to find out possible correlations with the age and gender distribution. The mean spleen length in adults was 8.8 ± 1.32 cm. In males and females, the length was 8.85 ± 1.54 cm 8.72 ± 0.89 cm respectively. All the spleen length (100%) was found below 12.33 cm and most of the cases (91.1%), the spleen length was within the range of 7-11cm. It was observed that, the spleen length decreased with increasing age, which was found to be statistically significant. .

Conclusion

Concluded that length of spleen, width, thickness and volume was more in males than females.

References

1. Frank K, Linhart P, Kortsik C: Sonography milzgrobenbestimmung: Normal mabebeimmilzgesundenErwachsenen (English abstract). *Ultraschall Med.* 1986;7:134.
2. Niederau C, Sonnenberg A, Jurgen E, Muller TS, Wolf P. Sonographic measurement of normal liver, spleen, pancreas and portal vein. *Radiology.* 1983;149:537-40.
3. Picardi M, Martinelli V, Ciancia R, Morante R, Sodano A, Fortunato G, Rotoli B. Measurement of spleen volume by ultrasound scanning in patients with thrombocytosis: a prospective study. *2002;99(11):4228-30.*
4. Mittal R, Chowdhary DS. A Pilot study of the normal measurements of the liver and spleen by ultrasonography in Rajasthani population. *Journal of clinical and diagnostic research.* 2010;4:2733-36.
5. Spielmann AL, DeLong DM, Kliwer MA. Sonographic evaluation of spleen size in all tall healthy atheletes. *AJR.* 2005;184:45-49.
6. Konus OL, Ozdemir A, Akkaya A, Erbas G, Celik H, Isik S. Normal liver, spleen and kidney dimensions in neonates, infants and children: evaluation with sonography. *Am J Roentgenol.* 1998;171:1693-98.
7. De Odorico I, Spaulding KA, Pretorius DH, Lev-Toaff AS, Baily TB, Nelson TR, *et al.*: Normal splenic volumes estimated using three-dimensional ultrasonography. *J ultrasound Med.* 1999;18:231-236.
8. Prassopoulos P, Daskalogiannaki M, Raissaki M, Hatjidakis N, Gourtsoyiannis N. Determination of normal splenic volume on computed tomography in relation to age, gender and body habitus. *Eur. Radiol.* 1997;7:246-48.
9. Ishibashi H, Higuchi N, Shimamura R, *et al.* Sonographic assessment and grading of spleen size. *J clin ultrasound.* 1991;19:21.
10. Brieman RS, Beck JW, Korobin M. Volume determinations using computed tomography. *AJR.* 1982;138:329.

11. Demissie S, Mergu P, Hailu T, Abebe G, Warsa M, Fikadu T. Morphometric assessment of spleen dimensions and its determinants among individuals living in Arba Minch town, southern Ethiopia. *BMC medical imaging*. 2021 Dec;21(1):1-8.
12. Asghar A, Naaz S, Agrawal D, Sharma P. Morphometric study of spleen in North Indian adult population: CT Scan image-based study. *J Clin Diagn Res*. 2011Oct;5(5):974-7.
13. Tekle Y, Gudadhe DR, Abreha M, Muche A, Tegegne Z, Hiware SD. Morphometric assessment of the normal dimensions of the adult spleen in North-west Ethiopia Region-A radiological study. *Ann Int Med Dent Res*. 2018;4(4):34.
14. Chakraborti S, Saha N, Debbarma B, Das S, Leishram D. Normal spleen length by ultrasonography in adults of Tripura. *IOSR J Dent Med Sci*. 2016;15(1):55-60.