



Anomalous drainage of superficial veins of head and neck along with unilateral complete absence of External jugular and cephalic veins

**Ravi Shankar Panneerselvam^{1*}, Ravi Sankar Periyasamy²,
Lavanya Prathap³, Bharan Ravindran⁴**

^{1*}Senior Lecturer, Department of Anatomy, SRM Dental College, Ramapuram Campus, Chennai - India. Email:-p. ravishankar.ms@gmail.com

²Professor and HOD, Department of Anatomy, SRM Dental College, Ramapuram Campus, Chennai-India. Email: - ravi_anat@yahoo.com

³Associate Professor, Department of Anatomy, Saveetha Dental College and Hospitals, Chennai-email: -lavanya_anatomist@gmail.com

⁴Postgraduate student, Department of Oral and Maxillofacial surgery, SRM Dental College, Ramapuram Campus, Chennai, India.
email: -la7bharan@gmail.com

Corresponding author*

Dr. Ravi Shankar Panneerselvam

Senior Lecturer

Department of Anatomy

SRM Dental College

Ramapuram Campus, Chennai -600089, India

Abstract

External jugular vein (EJV) is a significant vein draining the head and neck is being used for central venous cannulation, oral reconstruction and parenteral nutrition in debilitated patients. Clinical and sonological examinations of EJV provide clues towards underlying cardiac pathology, clear knowledge about the variations of EJV and associated superficial veins is important for the surgeons to prevent complications during procedures. During routine cadaveric dissection we observed a rare case of complete absence of EJV and Cephalic vein (CV), the Posterior division of Retromandibular vein (PRMV) and the Posterior auricular vein (PAV) entered into Sternocleidomastoid muscle (SCM), the Superior thyroid vein (STV) drained into the Common facial vein (CFV) all these variations were observed only in the left side and no such variations were seen in right side. Details about these variations and the related angiogenesis were discussed.

Key words: External jugular vein (EJV); External jugular; Cephalic veins;

Introduction:

External jugular vein (EJV) is usually formed by union of the posterior division of the retromandibular vein (PRMV) with the posterior auricular vein (PRV) near to the mandibular angle just below or within the parotid gland and it terminates into subclavian vein at the root of the neck. Posterior external jugular, transverse cervical, suprascapular and anterior jugular veins are the tributaries of EJV [1]. The superficial veins, especially the EJV are often utilized for cannulation to conduct diagnostic procedures or intravenous therapies. The ease of access of the EJV has facilitated its use in patients undergoing transjugular liver biopsy and portosystemic shunts. It has also been used to monitor central venous pressure [2 3]. The absence of the EJV should be borne in mind while attempting any nonsurgical and surgical procedures.

Case Report

During a routine dissection for Postgraduate students we observed that in a 45 years old male cadaver there is complete absence of EJV (Fig-01) and Cephalic vein (CV) .The anterior division of retromandibular vein (ARV) joined with the facial vein to form CFV, the PRMV and the PAV entered into Sternocleidomastoid muscle (SCM), the Superior thyroid vein (STV) drained into the CFV (Fig - 02) and (Fig-03) all these variations were observed only in the left side and no such variations were seen in right side . The diameter of IJV and CFV is measured with digital vernier caliper.

Discussion

Variations in the formation, course and termination of the EJV have long been reported but in our present case report there is gross abnormality in the formative veins of EJV with complete absence of the EJV and CV, no such case report has been reported in the literature. Gupta (2003) et al. reported the case of an EJV that split into two channels on the external surface of SCM and reunited just above its junction with the facial vein [4]. Brown (1941) [5] as well as Pikkieff (1937) [6] observed similar cases as the above-mentioned case in 6.2%. Two similar cases of partial EJV duplication have been described one by Comert (2009) et al. [7] and one by Shenoy (2012) et al. [8]. Pikkieff (1937) described a double EJV as two independent veins emerging from the parotid gland in 7.8%. Double termination of the EJV in the subclavian vein (SV) was detected in 2.2%, whereas triple termination in 0.6% [6]. The EJV was absent in 3.3% [5] or in 1% [6]. Double and triple EJV were usual but the total absence of EJV seen to be a very rare phenomenon. The angiogenesis of head and neck, veins sprout from the ventral pharyngeal vein (VPV), it drains the mandibular and the hyoid arches and opens into the common cardinal vein. As the neck elongates (10 mm embryo stage), the termination of VPV is transferred to the cranial part of the precardinal vein which later becomes the internal jugular vein. The ventral pharyngeal vein receives the linguofacial vein, which drains the face and tongue. The primitive maxillary vein which drains the territory of the ophthalmic and the mandibular divisions of the trigeminal nerve, anastomoses with the linguofacial vein to form the anterior facial vein. The retromandibular vein (RMV) draining the temporal region opens into the linguofacial vein to form a common trunk known as the common facial vein, which ultimately drains into the internal jugular vein.

In the upper limb, the preaxial vein becomes the primitive cephalic vein. The EJV develops as a tributary of the Cephalic vein (CV) from the tissues of the neck and anastomoses secondarily with the anterior facial vein. The CV forms a venous ring around the clavicle, from which it is connected to the caudal part of the precardinal vein. The deep segment of this venous ring forms the SV and receives the definitive EJV [1].

In this cadaver there is complete absence of CV only on the left side. This confirms the failure or regression of the development of the venous plexus connecting the CV and the anterior facial vein, a similar case was reported by Rashmi (2013) et al but the CV was seen draining into the SV of the same side [9]. The left side complete absence of EJV is reported by very few authors like Abhinitha (2013) et al [10] and Cvetko (2015) et al [11]. Regarding formation and drainage of superficial veins of Head and Neck standard Anatomy textbooks illustrates that the level of bifurcation of RMV is at the inferior pole of Parotid gland and the formation of EJV is near to the angle of mandible. In our case both the formative veins of EJV entered into the SCM at the level of hyoid bone the CFV descended to drain into IJV and at the same level STV is ascended to drain into the CFV instead Internal Jugular Vein (IJV). There is abnormal hypertrophy of CFV measuring about 10.3mm in diameter and 32.2mm in length, the IJV measures about 8.6 mm in diameter. In a CT scan cross sectional study conducted by Tartiere (2009) et al [12] the left IJV mean diameter measured about 13 mm in correlating with this study we noticed there is minimal hypoplasticity in the diameter of IJV and also there is maximum hypoplasticity identified in PRMV and PAV. The congenital hypoplasticity of formative veins of EJV, absence of EJV might had created a physiological hypertrophy of the CFV the knowledge of the anatomy about the superficial veins in the anterolateral cervical region, particularly the thyroid veins were important because of its application in thyroid, parathyroid and laryngeal surgery [13]. Most of the surgical accidents were caused due to variations in vessels, Muhammad (2000) et al. [14,15] report 4.8% unsuccessful tracheostomies where hemorrhages were caused by vascular lesions and recommend the use of ultrasonography to assess the anatomical variations of these vessels.

Conclusion:

Knowledge about EJV and associated veins of head and neck is a prerequisite for any surgical and non-surgical procedure, information about this rare variation will be useful for Oral and Maxillofacial surgeons, Anatomists, and Radiologists.

Acknowledgements

The authors sincerely thank Mr.Raba Ibnu Habeeb I year BDS student, SRM Dental College for Photography works.

Conflicts of Interest

No potential conflict of interest relevant to this article was reported.

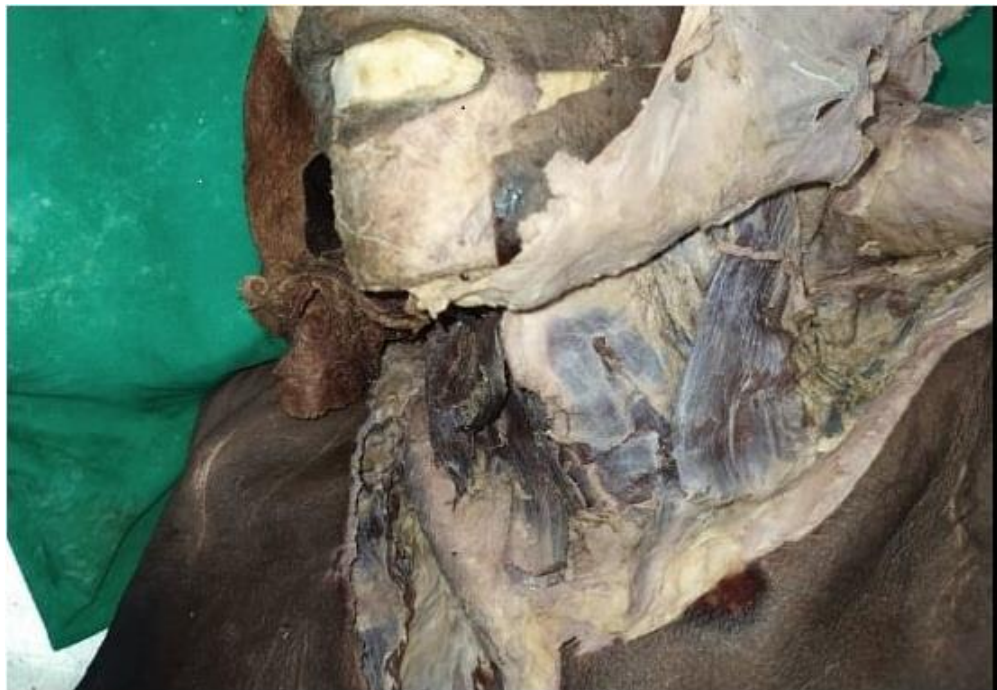

Figure-01




Figure-02



Figure-03

References:

1. Standing S: Gray's Anatomy: The Anatomical Basis of Clinical Practice, 39 edition. Edinburgh, Elsevier Churchill Livingstone, 2006, pp 273-4.
2. Siegel EA, Caresio J, Eckard DA: Use of the external jugular vein approach for transvenous liver biopsy. *Journal of vascular and interventional radiology* 1992; 3: 371-4.
3. Kumar, S., Murugan, S., Krishnan, V. *et al.* Laser-Assisted Microvascular Anastomosis of Free Flaps in Reconstruction of Orofacial Defects: A Comparative Study Among Conventional Methods and Diode Laser Anastomosis. *J. Maxillofac. Oral Surg.* **20**, 635–641 (2021). <https://doi.org/10.1007/s12663-020-01389-w>.
4. Gupta V, Tuli A, Choudhry R, Agarwal S, Mangal A. Facial vein draining into external jugular vein in humans: Its variations, phylogenetic retention and clinical relevance. *Surg Radiol Anat* 2003;25:36-41.
5. Brown S. The external jugular vein in American whites and negroes. *Am J Phys Anthropol* 1941; 28(2): 213–26.
6. Pikkieff E. On the subcutaneous veins of the neck. *J Anat* 1937; 72(Pt 1): 119–27.
7. Comert E, Comert A. External jugular vein duplication. *J Craniofacial Surg* 2009; 20(6): 2173–4.

8. Shenoy V, Saraswathi P, Raghunath G, Karthik JS. Double external jugular vein and other rare venous variations of the head and neck. *Singapore Med J* 2012; 53(12): e251-e3.
9. Rashmi, Avinash, Patil., Lakshmi, Rajgopal., Praveen, Iyer. (2013). Absent external jugular vein - ontogeny and clinical implications.
10. Abhinitha, P and Rao, MKG and Kumar, Naveen and Nayak, Satheesha B and Ravindra, SS and Aithal, PA (2013) Absence of the external jugular vein and an abnormal drainage pattern in the veins of the neck. *OA Anatomy*, 1 (2). pp. 1-3.
11. Cvetko E. A case of left-sided absence and right-sided fenestration of the external jugular vein and a review of the literature. *Surg Radiol Anat.* 2015 Sep;37(7):883-6. doi: 10.1007/s00276-014-1398-z. Epub 2014 Nov 30. PMID: 25432662.
12. Tartière D, Seguin P, Juhel C, Laviolle B, Mallédant Y. Estimation of the diameter and cross-sectional area of the internal jugular veins in adult patients. *Crit Care.* 2009;13(6):R197. doi: 10.1186/cc8200. Epub 2009 Dec 9. PMID: 20003190; PMCID: PMC2811899.
13. Lázaro da Silva A, Delorenzo S, Pelaquim AF, Freire MTG, Rezende Neto JB (1989) Anatomia das veias tireóideas inferiores: aplicação cirúrgica. *Arq Bras Med*, 63: 243–246.
14. Muhammad JK, Major E, Woods A, Patton DW (2000) Percutaneous dilatational tracheostomy: haemorrhagic complications and the vascular anatomy of the anterior neck. A review based on 497 cases. *Int J Oral Maxillofac Surg*, 29: 217–222.
15. Shankar P.R, Ananthi K, S Krishanan P.L, Bilateral elongated styloid process in human dry skull, *SRM J Res Dent Sci* 2018;9;26-