



COMPARATIVE CHARACTERIZATION OF THE RESULTS OF SURGICAL TREATMENT OF TUMORS OF THE PONTocerebellar ANGLE

B.A. Saidov

Republican Scientific Center of Neurosurgery under the Ministry of Health of the Republic of Uzbekistan

Tashkent, Uzbekistan

Saidov.bekzod.81@mail.ru

ABSTRACT

This article is discussing a study that was conducted on patients with pontocerebellar angle tumors who underwent surgical treatment between 2012 and 2019. The study included 120 patients who were divided into two groups: the main group and the control group. The main group consisted of patients who underwent electrophysiological monitoring of facial nerve function during surgery, while the control group did not receive this type of intraoperative monitoring.

The purpose of this study was to determine whether intraoperative monitoring of facial nerve function during surgery had an impact on the outcomes of the surgical procedure. The results of the study showed that patients in the main group, who underwent electrophysiological monitoring of facial nerve function, had significantly better outcomes than those in the control group.

The findings suggest that monitoring the facial nerve function during surgery can help prevent facial nerve damage and improve the outcomes of the surgical procedure. This type of intraoperative monitoring is particularly important for patients with pontocerebellar angle tumors, as the facial nerve is often located in close proximity to the tumor and is at risk of damage during surgery. Overall, the study provides valuable insights into the importance of intraoperative monitoring of facial nerve function during surgery and its impact on patient outcomes.

KEYWORDS: pontocerebellar angle, electroneuromyography, intraoperative monitoring.

INTRODUCTION

Neurinomas of the VIII pair (acoustic neuromas, neurolemmomas, and neurinomas of the auditory nerve), which are slow growing intracranial benign neoplasms, are one of the common pathologies of the subtentorial space. Auditory nerve neurinomas form due to the hyperproduction of Schwann cells, which normally surround the fibres of the vestibular portion of the nerve and support and isolate it. However, in 5% of cases, it is also known to grow from the cochlear portion of the VIII nerve. The surgical treatment of ventral cochlear neurinomas has received considerable attention in the literature, due to the complex intracranial location of the tumor near the brainstem, its feeding vessels, and the outlying cranial nerves. However, in the early stages of the disease, patients rarely come to specialised clinics, which makes it difficult to surgically treat these neoplasms that compress the brainstem in stages III-IV of the disease. In recent years, the surgical tactics for removal of neurinomas of the VIII nerve have been widely debated. Four main approaches are generally accepted: retrosigmoid, presigmoid, translabial and subvisceral transmeatal. The use of each of these methods has its own indications and strict technical conditions. In recent years, the results of microneurosurgical treatment

have been encouraging. Experts emphasise a low mortality rate, 2-3% as a rule [1]. However, some studies show that the risk of facial nerve damage during surgeries in this area ranges from 5% to 40%. Of these, about 2-5% of cases may be associated with complete loss of facial nerve function [3].

Studies have shown that the use of intraoperative monitoring of facial nerve function can reduce the risk of damage to 2-5% [4]. In addition, the degree of facial nerve damage can range from temporary muscle weakness to complete paralysis. Currently, much attention is paid to the application of evoked potential methods, which during surgery allow you to monitor the functional activity of the brain structures and prevent the development of neurological disorders in the postoperative period. Electroneuromyography (ENMG), in particular, can achieve good results. Electroneuromyography is highly informative in diagnosing brain stem pathology and is the most adequate criterion in assessing the functional state of various parts of the nervous system during surgeries for neoplasms of the deep structures of the brain.

It should be noted that ENMG has a great diagnostic value – ENMG parameters do not change depending on the patient's condition (awake or asleep) and do not change under the influence of pharmacological drugs. The greatest changes of ENMG parameters are registered at direct lesion of stem structures. ENMG has low individual variability, i.e. normally the response is almost identical in all individuals.

The aim of this work was to study the results of surgical treatment of the pontocerebellar angle tumours using the ENMG method.

MATERIALS AND METHODS

This study presents the findings from a retrospective analysis of 120 patients with tumors of the pontocerebellar angle who underwent surgical treatment at the Republican Scientific Center of Neurosurgery under the Ministry of Health of the Republic of Uzbekistan between 2012 and 2019. To conduct the study, we divided 120 patients into two groups. The first (main) group consisted of 59 patients who underwent surgical treatment for tumors of the pontocerebellar angle using intraoperative monitoring of facial nerve function (IMFNF). The second (control) group consisted of 61 patients who did not undergo monitoring of facial nerve function during surgery. The main group of 59 patients had intraoperative electromyography (ENMG) monitoring during surgery, with 39 having auditory nerve neurinomas, 12 having meningiomas, and 8 having epidermoid cysts. A control group of 61 patients who underwent surgical treatment for tumors of the pontocerebellar angle without ENMG monitoring was also investigated, with 40 patients having histologically confirmed acoustic neuromas, 13 patients with meningiomas, and 8 patients with epidermoid cysts (Table 1).

Table 1. The number of patients divided into groups in the study of tumors of the pontocerebellar angle.

The main group		Control group	
Tumors of the pontocerebellar angle	(n=59)	Tumors of the pontocerebellar angle	(n=61)
Auditory nerve neurinomas	39 patients	Auditory nerve neurinomas	40 patients
Meningiomas	12 patients	Meningiomas	13 patients
Epidermoid cysts	8 patients	Epidermoid cysts	8 patients

RESULTS AND DISCUSSION

In this manuscript, we are reporting the outcomes of our investigation on postoperative facial nerve function and their comparison between two groups of patients. It should be noted that patients who succumbed post-surgery were not considered in this study. The evaluation of facial nerve dysfunction, or the onset of paresis, was based on the Haus-Bruckmann grading system (Table 2).

Table 2. House-Brackmann scale

	General characteristics	At rest	Movements		
			Forehead	Eye	Mouth
I	Normal	Normal	Normal	Normal	Normal
II	Mild impairment	Tone normal, symmetry preserved	Movement is preserved or mildly impaired	Completely closes with minimum effort	Slight asymmetry
III	A pronounced but not ugly asymmetry	Tone normal, symmetry preserved	Slight to moderate impairment of movement	Completely closes with effort	Slight asymmetry with maximum effort of the mimic muscles
IV	Obvious asymmetry (or pronounced synkinesia) Tone normal, symmetry preserved No movement Not fully closed Asymmetry with maximum effort of facial muscles	Normal tone, symmetry maintained	No movement is present	It does not close completely	Asymmetry at maximum mimic muscle effort
V	Only slight movements of the facial muscles are preserved	An asymmetry	No movement is present	Does not close completely	Slight movements
VI	No movement is present	No movement is present	No movement is present	No movement is present	No movement is present

This study looked at patients who had no facial nerve dysfunction before surgery. After performing the surgeries, clinical manifestations of facial nerve were evaluated. Based on the House-Brackmann scale, in the main group, 20 patients had grade I, which accounted for 33.9% of the group; 24 patients had grade II, accounting for 40.67%; 8 patients had grade III, accounting for 13.55%; 5 patients had grade IV, accounting for 8.47%; and 2 patients had grade V, accounting for 3.39%. Grade 6 complications were not observed in any patient of the main group. (Table 3)

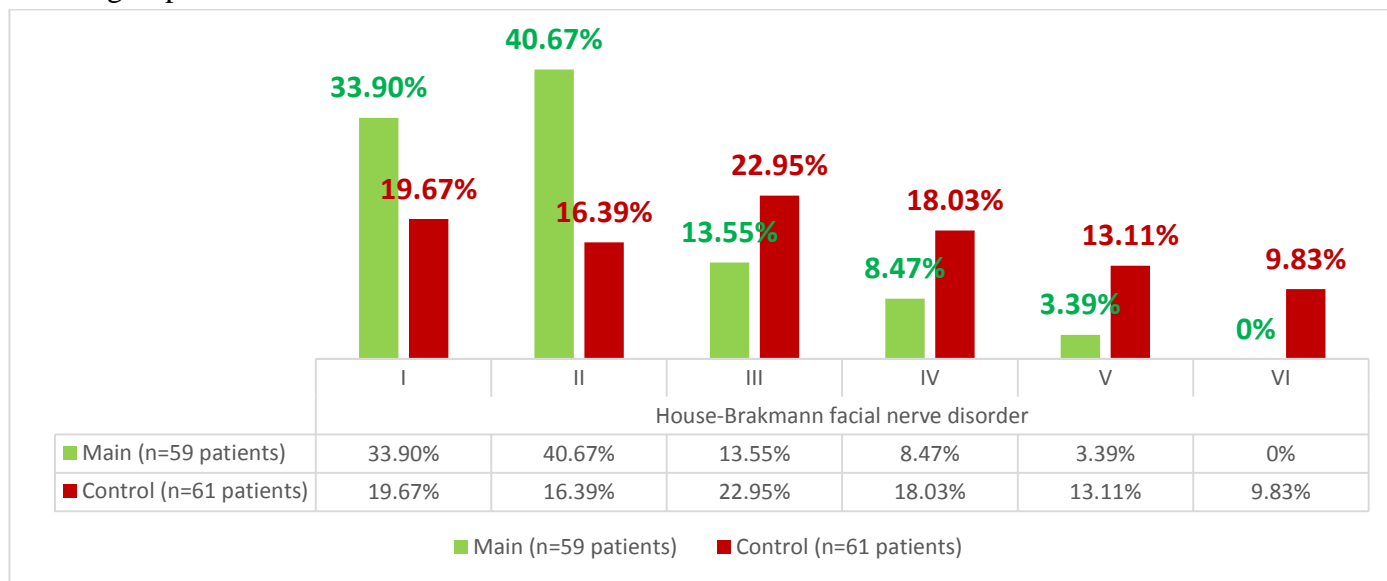
In the control group, 12 patients had grade I, accounting for 19.67%; 10 patients had grade II, accounting for 16.39%; 14 patients had grade III, accounting for 22.95%; 11 patients had grade IV, accounting for 18.03%; and 8 patients had grade V, accounting for 13.11%. Grade VI complications were observed in 6 patients, accounting for 9.83%. (Table 3)

Table 3 Examination of facial nerve function

Groups	House-Brakmann facial nerve disorder					
	I	II	III	IV	V	VI
Main 59 patients	20	24	8	5	2	0
Control 61 patients	12	10	14	11	8	6

Based on the results, it can be concluded that the use of electroneuromyographic monitoring plays a crucial role in postoperative complications. The percentage of patients with complications in the main group was lower compared to the control group, indicating the effectiveness of the monitoring method in reducing the incidence of facial nerve dysfunction (Fig. 1)

Fig. 1. The percentage of patients with complications in the main group was lower compared to the control group.



There are several other scientific studies that confirm the significance of using electromyographic monitoring to prevent complications during operations on the facial nerve. The study conducted in Turkey was published in the journal *J Int Adv Otol*. In this study, methods of intraoperative electroneuronavigation and electromyography were used for acoustic neuroma surgery. The researchers found that the use of intraoperative electroneuronavigation and electromyography reduces the risk of facial nerve injury and improves facial muscle function in the postoperative period. [13]. The study conducted in Bosnia and Herzegovina was published in the journal *Med Arch*. In this study, electroneurography methods and the House-Brackmann classification system were used to assess facial nerve function after surgery on the parotid gland. The researchers found that the use of electroneurography and the House-Brackmann classification system increases the accuracy of facial nerve function assessment and allows for a more precise determination of the presence or absence of paralysis [14]. The study conducted in Japan was published in the journal *J Oral Maxillofac Surg*. In this study, the researchers examined cases of facial nerve paralysis after treatment for oral cavity cancer and assessed the risk of developing this complication. The researchers found that the use of methods such as monitoring facial nerve function can reduce the risk of paralysis development in the postoperative period [15]. The study conducted in the United States was published in the journal *Am J Otolaryngol*. In this study, the method of monitoring facial nerve function during parotidectomy was used. The researchers found that the use of facial nerve function monitoring allows for a reduction in the risk of nerve injury and improved surgical outcomes [16].

CONCLUSION

The implementation of Electroneurography (ENMG) during surgical procedures offers a promising approach for monitoring the functional activity of cranial nerves, thereby mitigating the incidence of postoperative complications.

REFERENCES

1. Sterkers, J.M. (1981). Facial Nerve Preservation in Acoustic Neuroma Surgery. In: Samii, M., Jannetta, P.J. (eds) *The Cranial Nerves*. Springer, Berlin, Heidelberg. https://doi.org/10.1007/978-3-642-67980-3_57
2. Fadeeva T.N. Results of application of the complex Fadeeva T.N. Results of application of complex electrophysiological monitoring in surgery of VIII nerve neurinomas / T.N.
3. Wiedemayer H, Sandalcioğlu IE, Armbruster W, *et al* False negative findings in intraoperative SEP monitoring: analysis of 658 consecutive neurosurgical cases and review of published reports *Journal of Neurology, Neurosurgery & Psychiatry* 2004;**75**:280-286.
4. Lalwani AK, Butt FY, Jackler RK, Pitts LH, Yingling CD. Facial nerve outcome after acoustic neuroma surgery: a study from the era of cranial nerve monitoring. *Otolaryngol Head Neck Surg.* 1994 Nov;**111**(5):561-70. doi: 10.1177/019459989411100505. PMID: 7970793.
5. Fadeeva, V.E. Olyushin, P.G. Goman *et al.* // Polenov's readings: Dokl. – C. 224. Stupak V.V., Pendyurin I.V. RESULTS OF SURGICAL TREATMENT OF BIG AND GIANT NEVRINOMOUS NERVOUS HEAD // Modern problems of science and education. – 2017. - № 5.;
6. Aage, R. *Intraoperative Neurophysiological Monitoring / R. Aage//Hardcover.* - 2005. - Vol. 2. - 434 p.
7. 220. Allison, T. *Evoked Potentials / T. Allison // Neurology.* - 1990.-Vol.4 0 . - P . 565.
8. 248. Cabraja, M . *Intraoperative monitoring in der Klinik für Neurochirurgie/M . Cabraja.* - Berlin, 2005. - 51 8 p.
9. Jia W, Yu CJ, Wang FM, Chen F. Research on suboccipital retrosigmoid transmeatus approach microanatomy. *J Cap Med Univ (Chin)* 2004; 25: 60-63.
10. Ojemann R.G. Retrosigmoid approach to acoustic neuroma (vestibular schwannoma) // *Neurosurgery.* — 2001. — V.48, №3. — P.553–558., 18 Ross D.A. Vestibular schwannoma // *MedLink-Neurobase.* Third Ed. — 2000. — Arbor Publishing Corp. — CD.
11. Rhoton A.L. The Cerebellopontine Angle and Posterior Fossa Cranial Nerves by the Retrosigmoid Approach // *Neurosurgery.* — 2000. — V.47, №3. — P.92–127.
12. Ross D.A. Vestibular schwannoma // *MedLink-Neurobase.* Third Ed. — 2000. — Arbor Publishing Corp. — CD.
13. Karsidag S, Batik U, Sennaroglu L. Use of Intraoperative Electroneuronavigation and Electromyography in Acoustic Neuroma Surgery. *J Int Adv Otol.* 2017;**13**(3):366-371. doi: 10.5152/iao.2017.3198.
14. 2. Hadžiosmanovic N, Kabil E, Bajramovic F. Facial Nerve Function after Parotid Surgery: Use of Electroneurography and the House–Brackmann Grading System. *Med Arch.* 2019;**73**(4):244-248. doi: 10.5455/medarh.2019.73.244-248.
15. 3. Hamada N, Asahi K, Kimura H, Fujimaki T, Yamamoto Y, Baba Y. Postoperative facial nerve paralysis associated with cervical lymph node dissection in the treatment of oral cancer. *J*

Oral Maxillofac Surg. 1999 Oct;57(10):1149-1153; discussion 1153-1144. doi: 10.1016/s0278-2391(99)90005-0.

16. 4. Lechner M, Hirano A, Ramakrishna J, Svider PF, Raza SN. Role of intraoperative facial nerve monitoring in preventing complications in parotidectomy. Am J Otolaryngol. 2017 Sep-Oct;38(5):522-527. doi: 10.1016/j.amjoto.2017.06.008.