



CRITERIA FOR CHOOSING A PLASTY METHOD IN PATIENTS WITH POSTOPERATIVE VENTRAL HERNIAS

Makhmudov Saidinjon Botirovich, Khudainazarov Utkir Rabbimovich

Samarkand State Medical University

ABSTRACT

An analysis of the results of a comprehensive examination and surgical treatment of 145 patients with ventral hernia and concomitant morbid obesity using a differentiated approach to the choice of the method of hernioplasty and abdominoplasty is presented. Improvement of the technical aspects of non-tension methods of hernia alloplasty with implantation of the endoprosthesis using the combined method "onlay + sublay" in combination with abdominoplasty made it possible to level the recurrence of the disease (in the comparison group, recurrence was 12.5%). The proposed algorithm for adequate preoperative preparation and choice of the method of hernia allo- and abdominoplasty in patients with abdominal hernias and abdominoptosis made it possible to reduce the incidence of postoperative complications from 14.8% to 8.9% ($p = 0.045$), including wound complications from 11.5% up to 4.5%.

Keywords: Ventral hernias, morbid obesity, surgical tactics.

DOI: [10.48047/ecb/2023.12.8.668](https://doi.org/10.48047/ecb/2023.12.8.668)

INTRODUCTION

According to the World Health Organization, "hernia of the anterior abdominal wall is one of the most common surgical diseases, occurs in 3-7% of the population, with a predominant lesion of people of working age", "More than 5% of all laparotomies are complicated by the formation of postoperative ventral hernias (PVH), and the frequency of their occurrence depends on the nature and urgency of the surgical intervention. Surgical interventions to eliminate postoperative ventral hernias account for about 10% of all surgical interventions. The existing traditional methods of hernioplasty do not always provide an effective treatment result, while the number of relapses varies from 4.3% to 46%, and with extensive defects, their frequency can reach up to 60% of cases. In this connection, at present, various options for allohernioplasty are the priority method of surgical treatment, which made it possible to significantly improve long-term results. However, the ongoing developments in this direction, the emergence of publications on the need for a differentiated approach to choosing the optimal method of surgery, taking into account the background pathology, the size and location of hernias and other factors, indicates dissatisfaction with the results of treatment of this category of patients and determine the relevance and social significance of this problem.

At present, the most relevant research continues to be the study of the pathogenetic mechanisms of the development of hernia defects depending on various factors, including structural changes in the muscular and connective tissue skeleton of the anterior abdominal wall, metabolic disorders, impaired collagen synthesis in middle-aged and elderly people, and other prerequisites for hernia formation. The problems of increased production of serous-hemorrhagic fluid in response to the implantation of a mesh prosthesis remain unresolved. Particularly relevant are the issues of studying the age, typical and gender features of the structure of the fascial-muscular-aponeurotic complex of the anterior abdominal wall, with a morphological and functional justification for the treatment of ventral hernias by various surgical methods and an individual approach to the use of synthetic alloplastic materials, including the use of endovideosurgical hernioplasty.

The aim of the study is to improve the results of surgical treatment of patients with incisional ventral hernias based on the criteria for choosing the method of hernioplasty.

MATERIALS AND METHODS

The study is based on the results of examination and treatment of 245 patients with postoperative ventral hernias, who were operated on in the surgical departments of the Samarkand City Medical Association No. 1 and the 1st clinic of the Samarkand State Medical University in the period from 2016 to 2021. All patients were operated on in a planned manner, and depending on the choice of treatment tactics, the patients were divided into 2 groups. The comparison group consisted of 84 operated patients in the period 2016-2018, in the treatment of which standard generally accepted approaches were used. The main group consisted of 161 patients who underwent operations in 2019-2021 according to the developed criteria for choosing the hernia alloplasty method.

Of the 245 sick men, there were 73 (29.8%), women - 172 (70.2%).

Age distribution: up to 45 years old - 44 (16.8%), 46-59 years old - 138 (52.9%), 60-74 years old - 56 (21.5%), 75-80 years old - 7 (2.7%).

In the study groups, 139 (53.3%) patients had uncomplicated forms of hernia and 106 (46.7%) had such a complication as irreducibility. Patients with strangulated hernia were not included in our study.

According to the classification, Chervel JP and Rath AM (1999), the vast majority of patients (187 - 76.3%) had hernias in the midline of the abdomen - supra-umbilical (M₁), para-

umbilical (M₂) and sub-umbilical (M₃) hernias. The smallest number of patients was with lateral (L) 48 (19.6%) and combined (M + L) 10 (4.1%) postoperative ventral hernias. 116 (47.3%) patients had large (W₃) and giant (W₄) hernias. In 162 (66.2%) they were postoperative (R₀), in 83 (41.3%) recurrent postoperative ventral hernias (R_n).

Computed tomography was performed in 69 (42.9%) patients of the main group and was performed to determine the size of the hernial orifice, the volume of the contents of the hernial sac, identify additional defects in the aponeurosis, identify concomitant pathology of the abdominal organs and topographic changes due to adhesions, thickness and uniformity subcutaneous fat of the anterior abdominal wall, as well as for the preliminary determination of the method of hernioplasty (Fig. 1).

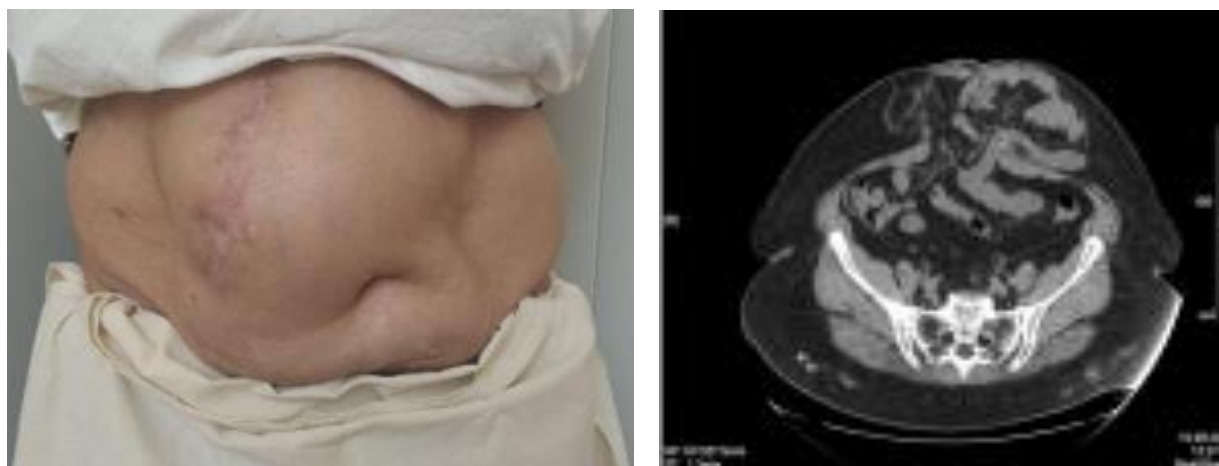

Fig. 1. Patient P., 56 years old with postoperative ventral hernia (M²W³R⁰) and computed tomography of the anterior abdominal wall and abdominal cavity

Patients in the comparison group (n = 84) underwent hernia alloplasty in 37 (44.1%) patients using tension methods and in 47 (55.9%) patients using non-tension methods.

In the main group, the choice of hernia alloplasty was differentiated in accordance with the developed criteria for choosing the method of hernia alloplasty in patients with postoperative ventral hernias (Table 1).

Table 1

Types of hernioplasty in the main group

Subgroups	Type of operation	Quantity	%
1	Laparoscopic hernioplasty (IPOM)	49	30.4

2	Hernioplasty " onlay " with preliminary suturing the defect	41	25.5
3	Hernioplasty " onlay " without suturing the defect with implantation of the endoprosthesis with U-shaped sutures	57	35.4
4	Hernioplasty " onlay + sublay " without suturing the defect in a combined way	14	8.7
	Total	161	100

Patients with a total score of up to 5 in accordance with our program, as well as with a hernial protrusion volume of up to 5% of the volume of the abdominal cavity according to CT, were given priority laparoscopic surgery. hernioplasty. With a score of up to 5 and a hernia volume of 5.1% - 14% of the volume of the abdominal cavity, as well as with the technical difficulties of a laparoscopic operation, hernia alloplasty " onlay " was performed with preliminary suturing the defect.

Laparoscopic prosthetic hernioplasty according to the IPOM method for postoperative ventral hernias was used by us in 49 patients with small and medium hernias (W_1 , W_2), with the corresponding sizes of the aponeurosis defect up to 5 cm and from 5 to 10 cm.

Depending on the type of mesh implant, the patients of the main group underwent the following surgical interventions. 37 (75.5% of 49 patients) underwent laparoscopic prosthetic hernioplasty) in patients who have used standard polypropylene mesh implants. In 12 (24.5%) patients, composite mesh implants "Physiomes " or "Prosi " (Ethicon) were used.

Prior to the introduction of the implant into the abdominal cavity, the patients underwent an opening of the peritoneum, the hernial sac was isolated and a "pocket" was created in the preperitoneal space, the indentation along the perimeter from the hernial orifice was 5-6 cm. was placed in the created preperitoneal "pocket". It was pressed against the anterior abdominal wall using ligatures tied around the edges of the implant. The implant was sutured to the anterior abdominal wall extracorporeally using our modified Endo needle. Close (Figure 2).

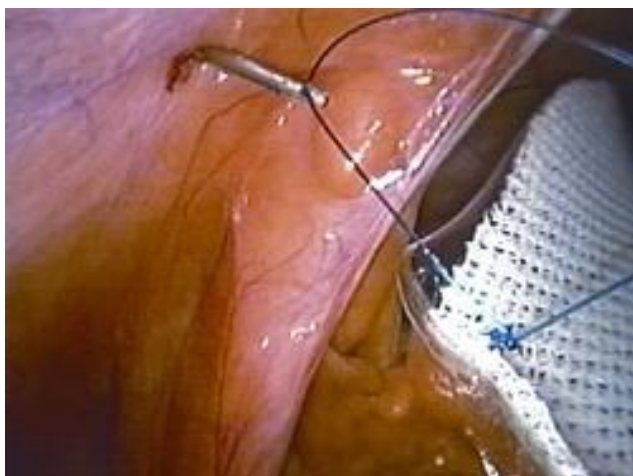

Fig. 2. Removal of the suture thread with a modified Endo Close needle (view from the side of the abdominal cavity)

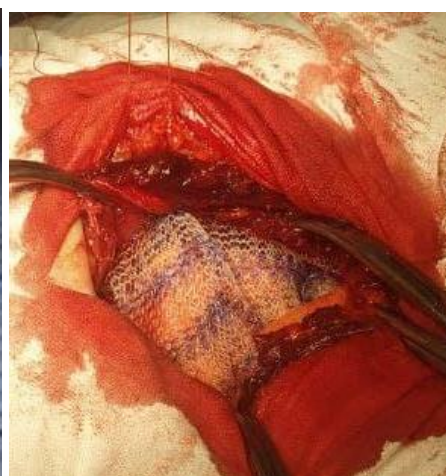

Fig. 3. Fixation of the “sublay” endoprosthesis to the anterior abdominal wall with previously applied U-shaped sutures

The use of composite mesh implants "Physiomesch" or "Prosid" (Ethicon) in 12 (26.7%) patients avoided the need to create a preperitoneal "pocket" before fixing the prosthesis to the anterior abdominal wall.

However, 41 patients with a total score of up to 5, as well as with a hernial protrusion volume of up to 14% of the volume of the abdominal cavity according to CT data, an “onlay” endoprosthesis was implanted with suturing of the defect. At the same time, in 6 patients this type of operation was continued as a conversion when performing laparoscopic hernioplasty.

For patients with a score of 6 to 10 and taking into account CT data with a hernial protrusion volume of more than 14.1% of the volume of the abdominal cavity, we performed “onlay” hernioplasty without suturing the defect with implantation of the endoprosthesis with U-shaped sutures in 57 patients. In order to increase the volume of the abdominal cavity, to prevent the development of SAH, after delimiting the abdominal cavity with a hernial sac flap, plastic surgery of the anterior abdominal wall was performed by applying a mesh to the aponeurosis without his suturing. The endoprosthesis was fixed with U-shaped sutures previously applied with the capture of all layers of the muscular aponeurotic wall up to the peritoneum (Fig. 3).

In 14 (17.9%) patients of the main group with a hernial defect larger than 10 cm and a hernial protrusion volume of more than 18% of the volume of the abdominal cavity, according to CT data, a combined tension- free hernioplasty "onlay + sublay", i.e. one implant was placed

behind the muscular-aponeurotic layer after the abdominal cavity was delimited by a hernial sac flap, the second implant was placed above the aponeurosis. Next, the endoprosthesis was placed according to the "sublay" type, the previously applied U-shaped sutures were passed through all layers above the aponeurosis, and the second endoprosthesis of the placed "onlay" was fixed to these sutures.

Interrupted sutures were also applied between the endoprostheses, creating an artificial "white line" of the abdomen. Of particular importance of this method is the anatomical and physiological reconstruction of the anterior abdominal wall, as well as the white line of the abdomen. The use of this method in the clinic gave a good functional result.

Based on a comparative analysis of the effectiveness of the proposed tactical and technical aspects in postoperative ventral hernias, an algorithm of criteria for choosing the method of hernia alloalloplasty was proposed.

In 241 (98.3%) patients, normal function of the gastrointestinal tract remained after surgery, only 4 (1.6%) patients, 2 patients each in the study groups, had intestinal paresis and 2 (2.4%) patients from the comparison group and 2 the main group (1.2%) noted urinary retention. Bronchopulmonary complications were noted in 3 (3.6%) and 4 (2.2%) patients, respectively, in the comparison group and the main group. The development of SAH (compartment -syndrome) occurred in 2 (2.4%) patients of the comparison group, the patients required prolonged mechanical ventilation with breathing training, which was successfully stopped conservatively. Cardiovascular complications were observed in 2 (2.4%) patients in the comparison group. Both respiratory and cardiovascular complications have been associated with abdominal compression due to tension hernioplasty.

Among the wound complications, postoperative hematomas were noted in 2 (2.4%) and 1 (0.6%) cases, respectively, seromas in 2 (2.4%) and 3 (1.8%) patients, lymphorrhea in 3 (1, 2%) of patients, in 2 and 1 cases in the comparison group and in the main groups, respectively, wound suppuration in 1 (1.2%) patient in the comparison group and necrosis of the edge of the skin flap in 2 (2.4%) and 1 (0.6 %) cases. It should be noted that, on average, one patient in the comparison group had 2-3 complications in the form of a combination of broncho-pulmonary or cardiovascular complications with wound complications. In general, in the comparison group there were 10 (11.9%) patients with various complications, of which 9 (10.7%) had wound complications and 10 (11.9%) had general non-abdominal complications.

In the main group, there were 7 (4.3%) patients with various complications, 6 (3.7%) had wound complications, and another 8 (4.9%) had general complications. According to the comparative sign in terms of the number of complications, a significant improvement was obtained in the main group (Criterion $\chi^2=4.043$; Df =1; p =0.045).

At the stages of treatment, the level of intra-abdominal pressure was measured in dynamics. Based on the data obtained, regular changes in intra-abdominal pressure indicators were revealed in the direction of their increase at the stages of the operation, associated with the immersion of the hernia contents and hernioplasty using a tension method. Performing tension-free hernioplasty with endoprosthesis implantation P - shaped sutures and the combined method "onlay + sublay" without suturing the defect, applied to 71 patients of the main group, made it possible to avoid an increase in intra-abdominal pressure.

RESULTS AND DISCUSSION

It should be noted that, on average, one patient in the comparison group had 2-3 complications in the form of a combination of broncho-pulmonary and/or cardiovascular complications with wound complications. In general, in the comparison group there were 8 (14.8% of 54) patients with various complications, of which 6 (11.1%) had wound complications and 4 (7.4%) had general extra-abdominal complications. In the main group, there were 6 (8.9% of 67) patients with various complications, 3 (4.5%) had wound complications, and another 3 (4.5%) had general complications. According to the comparative sign in terms of the number of complications, a significant improvement was obtained in the main group (Criterion $\chi^2=4.043$; Df =1; p =0.045).

Further, long-term results were analyzed in 93 (76.8%) of 121 operated patients, recurrence of ventral hernia was noted in 5 (12.5%) patients in the comparison group. It was determined that the main cause of hernia recurrence was the significant skin-fat apron left after hernioplasty, which, due to intra-abdominal pressure and gravitational force, displaces the implant downward, exposing the weak spots of the abdominal wall in the upper part of the prosthesis. Also, the cause of recurrence was suppuration of wounds with rejection of the implant in patients with severe abdominoptosis. III - IV degree. Improvement of the technical aspects of non-tension methods of hernia alloplasty with implantation of the endoprosthesis using the combined method " onlay + sublay " in combination with abdominoplasty made it possible to level the recurrence of the disease (Fig. 4).

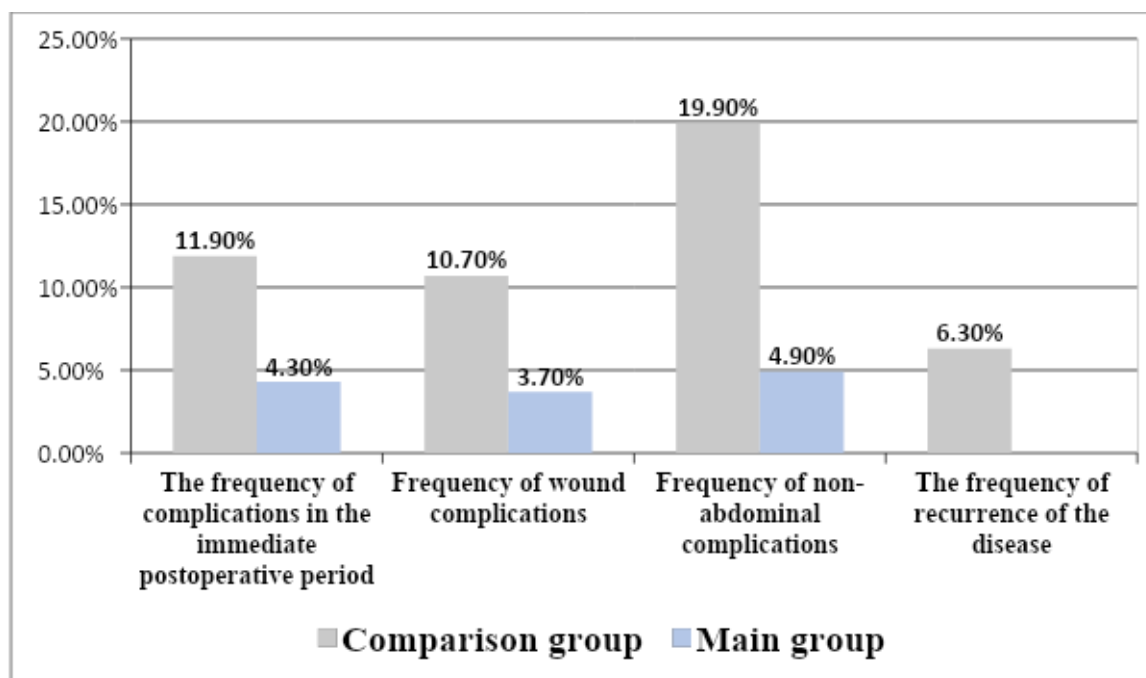


Fig. 4. Comparative analysis of treatment results in the study groups

The clinical efficacy of combined hernia allo - and abdominoplasty in patients with abdominal hernia and abdominoptosis is also confirmed by a significant decrease in the degree of obesity, improvement in external respiration, a tendency to reduce high blood pressure and diabetes mellitus.

According to the developed program for determining the quality of life of patients, 87 (93.5%) of 93 patients observed in the late postoperative period were evaluated. Of these, 36 patients from the comparison group and 51 patients from the main group. In the comparison group, excellent results were obtained in 11 (30.5%) patients, good in 17 (47.2%), satisfactory in 5 (13.9%) patients and unsatisfactory in 3 (8.3%) cases. In turn, in the main group, excellent results were obtained in 28 out of 51 (54.9%) patients, good in 19 (37.2%), satisfactory in 3 (5.9%) patients and unsatisfactory only in 1 (1, 9%) case.

CONCLUSION

The choice of hernialloplasty method for postoperative ventral hernias should be based not only on the size of the hernial defect, but also on determining the ratio of the hernia volume to the volume of the abdominal cavity according to computed tomography.

Laparoscopic IPOM hernioplasty is methodologically justified in postoperative ventral hernias of small and medium sizes (W1-W2). Improvement in the technical aspects of fixation of the endoprosthesis greatly simplifies the technique of the operation and reduces its duration.

Optimization of the tactical and technical aspects of the implementation of tension-free "onlay" hernioplasty with preliminary application of U-shaped sutures and the method of implantation of the endoprosthesis using the combined method "onlay + sublay" made it possible to level the development of the compartment syndrome and the recurrence of the disease in postoperative hernias of large and giant (W3-W4) sizes.

The proposed algorithm for the treatment of patients with postoperative ventral hernias, based on the criteria for choosing the method of hernia alloplasty, made it possible to reduce the incidence of postoperative complications from 11.9% to 4.3%, and to level the development of compartment syndrome and recurrence of the disease in the main group, which were observed in the comparison group in 2.4% and 6.3% respectively.

REFERENCES

1. Abduraxmanov D. Sh. Choice of treatment of patients with ventral hernias and morbid obesity by performing combined hernia allo-and abdominoplasty // Pedagogical sciences and teaching methods. - 2023. - Vol. 2. - No. 21. - S. 102-104.
2. Abduraxmanov D. Sh. Choice of treatment of patients with ventral hernias and morbid obesity by performing combined hernia allo-and abdominoplasty // Pedagogical sciences and teaching methods. - 2023. - Vol. 2. - No. 21. - S. 102-104.
3. Abduraxmanov D., Rakhmanov K., Davlatov S. Tactical and technical aspects of surgical interventions for abdominal hernia and concomitant abdominal pathology // Journal of hepato-gastroenterological research. - 2021. - Vol. 2. - No. 3. - S. 11-16.
4. Abduraxmanov D. Sh. et al. Results of surgical treatment of patients with abdominal hernias and associated abdominal pathology // Journal of Biomedicine and Practice. - 2022. - Vol. 7. - No. 2.
5. Abduraxmanov D. Sh. et al. Tensioned hernioplasty and abdominoplasty in patients with morbid obesity // Bulletin of Science and Education. – 2021. – №. 3-2 (106). – S. 88-98.
6. Akhmedov B. A. et al. Advanced long-tension hernioalloplasty method for inguinal hernia // Volgamedscience. - 2021. - S. 335-336.

7. Babazhanov A. S et al. Criteria for selecting hernioallo and abdominoplasty by the results of hernioabdominometry // Journal of biomedicine and practice. - 2022. - Vol. 7. - No. 4.
8. Baylon K. et al. Past, present and future of surgical meshes: a review //Membranes. - 2017. - T. 7. - no. 3. - S. 47.
9. Berrevoet F. et al. A multicenter prospective study of patients undergoing open ventral hernia repair with intraperitoneal positioning using the monofilament polyester composite ventral patch: interim results of the panacea study //Medical devices (Auckland, NZ). - 2017. - T. 10. - S. 81.
10. Davlatov, S., Rakhmanov, K., Usarov, S., Yuldoshev, F., Xudaynazarov, U., & Tuxtayev, J. (2020). Inguinal hernia: Modern aspects of etiopathogenesis and treatment. International Journal of Pharmaceutical Research, 12, 1912-1921. doi:10.31838/ijpr/2020.SP2.338
11. Davlatov, S., Teshayev, Sh, Fayziev, X., & Khamidova, N. (2020). Inguinal hernia: Modern aspects of etiopathogenesis and treatment. International Journal of Pharmaceutical Research, 13, 970-976. doi.org/10.31838/ijpr/2021.13.02.147
12. Elstner K.E. et al. Preoperative progressive pneumoperitoneum complementing chemical component relaxation in complex ventral hernia repair //Surgical endoscopy. - 2017. - T. 31. - no. 4. - S. 1914-1922.
13. Mardanov, B., Kurbaniyazov, Z., Davlatov, S., & Rakhmanov, K. (2020). Rationale for simultaneous operations on the abdominal organs and the abdominal wall in patients with a ventral hernia. International Journal of Pharmaceutical Research, 12, 1922-1930. doi:10.31838/ijpr/2020.SP2.339
14. World Health Organization. Hernias: fact sheet no. 199. World Health Organization website. 2017. www.who.int/iris/handle/10589/1111189.