



TYPES, CLINICAL FEATURES, DIAGNOSIS AND TREATMENT OF AMYLOIDOSES

Faisal Fahad Alzahrani¹, Mohammed Qhalib Alfaier², Jawharah Ayesah Alanazi³, Aljowharah Hamdan Alanazi³, Taghreed Awad Alanazi⁴, Maryam Mohammed Alanazy⁵, Ali Saad AlGhamdi⁶, Mohammed Hadi Assiri⁷, Nawaf Khalid Andijani⁸, Mohammed Abdullah Niyazi⁹, Shatha Awad Alraddadi¹⁰, Shada Omar Baoum¹¹, Ahmad Saud Alaskar¹²

ABSTRACT

Amyloidoses are a group of complex diseases marked by the abnormal deposition of amyloid proteins in extracellular spaces, leading to progressive organ dysfunction. This review delves into the pathogenesis, classification, diagnosis, and treatment of amyloidoses, emphasizing the critical role of protein misfolding and aggregation in disease progression. The transformation of soluble proteins into insoluble fibrils through fibrillogenesis, involving abnormal folding into β -pleated sheets, induces the development of amyloidosis. These processes are influenced by genetic mutations, aging, and the proteolytic conversion of normal proteins, challenging the body's protein quality control mechanisms. The classification of amyloidosis is determined by the specific amyloid protein implicated, with more than 36 amyloidogenic proteins recognized, leading to deposits that are either localized or systemic. The diagnosis involves a combination of clinical evaluation, lab tests, biopsies, and sophisticated imaging methods to precisely determine the nature and scope of amyloid accumulation. Treatment strategies focus on reducing amyloid protein production, promoting amyloid removal, and supporting organ function, incorporating chemotherapy, targeted therapies, stem cell transplantation, and innovative approaches like gene editing.

The review highlights the ongoing challenges in amyloidosis management, including late diagnosis and the need for improved therapeutic strategies. It underscores the importance of early detection and intervention in enhancing patient outcomes, advocating for increased research into diagnostic and treatment innovations.

Keywords: Amyloidoses, genetic mutations, classification, diagnosis, treatment, chemotherapy, early detection

¹ Department of Internal Medicine, King Abdulaziz Hospital, Jeddah, Saudi Arabia

² Department of Emergency Medicine, King Abdulaziz Specialist Hospital, Taif, Saudi Arabia

³ Department of Forensic Medicine, Northern Border University, Arar, Saudi Arabia

⁴ Internal Departments, North Medical Tower Hospital, Arar, Saudi Arabia

⁵ Department of Infection Control, Prince Abdulaziz Bin MUSAAD Hospital, Northern Border Province, Saudi Arabia

⁶ Riyadh Second Health Cluster, Second Health Cluster Region, Riyadh, Saudi Arabia

⁷ Department of Neurology, Khamis Mushait General Hospital, Khamis Mushait, Saudi Arabia

⁸ King Abdulaziz Airport Health Monitoring Center, Ministry of Health, Jeddah, Saudi Arabia

⁹ King Abdulaziz Primary Healthcare Center, Ministry of Health, Jeddah, Saudi Arabia

¹⁰ Department of Family Medicine, King Abdulaziz Hospital, Jeddah, Saudi Arabia

¹¹ Department of Family Medicine, East Jeddah Hospital, Jeddah, Saudi Arabia

¹² Hotat Bani Tamim General Hospital, First Health Cluster Riyadh, Riyadh, Saudi Arabia

***Corresponding Author:** Faisal Fahad Alzahrani

*Department of Emergency Medicine, King Abdulaziz Specialist Hospital, Taif, Saudi Arabia,

email: Dr.faisal.z@hotmail.com

DOI: 10.53555/ecb/2023.12.2.040

INTRODUCTION

Amyloidoses constitute a diverse and uncommon set of conditions, marked by the accumulation of proteins that have been improperly folded within bodily tissues. These proteins, initially soluble and globular, undergo a transformation that causes them to misfold and cluster together into stable, insoluble fibrils. This process results in the progressive deterioration of organ function. Observed under electron microscopy, amyloid fibrils are noted for their rigid, non-branching architecture, typically measuring between 8 and 12 nanometers in thickness (1). The process of fibril formation, known as fibrillogenesis, is marked by the abnormal folding of proteins into a β -pleated sheet structure. This alteration makes the proteins hydrophobic, insoluble, non-functional, and resilient to degradation. The genesis of amyloid is multifactorial, involving a persistent rise in the levels of proteins due to either acquired or hereditary mutations, the inherent tendency of certain wild-type proteins to misfold, or the proteolytic conversion of a normal protein into an amyloid-prone fragment (2-4).

The process of amyloid fibril formation, or amyloidogenesis, is a complex phenomenon tightly regulated by the body's protein quality control systems. These systems operate both within and outside cells to promptly identify and eliminate proteins that have misfolded, a natural safeguard against the accumulation of dysfunctional proteins. However, under certain conditions, such as genetic mutations that predispose proteins to misfold, the natural aging process that may diminish the efficiency of these control mechanisms, or the proteolytic transformation of normal proteins into amyloidogenic variants, these regulatory systems can become weakened or impaired. When this happens, misfolded proteins begin to accumulate, initially forming smaller aggregates known as protofibrils before eventually maturing into amyloid fibrils (5).

The toxicity associated with amyloid fibrils, referred to as proteotoxicity, initiates with protofibrils and intensifies as they mature into fibrils, which have a distinct affinity for Congo red, a dye used in the diagnosis of amyloidosis.

The process of fibril formation involves attracting specific elements like the amyloid P component, apolipoprotein E, and glycosaminoglycans. These components not only aid in maintaining the structural stability and durability of amyloid deposits but also act as consistent indicators of the disease, appearing in all varieties of amyloid accumulations. These components underscore the multifactorial nature of amyloidosis, reflecting the interplay between genetic predispositions,

environmental factors, and the body's failing defense mechanisms against protein misfolding (2-4).

METHODOLOGY

This study is based on a comprehensive literature search conducted on February 21, 2023, in the Medline and Cochrane databases, utilizing the medical topic headings (MeSH) and a combination of all available related terms, according to the database. To prevent missing any possible research, a manual search for publications was conducted through Google Scholar, using the reference lists of the previously listed papers as a starting point. We looked for valuable information in papers that discussed the types, clinical features, diagnosis, and treatment of amyloidoses. There were no restrictions on date, language, participant age, or type of publication.

DISCUSSION

Amyloidoses represent a group of diseases characterized by extracellular deposition of amyloid, a proteinaceous material, leading to organ dysfunction and a wide range of clinical manifestations depending on the type and location of amyloid deposition.

Classification

According to the International Society of Amyloidosis (ISA), amyloidosis classification depends on detecting extracellular deposits of fibrillar proteins. These proteins are identifiable by their capacity to adhere to Congo red dye, which, when observed under polarized light, exhibits a distinctive yellow-green birefringence (1). The classification depends on the particular type of protein causing the amyloid deposit, using a naming convention that begins with "A" for amyloid, followed by an abbreviation of the protein's name. Examples include AL for amyloid derived from immunoglobulin light chain, ATTR for amyloid derived from transthyretin, among others. ISA emphasizes a clear distinction between hereditary forms of amyloidosis, often named for the specific amino acid change in the protein (e.g., ATTRV30M where valine is replaced by methionine), and sporadic or non-hereditary forms. The use of single-letter versus three-letter amino acid codes and the preference for hereditary over familial classification reflect a standardization effort to classify these conditions accurately. Notably, the term hereditary ATTRv (where v indicates variant) is preferred over ATTRm to denote mutant forms, although the literature may use these terms interchangeably (5).

To date, 36 amyloidogenic proteins have been identified, capable of forming deposits that may be either localized to a single organ or systemic, affecting multiple organs and tissues (**Figure 1**) (5). Remarkably, at least 19 protein types are exclusively connected to localized amyloid deposits, whereas over 14 types are linked to

systemic amyloidosis. Interestingly, certain protein types, such as AL/AH (derived from immunoglobulin chains) and ATTR (from transthyretin), along with amyloidosis from β 2 microglobulin (A β 2M), have the capacity to present in both localized and systemic forms (**Table 1**) (5).

Table 1: Summary of amyloidogenic proteins, columns for fibril protein, precursor protein, localization (systemic or localized), acquisition (acquired or hereditary), and target organs (5)

Fibril Protein	Precursor Protein	Localization	Acquisition	Target Organs
AL, AH	Immunoglobulin Light (L) or heavy (H) chain	S, L	A (H)	All organs, usually except Central nervous system.
AA	Serumamyloid A	S	A	All organs, except Peripheral nervous system, Central nervous system.
ALECT2	Leukocyte chemotactic factor-2	S	A	Kidney primarily
ATTRv	Transthyretin variants (v)	S	H	Heart, Peripheral nervous system, Autonomic nervous system, eye, leptomeninges
AFib	Fibrinogen A α chain variants	S	H	Kidney primarily
Apolipoproteins AI, AII, CII, CIII	Apolipoprotein variants	S	H	All variants kidney, AApoAI also heart, liver, Peripheral nervous system, testis, larynx, skin
ALys, AGel	Lysozyme variants, Gelsolin variants	S	H	Kidney, Peripheral nervous system, cornea, kidney, heart Autonomic nervous system
A β 2Mv	β 2 microglobulin variant	S	A	Musculo-skeletal system
ATTRwt	Wild type, aging	S	H	Cardiac primarily, lung, ligaments, tenosynovium
AApoAIV	Apolipoprotein AIV	S	A	Kidney medulla, systemic
ASem1	Semenogelin 1	S	A	Seminal vesicles
A β 2M	Wild type, iatrogenic (dialysis)	S	A	Injection sites
AIns (insulin)	Wild type or variant	L	A	Cardiac atria, thyroid, islets of Langerhans, pituitary
AEnf (enfurvitide)	Iatrogenic	L	A	Skin, aorta, cornea
Cerebral: A β , ABri, ACys, APrP	Various hormones: Atrial natriuretic factor, calcitonin, Islet amyloid polypeptide, prolactin	L	A, H	Central nervous system.

Clinical features

Systemic AL Amyloidosis

In systemic AL amyloidosis, any organ in the body can be affected with the exception of the central

nervous system (6). The most common initial symptoms include asthenia and dyspnea, which are nonspecific and can lead to a delay in diagnosing the condition (**Table 2**).

Table 2: Summary of clinical characteristics of Systemic AL Amyloidosis

Characteristic	Details
Organs Affected	All except the central nervous system
Initial Symptoms	Asthenia, dyspnoea
Kidney Involvement	<ul style="list-style-type: none"> - Most frequent at diagnosis - Characterized by heavy proteinuria (mainly albumin), nephrotic syndrome, decreased glomerular filtration rate (20 to 45% of cases) (7, 8). - Renal manifestations may be absent initially but seldom appear during follow-up
Cardiac Involvement	<ul style="list-style-type: none"> - Present in up to 90% of patients - Approximately 50% present with diastolic heart failure at diagnosis [9] - Major prognosis factor, responsible for ~75% of deaths due to heart failure or arrhythmia (9, 10). - Amyloid deposition in the myocardium leads to thickening of ventricular and atrial walls, causing restrictive cardiopathy with increasing asthenia, dyspnoea, and lower limb oedema. May also induce conduction disorders and arrhythmias.
Peripheral Nerve Involvement	<ul style="list-style-type: none"> - Affects 20% of patients - Presents as painful, slowly progressing sensorimotor peripheral polyneuropathy, similar to diabetic neuropathy - Carpal tunnel syndrome and severe autonomic neuropathy (manifesting with gastroparesia, diarrhoea or constipation, impotence, severe postural hypotension) are common
GI Tract Involvement	<ul style="list-style-type: none"> - Common but often asymptomatic, detected in over 80% of biopsy samples from the rectum or stomach - Symptoms include impaired intestinal transit, possibly enhanced by autonomic neuropathy, or occult bleeding - Severe complications can include malabsorption, perforations, haemorrhages, or acute intestinal obstruction
Liver Manifestations	<ul style="list-style-type: none"> - Observed in 30% of patients, usually presenting as liver enlargement with isolated increased serum alkaline phosphatase levels - Liver disease demonstrated by scintigraphy with 123I-labelled serum amyloid P component (123I-SAP) and non-invasive Fibroscan for hepatic stiffness assessment (11). - In rare cases, severe cholestatic hepatitis may occur, usually rapidly fatal without effective treatment
Spleen Involvement	<ul style="list-style-type: none"> - Nearly constant, usually asymptomatic - In patients with massive deposits, signs of hyposplenism (Howell-Jolly bodies) and thrombocytopenia may be detected
Lung Disease	<ul style="list-style-type: none"> - Mainly characterized by interstitial amyloid infiltration - Rapidly progressive respiratory deficiency may result from bronchiolar and alveolar involvement, more frequent in patients with serum IgM paraprotein (12).
Skin Lesions	<ul style="list-style-type: none"> - Includes distinctive periorbital hematomas to a variety of papules, nodules, and patches, primarily located on the face and trunk.
Joint Symptoms	<ul style="list-style-type: none"> - Manifest as progressive bilateral and symmetrical polyarthropathy involving fingers, wrists, shoulders, and knees - Amyloid deposits may infiltrate tendon sheaths, resulting in the classical shoulder pad sign. When they invade muscle belts, they may cause muscular enlargement, resulting in a “pseudo-athletic” appearance often associated with amyloid cardiopathy
Exocrine Gland Infiltration	<ul style="list-style-type: none"> - May lead to sicca syndrome, thyroid or adrenal deficiencies
Hemorrhagic Complications	<ul style="list-style-type: none"> - Resulting from vascular infiltration, sometimes combined with a deficit in coagulation factors (mainly in factor X, less commonly in factors V or IX) or with increased fibrinolysis (7, 13, 14).
Diagnostic Criteria	<ul style="list-style-type: none"> - Pathological demonstration of renal amyloid or, when a kidney biopsy is not available, histological evidence from another tissue with proteinuria ≥ 0.5 g/day predominantly composed of albumin (15, 16).
Prognosis Factors	<ul style="list-style-type: none"> - Amyloid heart disease is a major factor, accounting for approximately 75% of deaths due to heart failure or arrhythmia (9, 10).
Specific Features	<ul style="list-style-type: none"> - Macroglossia, found in 15% of cases, can cause feeding problems or obstruction of the upper airways

Localized AL Amyloidosis

In some cases, AL amyloidosis is localized, with monoclonal LC deposition near the site of synthesis by a focal plasma cell clone, often without evidence of monoclonal gammopathy. The bladder, urinary tract, tracheobronchial system, lungs, larynx, eye, and skin are commonly affected areas (17, 18).

Diagnosing amyloidosis

The diagnosis of amyloidosis involves a multifaceted approach, starting with a comprehensive medical history and physical examination to document symptoms, their progression, family history, and specific physical signs such as macroglossia and periorbital bruising through clinical assessment. Laboratory tests play a crucial role in detecting abnormal protein levels in the blood or urine, including serum free light chains and immunofixation electrophoresis, utilizing techniques like serum and urine electrophoresis, immunofixation, and free light chains analysis. A biopsy and subsequent histological examination, where tissue is stained with Congo red and viewed under polarized light to reveal apple-green birefringence, are essential for confirming the presence of amyloid. Identifying the specific amyloid protein involved through mass spectrometry and immunohistochemistry is critical for subtyping amyloidosis. Genetic testing, particularly for hereditary forms, involves identifying mutations in genes, such as transthyretin for ATTR amyloidosis, through gene sequencing. Evaluating organ involvement is crucial and is conducted through echocardiography, renal and liver function tests, and imaging techniques like MRI and CT scans. Screening for monoclonal gammopathy is necessary for differential diagnosis and treatment planning. A detailed assessment of organ involvement informs treatment decisions and prognosis, combining clinical and laboratory assessment. Additionally, immunoelectron microscopy of abdominal fat aspirates serves as an effective diagnostic tool, further illustrating the comprehensive and detailed process required for diagnosing amyloidosis (19).

Treatment approaches for amyloidosis

The fundamental strategies for managing amyloidosis involve, reducing the production of proteins that form amyloid, enhancing the removal of amyloid deposits, and providing support for organs that are affected. The treatment of amyloidosis, a complex condition characterized by the accumulation of amyloid protein in tissues, requires a personalized approach due to its diverse types and the varying organs it can affect. Although

there is no cure for amyloidosis, the goal of treatment is to manage symptoms and limit the production of amyloid protein. For patients with AL amyloidosis, which is caused by the proliferation of abnormal cells that produce amyloid proteins, chemotherapy is a cornerstone treatment option. This approach aims to suppress the growth of these cells. Cardiac involvement in amyloidosis is managed with heart medications, including blood thinners to prevent clots, medications to regulate heart rate, and diuretics to reduce strain on the heart and kidneys (20).

Targeted therapies offer another layer of treatment. Drugs like patisiran (Onpattro) and inotersen (Tegsedi) are designed to interrupt the faulty genetic instructions responsible for amyloid production. Similarly, tafamidis (Vyndamax, Vyndaqel) and diflunisal work by stabilizing the protein fragments, preventing them from forming harmful amyloid deposits.

For certain patients, particularly those with non-advanced disease and limited cardiac involvement, an autologous blood stem cell transplant may be beneficial. This procedure involves collecting the patient's own stem cells, administering high-dose chemotherapy to eradicate the disease, and then reinfusing the stem cells to restore healthy bone marrow.

In cases where amyloidosis has caused kidney damage, dialysis may be required. Moreover, severe damage to organs may necessitate organ transplantation as a treatment strategy.

Innovative treatments are continuously being explored. Daratumumab, a human monoclonal antibody that targets CD38, has shown promise in the ANDROMEDA trial for AL amyloidosis, especially when combined with a regimen of bortezomib, cyclophosphamide, and dexamethasone. For ATTR amyloidosis, which has a genetic basis, gene editing techniques such as CRISPR-Cas9 are under investigation, offering hope for directly addressing the genetic causes of the disease. These emerging treatments represent the cutting edge of amyloidosis management, aiming to offer more effective and targeted solutions for this complex condition.

Challenges

Despite significant advances in understanding and treating systemic amyloidosis, the condition continues to pose considerable challenges. The prognosis for many patients remains poor due to late diagnosis and the rapid progression of the disease, compounded by a lack of awareness among both the public and healthcare professionals. This highlights the critical need for early detection, which can be facilitated by

increased vigilance for key symptoms such as unexplained cardiac failure, proteinuria, and organ swelling among others. Moreover, the complexity of the disease, exemplified by its progression even after the successful reduction of precursor proteins in certain cases, underscores the urgent need for research into more effective diagnostic and therapeutic strategies. These strategies should aim not only to halt amyloid deposition quickly upon detection but also to develop methods for the removal of existing deposits from the body. The journey towards better outcomes for patients with amyloidosis thus requires a concerted effort from

both fundamental and clinical research to innovate and improve treatment protocols, offering hope for those afflicted by these formidable diseases (21).

CONCLUSION

Amyloidoses are complex diseases with varied clinical presentations and a need for precise diagnosis and tailored treatment strategies. Advances in understanding the molecular mechanisms and the development of targeted therapies have improved outcomes. Early diagnosis and intervention remain critical for managing these diseases effectively.

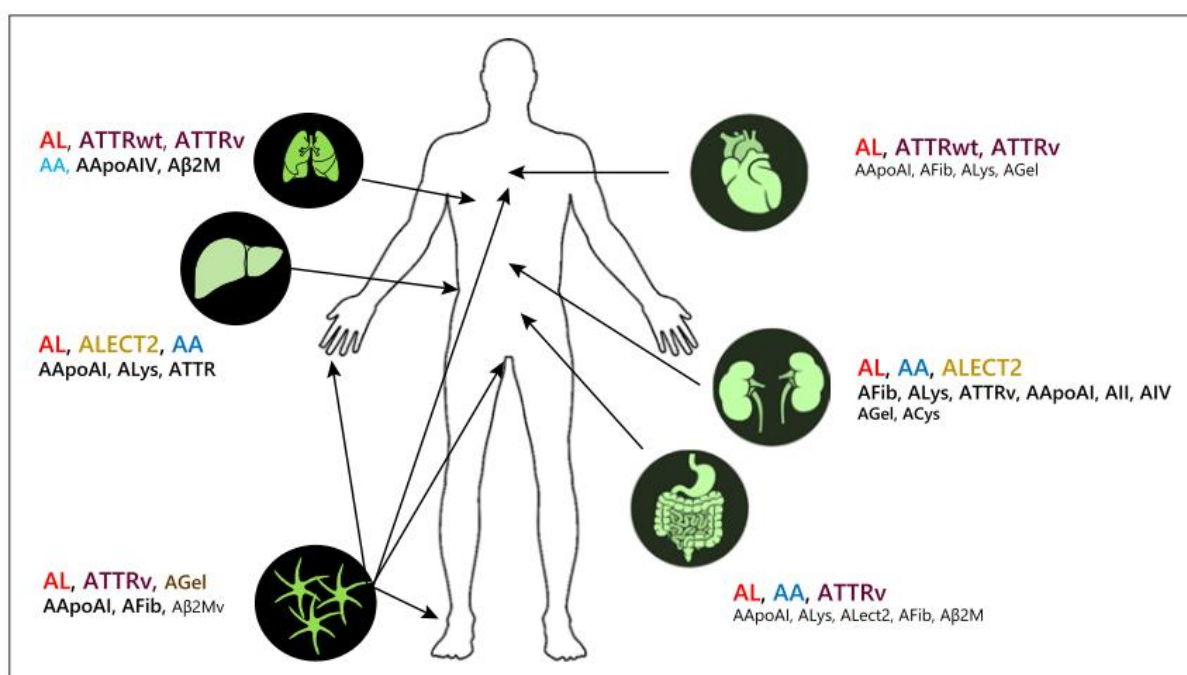


Figure 1. Systemic amyloidosis types by target organ involvement (5).

REFERENCES

- Benson MD, Buxbaum JN, Eisenberg DS, Merlini G, Saraiva MJ, Sekijima Y, et al. Amyloid nomenclature 2018: recommendations by the International Society of Amyloidosis (ISA) nomenclature committee. *Amyloid*. 2018;25(4):215-9.
- Chiti F, Dobson CM. Protein misfolding, amyloid formation, and human disease: a summary of progress over the last decade. *Annual review of biochemistry*. 2017;86:27-68.
- Nuvolone M, Merlini G. Systemic amyloidosis: novel therapies and role of biomarkers. *Nephrology Dialysis Transplantation*. 2017;32(5):770-80.
- Misra P, Blancas-Mejia LM, Ramirez-Alvarado M. Mechanistic insights into the early events in the aggregation of immunoglobulin light chains. *Biochemistry*. 2019;58(29):3155-68.
- Picken Maria M. The Pathology of Amyloidosis in Classification: A Review. *Acta Haematologica*. 2020;143(4):322-34.
- Desport E, Bridoux F, Sirac C, Delbes S, Bender S, Fernandez B, et al. AL amyloidosis. *Orphanet journal of rare diseases*. 2012;7:1-13.
- Obici L, Perfetti V, Palladini G, Moratti R, Merlini G. Clinical aspects of systemic amyloid diseases. *Biochimica et Biophysica Acta (BBA)-Proteins and Proteomics*. 2005;1753(1):11-22.
- Pinney JH, Lachmann HJ, Bansil L, Wechalekar AD, Gilbertson JA, Rowczenio D, et al. Outcome in renal AL amyloidosis after chemotherapy. *Journal of clinical oncology*. 2011;29(6):674-81.
- Selvanayagam JB, Hawkins PN, Paul B, Myerson SG, Neubauer S. Evaluation and management of the cardiac amyloidosis. *Journal of the American College of Cardiology*. 2007;50(22):2101-10.

10. Kapoor P, Thenappan T, Singh E, Kumar S, Greipp PR. Cardiac amyloidosis: a practical approach to diagnosis and management. *The American journal of medicine*. 2011;124(11):1006-15.
11. Loustaud-Ratti V, Cypierre A, Rousseau A, Yagoubi F, Abraham J, Fauchais A-L, et al. Non-invasive detection of hepatic amyloidosis: FibroScan, a new tool. *Amyloid*. 2011;18(1):19-24.
12. Terrier B, Jaccard A, Harousseau J-L, Delarue R, Tournilhac O, Hunault-Berger M, et al. The clinical spectrum of IgM-related amyloidosis: a French nationwide retrospective study of 72 patients. *Medicine*. 2008;87(2):99-109.
13. Sucker C, Hetzel GR, Grabensee B, Stocksclaeder M, Scharf RE. Amyloidosis and bleeding: pathophysiology, diagnosis, and therapy. *American journal of kidney diseases*. 2006;47(6):947-55.
14. Bouma B, Maas C, Hazenberg B, Lokhorst H, Gebbink M. Increased plasmin- α 2-antiplasmin levels indicate activation of the fibrinolytic system in systemic amyloidoses. *Journal of Thrombosis and Haemostasis*. 2007;5(6):1139-42.
15. Gertz MA, Comenzo R, Falk RH, Fermand JP, Hazenberg BP, Hawkins PN, et al. Definition of organ involvement and treatment response in immunoglobulin light chain amyloidosis (AL): a consensus opinion from the 10th International Symposium on Amyloid and Amyloidosis. *American journal of hematology*. 2005;79(4):319-28.
16. Ma G. Definition of organ involvement and response to treatment in AL amyloidosis: an updated consensus opinion. *Amyloid*. 2010;17:48-9.
17. Biewend ML, Menke DM, Calamia KT. The spectrum of localized amyloidosis: a case series of 20 patients and review of the literature. *Amyloid*. 2006;13(3):135-42.
18. Paccalin M, Hachulla E, Cazalet C, Tricot L, Carreiro M, Rubi M, et al. Localized amyloidosis: a survey of 35 French cases. *Amyloid*. 2005;12(4):239-45.
19. Fernández de Larrea C, Verga L, Morbini P, Klersy C, Lavatelli F, Foli A, et al. A practical approach to the diagnosis of systemic amyloidoses. *Blood*. 2015;125(14):2239-44.
20. Onuora S. New treatments for amyloidosis. *Nature Reviews Rheumatology*. 2021;17(9):510-.
21. Hazenberg BP. Amyloidosis: a clinical overview. *Rheumatic Disease Clinics*. 2013;39(2):323-45.