



EXTRAGENITAL PATHOLOGY OF THE MOTHER AND MORPHOLOGICAL FEATURES OF THE DEVELOPMENT OF THE SPLEEN IN THE PERIOD OF EARLY POSTNATAL ONTOGENESIS

Khasanov Bakhtiyor Burtkhanovich, Ilyasov Aziz Saidmurotovich, Sultanova Dildor Bakhshilloevna

*Associate professor, PhD¹, <https://orcid.org/0000-0002-7402-3454>,
Doctor of biology, professor,² <https://orcid.org/0009-0008-2332-7862>
assistant³, <https://orcid.org/0009-0003-1239-2347>*

¹ *Department of Histology, cytology and embryology;* ² *Department of Anatomy and clinical anatomy;* ³ *Department of Biological chemistry
Bukhara State Medical Institute, Uzbekistan
Bukhara, A.Navoi Avenue 1,
Tel.: +998 (65) 223-00-50 e-mail info@bsmi.uz*

ABSTRACT

Morphometric, cytometric and immunohistochemically methods have been used to research the effect of chronic toxic hepatitis (CTH) of the mother on the formation of the offspring spleen in the dynamics of early postnatal ontogenesis. We used 120 female outbred rats weighing 110-120 g, and 120 male rat pups on days 1, 3, 7, 15, 21 and 30 after birth. A decrease in weight and height, as well as a decrease in the absolute and relative weight of the spleen of rat pups, was established. The above processes in the offspring of female rats with CTH were morphologically accompanied by a lag in the formation of structural and functional zones of the white pulp of the spleen and a lag in the development of T- and B-dependent zones of the spleen of rat pups in the dynamics of early postnatal ontogenesis.

Key words: chronic toxic hepatitis, offspring, spleen, early postnatal ontogenesis, morphometry, T- and B-lymphocytes.

DOI: 10.48047/ecb/2023.12.8.674

INTRODUCTION

It is known that one of the main peripheral organs of the immune system is the spleen, in which the processes of further differentiation of T- and B-lymphocytes, their interaction with macrophages and the formation of clones of antibody-forming cells are carried out [9, 10, 13, 14, 21, 22]. Despite numerous researches devoted to the study of the structure and function of the spleen, the place and significance of this organ in physiological and pathological conditions remain insufficiently elucidated to date. The spleen has a close intersystem relationship with other organs and systems, primarily with the liver and blood system, which is a topical problem for our region, since hepatitis is a regional pathology in our country. The close correlation between the spleen and the liver in pathological conditions is widely known in clinical practice and served as the basis for the introduction of the term "hepatolienal syndrome" [5]. One of the serious complications of chronic hepatitis and cirrhosis of the liver is hypersplenism syndrome, which manifests itself as pancytopenia in the blood and is often combined with splenomegaly [9]. The relevance of this research is also determined by the need to reproduce a full-fledged generation. Whereas, according to the literature, it has been established that hepatitis is also often found among women of childbearing age. Moreover, numerous experimental and clinical

studies indicate a violation in the offspring of mothers with chronic pathology of the hepatobiliary system in the formation of life support systems, including reproductive, digestive, immune and macrophage [11]. At the same time, the mechanisms of the influence of chronic maternal hepatitis on the formation of the offspring spleen in the dynamics of early postnatal ontogenesis remain poorly understood.

Thereby, the aim of this research was to elucidate the effect of chronic toxic maternal hepatitis before pregnancy on the structural and functional development of the spleen of rat pups in the dynamics of early postnatal ontogenesis.

MATERIALS AND METHODS

Experimental studies were carried out in accordance with the requirements of the European Convention for the Protection of Vertebrate Animals used for Experimental and Scientific Purposes and the principles of the Helsinki Declaration on the Humane Treatment of Animals. For work, 120 female outbred rats weighing 110-120 g were used. To exclude infectious diseases, all animals were quarantined for two weeks. Then the experimental animals were divided into 2 groups (60 rats in each): experimental and control. A model of CTH was obtained by weekly administration of 0.05 mg of heliothrin per 1 g of body weight for 6 weeks [2]. The control group of animals received sterile saline instead of heliothrin. Males were added to the females 10 days after the last injection. Vaginal swabs obtained from females after mating determined pregnancy. Subsequently, the course of pregnancy was monitored.

It should be noted that toxic hepatitis in female rats had a significant negative impact on fertility and the course of pregnancy. All animals in the control group became pregnant, which successfully ended in childbirth. Whereas in the experimental group of animals out of 84% of rats, pregnancy ended in childbirth in 64%, miscarriages - in 8%. The rest died during pregnancy. The average number of pups from one mother in the control group was 9.7 ± 0.5 , in the experimental group -6.3 ± 0.6 . With toxic hepatitis in the mother, postnatal mortality of the offspring increased to 39.6% (in the control 6.2%). Moreover, the highest mortality (28.7%) was observed on the 1-7th day after birth (5.4% in the control). Dead rat pups were excluded from the experiments. In total, 60 cubs from females of the control group and 60 from females of the experimental group were included in the studies.

Rats were decapitated under light ether anesthesia on days 1, 3, 7, 15, 21, and 30 after birth. For morphological analysis of the spleen, pieces of the resulting tissue were fixed with 10% buffered formalin for 24 hours. Dehydration, compaction and filling of tissues in paraffin was carried out according to the generally accepted method. Sections with a thickness of 3-5 μm were stained with hematoxylin-eosin according to the standard method. **Morphometric researches** were carried out using the Avtandilov grid per unit area according to the generally accepted method. **Immunohistochemically studies** were carried out on 60 spleen samples (30 from the control group and 30 from the experimental group of animals). Tissues fixed with 10% buffered formalin for 24 hours were used. Routine tissue insertion was carried out on the STP120 carousel processor, ThermoFisher, Germany. Serial sections 3 μm thick were deparaffinized, dehydrated, unmasked, and stained with antigens using a specialized automated system Ventana Benchmark XT, Roche, Switzerland. For the study, samples of 1, 3, 7, 15, 21 and 30 day old rats with CD3 and CD20 antibodies were used to detect T- and B-lymphocytes, respectively, on spleen biopsies from the control and experimental groups of animals. Statistical processing of the obtained data was carried out using computer programs.

RESULTS AND DISCUSSION

The results of our research showed that the spleen of rats in the process of growth and development during breastfeeding undergoes certain structural and functional changes. In newborn rat pups, the spleen is covered on the outside with a thin connective tissue capsule, from which delicate layers of connective tissue extend into the organ. It should be noted that during the first day after birth, the spleen parenchyma is mainly represented by red pulp. During this period, the spleen of rats is characterized by the presence of many erythroid cells at various stages of differentiation, diffusely distributed lymphoid cells, granulocytes and megakaryocytes, as well as the absence of a formed white pulp. On the 3rd day of postnatal development, it is characterized by the relative development of the cellular components of the red pulp, pronounced processes of thrombocytopoiesis and erythropoiesis. Changes in the vascular system are determined by the appearance, along with sinusoidal hemocapillaries and arterioles, of arteries with a distinct wall containing circular bundles of smooth muscle. Around the arteries of the muscular type, there is an insignificant accumulation of cells of the lymphoid series, consisting of small and medium-sized lymphocytes. This process can be considered as the initial stage of the formation of the white pulp of the spleen, since later a thymus-dependent zone of the white pulp is formed in these areas. The presence of blast cells and megakaryocytes against the background of dark-colored erythroid cells gives the spleen tissue at this age a characteristic "variegated" appearance.

On the 7th day of postnatal development, significant quantitative and qualitative changes occur. The capsule and smooth muscle components thicken somewhat compared to the previous periods. Along with trabeculae, numerous reticular fibers depart from the capsule, forming a kind of network. Together with trabeculae, they are involved in the formation of venous sinuses and vessels filled with numerous blood cells. It should be noted that during this period, white and red pulp are quite clearly distinguished, white pulp occupies more than 8% of the total area of the organ and lymphoid follicles. Clusters of lymphocytes, single monocytes and macrophages represent the emerging white pulp. It distinguishes between the internal periarterial lymphoid cuff and the external marginal zone. In the center of the white pulp is the central artery of the muscular type, around, which are small and medium-sized lymphocytes that form the T-zone. Between the T-zone and the red pulp is a marginal zone, separated from the red pulp by a moderately pronounced, marginal sinus, the wall of which is lined with squamous endothelial cells. In the marginal zone, small, medium-sized lymphocytes and macrophages containing small lysosomes in the cytoplasm are determined.

The 15th day of development is characterized by the further formation of the stroma and parenchyma of the spleen. During this period, there is a decrease in the rate of erythropoiesis and thrombopoiesis in the spleen, and, on the contrary, intensification of the processes of lymphocytopoiesis and the formation of the white pulp of the organ. On the 21st day of postnatal ontogenesis, the predominant development of the white pulp of the organ is observed. In this case, there is an increase in the number and expansion of the diameter of the lymph nodes. It should be noted that in the lymph nodes. As in the previous periods of the research, germinal or light centers are not clearly expressed. At the same time, in each nodule, 3 zones can be distinguished during this period. Along with the periarterial and marginal zones, an intermediate zone is identified during this period, located between these zones. Thus, on the 21st day of postnatal development, the formation of a white pulp occurs, where the processes of lymphocyte, plasmacytopoiesis and antibody formation take place. At the same time, the intensity of erythropoiesis and thrombopoiesis is significantly reduced. An increase in the number of macrophages in the red pulp probably indicates that in this period the spleen begins to actively function as a hematopoietic organ. Further growth of the organ is accompanied by its quantitative and qualitative changes. We also examined the spleen on the 30th day after birth,

where it was found that the organ acquires a structure characteristic of the spleen of adult animals.

A completely different picture was observed in the study of the spleen of rat pups born from mothers with CTH, where a significant delay in the postnatal formation of structural and functional zones was noted. In rat pups of the experimental group, even on days 7-14, the parenchyma of the lymphoid follicle consisted mainly of diffuse lymphoid tissue without clear boundaries between the red and white pulp of the organ. The subcapsular sinuses were significantly dilated. The absence of formed lymph follicles during this period is characteristic of the spleen and, as established by other researchers, for lymph nodes and Peyre's patches [3, 6, 15, 16, 18, 20]. On the 14th day in the rats of the experimental group, only the formation of small lymphoid follicles was noted, but their number and diameters were significantly smaller and lower than those in the spleen of the control group of rats. In the control group, sufficiently formed lymphatic follicles were detected during this period. Even by the 21st day of the postnatal period, in rat pups of the experimental group, the lymphoid tissue of the spleen remained relatively hypoplastic, without clear boundaries of the various structural zones of the lymphatic follicles. It should be noted that even in 30-day-old rat pups, the degree of structural and functional development of the white pulp of the spleen reached only the lower limits of the indicators noted in the animals of the control group.

When carrying out anthropometric measurements, it was established (see Table 1) that in the rat pups of the experimental group there was a decrease in body weight indicators (about 1.1 times on average) from birth up to 7 days of development, while a lag in body length (about 1.2 times on average) was observed in 7-21 day old rat pups. It should be noted that in rat pups born from females with CTH, it was found: in newborns, on the 3rd and 7th days, a decrease (by 1.2; 1.2 and 1.1 times, respectively) and 1.2-fold increase in the mass of the spleen in 15, 21 and 30-day-old rat pups.

Table 1

The correlation between the ratio of body weight, spleen weight and growth parameters of rats born from females with CTH in the dynamics of early postnatal ontogenesis

Morphometric parameters of rat pups	Gr. of animals	Age of animals (in days)					
		1	3	7	15	21	30
Rat weight, g	C	5,6±0,08	6,0±0,09 +	8,9±0,11 +	18,6±0,43 +	29,1±0,82 +	42,3±0,75 +
	E	5,1±0,11 *	5,3±0,13 **	8,1±0,12 **	16,9±0,42 +	26,8±0,55 +	34,7±1,14 +
Rat body length, mm	C	27,1±0,4 7	33,0±0,5 8	44,2±0,3 9	51,6±0,52	55,2±0,88	57,6±0,96
	E	23,9±0,4 3	27,1±0,5 2	36,4±0,4 8*	41,5±0,52 *	47,6±0,82 *	51,6±1,05
Absolute weight of the spleen, mg	C	7,4±0,34	20,9±0,8 9	31,6±1,0 4	67,7±2,92	108,8±3,2 9	138,1±4,8 4
	E	6,3±0,36 *	17,0±0,4 5*	22,9±0,6 9*	82,9±3,12 *	129,6±4,1 3*	161,6±4,2 5*

Note: - conditional abbreviations: **Gr. of animals** – group of animals; C - control; E - experienced;

+ - differences are significant at $P \leq 0.05$ relative to the previous development period

rats of one group.

* - differences are significant at $P \leq 0.05$ at the same development period, relative to the data of the control group of animals.

As a result of morphometric and cytometric studies, it was found that the white pulp of the spleen, in the form of lymphoid follicles, in rat pups of both the control and experimental groups begins to clearly differentiate already on the 7th day of postnatal development, but it should be noted that in the experimental group of animals, on average, a 1.5-fold decrease in the number and 1.2-fold decrease in the diameter of the nodules is observed, the continuation of this development trend is noted up to the 15th day of development. Conversely, on days 21 and 30, a 1.2-fold increase in the number is noted, and an increase in the diameter of lymphoid follicles is also observed (see Table 2).

Table 2

The average number and diameter of lymph nodes in the spleen of rats born from females with CTH in the dynamics of early postnatal ontogenesis

No.	Parameter under study	Gr. of animals	Rat age in days			
			7	14	21	30
1	Average number of nodules	C	5,8±0,01	7,4±0,37 ⁺	8,7±0,28 ⁺	12,5±0,22 ⁺
		E	3,7±0,16 [*]	5,2±0,13 ^{**}	10,6±0,22 ^{**}	17,3±0,25 ^{**}
2	Average nodule diameter	C	176,4±1,32	278,5±2,66 ⁺	329,6±2,47 ⁺	338,3±2,63 ⁺
		E	151,4±1,80	231,3±2,41 ^{**}	342,3±2,06 ^{**}	354,9±2,31 ⁺ *

We obtained interesting data during the cytometric studies of the spleen of rat pups of the control and experimental groups in the dynamics of postnatal development. If in the spleen of the control group of rat pups, there is a gradual restructuring of cellular relationships, which goes parallel to the structural and functional formation of the spleen in the dynamics of postnatal development. Naturally, processes associated with the development of the protective function characteristic of the white pulp, and, consequently, with the development of structures characteristic of the lymphoid tissue and an increase in cells of the lymphocyte-monocytic series, prevail here (see Table 3). Along with this, in the spleen of rats, the hematopoietic function characteristic of the red pulp of the spleen simultaneously decreases, with a decrease in cells characteristic of myeloid hematopoiesis.

A completely different picture is observed in the spleen of rats from the experimental group of animals. Up to 15 days of development in rat pups, there is a decrease in the average number of cells of the lymphocytic series, monocytes, macrophages, plasma cells and mast cells. Nevertheless, in the spleen of 21-day-old rat pups, there is an increase in cells of the lymphoid-monocytic series and mast cells (see Table 3).

Table 3

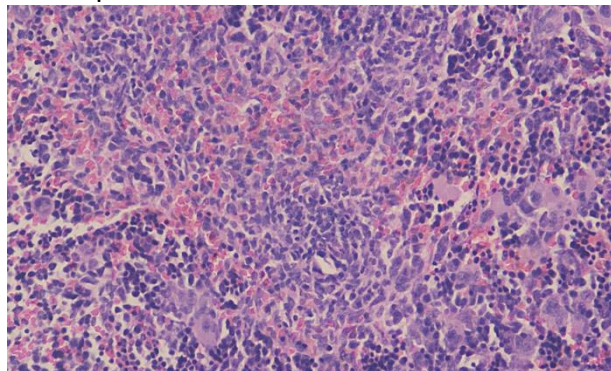
Cytogram of the white pulp of the spleen of rats born from females with CTH in the dynamics of early postnatal ontogenesis

Cell types	Gr. of animals	Terms of postnatal development (days)			
		7	15	21	30
Lymphoblast	C	200,3±6,74	274,5±9,68 ⁺	262,5±8,22	270,1±8,73
	E	174,3±7,66*	248,2±7,18**	284,8±7,53 ⁺	290,6±8,22
Prolymphocytes	C	215,1±7,84	306,3±12,22 ⁺	298,2±8,77	303,3±11,27
	E	179,8±5,82*	272,1±7,50**	325,9±8,20**	334,3±9,97
Medium lymphocytes	C	480,0±13,86	562,9±15,73 ⁺	701,4±14,11 ⁺	710,7±11,80
	E	451,9±11,07	532,1±11,01 ⁺	731,4±15,13 ⁺	730,7±12,08
Small lymphocytes	C	598,8±13,07	796,3±18,99 ⁺	903,3±16,04 ⁺	855,6±16,01
	E	552,4±12,24 ⁺ *	762,1±16,61 ⁺	957,1±13,26 ⁺ *	880,1±15,44 ⁺
Macrophages	C	116,3±5,16	207,2±8,39 ⁺	270,7±8,26 ⁺	288,5±9,27
	E	90,9±5,41*	171,7±5,82**	307,3±10,40 ⁺ *	312,9±8,99
Monocytes and monocyte-like cells	C	125,5±6,46	187,2±6,52 ⁺	218,5±8,89 ⁺	233,3±11,48
	E	88,7±5,00*	153,0±4,53**	237,5±8,07**	242,5±7,44
Reticular cells	C	545,3±13,54	552,6±13,61	561,2±15,69	575,2±17,66
	E	506,5±17,34	520,8±12,27	589,8±12,66 ⁺	582,8±10,72
Plasma cells	C	22,1±1,01	63,3±3,16 ⁺	94,6±5,03 ⁺	110,2±4,02
	E	12,2±0,91*	39,6±1,99**	112,2±4,37**	119,6±4,65
Mast cells	C	57,1±2,21	92,1±5,16 ⁺	106,5±7,18 ⁺	126,5±5,89
	E	32,2±1,52*	66,4±2,94**	129,2±5,20**	140,1±4,78

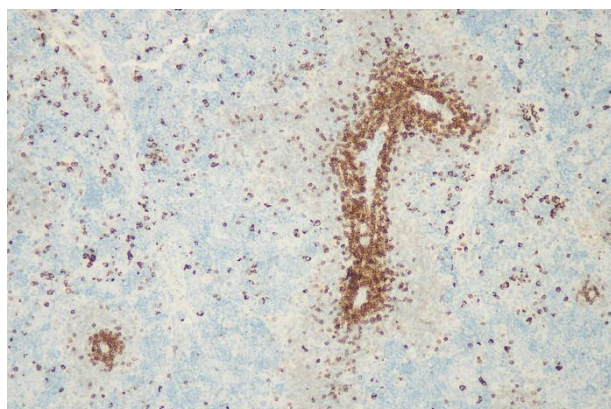
When conducting immunohistochemically researches using CD3 antibodies - markers of T- and CD20 antibodies of markers of B-lymphocytes in the spleen of rat pups of the control group of animals, a certain dynamic of changes in the ratio of these cells during the period of early postnatal ontogenesis was revealed. In the spleen of 1-3 day old rat pups, both T- and B-lymphocytes were distributed randomly over the entire area of the spleen. Starting from the 7th day of development, against the general background of the distribution of cells, they began to stand out grouped around the arterial clutches, as well as in the places of formation of lymphoid follicles, rosettes consisting mainly of 10-20 T-lymphocytes, for B-cells, against the general background of individual cells, an accumulation of cells in the form of rosettes of 3-10 or more cells in the places of the supposed formation of lymphoid follicles in the future was characteristic. It should be noted that the expression in T- and B-lymphocytes of the area of the spleen is well expressed, with the only difference being the density of the antigen detected in the cells, which increased in parallel with the increase in the period of development of postnatal ontogenesis. On days 21-30, in the white pulp of the spleen of rat pups, there is a significant increase in the accumulation of T-cells, which, in the form of separate islands of cells, replace rosettes. Rosettes of B cells are characterized by an increase in the number of cells up to 5-10. A somewhat different picture of immunohistochemical parameters was observed in the spleen of rat pups born from females with CTH researches. In rat pups, there was a pronounced lag in the formation of both T- and B-dependent zones, which are formed only by the 15th day of development. Visually, there

is a significant decrease in both T- and B-cells in the white pulp of the spleen. Only in the spleen of 30-day-old rat pups is the formation of T and B cell zones characteristic of the spleen of 21-day-old rat pups of the control group of animals.

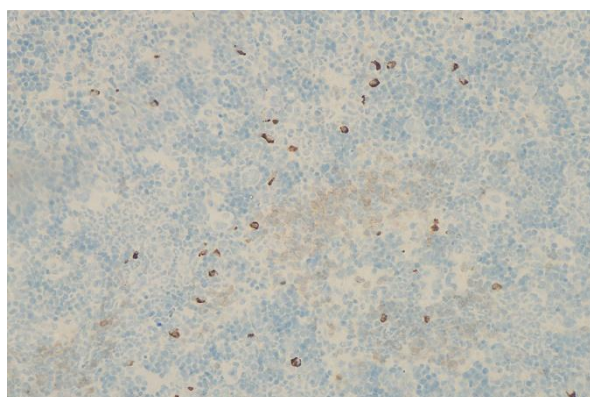
When analyzing the data obtained, it should be noted that a healthy child born at term from a healthy mother has sufficiently formed central and peripheral organs of the immune system and has certain homeostatic quantitative and functional parameters and reserves. But, it is also noteworthy that the lymphoid organs of young children respond to the penetration of pathogens and ordinary microflora into the body with severe hyperplasia, accompanied by the development



A



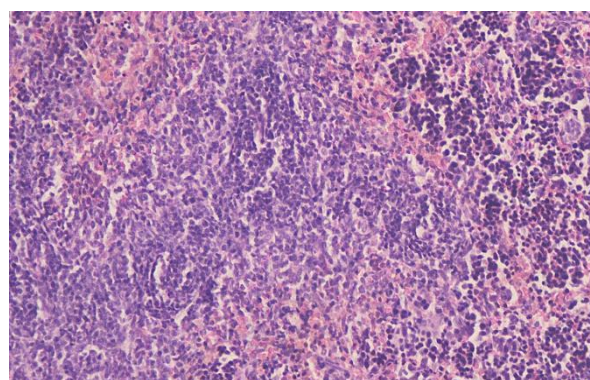
B



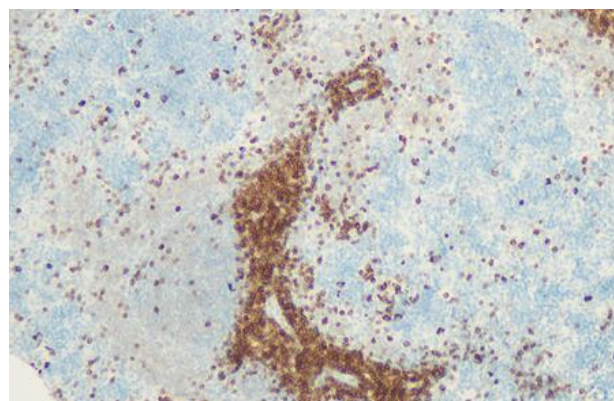
C

are visible. The emerging lymph node is highlighted. Paraffin cut. Hematoxylin-eosin staining. Magnification x 200 times;

Rat spleen from the control group on the 7th day after birth: (B) treated with CD3 monoclonal antibodies. Paraffin cut. Magnification x 130 (C) treated with CD20 monoclonal antibodies; Paraffin cut. Magnification x 130.

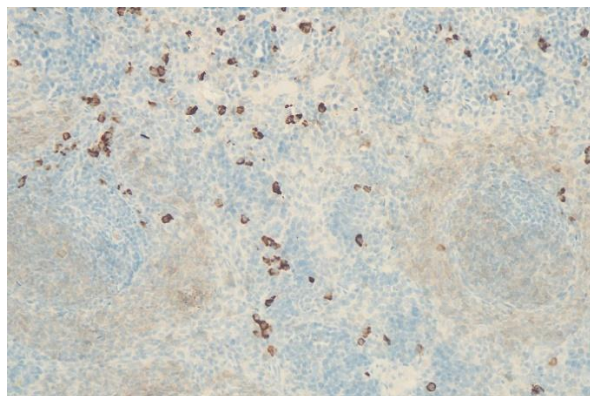


A



B

Picture 1 (A) Spleen of a rat pup of the control group of animals on the 7th day after birth. Clear boundaries of white and red pulp



C

Picture 2 (A) Spleen of a rat pup of the control group of animals on the 21st day after birth. The white pulp is the bifurcation of the per arterial clutch and the lymphoid follicle along the central artery. Paraffin cut. Hematoxylin -eosin staining. Magnification x 200 times

Spleen of a 21 day old rat pup: (B) treated with CD3 monoclonal antibodies. Paraffin cut. Magnification x 130; (C) treated with CD20 monoclonal antibodies. Paraffin cut. Magnification x 130;

of an inflammatory response, an increase in the volume and mass of peripheral lymphoid organs - lymph nodes, adenoids, spleen, that is, these "irritants" are stimulants for the development and formation of the infant's immune system [17, 19]. Along with this, as we pointed out earlier [7], after birth, the mammary glands of the mother are the only organ that connects two organisms and participates in the transfer of adoptive immunity to the newborn through mother's milk [8, 12, 17]. Nevertheless, unfortunately, this entire ideal system of genetically determined processes associated with the development of offspring is violated in the pathology of the maternal organism. In particular, diseases of the hepatobiliary system as a manifestation of extra genital pathology of the mother during pregnancy complicate the course of pregnancy itself and increase the likelihood of a prognostically unfavorable outcome for the offspring. Experimental researches have established that in the offspring of rats from females with chronic toxic hepatitis there are disturbances in the development of the digestive, endocrine and macrophage systems [1, 2, 4, 6].

Thereby, established in our study: reduction of body weight, growth and mass of spleen rats, lag in the development of white pulp, citrometric changes up to 15 days of postnatal ontogenesis, that is, during breastfeeding, there was a decrease in the amount and diameter of the lymphoid follicles, a decrease in lymphoid cells in the white pulp, and retardation of both t-B-lymphocytes are most likely associated with the negative influence of the mother of the mother. Detected after the transition of rat pups to a mixed diet, most clearly starting from the 21st day of development, the ongoing increase in: the area occupied by the white pulp, the number and diameter of lymphoid follicles; an increase in cellular infiltration of the organ and stabilization in the development of T- and B-dependent zones, most likely due to protective-compensatory reactions of the body of rat pups aimed at restoring the structure and function of the spleen.

CONCLUSION

Thus, under the influence of chronic toxic hepatitis of the mother, revealed in offspring born from female outbred rats with chronic toxic hepatitis, the features of the morphofunctional state of the spleen indicated significant and long-lasting changes in the postnatal morphogenesis of the organ. These changes were characterized by a delay in the formation of the spleen in the

period of early postnatal ontogenesis, that is, a slowdown in the transformation of the spleen from an organ of hematopoiesis into an organ of immune defense.

REFERENCES

1. Abdullayeva A.A. (2019). The influence of chronic toxic hepatitis of the mother on the formation of the offspring liver in early postnatal ontogenesis (pilot study). Actual problems of experimental and clinical medicine (pp. 405-405).
2. Abdullaev N.Kh., Karimov Kh.Ya. Liver in case of intoxication with hepatotropic poisons. - T.: Medicine. -1989. - 140 s.
3. Azizova F.Kh., Tukhvatulin F.F., Tursunmetov I.R., Tukhtaev K.R. Features of the formation of the immune system organs in rat pups born from females with chronic toxic hepatitis // Medical business (Kyiv "Health"). - 2001. - No. 2. - P.100-103.
4. Bryukhin G.V., Komarova T.M. Morphofunctional characteristics of peripheral blood monocytes and their precursors in the offspring of female rats with autoimmune liver damage // Human sport medicine. – 2016. – vol. 1, no. 1, pp. 42–50.
5. Christen corresponding U., Hinter Mann E. Pathogens and autoimmune hepatitis // Clin Exp Immunol. 2019 Jan; 195(1): 35–51.
6. Gafarova E. A. Initial and final stages of carbohydrate hydrolysis in the offspring of rats with chronic toxic hepatitis: Abstract of the thesis. dis. ... cand. honey. Sciences. - Tashkent, 2001. -18 p.
7. Khasanov B. B. Morphology of the mammary gland during pregnancy and lactation // Bukhara. Printing house "Sadridin Salim Buxoriy" at the Bukhara State University - 2022. - S. 120.
8. Kumar P, Dar Y, Kumar A. Functional anatomy of cow mammary glands with special reference to its defense mechanism Vergani G, Vergani D, Czaja: Int J Cow Sci 2022;6(2):30-31.
9. Kvaratskheliya A.G. Morphological characteristics of the thymus and spleen under the influence of factors of various origins. Review. ZhuMeredith B.A., Urbanski S., Swain M.G. Anti-TNF-induced autoimmune hepatitis Journal of Hepatology 2014 vol. 61 j 169–182. E-mail address: swain@ucalgary.ca.
10. Magri G. et al. Innate lymphoid cells integrate stromal and immunological signals to enhance antibody production by splenic marginal zone B cells. Nat. Immunol. 15, 354- 364 (2014).
11. Mieli-Vergani G, Vergani D, Czaja AJ et al Autoimmune hepatitis. Nat Rev Dis Primers 2018; 4:18017. [PubMed][Google Scholar]
12. Parker, M. G., Stellwagen, L. M., Noble, L., Kim, J. H., Poindexter, B. B., & Puopolo, K. M. (2021). Promoting human milk and breastfeeding for the very low birth weight infant. Pediatrics, 148(5).
13. Haley Patrick J. The lymphoid system: a review of species differences // Toxicol Pathol 2017; 30: P. 111-123.

14. Oripov, F., Blinova, S., Dekhkanov, T., & Davlatov, S. (2020). Development of immune structures of the leaning intestine of rabbits in early postnatal ontogenesis. *International Journal of Pharmaceutical Research*, 13(1), 299-301. doi:10.31838/ijpr/2021.13.01.042
15. Singh N., Gallagher H.C., Song R., Dhinsa J.K., Ostroff G.R., De Jesus M. RNA isolation from Peyer's patch lymphocytes and mononuclear phagocytes to determine gene expression profiles using nanostring technology// *J Biol Methods.*, 2018; 5(3):e 95. doi: 10.14440/jbm.8.
16. Snoeck V., Verfailhe T, Verdonck F. The jejuna Peyer s patches are the major inductive sites of the F4-specific immune response following intestinal immunization of pigs with F4 (K88) fibnae// *IJNaecine*, 2016. Vol.24. №18. 3812-20.
17. Thompson A, Monteagudo-Mera A, Cadenas M et al. Milk- and solid-feeding practices and daycare attendance are associated with differences in bacterial diversity, predominant communities, and metabolic and immune function of the infant gut microbiome. *Front Cell Infect Microbiol* 2015; 5: 3.
18. Voloshin V.N. and others. Morphology of the spleen in adult albino rats after whole-body exposure to low-level of toluene // *International Journal of Anatomy and Research*, hit *J Anat Res* 2014, Vol 2(2): P. 421-30. ISSN 2321- 4287.
19. Walker W. Bacterial Colonization of the Newborn Gut, Immune Development, and Prevention of Disease. *Nestle Nutr Inst Workshop Ser* 2017; 88: 23-33.
20. Yaglova N.V., Obernikhin S.S. Influence of activation of the immune system of the maternal organism in early pregnancy on the postnatal morphogenesis of the organs of the immune system of the offspring. *Reproduction problems*, 1, 2013. – C. 73-77.
21. Zufarov K.A., Tukhtaev K.R., Yuldashev A.Yu. Leukocytes and cells of loose connective tissue (ultrastructural and functional aspects). Tashkent, "Fan" UzSSR, 1979. S. 126.
22. Zufarov K.A., Tukhtaev K.R. Organs of the immune system (structural and functional aspects).–Tashkent: Fan.–1987.–232 p.