



NUTRACEUTICAL EFFECT OF ASHWAGANDA HERB (WITHANIA SOMNIFERA) AS USED FOR HYPERGLYCEMIC RATS

Fatma El-Sherif, Eman Fathey Helal*, Lamia Diab

Article History: Received: 02.05.2023

Revised: 03.06.2023

Accepted: 09.06.2023

ABSTRACT: Hyperglycemia is the most common metabolic disturbance disorder and has been considered as one of the major mortality causes globally. Dietary intake of phenolic compounds, flavonoids and antioxidants can offer evidence to promote the restoration of induced hyperglycemia harm.

Objective: This study has been done to investigate the impact of ashwagandha roots powder and aqueous extract on rats with increased glucose levels induced by alloxan. **Methods:** Thirty-six male white albino rats their weights between 150 ± 10 , were enrolled. For rats' adaptation, they were fed on basal diet for 7 days. After that, they were classified into two main categories as follows: The first main category (6 rats): Negative control (-ve), normal rats fed on the basal diet. The second one (30 rats): The hyperglycemic rats which were treated by intraperitoneal injection of alloxan 150 mg/kg of their weight. Then the second main group were subdivided into five groups (6 rats each) depending on that: Group (2): Fed on the basal diet as a positive control (+ve). Group (3): Fed on the basal diet containing (2.5% ashwagandha roots powder). Group (4): Fed on the basal diet containing (5% ashwagandha roots powder). Group (5): Fed on the basal diet and given ashwagandha roots extract (2.5%) orally. Group (6): Fed on the basal amount of diet and given ashwagandha roots extract (5%) orally. Serum samples after 28 days of the experiment were assessed for biochemical markers.

Results: The obtained results revealed that, treatment by alloxan caused remarkable hyperglycemia and increase levels of cholesterol, triglycerides, VLDL-c, uric acid, urea, LDL-c, creatinine, ALT, AST, and ALP, and reduced HDL-c. Treating rats which were injected by alloxan with the levels from ashwagandha roots powder and extract (2.5 & 5%) showed decreased levels of serum glucose, kidney function, liver function, TC, LDL-c, TG & VLDL-c, and elevated serum HDL-c. Also improved other parameters including BWG, FI and FER.

Conclusion: Rats treated with ashwagandha roots extract (5%) revealed an improvement in the blood glucose, functions of kidney and liver, lipid profile and original histological structure which was also restored.

Keywords: Diabetic, Glucose, Kidney function, Liver function, Lipid profile, Ashwagandha (*Withania somnifera*), Withaferin A.

Department of Nutrition and Food Science, Faculty of Home Economics, Menoufia University, Egypt.

*Corresponding Author: Eman Fathey Helal; E mail: Emanfathey22@gmail.com; Mobile: +201159537407

DOI: 10.48047/ecb/2023.12.7.30

1. INTRODUCTION:

Egypt is one of the countries having a high number of diabetes, globally. The major public health problem of diabetes has had a negative impact on the Egyptian economy. About 15.5% of persons between the ages of 20 and 79 have diabetes. Egyptian youth's poor lifestyle choices, unhealthy eating habits, and sedentary lifestyle may be to blame for this alarming rise in the prevalence of diabetes (Hegazi *et al.*, 2015).

As a result of increased obesity, reduction in activity, and aging of individuals, the incidence of hyperglycemia has raised over the past 20 years. The prevalence is equally among males and females. The highest prevalence of diabetes was recorded from China, the United States, India, Russia and Brazil. Families with low to medium incomes are more predisposed to suffer from hyperglycemia (Rawlings *et al.*, 2019).

Type 2 diabetes mellitus (T2DM) is known to cause serious repercussions, such as long-term

difficulties in many essential organs, and to impair protein, lipid, and glucose metabolism (Garcia-Garcia *et al.*, 2020). Insulin independent diabetes mellitus (T2DM) is a metabolic condition occurred due to lack of insulin and/or the tissues' inability to respond to it and metabolize glucose, which leads to chronic hyperglycemia (Hoyer, 2004).

Chronic vascular issues are prone to develop in people with T2DM. The two main types are microvascular issues and macrovascular difficulties. The three most typical microvascular side effects are retinopathy, nephropathy, and neuropathy. While cardiac, peripheral arterial, and cerebrovascular diseases are the most common macro vascular effects of diabetes. Diabetic nephropathy (DN), a chronic microvascular disease characterized by decreased renal function and increased albumin excretion in the urine, is mostly caused by diabetes mellitus. The rising prevalence of DN has also increased the morbidity and mortality of T2DM due to end-stage renal disease. Diabetes is a chronic condition that can

have major side effects on numerous important organ systems (Salama *et al.*, 2023).

Plants and herbal remedies have been utilized for medicine, flavor, smell, and other purposes since the dawn of time. The research has validated a number of these assertions regarding the usage of various plants in traditional medicine. The low toxicity of therapeutic herbs is the main justification for their usage. The effectiveness and safety of herbal therapy have drawn the attention of the majority of scientists studying pharmacological plants (Umadeviet *et al.*, 2012).

Withaniasomnifera, sometimes referred to as winter cherry, ashwagandha, Indian ginseng, and other names, is a significant medicinal plant in the solanaceae family that has been used in traditional and ayurveda medicine for more than 3,000 years (Umadeviet *et al.*, 2012).

Ashwagandha is a herb that is categorized as a Rasayana in Indian traditional medicine (*Ayurveda*), a class of drugs derived from plants that are said to improve physical and mental health, increase resistance to disease and other many harmful environmental factors, improve the body in weaken conditions, and lengthen life. The plant's aerial components (leaves and roots) are both utilized medicinally. Alkaloids including isopelletierine, ashwagandha ,cuscohygrine, anahygrine, anaferine, , topine, somniferin saponins, withaferin A , sitoindosides, withanolides, , withasomnidieone, and withanone are only a few of the more than 35 chemical components that have been identified (Kulkarni and Dhir, 2008; Singh *et al.*, 2011).

According to studies, ashwagandha's antidiabetic effects are mediated by an increase in insulin secretion and cellular glucose absorption in both skeletal and adipose cells. While the former process is produced by both leaf and root extracts, the latter only happens with leaf extracts. Withaferin A appears to be the primary chemical active in these reactions (Gorelick *et al.*, 2015).

Ashwagandha's antioxidant activity, which has been demonstrated in healthy volunteers and supported by several of the research mentioned above, may be a factor in the beneficial effects observed in type 2 diabetics. The antidiabetic effects of ashwagandha may possibly be partially mediated by its balancing effect on the hypothalamic-pituitary-adrenal HPA axis due to the fact that stress and increases in cortisol levels can have a deleterious influence on blood glucose management (Kuchewaret *et al.*, 2014; Nayak *et al.*, 2015).

For many years, ashwagandha has been recognized as a potent rejuvenator, , remedy for a variety of ailments, and general health tonic. It has powerful antibacterial, anti-inflammatory, hypoglycemic, hypolipidemic, anxiolytic, and antioxidant properties. Additional effects were seen, including those that were anti-stress, anti-aging, anti-Alzheimer's, anti-Parkinsonian, anti-cancer,

cardioprotective, anti-cortisol, antidepressant, and macrophage-activating (Shibu and Charan, 2018).

2. MATERIAL AND METHODS

2.1. Materials:

Plants: Ashwagandha roots were purchased from the Haraz Company AldarbAlahmar, Egypt.

Chemicals: Alloxan was obtained from El-Gomhoria Company for Chemicals, Drugs of Medical Equipment's, Cairo, Egypt.

2.2. Methods:

2.2.1. Diets:

Diet components were casein, L -Cystine, vitamins mixture, choline chloride, cellulose, mineral mixture, and methanol were obtained from El-Gomhoria Company for Drugs and Medical Equipments, Cairo, Egypt according to Reeves *et al.* (1993).

2.2.2. Induction of hyperhlycemia:

Hyperglycemia was stimulated in fasted rats for whole night using a single intrusion of intraperitoneal fresh Alloxan monohydrate prepared in normal saline (150 mg/kg body weight) based on Desaiand Bhide (1985).

2.2.3. Experimental design:

For acclimatization, 36 adult male albino rats were fed a basal diet for 7 days. After that, they were classified into two main categories as follows: The first main category (6 rats): Negative control (-ve), normal rats fed on the basal diet. The second one (30 rats): The hyperglycemic rats which were treated by intraperitoneal injection of alloxan 150 mg/kg of their weight. Then the second main group were subdivided into five groups (6 rats each). For 28 days, each group received food depending on the following categories:

Group (1): ("-"Control); n=6, feed on basal diet only.

Group (2): ("+"Control); n=6, received alloxan and were fed on basal diet only.

Group (3): n=6, received alloxan then basal diet involves 2.5 %ofashwagandha roots powder

Group (4): n=6, received alloxan solution, followed by basal diet includes 5%of ashwagandha roots powder.

Group (5): n=6, received alloxan solution treatment before fed on basal diet and given oral dose (2.5% of ashwagandha roots extract).

Group (6): n=6, received alloxan solution then fed on basal diet and given oral dose (5%of ashwagandha roots extract).

2.2.4. Biological Evaluation:

According to Chapmanet *al.*, (1959) the evaluation of the diet was done during a period of 28 days by determining feed efficiency ratio (FER) and body weight gain (BWG) . The ingested food was daily was recorded (feed intake).

2.2.5. Blood Sampling:

At the end of the experiment rats were fasted overnight then anesthetized with diethyl ether.

Serum recovered by aspiration of blood samples from hepatic portal vein in clean and dry tube centrifuged then stored at -20°C frozen for analysis **Malhotra (2003)**.

Quantitative estimation of glucose was performed based the strategy stated by **Kaplan (1984)**, serum aspartate aminotransferase (AST) and serum alanine aminotransferase (ALT) were assessed as U/L based on **Yound (1975)**, serum alkaline phosphatase (ALP) was evaluated U/L based on **Tietzet al. (1983)**, total cholesterol was evaluated according to **Allain et al. (1974)**, and enzymatic colorimetric evaluation of triglycerides was done based on **Fossati and Prencipe (1982)**. The assessment of HDL was performed according to the strategy of **Lopez (1977)**, evaluation of LDL and VLDL was performed in accordance with **Lee and Nieman (1996)**, urea evaluation was in line with **Patton and Crouch (1977)**, uric acid was estimated in agreement with **Fossati and Prencipe**

(1980). Serum albumin was done to the approach of **Doumaset al. (1973)**.

Very low density lipoprotein cholesterol (VLDL-c) and Low density lipoprotein cholesterol (LDL-c) were estimated based on the methods of **Lee and Nieman (1996)** as follows:

$$\text{VLDL-c (mg/dL)} = \text{Triglycerides} / 5$$

$$\text{LDL-c (mg/dL)} = \text{Total cholesterol} - (\text{HDL-c} + \text{VLDL-c}).$$

Kidney and liver underwent removal then washing in saline solution. The organs then were wiped by filter paper, weighted, and kept in formalin solution 10% frozen for histological analysis in line with the strategy reported by **Bancroft et al. (1996)**.

STATISTICAL ANALYSIS:

The data were processed statistically by using a computerized platform by one way ANOVA test. Findings were presented as mean±SD. Variations between treatments at $p \leq 0.05$ were considered significant (**SAS et al., 1985**).

RESULTS AND DISCUSSION:

Table (1): Impact of ashwagandha roots powder and aqueous extract on body weight gain (BWG), feed intake (FI) and feed efficiency ratio (FER) of hyperglycemic rats

Parameters Groups	BWG (g) Mean ± SD	FI (g) Mean ± SD	FER Mean ± SD
G1: Control -ve	1.07 ± 0.03 ^a	26.8 ± 1.14 ^a	0.039 ± 0.001 ^{ab}
G2: Control +ve	0.5 ± 0.06 ^c	20.1 ± 0.7 ^{bc}	0.025 ± 0.006 ^c
G3: ARP (2.5%)	0.69 ± 0.05 ^d	18.4 ± 0.2 ^c	0.037 ± 0.003 ^b
G4: ARP (5%)	0.87 ± 0.01 ^c	18.5 ± 0.8 ^c	0.047 ± 0.002 ^a
G5: AREx. (2.5%)	0.91 ± 0.02 ^{bc}	19.86 ± 1.2 ^{bc}	0.046 ± 0.001 ^a
G6: AREx. (5%)	0.98 ± 0.04 ^b	21.1 ± 0.9 ^b	0.047 ± 0.002 ^a
LSD	0.069	1.685	0.005

Means in the same column with different letters are significantly different at $P \leq 0.05$

* ARP, Ashwagandha Roots powder and AREx, Ashwagandha Roots extract

Results in table (1) show the impact of ashwagandha roots on body weight gain (BWG), feed efficiency ratio (FER) and feed intake (FI) in Alloxan injected rats. The mean of (BWG) of control (+) was lower than control (-), being 0.5 ± 0.06 & 1.07 ± 0.03 respectively. The best (BWG) level displayed for group 6 (ashwagandha roots extract 5%) when compared to (+) control.

The mean level of (FI) of (-) control was higher than (+) control, being 20.1 ± 0.7 & 26.8 ± 1.14 respectively. The best (FI) found for group 6 (ashwagandha roots extract 5%) when compared to control (+). Also, the mean level of FER of control (+) was lower than control (-), being $0.025 \pm$

0.006 & 0.039 ± 0.001 , respectively. The best FER was found for group 4 & 6 when compared to (+) control.

Udayakumaret al. (2009) discovered that while diabetic rats lost weight, when given ashwagandha root extracts orally for eight weeks, the diabetic rats were prevented from losing a significant amount of weight. **Arafa (2021)** investigated that ashwagandha roots powder (ARP) in different levels (2.5 & 5%) increased BWG % on rats suffering from diabetes

Ali (2021) reported that ashwagandha powder (100 mg/kg) and ashwagandha extract (10 mg/kg) increases body weight gain and feed efficiency ratio of rats on the reproductive hormones of male rats.

Table (2): Effect of ashwagandha roots powder and aqueous extract on serum glucose (mg/dl) of hyperglycemic rats

Parameters	Glucose (mg/dL) Mean ± SD
G1: Control –ve	75.3± 0.66 ^f
G2: Control +ve	235.8 ± 1.3 ^a
G3: ARP (2.5%)	110.3 ± 0.33 ^b
G4: ARP (5%)	108.2 ± 0.27 ^c
G5: AREx. (2.5%)	104.5 ± 1.3 ^d
G6: AREx. (5%)	102.7 ± 0.09 ^e
LSD	1.11

Means in the same colmun with different letters are significantly different at $P \leq 0.05$.

* ARP, ashwagandha roots powder and AREx, ashwagandha roots extract.

In table (2), the mean level of glucose in (+) control was found more compared to (-) one, being 235.8 ± 1.3 and 75.3 ± 0.66 (mg/dl) ,respectively. The level of serum glucose was better in group 4 (basal diet containing 5% ashwagandha root extract) when compared to (+) control.

Noshahret al. (2015) found that serum glucose was considerably lower in WS + fructose-fed rats compared to fructose-alone-fed rats, hence showing its anti-hyperglycemic activity. This study is

agreewith **Anweret al. (2008)** who reported that treatment with aqueous extract of ashwagandha (200 & 400 mg/kg) orally once daily for 5 weeks reduced blood glucose levels on sensitivity of insulin in non-insulin-dependent diabetes mellitus rats.**Tekulaet al. (2018)** revealed that withaferin A can efficiently control induction of type 1 diabetes in rats via signaling modulation of Nrf2/NFκB and as a result has considerable potential for therapy.

Table (3): Effect of ashwagandha roots powder and aqueous extract on serum total cholesterol (TC) and triglycerides (TG) (mg/dl) of rats with higher glucose levels

Parameters	TC(mg/dL) Mean ± SD	TG(mg/dL) Mean ± SD
G1: Control –ve	81.03 ± 0.21 ^f	80.3 ± 0.25 ^f
G2: Control +ve	102.12 ± 0.73 ^a	121.5 ± 0.73 ^a
G3: ARP (2.5%)	96.05 ± 0.9 ^b	92.2 ± 0.43 ^b
G4: ARP (5%)	94.21± 0.13 ^c	90.1 ± 0.39 ^c
G5: AREx. (2.5%)	92.51 ± 0.25 ^d	83 ± 0.22 ^d
G6: AREx.(5%)	87.31± 0.08 ^e	61 ± 0.19 ^e
LSD	0.6	0.732

Means in the same colmun w ith different letters are significantly different at $P \leq 0.05$.

* ARP, ashwagandha roots powder and AREx, ashwagandha roots extract.

In table (3), the mean of TC of control (+) was elevated compared to control (-), being 102.12 ± 0.73 and 81.03 ± 0.21 mg/dl respectively. The level of serum TC was better in groups 6 (rats fed on basal diet containing 5% ashwagandha roots extract) in comparison to control (+).

The mean triglycerides TG level in control (+) group was found more than control (-), being 121.5 ± 0.73 and 80.3 ± 0.25 mg/dl respectively. Serum TG level was better in group 6 when compared to control (+).

Our finding were in line with that of **Ojha and Arya (2015)**, where herbal mixture containing ashwagandha used in conjunction with conventional anti ischemic agents reduced total cholesterol, and triglycerides and raised high density lipoprotein cholesterol patients after myocardial infarction. **Anweret al. (2017)** demonstrated that 5 weeks administration of as0hwagandha (200 and 400 mg/kg) once daily orally, resulted in a remarkable ($P < 0.001$) decrease in TC and TG levels.

Table (4): Effect of ashwagandha roots powder and aqueous extract on serum HDLc, LDLc&VLDLc (mg/dl) of hyperglycemic rats

Parameters Groups	HDL-c (mg/dl) Mean ± SD	LDL-c (mg/dl) Mean ± SD	VLDL-c (mg/dl) Mean ± SD
G1: Control –ve	41.25 ± 0.23 ^a	23.72 ± 0.32 ^f	16.06 ± 0.19 ^c
G2: Control +ve	33.41 ± 0.12 ^f	44.41 ± 0.21 ^a	24.3 ± 0.25 ^a
G3:ARP (2.5%)	34.13 ± 0.03 ^e	43.48 ± 0.03 ^b	18.44 ± 0.04 ^b
G4:ARP (5%)	36.35 ± 0.07 ^d	39.86 ± 0.09 ^c	18.02 ± 0.02 ^b
G5: AREx. (2.5%)	38.01 ± 0.05 ^c	37.9 ± 0.06 ^e	16.6 ± 0.5 ^c
G6:AREx.(5%)	39.09 ± 0.08 ^b	38.2 ± 0.05 ^d	12.2 ± 0.8 ^d
LSD	0.208	0.292	0.723

Means in the same column with different letters are significantly different at $P \leq 0.05$.

* ARP, ashwagandha roots powder and AREx, ashwagandha roots extract.

In table (4), the mean of HDL_C in (-) control group was more than (+) control, being 41.25 ± 0.23 and 33.41 ± 0.12 mg/dl respectively. Serum HDL_C was better in group 6 in comparison to control (+). The mean of LDL_C in control (+) found more than control (-), being 44.41 ± 0.21 and 23.72 ± 0.32 mg/dL, respectively. Serum LDL_C was better in group 5 (rats fed on basal diet containing 5% ashwagandha roots extract) when compared to control (+). Also, the mean of VLDL_C in (-) control was lower than (+) control, being 24.3 ± 0.25 and 16.06 ± 0.19

mg/dL, respectively. Serum VLDL_C was better in group 6 than control (+). These findings are in accordance with Anwer *et al.* (2017), where the ashwagandha caused a remarkable ($P < 0.001$) decrease in LDL-c, & VLDL-c levels with remarkable increase of HDL-c levels.

Jha and Paul (2020) also illustrated that ashwagandha at a dose of 1000 mg/Kg b.w. was given for 4 weeks orally, induced reduction in LDL level and increased HDL level in swiss albino mice.

Table (5): Effect of ashwagandha roots powder and aqueous extract on liver enzymes (AST, ALT and ALP) of hyperglycemic rats

Parameters Groups	AST (U/L) Mean ± SD	ALT (U/L) Mean ± SD	ALP (U/L) Mean ± SD
G1: Control –ve	65.18 ± 0.35 ^f	41.13 ± 0.23 ^f	149.72 ± 1.3 ^f
G2: Control +ve	117.03 ± 0.83 ^a	90.53 ± 0.45 ^a	254.33 ± 1.6 ^a
G3:ARP (2.5%)	107.51 ± 0.62 ^b	63.33 ± 0.73 ^b	203.54 ± 1.8 ^b
G4:ARP (5%)	105.32 ± 0.32 ^c	61.75 ± 0.4 ^c	198.21 ± 1.51 ^c
G5: AREx. (2.5%)	103.42 ± 0.82 ^d	50.13 ± 0.53 ^d	183.35 ± 1.23 ^d
G6:AREx.(5%)	95.77 ± 0.14 ^c	49.23 ± 0.28 ^e	165.54 ± 1.12 ^e
LSD	1.423	0.831	2.572

Means in the same column with different letters are significantly different at $P \leq 0.05$.

* ARP, ashwagandha roots powder and AREx, ashwagandha roots extract.

In table (5), the mean of AST in (+) control found more than (-) control, being 117.03 ± 0.83 and 65.18 ± 0.35 (U/L), respectively. Group 6 underwent the best treatment compared to (+) control. The mean of ALT in control (+) found more than control (-), being 90.53 ± 0.45 and 41.13 ± 0.23 (U/L), respectively. Group 6 experienced the best treatment compared to (+) control. Also, the mean ALP in control (+) group was higher than control (-), being 254.33 ± 1.6 and 149.72 ± 1.3 (U/L), respectively. Group 6 displayed the lowest mean of ALP level in comparison to control (+).

These results supported by published by Sultana *et al.* (2012) who demonstrated considerable low levels of liver enzymes which return to normal level in the ashwagandha pretreated and gentamicin treated rats giving an evidence that, such extract may have hepatoprotective influences against gentamicin toxicity.

Also, Sabiba *et al.* (2013) and Jamuna *et al.* (2018) proposed that ashwagandha have impacts on promising hepatic protection. Treatment of the diabetic rats with ashwagandha root extract have positive efficacy on alterations of AST, ALT and ALP to their normal (Swamy *et al.*, 2019).

Table (6): Effect of ashwagandha root powder and aqueous extract on serum creatinine, uric acid and urea of rats with higher glucose levels

Parameters Groups	Urea (mg/dL) Mean ± SD	Creatinine (mg/dL) Mean ± SD	U.A (mg/dL) Mean ± SD
G1: Control -ve	21.13 ± 0.29 ^f	0.58 ± 0.04 ^d	3.31 ± 0.24 ^d
G2: Control +ve	55.67 ± 0.33 ^a	0.97 ± 0.09 ^a	5.12 ± 0.33 ^a
G3:ARP (2.5%)	47.25 ± 0.27 ^b	0.88 ± 0.01 ^b	5.12 ± 0.18 ^a
G4:ARP (5%)	37.17 ± 0.23 ^c	0.77 ± 0.02 ^c	4.8 ± 0.23 ^a
G5: AREx. (2.5%)	31.15 ± 0.29 ^d	0.71 ± 0.03 ^c	4.35 ± 0.15 ^b
G6:AREx.(5%)	28.07 ± 0.13 ^e	0.6 ± 0.05 ^d	3.89 ± 0.11 ^c
LSD	0.471	0.085	0.407

Means in the same column with different letters are significantly different at $P \leq 0.05$.

* ARP, ashwagandha roots powder and AREx, ashwagandha roots extract.

In table (7), the mean urea in control (+) was more than control (-), being 55.67 ± 0.33 and 21.13 ± 0.29 mg/dl, respectively. Group 6 displayed better findings as compared to (+) control.

Regarding creatinine, the mean level in control (+) found more than control (-), being 0.97 ± 0.09 and 0.58 ± 0.04 mg/dl, respectively. Better treatment was found for the group 6 when compared to (+) one. Regarding uric acid, the mean level in control (+) found more than control (-), being 5.12 ± 0.33 and 3.31 ± 0.24 mg/dl, respectively. Group 6 recorded better result as compared to control (+).

This study is in line with **Grunz-Borgmann et al. (2015)** who proposed that ashwagandha may act as a botanical agent for the renal dysfunction treatment. Also, **Rasheed et al. (2020)** revealed that renal toxicity in albino Wistar rainduced by cisplatin could be modified by ashwagandha root extract evidenced through the tests of renal function.

HISTOPATHOLOGICAL RESULTS:

Liver histopathological examination:

Rats liver in group 1 (negative) displayed the histological features of normal hepatic lobule (Photo

1). In contrast, that from group 2 (positive) exhibited hepatocellular vacuolar degeneration, widening of hepatic sinusoids (photo 2), congestion in blood vessel of hepatoportal, biliary epithelium hyperplasia with geneses of newly bile ductules and portal edema (Photo 3). However, some sections from group 3 (ashwagandha roots powder 2.5%) showed mild hepatocellular vacuolar degeneration of some hepatocytes (Photo 4) and mild congestion of central vein (photo 5), whereas, other histopathological sections revealed no alterations (Photo 6). Furthermore, several liver examination from group 4 (ashwagandha roots powder 5%) described mild activation of Kupffer cells (Photo 7), mild hepatocellular vacuolar degeneration of some hepatocytes and mild congestion of hepatic sinusoids (Photo 8), whereas, other sections small focal hepatocyte necrosis related to infiltration of inflammatory cells (Photo 9). Otherwise, liver of rats from groups 5 & 6 (ashwagandha roots extract 2.5 & 5%) exhibited no histopathological changes (Photos 10 & 11).

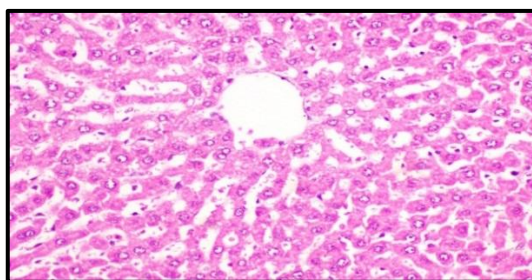


Photo (1): Photomicrograph of liver of rat from group 1 (negative) shows the normal histological architecture of hepatic lobule (H & E X 400)

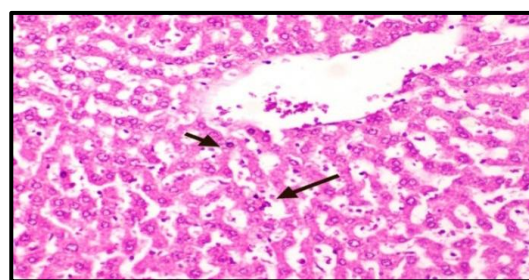


Photo (2): Photomicrograph of liver of rat from group 2 (positive) displaying hepatocellular vacuolar degeneration and dilatation of hepatic sinusoids (H & E X 400).

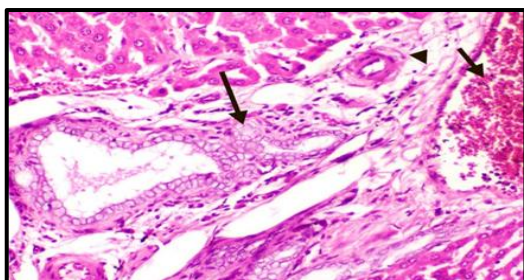


Photo (3): Photomicrograph of liver of rat from group 2 (positive) showing congestion of hepatoportal blood vessel, hyperplasia of biliary epithelium with formation of newly formed bile ductules and portal edema (H & E X 400).

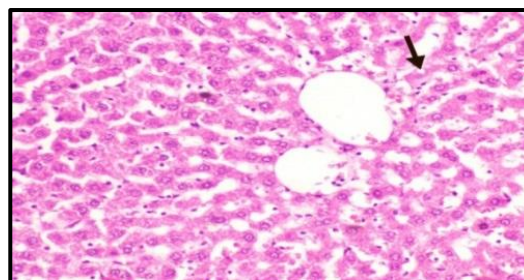


Photo (4): Photomicrograph of liver of rat from group 3 (ashwagandha roots powder 2.5%) displaying slight hepatocellular vacuolar degeneration of some hepatocytes (H & E X 400).

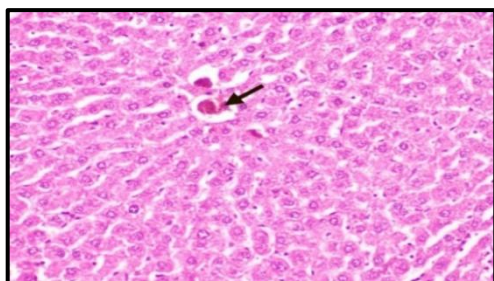


Photo (5): Photomicrograph of liver of rat from group 3 (ashwagandha roots powder 2.5%) showing slight congestion of central vein (H & E X 400).

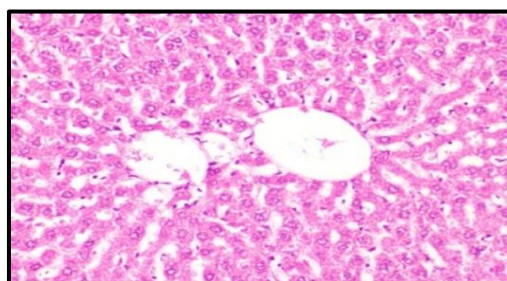


Photo (6): Photomicrograph of liver of rat from group 3 (ashwagandha roots powder 2.5%) showing no histopathological changes (H & E X 400).

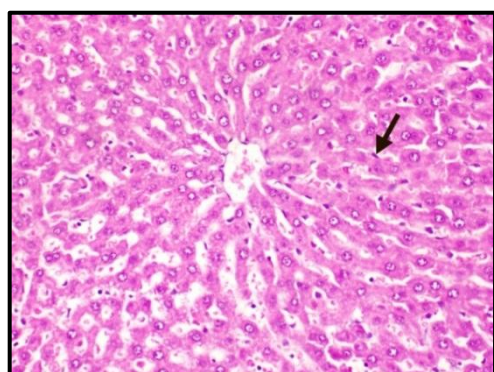


Photo (7): Photomicrograph of liver of rat from group 4 (ashwagandha roots powder 5%) showing slight Kupffer cells activation (H & E X 400).

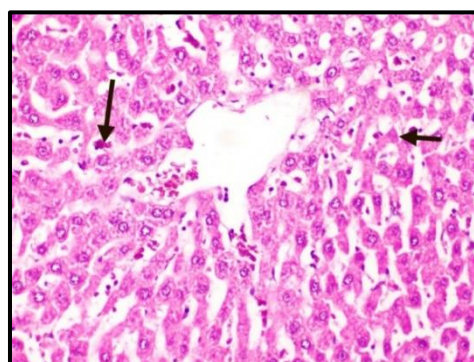


Photo (8): Photomicrograph of liver of rat from group 4 (ashwagandha roots powder 5%) showing slight hepatocellular vacuolar degeneration of some hepatocytes and slight congestion of hepatic sinusoids (H & E X 400).

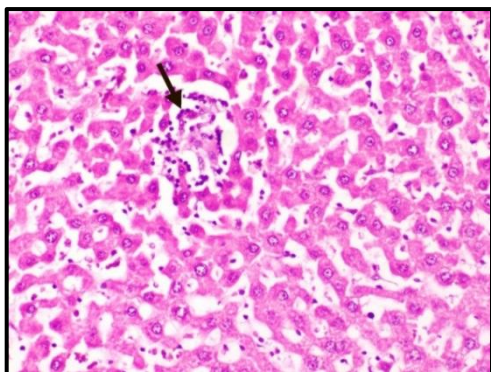


Photo (9): Photomicrograph of liver of rat from group 4 (ashwagandha roots powder 5%) showing small focal hepatic necrosis associated with inflammatory cells infiltration (H & E X 400).

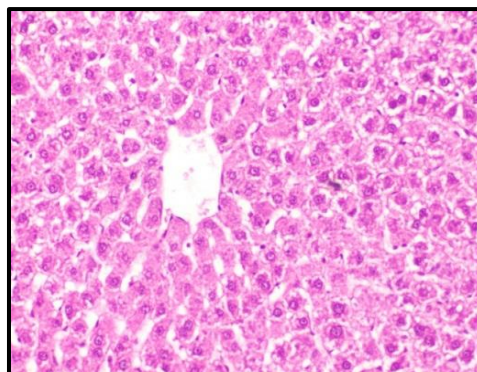


Photo (10): Photomicrograph of liver of rat from group 5 (ashwagandha roots extract 2.5%) showing no histopathological changes (H & E X 400).

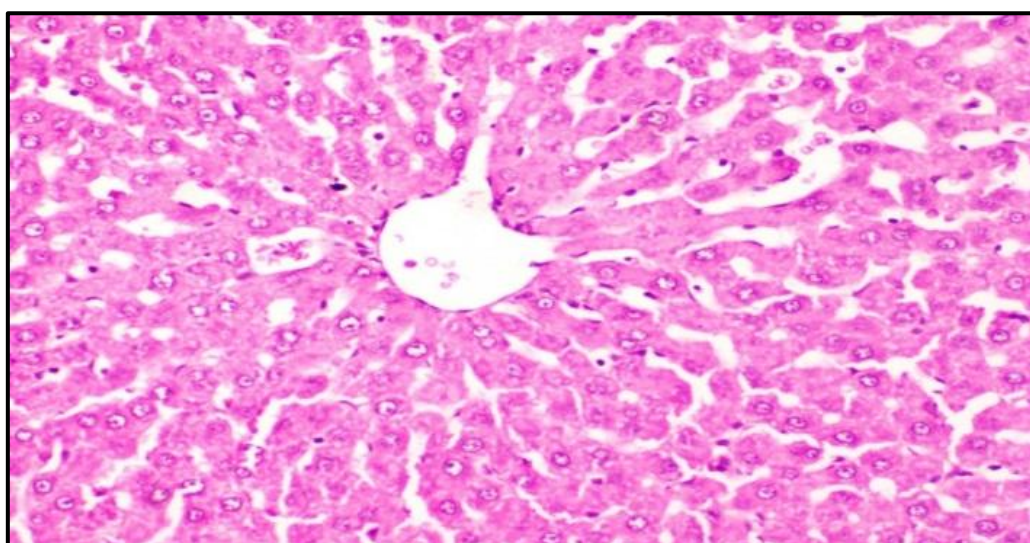


Photo (11): Photomicrograph of liver of rat from group 6 (ashwagandha roots extract 5%) showing no histopathological changes (H & E X 400).

Histopathological examination of kidney:

Group 1 (negative) rats' kidney displayed histological features of normal renal parenchyma; normal renal medulla and cortex (Photos 12 &13). On the other hand, kidney sections of group 2 (positive) rats displayed congestion of renal blood vessels (Photo 14), severe vacuolar degeneration of renal tubules epithelium (Photos 15 &16), peritubular inflammatory cells infiltration and congestion of intertubular blood capillaries (Photo17)., whereas, other sections showed mild vacuolar degeneration of some renal tubules epithelium (Photos 18 & 19) and mild congestion of glomerular tufts (Photo 20). Furthermore, some sections from group 4

(ashwagandha roots powder 5%) described mild vacuolar degeneration of some renal tubules epithelium and glomerular tuft endothelium (Photo 21) as well as slight perivascular edema (Photo 22), whereas, other sections exhibited no histopathological changes (Photo 23&24) Moreover, some kidneys sections of rats from groups 6 (ashwagandha roots extract 5%) exhibited vacuolar degeneration of some renal tubules epithelium and mild congestion of glomerular tuft (Photos 25), whereas, other sections exhibited no histopathological changes and appeared histologically normal (Photos 26& 27).

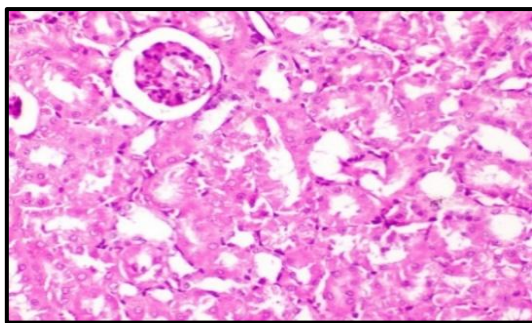


Photo (12): Photomicrograph of kidney of rat from group 1(negative) showing the normal histological structure of renal parenchyma (H & E X 400).

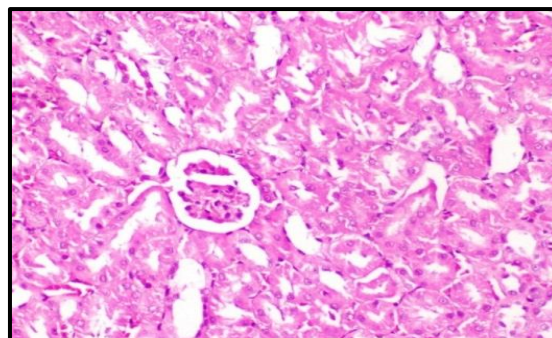


Photo (13): Photomicrograph of kidney of rat from group 1(negative) showing the normal histological structure of renal parenchyma (H & E X 400).

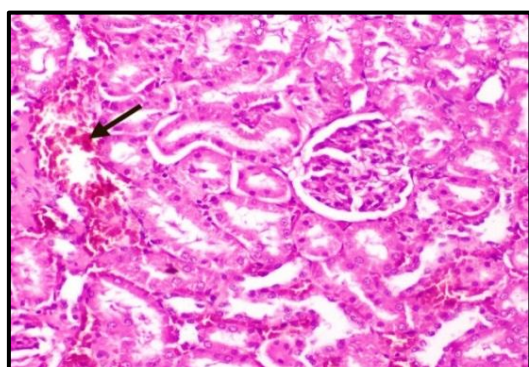


Photo (14): Photomicrograph of kidney of rat from group 2 (positive) showing congestion of renal blood vessels (H & E X 400).

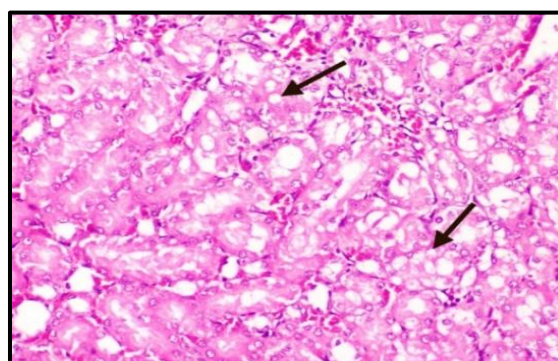


Photo (15): Photomicrograph of kidney of rat from group 2 (positive) showing marked vacuolar degeneration of epithelial lining renal tubules (H & E X 400).

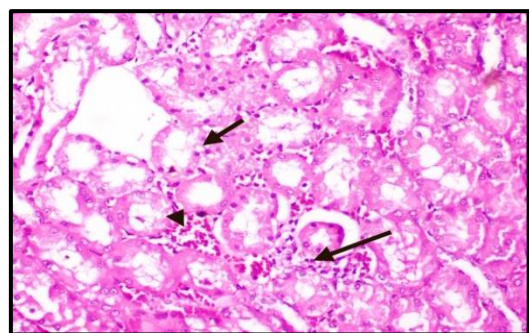


Photo (16): Photomicrograph of kidney of rat from group 2 (positive) showing marked vacuolar degeneration of epithelial lining renal tubules, peritubular inflammatory cells infiltration and congestion of intertubular blood capillaries (H & E X 400).

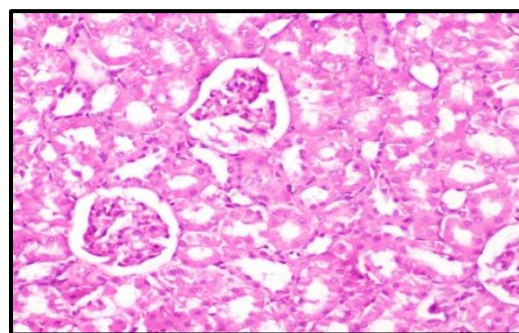


Photo (17): Photomicrograph of kidney of rat from group 3 (ashwagandha roots powder 2.5%) showing peritubular inflammatory cells infiltration and congestion of intertubular blood capillaries (H & E X 400).

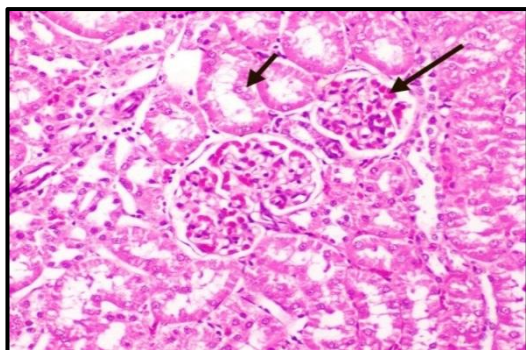


Photo (18): Photomicrograph of kidney of rat from group 3 (ashwagandha roots powder 2.5%) showing slight vacuolar degeneration of epithelial lining some renal tubules and slight congestion of glomerular tufts (H & E X 400)

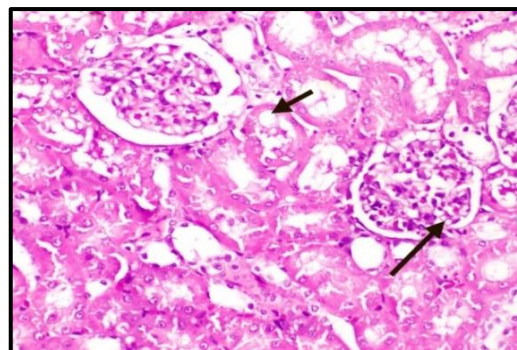


Photo (19): Photomicrograph of kidney of rat from group 4 (ashwagandha roots powder 5%) showing slight vacuolar degeneration of epithelial lining some renal tubules and endothelial lining glomerular tuft (H & E X 400).

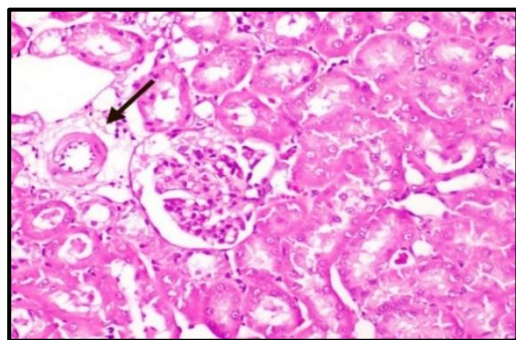


Photo (20): Photomicrograph of kidney of rat from group 4 (ashwagandha roots powder 5%) showing slight perivascular edema (H & E X 400).

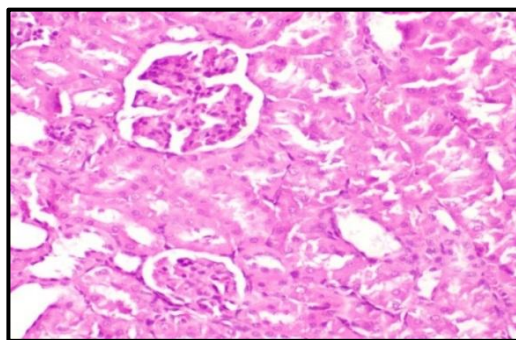


Photo (21): Photomicrograph of kidney of rat from group 4 (ashwagandha roots powder 5%) showing no histopathological changes (H & E X 400).

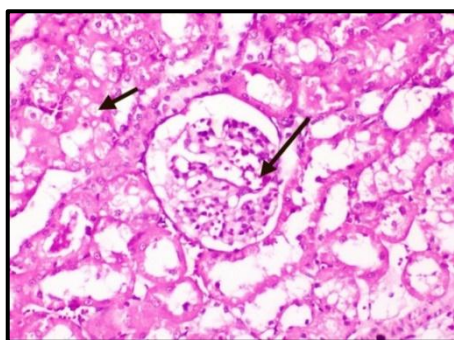


Photo (22): Photomicrograph of kidney of rat from group 5 (ashwagandha roots extract 2.5%) showing vacuolar degeneration of epithelial lining some renal tubules and slight congestion of glomerular tuft (H & E X 400).

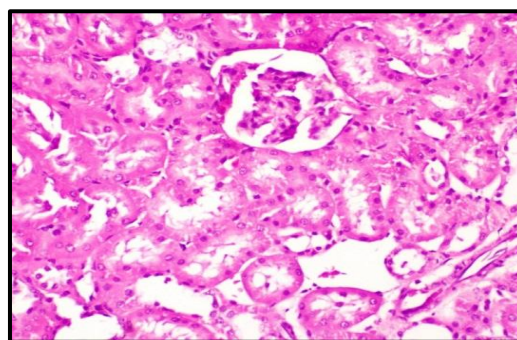


Photo (23): Photomicrograph of kidney of rat from group 5 (ashwagandha roots extract 2.5%) showing no histopathological changes (H & E X 400).

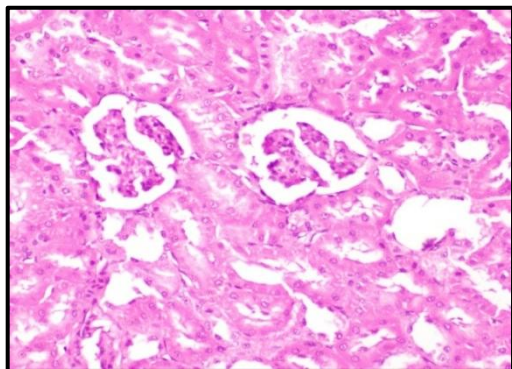


Photo (24): Photomicrograph of kidney of rat from group 5 (ashwagandha roots extract 2.5%) showing no histopathological changes (H & E X 400).

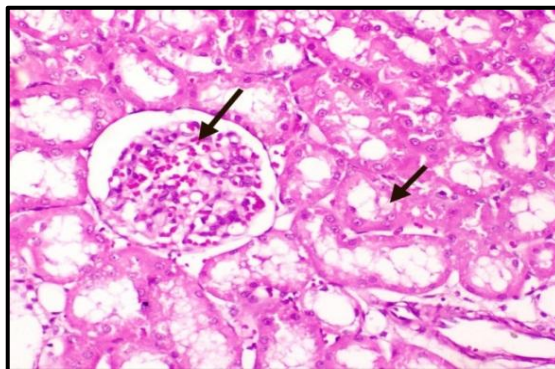


Photo (25): Photomicrograph of kidney of rat from group 6 (ashwagandha roots extract 5%) showing vacuolar degeneration of epithelial lining some renal tubules and slight congestion of glomerular tuft (H & E X 400).

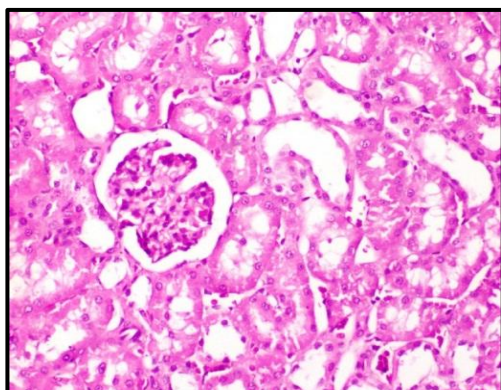


Photo (26): Photomicrograph of kidney of rat from group 5 (ashwagandha roots extract 2.5%) showing no histopathological changes (H & E X 400).

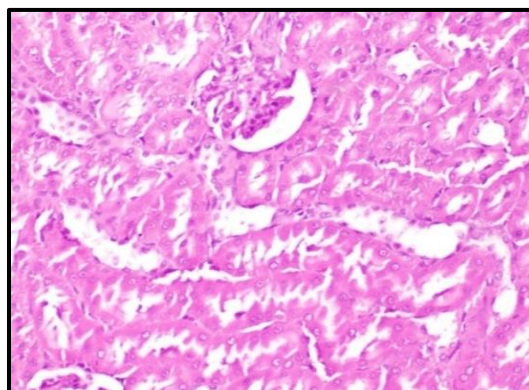


Photo (27): Photomicrograph of kidney of rat from group 6 (ashwagandha roots extract 5%) showing no histopathological changes (H & E X 400).

The histopathological alterations seen in the liver and kidneys by ashwagandha roots in hyperglycemic rats, in this study, were in agreement with the reported biochemical parameters. Moreover, these histopathological alterations in the present study were similar to those demonstrated by **Nayak *et al.*, (2015)** ;**Anwer *et al.*, (2017)** and **Arafa (2021)** who reported that *Withaniasomnifera* would be an effective curative for carbendazim-induced histopathological changes in the liver and kidney.

REFERENCES

- AIN(1993): American institute of Nutrition, purified diet for laboratory rodent: Final report .*J. Nutrition.*; 123:1939-51.
- Ali, H. (2021):** Ashwagandha (*Withaniasomnifera*) and their effects on the reproductive hormones of male rats .*Home Economic. J.*, 37(2):1-20.
- Allain, C.C.; Poon, L.S; Chan, C.S.; Richmond, W. and Fu, P.C. (1974):** Enzymatic

determination of total serum cholesterol. *Clinical Chemistry*, 20(4):470-5.

- Anwer, T.; Sharma, M.; Khan, G.; Alam, M. F.; Alam, N.; Ali, M. S. and Alam, M. S. (2017):** Preventive role of *Withaniasomnifera* on hyperlipidemia and cardiac oxidative stress in streptozotocin induced type 2 diabetic rats. *Tarique Tropical Journal of Pharmaceutical Research*, 16 (1): 119-125.
- Anwer, T.; Sharma, M.; Pillai, K. K. and Iqbal, M. (2008):** Effect of *Withaniasomnifera* on insulin sensitivity in non- insulin- dependent diabetes mellitus rats. *Basic & Clinical Pharmacology & Toxicology*, 102(6): 498-503.
- Arafa, R. (2021):** The effect of different levels from ashwagandha roots powder (*Withaniasomnifera*) on rats suffering from diabetes. *Journal of research in the fields of specific education*, 35(7): 1239-1272.

- Bancroft, J.; Stevens, A. and Turner, D. (1996):** Theory and Practice of Histological Techniques 4th Ed Churchill Living Stone, New York Edinburgh. Madrid, Sanfrancisco, 20.
- Chapman, D.G.; Castilla, R. and Champbell J.A. (1959):** Evaluation of protein in foods. I. A method for the determination of protein efficiency ratios. *Can. J.Biochemistry Physiology*, 37(5):679-686.
- Desai, A. and Bhide, M. (1985):** Hypoglycemic effect of *Hanitoniasuavecolens*. *Indian. J. Medicine*, 81:86-91.
- Doumas, B.T.; Perry, B.W.; Sasse, E.A. and Straumfjord, J.V. (1973):** Standardization in bilirubin assays: evaluation of selected methods and stability of bilirubin solutions. *Clinical Chemistry*, 19(9):984-993.
- Fossatti, P.; Prencipe, L. (1980):** Enzymatic colorimetric test of uric acid. *J. Clinical Chemistry*, 26(2):227-273.
- Fossatti, P. and, Prencipe L. (1982):** Serum triglycerides determined colorimetrically with an enzyme that produces hydrogen peroxide. *Clinical Chemistry*, 28(10): 2077-2080.
- Galicia-Garcia, U.; Benito-Vicente, A.; Jebari. S.; Larrea-Sebal, A.; Siddiqi, H.; Uribe, K. B.; Ostolaza, H. and Martín, C. (2020):** Pathophysiology of type 2 diabetes mellitus. *International journal of molecular sciences*, 21(17):62-75.
- Gorelick, J.; Rosenberg, R.; Smotrich, A.; Hanuš, L. and Bernstein, N. (2015):** Hypoglycemic activity of withanolides and elicited *Withaniasomnifera*. *Phytochemistry*, 116: 283-289.
- Grunz-Borgmann, E.; Mossine, V.; Fritsche, K. and Parrish, A. R. (2015):** Ashwagandha attenuates TNF- α - and LPS-induced NF- κ B activation and CCL₂ and CCL₅ gene expression in NRK-52E cells. *BMC (Complementary and Alternative Medicine)*, 15:1-8.
- Hegazi, R.; El-Gamal, M.; Abdel-Hady, N. & Hamdy, O. (2015):** Epidemiology of and Risk Factors for Type 2 Diabetes in Egypt. *Ann Glob Health*, 81(6):814-20.
- Hoyer, S. (2004):** Glucose metabolism and insulin receptor signal transduction in Alzheimer disease. *European journal of pharmacology*, 490(1-3):115-25.
- Jamuna, G.; Sharma, A. K.; Manimaran, A. and Sankar, P. (2018):** Hepatoprotective effects of *Allium sativum* and *Withaniasomnifera* on ochratoxin A-induced toxicity in rats. *Journal of Pharmacognosy and Phytochemistry*, 7(3): 2675-2680.
- Jha, S. K. and Paul, D. K. (2020):** Efficacy of *Withaniasomnifera* on lipid profile of endosulfan induced toxicity in swiss albino mice. *Journal of Applied and Natural Science*, 12(3): 454 – 459.
- Kaplan, R. (1984).** Impact of urban nature: A theoretical analysis. *Urbanecology*, 8(3): 189-197.
- Kuchewar, V.V.; Borkar, M.A. Nis and Argandha, M.A. (2014):** Evaluation of antioxidant potential of Rasayana drugs in healthy human volunteers. *An international Quarterly journal of research in Ayurveda*, 35(1): 46-49.
- Kulkarni, S.K. and Dhir, A. (2008):** *Withaniasomnifera*: An Indian ginseng. *Progress in Neuropsychopharmacology and Biological Psychiatry*, 32(5): 1093–1105.
- Lee, R.; Nieman, D. (1996):** National Assessment. 2nd Ed., Mosby, Missouri, USA.
- Lopez MF. (1977):** HDL-cholesterol colorimetric method. *J. of Clinical Chemistry*, 23(5): 882-884.
- Malhotra, KV.(2003):** Practical Biochemistry for Students. Practical Biochemistry for Students. Fourth Edition, *Jaypee Brothers Medical Publishers (p) LTD*, New Delhi;10.
- Nayak, S.; Panda, B.K. and Das, S. (2015):** A clinical study on management of stress in type-2 diabetes mellitus (Madhumeha) with ashwagandha (*WithaniaSomnifera*). *Ayushdhara*, 2(6): 413-417.
- Noshahr, Z. S.; Shahraki, M. R.; Ahmadvand, H.; Nourabadi, D. and Nakhaei, A. (2015):** Protective effects of *Withaniasomnifera* root on inflammatory markers and insulin resistance in fructose-fed rats. *Reports of Biochemistry & Molecular Biology*, 3(2): 62.
- Ojha, S. K. and Arya, D. S. (2015):** *Withaniasomnifera* Dunal (ashwagandha): A promising remedy for cardiovascular diseases. *World Journal of Medical Sciences*, 4(2): 156-158.
- Patton, C. J. and Croush, S.R. (1977):** Enzymatic determination of urea. *Analytical chemistry*, 49(3): 464-469.
- Rawlings, A. M.; Sharrett, A.R.; Albert, M. S.; Coresh, J.; Windham, B.G.; Power, M. C.; Knopman, D. S.; Walker, K.; Burgard, S.; Mosley, T. H.; Gottesman, R. F. and Selvin, E. (2019):** The association of Late-life diabetes status and hyperglycemia with incident mild cognitive impairment and dementia: The ARIC Study. *Diabetes Care*, 42(7):1248-1254.
- Rasheed, A.; Younus, N.; Waseem, N. and Badshah, M. (2020):** Protective effect of *Withaniasomnifera* root extract against cisplatin induced nephrotoxicity through renal function analysis in albino wistar rats. *In. Med. Forum*, 31(4):61.

- Sabiba, E. P.; Rasool, M.; Vedi, M.; Navaneethan, D.; Ravichander, M.; Parthasarathy, P. and Thella, S. R. (2013):** Hepatoprotective and antioxidant potential of *Withaniasomnifera* against paracetamol-induced liver damage in rats. *International Journal of Pharmacy and Pharmaceutical Sciences*,5(2): 648-651.
- Salama, M.; Biggs, B. K.; Creo, A.; Prissel, R.; Al Nofal, A. & Kumar, S. (2023):** Adolescents with type 2 diabetes: Overcoming barriers to effective weight management. *Diabetes, Metabolic Syndrome and Obesity*,16:693-711.
- S A S. (1985):** *User's Guide Statistics*, Cary, NC: S A S Institute.
- Shibu, N.J and Charan, S.M (2018):** Health benefits and medicinal potency of *Withaniasomnifera*: A review.*International Journal of Pharmaceutical Sciences Review and Research*, 48(1):22-29.
- Singh, N.; Bhalla, M.; de Jager, P. and Gilca M. (2011):** An overview on ashwagandha: A Rasayana (rejuvenator) of Ayurveda. *Africa Journal Traditional Complement Alternative Medicene*, 8(5):208-13.
- Sultana, N.; Shimmi, S. C.; Parash, MT. H. and Akhtar, J. (2012):** Effects of ashwagandha (*Withaniasomnifera*) root extract on some serum liver marker inzymes (AST, ALT) in gentamicin intoxicated rats. *Journal of Bangladesh Society of Physiologist*,7(1): 1-7.
- Swamy, M. K.; Patra, J. K. and Rudramurthy, G. R. (2019):** Medicinal Plants: Chemistry, Pharmacology and Therapeutic Applications. *CRC Press*.
- Tekula, S.; Khurana, A.; Anchi, P. and Godugu, C. (2018):** Withaferin-A attenuates multiple low doses of Streptozotocin (MLD-STZ) induced type 1 diabetes. *Biomedicine & Pharmacotherapy*, 106(6): 1428-1440.
- Tietz, NW.; Rinker, AD and Shaw LM. (1983):** IFCC methods for the measurement of catalytic concentration of enzymes Part 5. IFCC method for alkaline phosphatase (orthophosphoric-monoester phosphohydrolase, alkaline optimum, EC 3.1.3.1). *Clinicachimica acta; international journal of clinical chemistry* 21(11):731-48.
- Udayakumar, R.; Kasthuriengan, S.; Mariashibu, T.S., Rajesh, M.; Anbazhagan, V.R.; Kim, S.C. and Choi, C.W. (2009):**Hypoglycaemic and hypolipidaemic effects of *Withaniasomnifera* root and leaf extracts on alloxan-induced diabetic rats. *International Journal of Molecular Sciences*, 10(5): 2367-2382.
- Umadevi, M.; Rajeswari, R.; Rahale, C.S.; Selvavenkadesh, S.; Pushpa, R.; Kumar, K.S. and Bhowmik, D. (2012):** Traditional and medicinal uses of *Withaniasomnifera*. *The Pharma Innovation*, 1(9): 102-110.
- Yound, DS.(1975):** Determination of GOT. *Clinical Chemistry*, 22(5): 1-21.