



## Transforaminal Lumbar Interbody Fusion: Review Article

**Mohamed Reda Abdelaziz, Mahmoud Mostafa Taha, Ahmed Gamal Mohamed ElToukhy and Mohammad Ezzat ElSayed.**

*Neurosurgery Department, Faculty of Medicine- Zagazig University, Egypt*

**Corresponding Author: Ahmed Gamal Mohamed ElToukhy**  
**a.eltoukhy22@medicine.zu.edu.eg**

---

**Article History:** Received: 26.05.2023

Revised: 28.06.2023

Accepted: 23.07.2023

---

### **Abstract:**

The unilateral transforaminal approach for lumbar interbody fusion as an alternative to the anterior (ALIF) and traditional posterior lumbar interbody fusion (PLIF) combined with pedicle screw instrumentation is gaining in popularity.

**Keywords:** TLIF, PLIF, PEEK.

---

**DOI: 10.48047/ecb/2023.12.10.977**

### **Introduction:**

Posterior lumbar interbody fusion (PLIF) after lumbar disk removal was first reported by Jaslow in 1946.

Perhaps the greatest concern with a standard PLIF is the amount of neural retraction needed. An improper amount could potentially lead to nerve root injury, cauda equine injury, dural laceration, and epidural fibrosis. Consequently, the transforaminal posterior lumbar interbody fusion (TLIF) was developed to address some of these problems. The purpose of this approach was to obtain the same goals as a PLIF without the potential risks and complications(1).

TLIF is a modification of the PLIF technique involving unilateral total facetectomy. The pars interarticularis is resected, and the inferior facet is removed. The superior facet is then resected until it is

flush with the pedicle. The traversing nerve root is mobilized and retracted medially, but to a much lesser degree than with PLIF. Access to the disk can then be obtained transforaminally. Using special curets and shavers, discectomy is performed across to the opposite side. Disk height is reestablished using special distractors or pedicle screws. One or two interbody grafts are placed. When using a single interbody device (**Figure 1**), emphasis is placed on crossing the midline. The addition of bilateral pedicle screw instrumentation is recommended to restore spinal stability (2).

**Ames et al** found that the position of the interbody graft in either an anterior or middle column position during TLIF had no effect on stability. While after 2-level instrumentation, TLIF with anterior graft placement had a higher stabilizing effect on flexion-extension movement across the

operated level than did PLIF (**Figure 2**). (**3**)

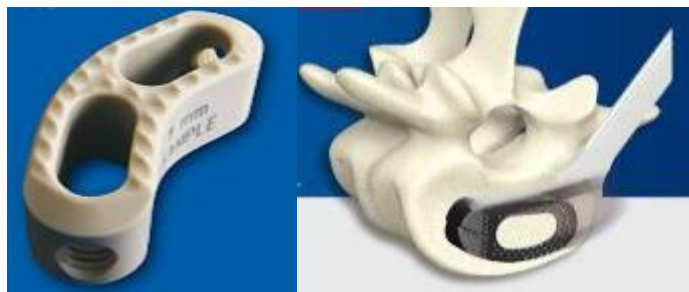In a comparison of posterior and transforaminal approaches to lumbar interbody fusion, (**4**) listed various potential advantages and disadvantages of TLIF technique as shown in (**Table 1**). Also he found that with the TLIF technique, the path to the disc runs laterally to the vertebral foramen, reducing the risk of neural damage from retraction and because the cauda equina obstructs the approach to the disc when PLIF is performed, the spine surgeon must perform the discectomy and graft insertion in a bilateral fashion, increasing the operative time. In contrast, the angle of approach normally obtained during TLIF allows a unilateral approach to the disc space, thus reducing operative time and blood loss (**5**).

The TLIF technique allows clearance of the entire intervertebral disk compartment by opening the neural foramen on one side. After appropriate clearance, it is possible to achieve further enlargement of the cleared intervertebral compartment by posterior transpedicular distraction. This enables definitive anterior column support and certain fusion by transforaminally introduced bone material and support

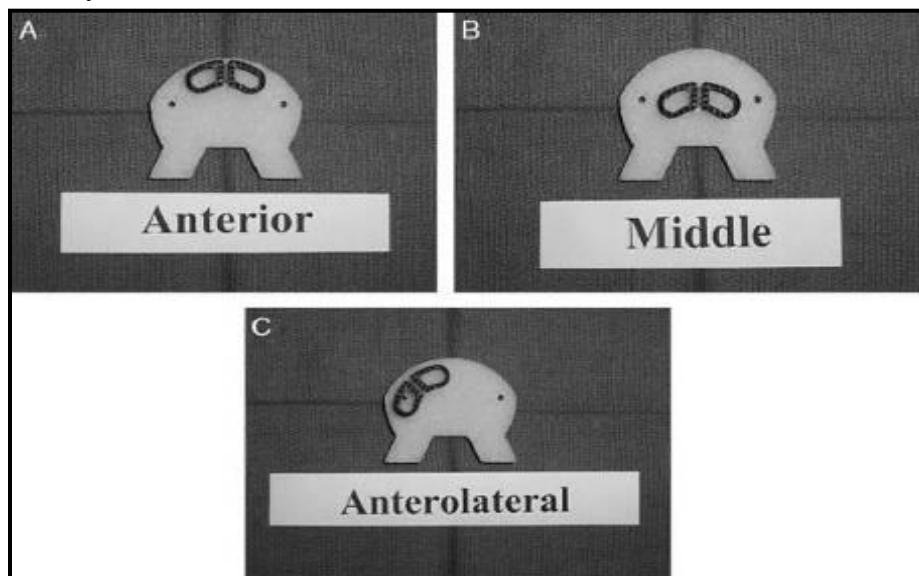
structures. After the introduction of these anterior fusional elements, segment stability is restored by converting the distraction force into compression force. The TLIF approach helps to avoid damage to important anatomic structures such as the nerve roots, dura, ligamentum flavum, and interspinous ligament. Preservation of the ligamentous structures is of great importance to restoring biomechanical stability of the segment and its adjacent counterparts (**1**).

The advantages over the standard PLIF include the ability to provide bilateral anterior column support through a single posterolateral approach of the disk space. The transforaminal approach preserves the anterior and most of the posterior longitudinal ligamentous complex, which provides a tension band for compression of the graft and prevents retropulsion of the graft. It avoids excessive soft tissue dissection, which may help prevent scarring and instability of adjacent segments, as well as injury to the exiting nerve root. Epidural bleeding is less of a problem than with the standard bilateral PLIF because of the unilateral transforaminal approach, and, with experience, proper cage placement within the disk space is consistently achieved (**1**).





**Figure (1):** Different TLIF interbody devices designed to cross the midline after application of them unilaterally (6).



**Figure (2):** Different positions of the cage in TLIF. (3)

**Table (1):** Potential Advantages and Disadvantages of the TLIF Procedure (4)

Advantage	Disadvantage
Interbody fusion without anterior approach	Limited epidural and perineural scarring
Unilateral, incomplete resection of facet	High costs
Protection of dura and nerve roots	Technically demanding procedure
Decreased risk of decompensation of neighboring motion segments	
Reestablishment of normal alignment	
Early mobilization	
Short hospital stay and early return to work	
Prevention of retrograde ejaculation	

**Lumbar Interbody Cages:**

The primary goal of lumbar surgery in the degenerative setting is the relief of the

patient’s pain with improvement in overall functional status. It has long been thought

that this would be best achieved by correction of existing mechanical deformation to its anatomic baseline and by minimizing abnormal pain-producing motions. In theory lumbar interbody fusion has been the preferred surgical technique to achieve these goals (3).

As a result, interbody cages have been developed with the aim of overcoming these problems. They strive to:

1. Correct the existing mechanical deformation.
2. Provide stability to the segment until arthrodesis is obtained.
3. Provide the best possible environment for successful arthrodesis.
4. Achieve fusion with limited morbidity associated with their use.
5. Serve as a delivery mechanism for osteogenic, osteoinductive, and/or osteoconductive material (3).

A biomechanical study on human cadaver spines was performed to determine the effect of three different cage designs (Figure 3), with and without instrumentation, on the three-dimensional flexibility of the spine. No significant difference in the stabilizing potential of the three cage designs was found. The cages used alone significantly decreased the intervertebral movement in flexion and lateral bending, but no stabilization was achieved in extension or axial rotation. For all types of cages, the greatest stabilization in flexion and extension and lateral bending was achieved by the addition of instrumentation (6).

Cages made of steel or titanium alloys show good fusion rates. Unfortunately


three disadvantages emerged with the use of the metal cages. Subsidence of the cage in the adjacent vertebrae has been described and difficulties in assessing fusion in radiological imaging. Another shortcoming of metal cages is the stiffness of the material. The stiffness reduces the amount of mechanical stimulation to the bone grafts which might delay fusion or shielding of the bone graft(3).

To overcome these problems, polyetheretherketone (PEEK) cages have been introduced (Figure 4). Proposed advantages over the conventional materials are a better load transfer, which should result in a lower subsidence rate and increased fusion. Radiolucency of the cage should result in a more reliable evaluation of fusion on CT-images. Although some cancellous autologous bone certainly has to be placed in the intervertebral space for efficiently inducing fusion, the complete filling of the intervertebral space (within and around the cage) seems unnecessary. It is possible that mechanical properties of PEEK help reducing the needs in cancellous bone autograft. Yet, the minimal amount of intervertebral bone graft still has to be defined. But on the other side, it was found that the absence of posterior fixation in combination with the lower stiffness of PEEK and the lack of sharp teeth on the cage probably lead to insufficient initial stability, creating suboptimal conditions for bony bridging, and thus solid fusion (7).

This was concluded by Rousseau et al. whom conducted a study to investigate a series of patients with circumferential fixation using anterior PEEK cages for

degenerative lumbar spine disorders with a specific interest in the local lordosis. They concluded that lumbar circumferential arthrodesis using PEEK cages (posterior/anterior procedure) provided good clinical results and fusion rate, for various amount of cancellous bone autograft. They also stated that after the initial increase in local lordosis, they observed a radiologic trend to join the preoperative angle, specifically at lower levels. The effect of the rigidity of the posterior instrumentation on the lordosis correction may depend on the order of the posterior and anterior combined procedure (8).

Carbon Fiber Reinforced Polymer (CFRP) was introduced in the 1990s. CFRP products have a unique 70/30 (PEEK to Carbon Fiber) matrix and manufacturing process. 2mm Chopped Carbon Fiber is embedded into PEEK. CFRP has a modulus of elasticity that approximates cortical bone. Implants made of CFRP allows for compressive forces from the vertebral bodies to be transferred to the bone packed within and surrounding the implant. Other



**Figure (3):** Three different cage designs.

materials such as titanium have a high modulus of elasticity and can be stress shielding. This causes the implant to carry the stress loads from the vertebral bodies (9).

Several recent studies have attempted to address the in-vitro biomechanical properties of different types of lumbar interbody cages with respect to cage design and positioning in the disc space. In general, the conclusions have been fairly consistent, in that there are no significant differences in construct stiffness and failure loads between a unilaterally inserted cage versus bilaterally inserted cages, and that positioning of the cage(s) whether it be in the posterolateral versus central quadrants of the vertebral body, do not significantly affect construct stiffness and hence subsidence. In a study compares 3 different carbon fiber cage designs Lam et al had found the same conclusion: cage shape and positioning does not significantly affect the in-vitro biomechanical properties of the interbody cage across the vertebral endplates(10).



**Figure (4):** Different PEEK cages.

### Indications and Contraindications:

#### Indications:

- Best indication is a grade I or grade II spondylolisthesis without neurologic

deficit or with a deficit on one side only.

- Degenerative disease with positive diskography without any intracanal pathologic condition.

- Anterior column deficiency with chronic mechanical pain related to degenerative disk disease, recurrent disk herniation, and/or spondylolisthesis.
- Segmental kyphosis related to disk narrowing.
- Grade II or III spondylolisthesis can also be reduced with this technique without the need for anterior surgery.
- Patients with multiple comorbidities potentially affecting successful arthrodesis (obesity, smoking, diabetes, previous failed fusion) are also candidates for the TLIF because it provides a circumferential fusion through a posterior-only approach.
- The TLIF procedure can also be used to decrease pseudoarthrosis at the lumbosacral junction. (11).

**Contraindication:**

- Tight anterior disk space with osteophyte formation in which there is no potential for disk space distraction.

**Relative Contraindications:**

- If there is extensive epidural scarring or history of prior infection, a TLIF may be performed; however, in this case, it is often more prudent to perform a direct anterior lumbar interbody fusion.
- Severe osteopenia (bone mineral density <60% predicted).
- Bilateral epidural fibrosis with pseudoarthrosis.
- Fusion of more than two levels. (12).

**Operative Technique:**

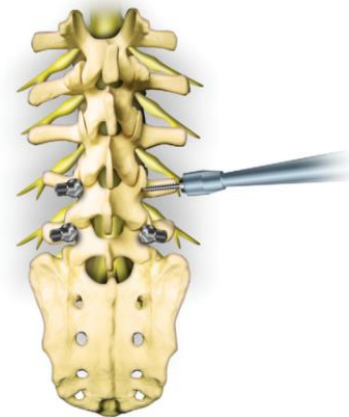
✓ **Equipment**

- X-ray-compatible operating table
- Jackson table, Wilson frame, or chest rolls
- Headlight system
- Pneumatic compression stocking or antiembolic stocking to both legs
- Lumbar laminectomy set

- Bone graft source
- Lumbar pedicle screw system (12).

✓ **Patient Positioning And Pedicle Screw Placement**

- After endotracheal anesthesia, the patient is placed in a prone position with avoidance of epidural venous distention from abdominal compression.
- Posterior spinal elements are exposed through a midline longitudinal incision.
- A subperiosteal dissection of the paraspinal muscles is completed to the transverse processes.
- Pedicle screws are sized and inserted under C-arm x-ray guidance before decompression to minimize blood loss and achieve distraction (Figure 5). (12).

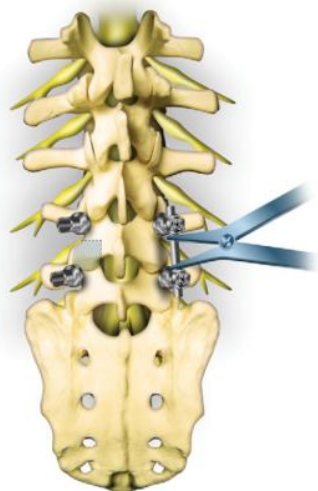


**Figure (5):** After the subperiosteal dissection, pedicle screws are sized and inserted before decompression (12).

✓ **Unilateral facetectomy and contralateral distraction**

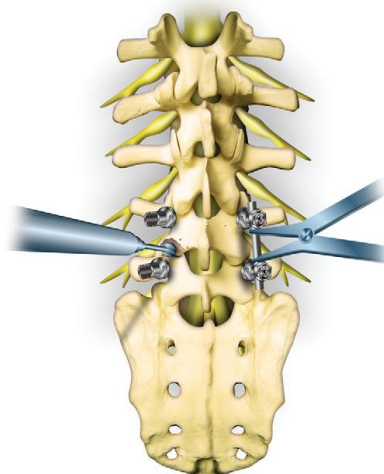
- If radiculopathy is present, the spinal canal is entered through a unilateral laminectomy and inferior facetectomy on the side of the radicular pain. If no radiculopathy is present, the side is chosen arbitrarily.

- Apply the rod system at the contralateral side and distract the disk space. The interspinous ligament as well as the ligamentum flavum on the opposite side is left intact. The degree of bone resection necessary for this unilateral TLIF technique is indicated in **(Figure 6)(12)**.



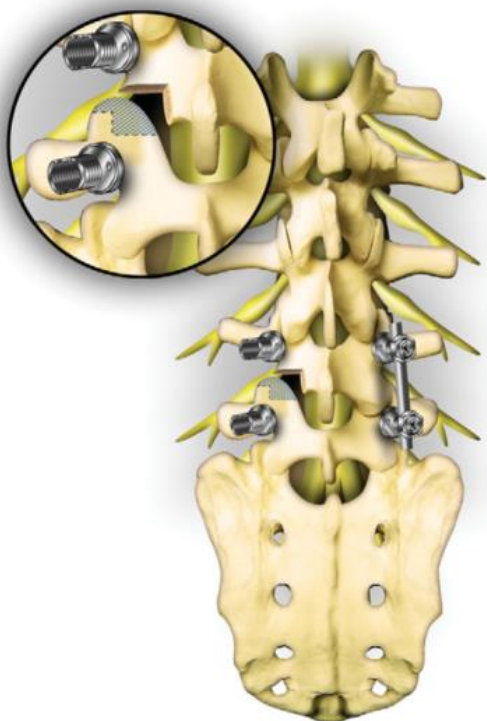
**Figure (6):** Apply the rod system at the nonradiculopathy side and distract the disk space. A facetectomy will be done at the radiculopathy side (12).

- The next step is to gain access to the disk at L4-L5 via the transforaminal approach. The inferior articular process of the cranial vertebra is now thinned out with the use of a burr, while distraction forces are applied to the contralateral side **(Figure 7)**.



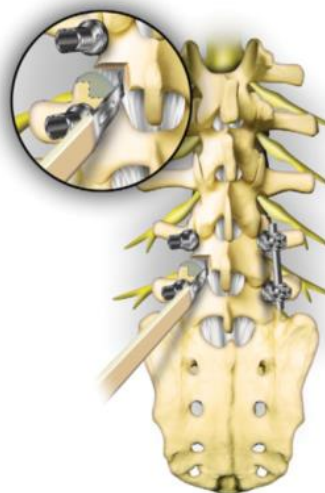
**Figure (7):** The inferior articular process of the cranial vertebra is thinned out with the use of a burr, while distraction forces are applied to the contralateral side (12).

- Once thinned, resect the inferior articular process of the cranial vertebral body with a chisel or bone cutter, uncovering the next stage in the approach to the neural foramen. The degree of bone to be resected from the superior facet of the inferior vertebra is indicated in **(Figure 8)**.



**Figure (8):** After thinning by using a drill, resect the inferior articular process of the cranial vertebral body with a chisel or bone cutter, thereby uncovering the neural foramen. The degree of bone to be resected from the superior facet of the inferior vertebra is indicated (12).

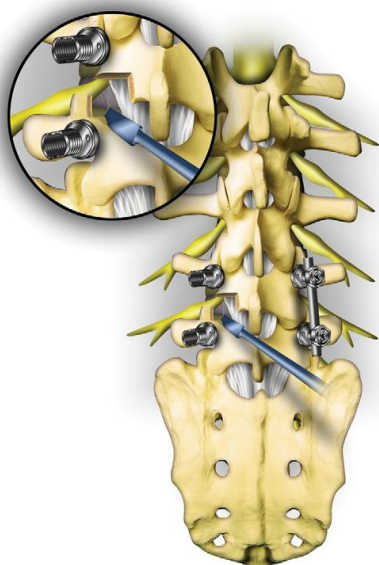
- The capsular part of the ligamentum flavum is now visible and can be resected. To avoid damage to the nervous structures, it is necessary to cut around the superior articular facet of the caudal vertebral body. Care must be taken to ensure the lateral delimitation of the ligamentum flavum is largely preserved.
- Only in exceptional cases is resection of the lateral part of the ligamentum flavum necessary. Tactile exploration of the neural foramen is recommended with palpatory identification of the cranial nerve root and the position and breadth of the pedicle of the caudal vertebral body (Figure 9). (12).



**Figure (9):** The ligamentum flavum removal. Care must be taken to ensure that the lateral delimitation of the ligamentum flavum is largely preserved. The exiting nerve root is identified and protected from surgical trauma. Tactile exploration of the neural foramen is recommended with palpatory identification of the upper nerve root and the position and breadth of the pedicle of the caudal vertebral body (12)

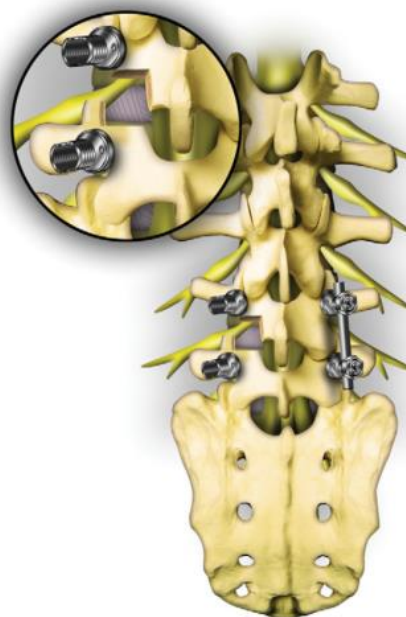- Resect the superior facet of the inferior vertebra as the final step in gaining access to the disk at L4-L5, the posterolateral parts of the annulus fibrosus, and the longitudinal ligament (Figure 10).





**Figure (10):** Resect the superior facet of the inferior vertebra as the final step in gaining access to the disk at L4- L5, the posterolateral parts of the annulus fibrosus, and the longitudinal ligament (12).

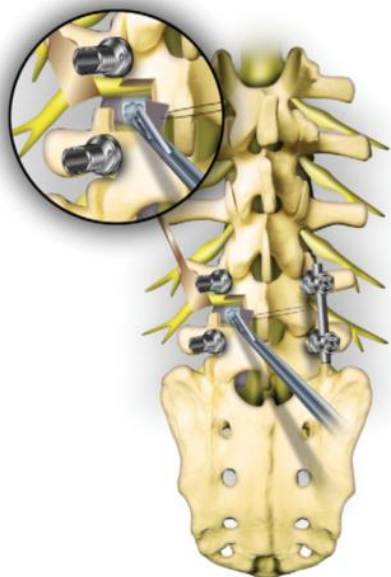
- The entire neural foramen is identified after resection of the upper medial parts of the superior articular facet of the lower vertebral body. The upper nerve root that passes around the pedicle of the upper vertebral body and the lateral part of the intervertebral disk can be identified. The nerve root can be identified merely by palpation in its course within the foramen, especially where it crosses over the lateral parts of the intervertebral space. The origin of the next nerve root in the caudal direction and the dural sac in the medial border can also be identified. After identification of these nervous structures, meticulous coagulation of the epidural veins in the neural foramen is carried out (**Figure 11**) (12).



**Figure (11):** After resection of the upper medial parts of the superior articular facet, the neural foramen is opened. The upper nerve root and the lateral part of the intervertebral disk can now be identified (12).

#### ✓ Total Discectomy Through Unilateral Approach

- The thecal sac is gently retracted medially, if necessary.
- A discectomy is performed through this unilateral approach (**Figure 12**).
- Partially clear the intervertebral disk compartment by using various rongeurs. Curettes can be used to remove the intervertebral disk remnants adhering to the upper plates. With the curettes, the cartilaginous coats of the end plates can be removed at the same time without destroying the osseous structure of the end plates (12).

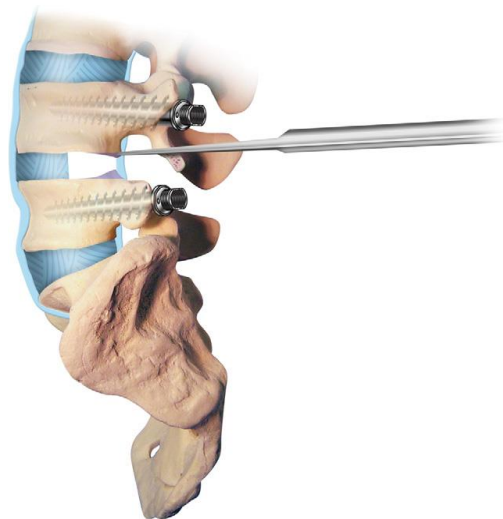


**Figure (12):** The thecal sac is gently retracted medially, if necessary. The discectomy is performed through this unilateral approach (12).

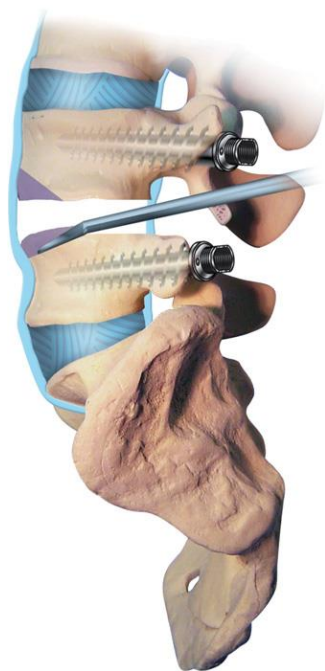
✓ **End Plate Preparation:**

- After the initial discectomy, gradual distraction is applied to the pedicle screws on the opposite side.
- An osteotome is used to remove the posterior lateral lip of concave bone to achieve a flat end plate surface. This is important, because the upper plates of the lumbar vertebral bodies always have a pronounced concave shape.
- By a marginal resection of the dorsal edges of the end plates, a parallel plane between the adjacent vertebral bodies can be established. This is for the introduction of the structural graft. The dorsal lips of the vertebral body should be resected to form a uniform aperture (**Figure 13**).
- Carefully curette the remaining cartilaginous parts of the end plates. A chisel is not indicated, because it will destroy the cortical structure of the end plates.

- It is necessary to remove the anterior one third or one quarter of the opposing end plates to enable definitive osseous fusion. By this resection with angular chisels, the cancellous bone structure of the vertebral body is exposed, guaranteeing rapid osteointegration. Only the anterior one third or one quarter is resected. The remaining part of the osseous end plate must be carefully preserved to accommodate the supporting structural graft, which will be inserted later. In the process of chiseling, the anterior longitudinal ligament must not be damaged, as this can result in vascular injury. A surgeon who is inexperienced in this procedure should initially use an image intensifier or fluoroscopy when completing this step (**Figure 14**). (13).



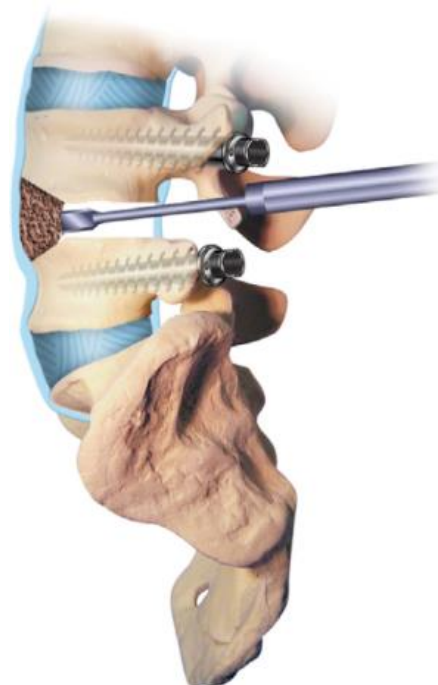
**Figure (13):** Clear the intervertebral disk compartment by using various rongeurs and curettes. An osteotome is used to remove the posterior lateral lip of concave bone to achieve a flat end plate surface. The dorsal lips of the vertebral body should be resected to form a uniform aperture (13).



**Figure (14):** Remove the anterior one third or one quarter of the end plates to enable osseous fusion. The remaining part of the osseous end plate must be carefully preserved to accommodate the supporting structural graft. The anterior longitudinal ligament must be preserved to prevent the vascular injury (13).

#### ✓ Cancellous Bone And Strut Bone (Or Cage) Graft

- The previously harvested cancellous bone is introduced into the retracted intervertebral disk compartment and brought to the anterior longitudinal ligament. Impact the introduced cancellous bone with straight and angled impactors. This procedure can attain a definite bone layer in the anterior one third of the intervertebral space. Also, this impacted cancellous bone prevents the structural graft from being positioned too far anteriorly (Figure 15). (13).



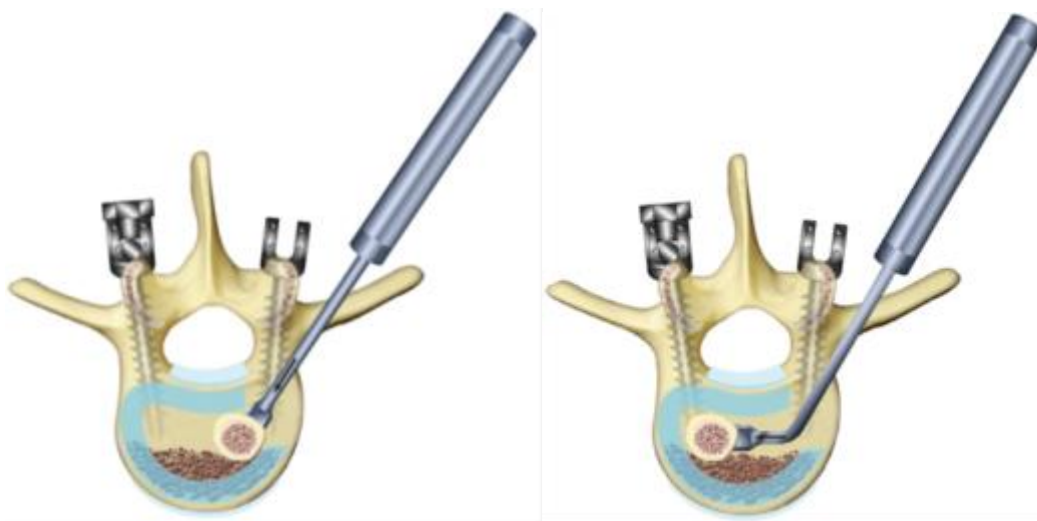**Figure (15):** Cancellous bone is introduced into the intervertebral disk space and brought to the anterior longitudinal ligament. This is necessary to attain a definite bone layer in the anterior one third of the intervertebral space. At the same time, this impacted cancellous bone prevents the structural graft from being positioned too far anteriorly (13).

- Cut the structural graft to the appropriate height and insert it with the use of cage. For biomechanical reasons, the graft should be situated in the middle or posterior half of the intervertebral space. Insert the first graft transforaminally into the disk space and place it primarily close to the posterior wall and slide it anteriorly to the contralateral side.
- Bring the first graft over the midline to the opposite side in a rolling movement. The graft is supported on the ventrally introduced autologous bone chips, which prevents it from becoming positioned too far ventrally (Figure 16).

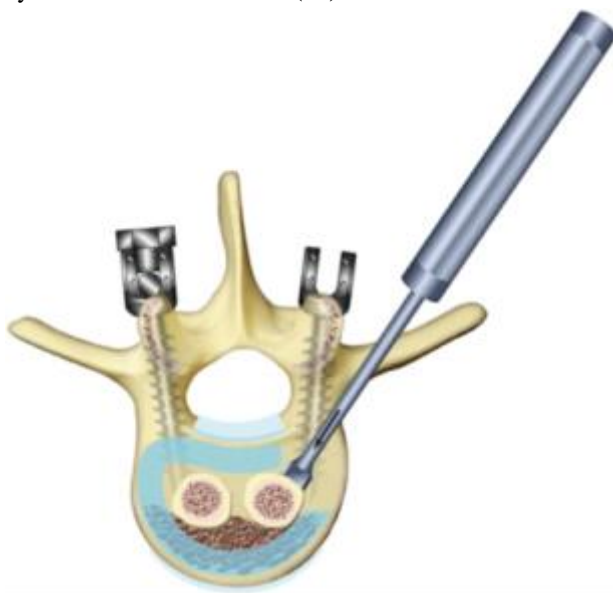- A second graft is seated next to the first one to line them up to the left and to the right of the midline, respectively. In this way, a good broad area of support from the adjacent vertebral bodies is attained (**Figure 17**).
- A cage of the proper height and packed with cancellous bone is

inserted into the disk space (**Figure 18**).

- After insertion of the bilateral strut graft or cages from a unilateral approach, the final position is checked visually and radiologically. Then the disk space distraction is released (**13**).

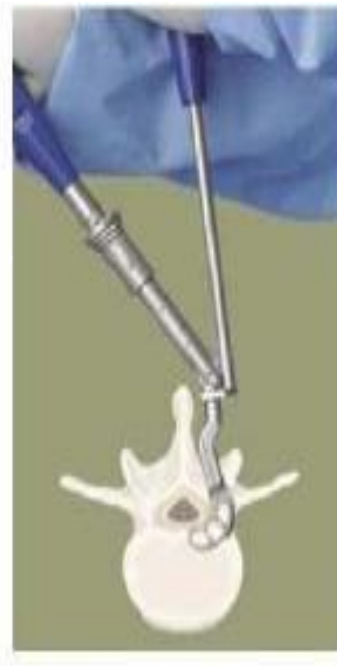


**Figure (16):** Insert the first graft transforaminally into the disk space and place it primarily close to the posterior wall. Then slide it anteriorly to the contralateral side (**13**).



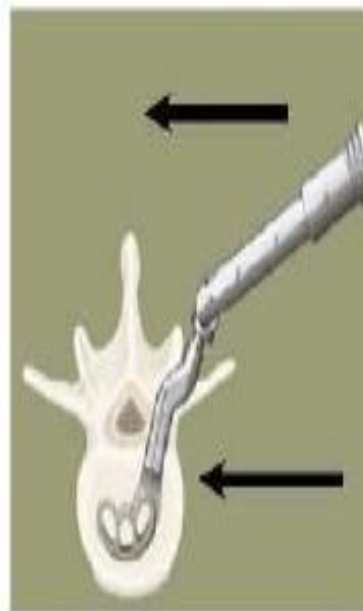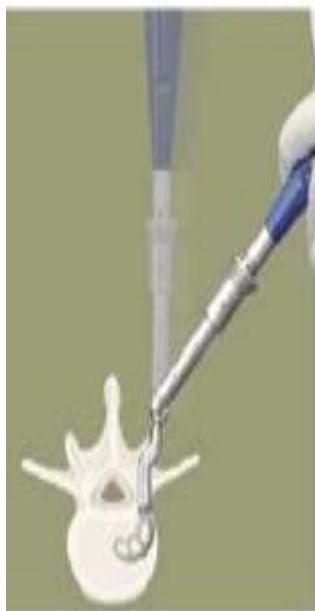**Figure (17):** A second graft is seated next to the first one to line these up to the left and to the right of the midline, respectively. In this way, a good broad area of support from the adjacent vertebral bodies is attained (**13**).

Local autologous have graft and / or bone morphogenetic protein may be placed anterior to or packed with in the interbody device it should be noted that the use of bone morphogenetic protein in this fashion is an off-label indication (14).

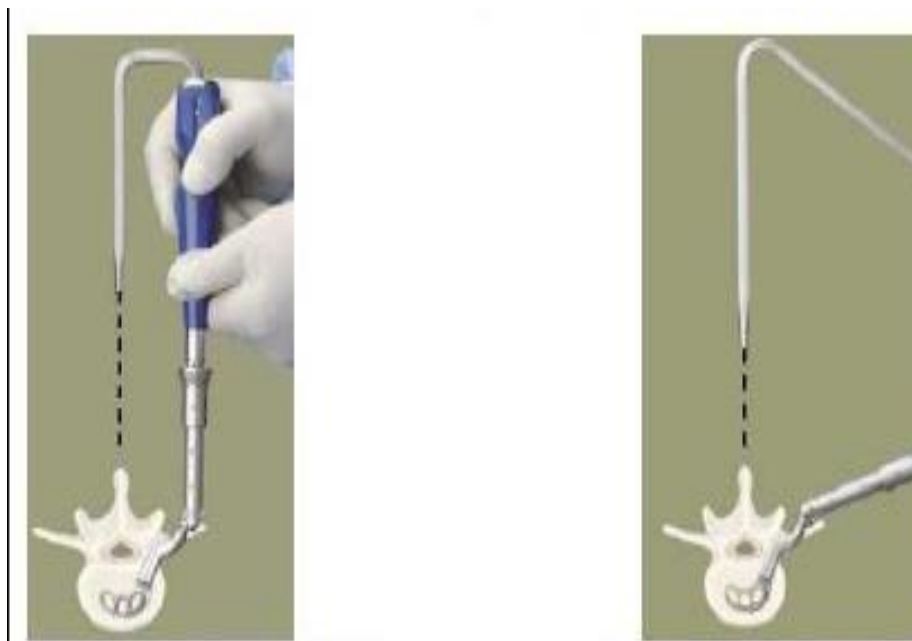


**Step 1: Attach the appropriate sized cage to the inserter by placing the cage into the claw on the inserter and tighten with screwdriver.**

**Step 2: Use the inserter. In combination with pusher. To begin insertion of the cage.**



**Step 3: Rotate the inserter handle to the second position and impact the cage.**

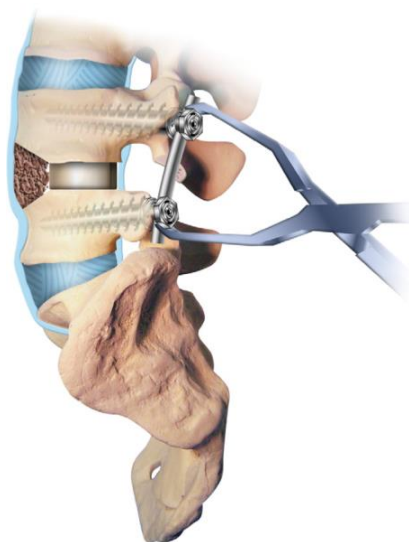


Step 4: Use the alignment rods to verify the final position of the cage.

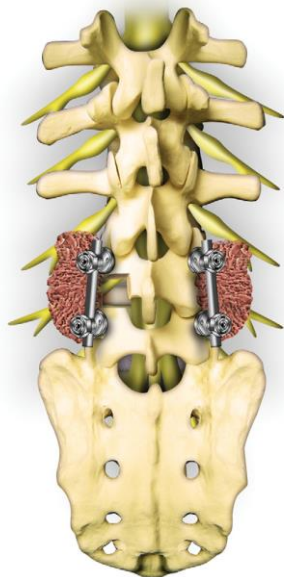
Figure (18): Steps of cage insertion (14)

✓ **Final Assembly Of Rod-Screw System And Closure**

- The construct is compressed to establish an optimal graftbone interface and to reestablish lumbar lordosis at the operated segments (**Figure 19**).
- The rod-screw system is tightened and cross-linked.
- Perform a posterolateral fusion with cancellous iliac bone graft over the transverse processes after adequate decortication on both sides (**Figure 20**).
- Insert drains and carry out the muscle closure, followed by fascia suture, subcutaneous suture, and finally skin closure (**15**).



**Figure (19):** After insertion of the bilateral cages from a unilateral approach, the final position of the structural graft is checked visually and radiologically. Then the disk space distraction is released. The construct is compressed to establish an optimum graft-bone interface and to reestablish lumbar lordosis at the operated segments (**15**).



**Figure (20):** After tightening and cross-linking of the rodscrew system, perform a posterolateral fusion with bone graft over the transverse processes (15).

✓

#### ✓ Postoperative Care

- All wound drains are removed 24 to 48 hours after surgery.
- Patients with a one-level lumbar fusion do not need external orthosis.
- Patients are mobilized postoperatively on day 1.
- Physical therapy for rehabilitation is then provided.
- Patients are usually discharged from the hospital at 2 to 3 days after operation if there are no complications. (16)

#### ✓ Complications

- Pseudoarthrosis
- Excessive hemorrhage
- Dural tear
- Infection (16).

#### References:

1. **Meng B, Bunch J, Burton D & Wang J (2021):** Lumbar interbody fusion: recent advances in surgical techniques and bone healing strategies. *European Spine Journal*, 30, 22-33.

2. **DiPaola CP, Molinari RW (2012):** Posterior Lumbar Interbody Fusion. *J Am Acad Orthop Surg*. 2012;16:130–9.
3. **Ames CP, Acosta FL, Chi J, Iyengar J, Muiru W, Acaroglu E, et al. (2005):** Biomechanical Comparison of Posterior Lumbar Interbody Fusion and Transforaminal Lumbar Interbody Fusion Performed at 1 and 2 Levels. *Spine*. Oct 1;30(19):E562–566.
4. **Humphreys SC, Hodges SD, Patwardhan AG, Eck JC, Murphy RB, Covington LA (2001):** Comparison of Posterior and Transforaminal Approaches to Lumbar Interbody Fusion. *Spine*. Mar 1;26(5):567–71.
5. **Rezk EMA, Elkholy AR & Shamhoot EA (2019):** Transforaminal lumbar interbody fusion (TLIF) versus posterior lumbar interbody fusion (PLIF) in the treatment of single-level lumbar spondylolisthesis. *Egyptian Journal of Neurosurgery*, 34(1), 1-8.
6. **Prpa B, Whitfield MD, Lieberman IH (2005):** Lumbar Interbody Cages. In: Benzel EC, editor. *Spine surgery: techniques, complication avoidance and management*. Second. Elsevier Inc.; p. 489–500.
7. **Lee JH, Lee JH, Park JW, Lee HS (2011):** Fusion Rates of A Morselized Local Bone Graft in Polyetheretherketone Cages in Posterior Lumbar Interbody Fusion by Quantitative Analysis Using Consecutive Three-Dimensional Computed Tomography Scans. *The Spine Journal*. Elsevier Inc; Jul; 11(7):647–53.
8. **Rousseau M-A, Lazennec J-Y, Saillant G (2007):** Circumferential Arthrodesis using PEEK Cages at the

- Lumbar Spine. *Journal of Spinal Disorders & Techniques.*; 20(4):278–81.
9. **Brantigan JW, Neidre A, Toohey JS (2004):** The Lumbar I/F Cage for posterior lumbar interbody fusion with the variable screw placement system: 10-year results of a Food and Drug Administration clinical trial. *The Spine Journal.* 4(6):681–8.
  10. **Lam FC, Alkalay R, Groff MW (2012):** The Effects of Design and Positioning of Carbon Fiber Lumbar Interbody Cages and Their Subsidence in Vertebral Bodies. *Journal of Spinal Disorders & Techniques.* Apr; 25(2):116–22.
  11. **Lowe TG, Tahernia AD (2005):** Unilateral transforaminal posterior lumbar interbody fusion. *Clin Orthop Relat Res*; 394: 64 –72.
  12. **Moskowitz A (2002):** Transforaminal lumbar interbody fusion. *Orthop Clin North Am*; 33:359–366.
  13. **Harms J, Jeszyszky D, Stolze D (1997):** True spondylolisthesis reduction and more segmental fusion in spondylolisthesis. In Bridwell KH, Dewald RL, Hammerberg KW (eds): *The Textbook of Spinal Surgery*, 2nd ed. Philadelphia, Lippincott-Raven, pp 1337– 1347.
  14. **Anderson P, Tribus C, Kitchel S (2006):** Treatment of neurogenic claudication by interspinous decompression: application of the X STOP device in patients with lumbar degenerative spondylolisthesis. *J Neurosurg Spine*; 4:463-47.
  15. **Harms J, Roliger H (1982):** A one-stage procedure in operative treatment of spondylolistheses: Dorsal traction-reposition and anterior fusion. *Z Orthop Grenzgeb*;120:343–347.
  16. **Tan T, Lee H, Huang MS, Rutges J, Marion TE, Mathew J & Tee J (2020):** Prophylactic postoperative measures to minimize surgical site infections in spine surgery: systematic review and evidence summary. *The Spine Journal*, 20(3), 435-447.