



## COMPARISON OF TWO MAXILLARY HYBRID EXPANDERS – PERPENDICULAR SCREW SUPPORTED VERSUS LATERAL ANGULATED ONE: A PROSPECTIVE RANDOMIZED CLINICAL STUDY

Abdallah El Sayed Mohamed Hassan<sup>1\*</sup>, Raafat EL Ghitany  
Mohamed<sup>2</sup>, Mohamed Abdelrhman Shendy<sup>3</sup>

Article History: Received: 15.05.2023

Revised: 25.06.2023

Accepted: 01.07.2023

### Abstract

**Objectives:** purpose of this study was to assess the skeletal, dentoalveolar and dental changes produced by rapid maxillary expansion using the skeletal anchored hybrid hyrax expander with two different designs .

**subjects and methods:** Twenty healthy patients with transverse maxillary deficiency based on the transvers analysis of Andrew's elements were selected. The patients were distributed in to two groups: group1: miniscrews were placed perpendicular while group 2 were placed at lateral angulation. The CBCT images were performed before the start of the orthodontic expansion (T 1) and 3 months after the last activation (T 2): the mean differences between pre-expansion and pos- expansion measurements within each group were measured.

**Results:** pre and post expansion measurements did not differ statistically from one another. Skeletal expansion was observed in the clinical appearance of the midline diastema. Evidence of midpalatal suture opening with the hybrid hyrax expander was evident in the antero-posterior cephalometric radiographs. Hybrid hyrax has a clinical significance throughout increase most of maxillary arch parameters.

**Conclusion:** There was significant difference between the pre and post expansion measurements at the skeletal and dental levels in each group but no statistically significant difference between the two groups .However, the palatal tissue reaction to the perpendicular positioned miniscrews is better than that to the angulated one in which some degree of palatal mucosa over growth was occurred.

**keywords:** Rapid maxillary expansion, hybrid expanders, perpendicular screw, lateral angulated

1 B.D.S (2016) Al-Azhar University, Dentist at Ministry of Health, Egypt.

2 Professor, Department of Orthodontics, Faculty of Dental Medicine, Boys, Cairo, Al-Azhar University.

3 Associate Professor, Department of Orthodontics, Faculty of Dental Medicine, Boys, Cairo, Al-Azhar University.

\* **Corresponding author:** Abdallah El Sayed Mohamed Hassan

### Introduction

Maxillary expansion is a treatment strategy in which the maxilla's transverse dimension is widened utilizing various devices. To make an interincisal diastema, Angell employed a screw in the area of the premolars. When there was a clinical case of transverse insufficiency, he forced the midpalatal suture to expand bilaterally <sup>(1)</sup> orthodontists frequently perform rapid maxillary expansion (RME), as orthopedic procedure. RME is recommended to treat maxillary constriction in individuals who are growing, hence enhancing the transverse interarch relationship. RME modifies nearby craniofacial features, including the midpalatal suture and dentoalveolar area. <sup>(2)</sup>

During the juvenile stage, the midpalatal suture starts to disappear, and as people age, their circummaxillary and midpalatal sutures ossify more and more. It is challenging to use traditional tooth-borne expansion on individuals with transverse maxillary insufficiency due to the

increased degree of suture fusion. Additionally, this clinical issue with the expansion technique may result in unfavorable side effects such expansion failure, alveolar bone dehiscence, buccal crown tilting, root resorption, a decrease in buccal bone thickness, marginal bone loss, discomfort, edema, and gingival recession. <sup>(3-5)</sup>

The adoption of tooth-bone-borne anchored RME appliances was suggested as a solution to these disadvantages. This hybrid hyrax device, which is attached to the first molars at the posterior and the palate at the front using miniscrews, has various benefits, including preventing the need for invasive surgery, being more affordable, and lessening buccal tilting. Additionally, it can be applied to individuals with insufficient anterior dental anchoring (missing baby teeth or premolars with immature roots) <sup>(6)</sup>. The aim of this study was to study the effects of two different designs of hybrid hyrax maxillary expander appliances on skeletal and dental structures using CBCT images.

### Subjects and methods

The study and the patient selection were done in the out-patient clinic of the orthodontic department, faculty of Dental Medicine, Boys, Al-Azhar University, Cairo, Egypt. After the study was approved by the Ethics Committee of faculty of Dental Medicine, Boys, Al-Azhar University, Cairo, Egypt (No. 628/3133).

The current study was conducted on a total sample of twenty young adult orthodontic patients (13 girls and 7 boys) ten in each group presented with maxillary deficiency with an age ranged from 12 to 18 years and mean age of  $13.77 \pm 2.02$  in angulated group, in comparison to  $14.89 \pm 1.41$  in the perpendicular group. The sample was selected, screened, allocated then distributed randomly from patients seeking orthodontic treatment in outpatient clinic, Orthodontic Department, Faculty of Dental Medicine, Al- Azhar University, Cairo (Boys), Egypt.

#### Inclusion criteria:

Male or female patients who are not in need of medical care. Patients who need maxillary expansion because of a narrowed maxillary arch as shown by a unilateral or bilateral posterior crossbite. Except for the third molars, the patient should not be missing any teeth. Ages varied from 12 to 18 years old. The patient should have healthy gingiva. The patient should have healthy periodontal tissue.

#### Exclusion criteria:

History of previous orthodontic treatment. Lack of cooperation. Mental problems. Skeletal open bite.

TMJ problem. neuromuscular disease. Current or past periodontal disease. Smoking.

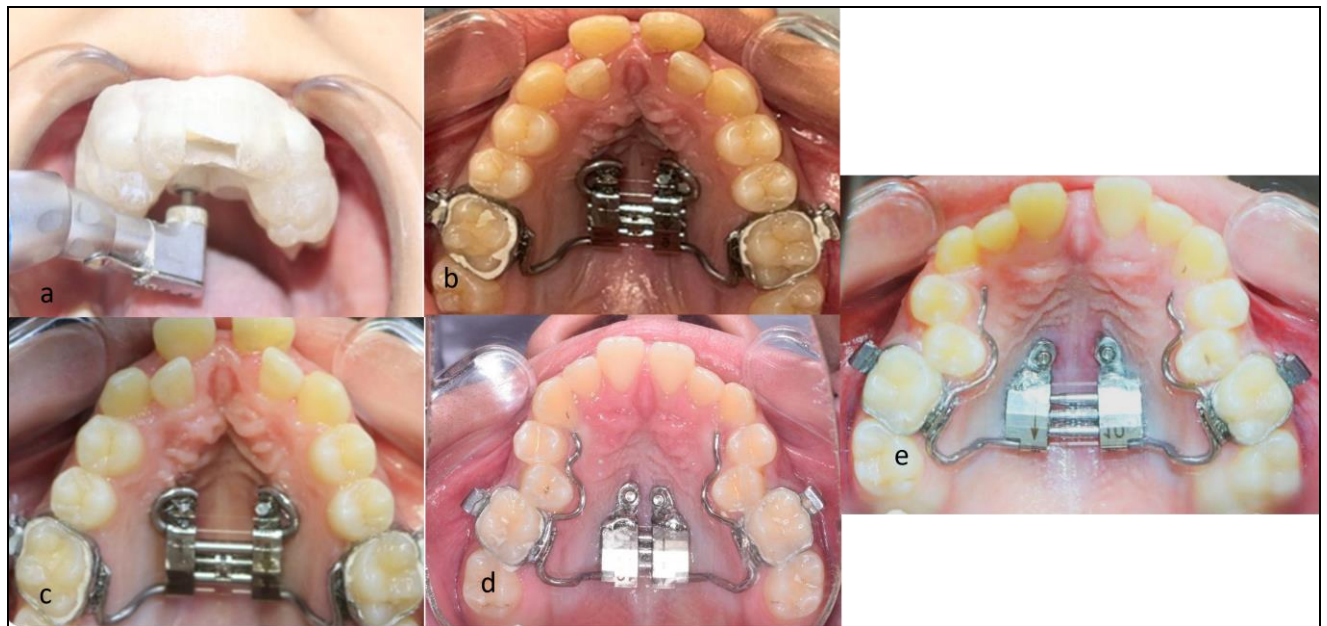
#### Interventions:

The total sample was randomly divided into two equal groups. Group 1 received treatment with hybrid hyrax appliance where the two miniscrews were placed with lateral angulations in the anterior palate with two bands on the upper maxillary first molars. Group 2 received treatment with hybrid hyrax appliance where the two mini screws were placed perpendicular in the anterior palate with two bands on the upper maxillary first molars. The proper position and direction of miniscrews placement is recognized on a CBCT scan as following.

After scanning the upper arch ,it was superimposed onto the CBCT scan to produce surgical guide that will in shape the morphology of the palate and the teeth in the buccal and posterior segments of the upper arch. Two cylindrical guides are designed to duplicate the angle of insertion and avoid penetrating of the palate by the miniscrews beyond the required depth.

#### Observation:

The CBCT images were performed before the start of the orthodontic expansion (T 1) and 3 months after the last activation (T 2): Buccal and palatal maxillary width, NFMW, HPMW, HPW, DABW, PAW, PPA, and change in slope were measured. the mean differences between pre-expansion and pos- expansion measurements within each group were measured.



**Figure (1):** a, placement of miniscrews using surgical guide b, upper occlusal view During insertion in Angulated group, c, upper occlusal view after activation in Angulated group d, upper occlusal view During insertion in perpendicular group e, upper occlusal view after activation in perpendicular group

**RESULTS**

The current study was conducted on a total sample of twenty young adult orthodontic patients (13 girls and 7 boys) ten in each group presented with maxillary deficiency with an age ranged from 12 to 18 years and mean age of  $13.77 \pm 2.02$  in angulated group, in comparison to  $14.89 \pm 1.41$  in the perpendicular group. And there was no statistically significant difference ( $p > 0.05$ ).

The mean values of the pre-expansion maxillary skeletal, alveolar, and was no significant difference

between the groups in terms of their initial values ( $p > 0.05$ ). The effects of the angulated and perpendicular groups on the alveolar and dental level of the maxilla are presented in Table 1. In the intergroup comparisons, there was no significant difference between the groups in any measurement ( $p > 0.05$ ). In the analysis of the skeletal changes of the maxilla on the levels of the nasal floor and hard palate are presented in Table 2. In the intergroup comparisons, there was no significant difference between the groups in measurement ( $p > 0.05$ ).

**Table (1): Comparison of Percent change in Buccal and palatal maxillary width**

	Angulated group		Perpendicular group		P value
	Mean	SD	Mean	SD	
Buccal maxillary width 6	9.80	2.34	7.39	3.91	.077ns
Buccal maxillary width 5	8.46	3.42	6.20	5.43	.190ns
Buccal maxillary width 4	8.85	4.23	6.75	5.67	.387ns
Buccal maxillary width 3	7.85	5.64	8.82	6.48	.863ns
Palatal maxillary width 6	17.77	8.83	11.32	7.23	.113ns
Palatal maxillary width 5	10.18	10.14	11.51	6.63	.666ns
Palatal maxillary width 4	13.14	8.78	14.74	13.52	.863ns
Palatal maxillary width 3	22.23	14.38	18.54	16.68	.489ns

Significance level  $p \leq 0.05$ , ns=non-significant

**Table (2): Comparison of Percent change in NFMW, HPMW, HPW, DABW, PAW, PPA**

	Angulated group		Perpendicular group		P value
	Mean	SD	Mean	SD	
NFMW4	6.27	3.34	6.48	6.30	.743ns
NFMW6	4.94	2.87	4.63	2.47	.990 ns
HPMW4	6.49	3.15	5.45	4.36	.481 ns
HPMW6	6.13	3.36	4.08	2.41	.190 ns
HPW4	20.14	7.74	18.05	12.52	.541 ns
HPW6	15.43	6.69	9.89	6.67	.258 ns
DABW4	10.63	4.80	11.34	6.02	.815 ns
DABW6	18.00	3.88	12.44	5.20	.031*
PAW4	17.44	8.70	10.10	7.77	.105 ns
PAW6	12.05	5.62	10.79	6.61	.730 ns
PAA4	12.53	8.44	13.19	7.42	.606 ns
PAA6	16.74	7.26	11.14	6.61	.161 ns

Significance level  $p \leq 0.05$ , \* significant, ns=non-significant

**NFMW 4:** Nasal Floor Maxillary Width first premolar, **NFMW 6:** Nasal Floor Maxillary Width first molar, **HPMW 4:** Hard Palate Maxillary Width first premolar, **HPMW 6:** Hard Palate Maxillary Width first molar. **HPW 4:** Hard palate width first premolar, **HPW 6 :** Hard palate width first molar, **PAA 4(°):** Palatal alveolar angle first premolar, **PAA 6(°):** Palatal alveolar angle first molar. **DABW 4:** Dental Arch Buccal Width first premolar, **DABW 6:** Dental Arch Buccal Width first molar, **PAW 4:** Palatal Apex Width first premolar, **PAW 6:** Palatal Apex Width first molar,.

**DISCUSSION**

Using CBCT scans, this study aimed to assess how different hybrid hyrax maxillary expander appliance designs affected skeletal and dental structures. In terms of age, sex distribution, or skeletal dimensions, the baseline features of the

perpendicular (group 1) and the angulated (group 2 ) groups were essentially unified and harmonized prior to treatment, indicating that the two groups were nearly identical. The activation period for each group lasted 16 to 20 days

Although there was no statistically significant difference between the groups in our study, it was

found that both of the studied groups significantly increased the maxillary width on the levels of the hard palate and nasal floor. Both devices also demonstrated the same skeletal efficacy and expansion potentials; this was in accordance with previous studies.<sup>(8-13)</sup> Garib et al found that when compare the traditional Hyrax expander to the hybrid one there was higher increase in the nasal cavity and maxillary widths.<sup>(9)</sup> On the other hand Toklu et al, was in discordance with our study, since they found that similar increases in nasal cavity width after expansion using hybrid and conventional Hyrax expanders in growing individuals.<sup>(14)</sup>

The use of a tooth-bone-borne hybrid expander may be more appropriate when a more definite skeletal expansion is required in adult patients with a transverse maxillary deficiency because, according to An et al., the hybrid appliance group led to more skeletal and parallel expansion of the maxilla than tooth-borne-RME in adult patients. Vanarsdall et al and Chane-Fane concluded the same.<sup>(15-17)</sup>

In disagreement with our study several studies concluded that the disconnection of the maxillary bones occurs in a triangular manner (V-shaped) in the axial plane, with the apex toward the nasal cavity and the base at the same level as the palatine processes. In other words, the midpalatal suture has its largest opening anteriorly, with decreasing separation as it moves posteriorly.<sup>(18, 19)</sup> As a result, with the hybrid hyrax expander, the borders of the midpalatal suture moved almost parallel to one another in the axial palatal plane, indicating an almost parallel opening pattern. It was shown that both appliances produced comparable levels of expansion in the molar region on the hard palate level and the nasal floor level. This is also supported by a postero-anterior radiograph. This supports earlier research.<sup>(20, 21)</sup>

There was a slight resistance in suture opening and this was demonstrated by Midline diastema and radiologic suture opening. Three patients (one from Group 1 and two from Group 2) exhibited failure of suture separation. Variations in suture obliteration and the resistance from craniofacial structures could be the reason for expansion failure in adults.<sup>(22, 23)</sup>

Transverse dimensional changes are predictable results of RME. After expansion with hybrid hyrax appliances, all interdental and intra alveolar measurements significantly increased.<sup>(24)</sup> In our study, the palatal and buccal maxillary transverse width measurements were increased in both groups. The first molar in both groups showed the greatest increase in palatal and buccal alveolar bone width where the orthopedic forces were directly applied on the posterior teeth. This may be explained by the fact that hybrid expanders typically showed a slight posterior divergence of the screw hinges due

to the expansion limitation caused by the anterior skeletal anchorage. The dentoalveolar area of the maxillary first molars may therefore be more affected by the expansion force. Another hypothesis was that while the hybrid hyrax was in the oral cavity, the eruption of the first molar was suppressed. Subjects treated with hybrid hyrax showed a relative intrusion of the maxillary first molars. These side effects could have combined to increase the molar intercrestal distance. This results was in agreement with previous studies<sup>(25-26)</sup> and was in disagreement with Weissheimer et al because he used conventional hyrax without supporting miniscrews.<sup>(27)</sup>

Considering first molar inclination in our study the average increase at the right and left first molars level in the perpendicular group was 7.08 and 5.60 respectively while the average increase at the right and left first molars level in the angulated group was 7.08 and 5.60 respectively. No great difference was found between right and left sides, representing symmetrical effect of expansion, this was in agreement to previous studies.<sup>(25, 19, 28)</sup> And was in disagreement with other studies due to using different expansion expanders and protocol.<sup>(29)</sup> This significant increase in molar inclination was in accordance with Moon et al.<sup>(30)</sup> Who found that, molar inclination increased in mini implants supported expansion also the same results was found by Bhaa et al.<sup>(31)</sup> Vassar.<sup>(32)</sup> and Lagravère et al.<sup>(33)</sup> The degree of buccal tipping in the alveolar plates was comparable in both groups according to the angular measures used to characterize tipping happening in the palatal alveolar plates in our study. In addition, it was noted that in both groups, the anterior skeletal anchoring provided by the miniscrews reduced the alveolar bone's tendency to tip posteriorly. As a result of the lateral rotation of the maxillary halves as well as tooth movement in the alveolar bone, buccal tipping occurs following RME.

#### Conclusion:

There was significant difference between the pre and post expansion measurements at the skeletal and dental levels in each group but no statistically significant difference between the two groups. However, the palatal tissue reaction to the perpendicular positioned miniscrews is better than that to the angulated one in which some degree of palatal mucosa over growth was occurred.

#### REFERENCES

1. Timms DJ. The dawn of rapid maxillary expansion. Angle Orthod. 1999;69(3):247-50.
2. Hansen L, Tausche E, Hietschold V, Hotan T, Lagravère M, Harzer W. Skeletally-anchored rapid maxillary expansion using the Dresden



- distractor. *J Orofac Orthop/Fortschritte der Kieferorthopädie*. 2007; 68:148–58.
3. Shrivastava N, Thukral R, Garg A, Tripathi A, Marothiya S. Stress pattern and deformation in mid-palatal suture and posterior dentoalveolar area with two different types of rapid maxillary expansion appliances: a finite element method study. *J Indian Orthod Soc*. 2021; 55:278–84.
  4. Choi SH, Shi KK, Cha JY, Park YC, Lee KJ. Nonsurgical miniscrew-assisted rapid maxillary expansion results in acceptable stability in young adults. *Angle Orthod*. 2016;86:713–20.
  5. Kaya N, Seker ED, Yücesoy T. Comparison of the effects of different rapid maxillary expansion techniques on craniofacial structures: a finite element analysis study. *Progress in Orthodontics*. 2023 Dec;24(1):1-1.
  6. Toklu MG, Germec-Cakan D, Tozlu M. Periodontal, dentoalveolar, and skeletal effects of tooth-borne and tooth-bone-borne expansion appliances. *American journal of orthodontics and dentofacial orthopedics*. 2015 Jul 1;148(1):97-109.
  7. Wilmes B, Nienkemper M, Drescher D. Application and effectiveness of a mini-implant- and tooth-borne rapid palatal expansion device: the hybrid hyrax. *World J Orthod* 2010; 11(4):323-30.
  8. Garib DG, Henriques JF, Janson G, Freitas MR, Coelho RA. Rapid maxillary expansion--tooth tissue-borne versus tooth-borne expanders: a computed tomography evaluation of dentoskeletal effects. *Angle Orthod* 2005; 75(4):548-57.
  9. Garib D, Miranda F, Palomo JM, Pugliese F, da Cunha Bastos JC, Dos Santos AM, et al. Orthopedic outcomes of hybrid and conventional Hyrax expanders. *Angle Orthod* 2021; 91(2):178-86.
  10. Pasqua BPM, André CB, Paiva JB, Tarraf NE, Wilmes B, Rino-Neto J. Dentoskeletal changes due to rapid maxillary expansion in growing patients with tooth-borne and tooth-bone-borne expanders: A randomized clinical trial. *Orthod Craniofac Res* 2022; 25(4):476-84.
  11. Kanomi R, Deguchi T, Kakuno E, Takano-Yamamoto T, Roberts WE. CBCT of skeletal changes following rapid maxillary expansion to increase arch-length with a development-dependent bonded or banded appliance. *Angle Orthod* 2013; 83(5):851-7.
  12. Ballanti F, Lione R, Fanucci E, Franchi L, Baccetti T, Cozza P. Immediate and post-retention effects of rapid maxillary expansion investigated by computed tomography in growing patients. *Angle Orthod* 2009; 79(1):24-9.
  13. Phatouros A, Goonewardene MS. Morphologic changes of the palate after rapid maxillary expansion: a 3-dimensional computed tomography evaluation. *Am J Orthod Dentofacial Orthop* 2008; 134(1):117-24.
  14. Gunyuz Toklu M, Germec-Cakan D, Tozlu M. Periodontal, dentoalveolar, and skeletal effects of tooth-borne and toothbone-borne expansion appliances. *Am J Orthod Dentofacial Orthop*. 2015;148:97–109.
  15. Chane-Fane C, Darqué F. Rapid maxillary expansion assisted by palatal mini-implants in adolescents - preliminary study. *Int Orthod* 2015; 13(1):96-111.
  16. An JS, Seo BY, Ahn SJ. Comparison of dentoskeletal and soft tissue changes between tooth-borne and tooth-bone-borne hybrid nonsurgical rapid maxillary expansions in adults: a retrospective observational study. *BMC Oral Health* 2021; 21(1):658.
  17. Vanarsdall Jr RL, Blasi I, Evans M, Kocian P. Rapid maxillary expansion with skeletal anchorage vs. bonded tooth/tissue born expanders: a case report comparison utilizing CBCT. *RMO Clin Rev* 2012; 1(1):18-22.
  18. Ghoneima A, Abdel-Fattah E, Hartsfield J, El-Bedwehi A, Kamel A, Kula K. Effects of rapid maxillary expansion on the cranial and circummaxillary sutures. *Am J Orthod Dentofacial Orthop* 2011; 140(4):510-9.
  19. Shendy M, A Atwa A, Y Abu Shahba R. Effect of rapid maxillary expansion on the buccal alveolar bone: Clinical and radiographic evaluation. *Al-Azhar J Dent Sci* 2018; 21(2):175-82.
  20. Park JJ, Park YC, Lee KJ, Cha JY, Tahk JH, Choi YJ. Skeletal and dentoalveolar changes after miniscrew-assisted rapid palatal expansion in young adults: A cone-beam computed tomography study. *Korean J Orthod* 2017; 47(2):77-86.
  21. Cross DL, McDonald JP. Effect of rapid maxillary expansion on skeletal, dental, and nasal structures: a postero-anterior cephalometric study. *Eur J Orthod* 2000; 22(5):519-28.
  22. Lee KJ, Park YC, Park JY, Hwang WS. Miniscrew-assisted nonsurgical maxillary expansion before orthognathic surgery for a patient with severe mandibular prognathism. *Am J Orthod Dentofacial Orthop*. 2010; 137:830–839.
  23. Choi, S. H., Shi, K. K., Cha, J. Y., Park, Y. C., & Lee, K. J. (2016). Nonsurgical miniscrew-assisted rapid maxillary expansion results in acceptable stability in young adults. *The Angle Orthodontist*, 86(5), 713-720.
  24. Gunyuz Toklu M, Germec-Cakan D, Tozlu M. Periodontal, dentoalveolar, and skeletal effects of tooth-borne and tooth-bone-borne expansion appliances. *Am J Orthod Dentofacial Orthop* 2015; 148(1):97-109.

25. Silva I, Miranda F, Bastos JCC, Garib D. Comparison of alveolar bone morphology after expansion with hybrid and conventional Hyrax expanders. *clin Oral Invest* 2023; 3(1):2702682.
26. Garib D, Miranda F, Palomo JM, Pugliese F, da Cunha Bastos JC, Dos Santos AM, et al. Orthopedic outcomes of hybrid and conventional Hyrax expanders: Secondary data analysis from a randomized clinical trial. *Angle Orthod* 2021; 91(2):178-86.
27. Weissheimer A, de Menezes LM, Mezomo M, Dias DM, de Lima EM, Rizzatto SM. Immediate effects of rapid maxillary expansion with Haas-type and hyrax-type expanders: a randomized clinical trial. *Am J Orthod Dentofacial Orthop* 2011; 140(3):366-76.
28. Pangrazio-Kulbersh V, Jezdimir B, de Deus Haughey M, Kulbersh R, Wine P, Kaczynski R. CBCT assessment of alveolar buccal bone level after RME. *Angle Orthod* 2013; 83(1):110.
29. Brunetto M, Andriani Jda S, Ribeiro GL, Locks A, Correa M, Correa LR. Three-dimensional assessment of buccal alveolar bone after rapid and slow maxillary expansion: a clinical trial study. *Am J Orthod Dentofacial Orthop* 2013; 143(5):633-44.
30. Moon HW, Kim MJ, Ahn HW, Kim SJ, Kim SH, Chung KR, et al. Molar inclination and surrounding alveolar bone change relative to the design of bone-borne maxillary expanders: A CBCT study. *Angle Orthod* 2020; 90(1):13-22.
31. Bahaa AM, Saleh MH, Abu-Shahba RY. Evaluation of the Dento-skeletal effects of Mini-implant Assisted Rapid Palatal Expansion in a sample of Adult Orthodontic Patients: A prospective clinical study. *Al-Azhar J Dent Sci* 2020; 23(3):311-9.
32. Vassar JW, Karydis A, Trojan T, Fisher J. Dentoskeletal effects of a temporary skeletal anchorage device-supported rapid maxillary expansion appliance (TSADRME): A pilot study. *Angle Orthod* 2016; 86(2):241-9.
33. Lagravère MO, Carey J, Heo G, Toogood RW, Major PW. Transverse, vertical, and anteroposterior changes from bone-anchored maxillary expansion vs traditional rapid maxillary expansion: a randomized clinical trial. *Am J Orthod Dentofacial Orthop* 2010; 137(3):304.e1-12.