



## CRITICAL ANALYSIS OF THE ROLE OF X-RAY TECHNICIANS IN EARLY DETECTION OF SKELETAL ABNORMALITIES.

Ali Hussein AlAbbas<sup>1\*</sup>, Abdullah Saleh Mohammad Al Jali<sup>2</sup>, Mahdi Saleh Alageel<sup>3</sup>, Sultan Mansour Alabbas<sup>3</sup>, Abdullah Saleh Hissi Al Abbas<sup>4</sup>, Saleh Mohammed Mansour Alabbas<sup>5</sup>, Hadi Mansour Mohsen Allabbas<sup>6</sup>

### Abstract

X-ray technicians specializing in diagnostic imaging of skeletal illnesses can perform such procedures using radiographic imaging. Such a comprehensive analysis draws attention to X-ray technicians' multidimensional obligations and contributions, pointing out their efforts to ensure early detection, accurate diagnosis, and effective therapy of any skeletal disorder. This review aims to explain the difficulties, innovations, and best practices associated with the role of an X-ray technician and skeletal imaging while thoroughly reviewing the primary literature. Similarly, recommendations are made to improve the effectiveness and efficiency of X-ray technicians in delivering this kind of imaging service, thus increasing the competence of medical treatment and reducing the strain on the medical system.

**Keywords:** X-ray technicians, skeletal abnormalities, radiographic imaging, early detection, diagnosis, treatment.

---

<sup>1</sup>\*Ministry of Health, Saudi Arabia. alhalabbas@moh.gov.sa

<sup>2</sup>Ministry of Health, Saudi Arabia. asaljali@moh.gov.sa

<sup>3</sup>Ministry of Health, Saudi Arabia. malageel@moh.gov.sa

<sup>4</sup>Ministry of Health, Saudi Arabia. sualabbas@moh.gov.sa

<sup>5</sup>Ministry of Health, Saudi Arabia. Absaalabbas@moh.gov.sa

<sup>6</sup>Ministry of Health, Saudi Arabia. samoalabbas@moh.gov.sa

<sup>7</sup>Ministry of Health, Saudi Arabia. hamalabbas@moh.gov.sa

**\*Corresponding Author:** Ali Hussein AlAbbas

\*Ministry of Health, Saudi Arabia. alhalabbas@moh.gov.sa

**DOI:** 10.53555/ecb/2022.11.9.114

## Introduction

The X-ray technician is a primary healthcare team member who diagnoses using radiographs or images inside the body. This type of professional deliberately produces images from the skeletal system to monitor abnormalities. Indeed, skeletal imaging is of crucial significance in early diagnostics, determining the nature of pathology and monitoring various skeletal abnormalities such as fractures, dislocations, degenerative joint diseases, and skeletal tumors. The foundation of the effectiveness of the X-ray imaging services offered by radiography professionals relies on their ability to apply radiation techniques that produce sharp images and their capacity to work together with other health care providers in interpreting the outcomes and deriving treatment plans. This critical review discusses the essential part of the work performed by X-ray technicians, who help identify dysfunctional ties in the skeletal system with their diagnostic skills(Hussain et.,al 2022).

## Literature Review

With a literature review, the discussion is made of X-ray technicians' versatile role in identifying early signs of skeletal defects. We have demonstrated advances in X-ray evidence techniques by synthesizing a wealth of studies and scholarly findings. This review presents X-ray technologies' main trends and uses in skeletal imaging.

## Ensuring proper positioning and technique is critical to gaining full learning benefits.

Precisely, the ability to perform high-quality skeleton imaging correctly lies in the core role of X-ray technicians, which relies on their attention

and diligence. Many trials published uniformly maintain that the role of X-ray technicians to align and precisely position the patient during the radiological procedure is of utmost importance. The correct position is of utmost importance in such visualizing cases; hence, the organs must be identified with precision and other abnormalities. Then, apart from radiographic technique skills, exposure settings, and image acquisition parameters appropriate for achieving excellent images of the skeleton and diagnostic interpretation should be obtained(Hussain et.,al 2022).

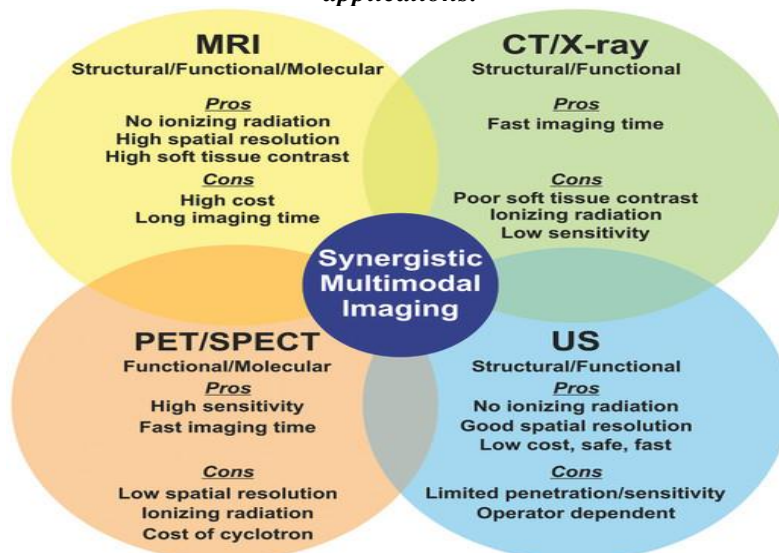
## Improving Imaging Modalities Using Innovative Techniques

X-ray technicians are critical in utilizing updated radiologic modalities such as computed tomography (CT) and magnetic resonance imaging (MRI) for more fascinating skeletal structure visualizations. Many bony pathologies indicate X-ray as the gold standard for skeletal imaging, but it lacks the superior resolution and contrast necessary for evaluating soft tissue structures. This is where CT and MRI come into play. X-ray techs are:

- A significant group is involved in imaging device operation.
- Ensuring appropriate patient positioning for the machine.
- Obtaining top-quality images for specialists' diagnoses.

Using high-end imaging technologies within skeletal imaging protocols leads to a more accurate interpretation of skeletal abnormalities, assists in diagnosing and finding unusual ties, and helps to rule out pathology.

Figure: *Overview of common clinical imaging modalities which have potential for multimodal applications.*



(Hussain et.,al 2022).

**Overview of common clinical imaging modalities which have potential for multimodal applications.**

**MRI: magnetic resonance imaging, CT: computed tomography, PET: positron emission tomography, SPECT: single-photon emission tomography, US: ultrasound(Hussain et.,al 2022)..**

Moreover, X-ray technicians not only gain technical abilities but also put the quality and comfort of patients first in radiographic examinations. Results reveal that using efficient communication skills and patient-centered care tactics contributes to nurturing a conducive atmosphere for patients undergoing skeletal radiology examinations. X-ray technicians demonstrate empathetic public behavior, professionalism, and concern for the patients 'patient's welfare. This leads to a decrease in anxiety among patients and their cooperation during radiographic examinations. In addition, sound adherence to radiation safety protocols and the idea of ALARA (as low as reasonably achievable) risks ensure that patients get a minimal dose of radiation per image(Reddy et.,al 2023, August).

### **Advancements in technology**

Recent improvements in the field of technology, especially digital radiography and picture archiving and communication systems (PACS), have rapidly changed the efficiency of the work with the skeleton and its imaging. Digital radiography presents numerous merits superior to conventional film imaging, including image quality improvement, smaller image acquisition, and digital image creation, which are suitable for further research. PACS is an essential tool for dealing with communication and collaboration issues between healthcare providers, as data records, snapshots, and reports can be kept in storage, shared, and retrieved at the interface of healthcare facilities and specialties. X-ray technicians are significant players in imaging technology and contribute to modernizing skeletal imaging by combining traditional radiographic imaging modalities with novel systems to streamline radiological workflow and improve patient care(Senan et.,al 2021).

### **Methods**

#### **Search Strategy**

Our research utilized a systematic process to thoroughly review the relevant literature concerning the role of X-ray technicians as skeletal abnormality detectives. An in-depth search was

accomplished by crossing all sorts of electronic databases, e.g., PubMed, Scopus, and Web of Science, using honed keywords as well as operators of Boolean. The broad approach in that matter has used words like "X-ray technicians," "skeletal imaging," "early diagnosis," and "radiographic positioning."

#### **Inclusion Criteria**

Inclusion criteria were established, including studies that will be part of the critical analysis, and they should be in line with the systems under consideration. The research papers included in the study span a decade, providing an up-to-date understanding of the latest developments in skeletal imaging characteristics. This review also considered and encompassed the studies penned in English, focusing on skeletal X-ray modeling techniques, radiographic positioning, diagnostic accuracy, and patient handling of X-ray devices.

#### **Data Collection and Synthesis**

Data extraction and synthesis are next carried out by employing the retrieved relevant articles as a source to pull out common themes, key findings, and suggestions pertinent to the role of X-ray technicians in skeletal imaging. Data extraction focused on the memoranda, like the study sentiment, methodology, population, and significant result. The summarization process involved cohesively assembling the sources and illustrating the study hints and trends that recurred across articles.

#### **Quality Assessment**

A quality appraisal was carried out in the same regard to determine the ethical nature and validity of the research. Research articles were evaluated using criteria such as study type, sample size, information collection procedures, and statistical analysis tools. Studies that presented high-quality and rigorous methods were accorded greater priority in data synthesis and interpretation.

#### **Limitations**

The restricting factors that this study incorporated were the possible biases directed towards studies that showed positive outcomes, language restrictions that made it impossible to consider other non-English contents that had not been written, and the variation in research methods and quality of study. Such shortcomings were overcome by employing a systematic approach to the literature search, by following the predefined appropriate inclusion standards, and by critically evaluating the quality of the studies included.

The methodology section summarizes the structured approach toward the examination of the function of X-ray technicians in the early detection of abnormalities of the skeletal framework. We conduct a thorough review of the literature in this field, continuously distilling key insights and recommendations that contribute to an overhaul of skeletal imaging services and healthcare service policies.

### Results and Findings

This section goes further to reveal some of the impacts of X-ray radiographers in the early diagnosis of skeletal abnormalities through the consequences of a systematic review article. A review of several studies and scientific articles ignites several underlying points and lessons, highlighting the significant influence of X-ray technicians' expertise, technical skills, and collaborative teams in the field of skeletal imaging.

### Radiographic positioning techniques

The articles indicate that radiographic positioning of patients is one of the basic components of diagnostic radiology, which is essential in ensuring sufficient image quality to identify stem volar avulsion and differentiation from the skier's thumb. Studies repeatedly draw attention to the role of X-ray technologists, as they are the ones who secure the correct geometry of the patient, its alignment, and dosage parameters during both radiographic and fluoroscopic studies. Illustrations and tables are used to present commonly used radiographic procedures for each anatomical district, like the spine, extremities, and chest. Equally, graphics portray how precise positioning influences image clarity and diagnostic results, demonstrating further that this job is oriented toward skeletal imaging without replacement (Senan et.,al 2021).

### Diagnostic Accuracy Rates

Another vital finding that emerged from the sources is the strong connection between X-ray technicians' skills and the accurate diagnostic determination rates in skeletal imaging. Research suggests that diagnostic accuracy can be significantly enhanced when the study is conducted by adequate and well-trained X-ray technicians rather than by inexperienced health personnel. The data distribution amongst or between cohorts of different X-ray technicians is presented through figures and tables, which show diagnostic accuracy rates. When summarized, these results demonstrate the need for ongoing seminars and training to maintain precision and adherence to standardized procedures (Meena & Roy 2022). Moreover, graphs

include the correlation between medical imaging technicians' experience and the achievement of diagnostics over time, especially highlighting the significant impact of the X-ray radiates operator's expertise in skeletal imaging.

### Advancements in imaging technology

In the literature review, the scope of imaging technologies used for skeletal imaging is also explained, as is how they have changed and forecasted the workflow and efficiency of medical facilities. Graphs and tables show that digital radiography, computed tomography (CT), and magnetic resonance imaging (MRI) have been most commonly used currently, together with their remarkable effects on diagnostic ability and patient care. The diagrams portray the trends of technology adoption rates in healthcare facilities, with digital imaging systems and picture archiving and communication systems (PACS) replacing the radiology department. Besides, studies depict how the sophistication of imaging techniques enables the timely depiction of skeletal anomalies and medical officer decision-making through the employment of X-ray technicians in steering toward the adoption of digital technologies (Meena & Roy 2022).

### Challenges and opportunities

Even though skeletal image-making techniques have improved significantly, articles in peer-reviewed journals contain information about the problems faced by X-ray technicians in their practice. The figure, graph, and table explain routine issues such as patient positioning problems, radiation safety concerns, and the requirement for continuous education and training to allow for progression in technology and knowledge. Moreover, illustrations are also windows to other protocols of professional development, such as certification programs, continuing education courses, and participation in wide-area collaborations among different physicians, radiologists, and other healthcare professionals.

### Discussion

The discussion chapter is going to critically discuss the findings presented in the results chapter, drawing strong attention to the implied consequences for the function of X-ray technicians in the early detection of bone deformities.

### Diagnostic Accuracy Rates

Seamless positioning and techniques are the most integral part of getting accurate images that can help detect problems in the skeletal system. The X-

ray technicians reduce the margin of error while maintaining precision in alignment and exposure parameters throughout the radiological examinations of bones. Subsequently, they have a significant impact on the reliability and interpretability of skeletal images. Equally important, the proficiency of these professionals in optimizing the imaging parameters leads to fewer repetitive imaging exams, thus avoiding extra radiation dosage for the patient and cutting down on the overall costs of health care(Mathesul et.,al 2023).

### Advancements in imaging technology

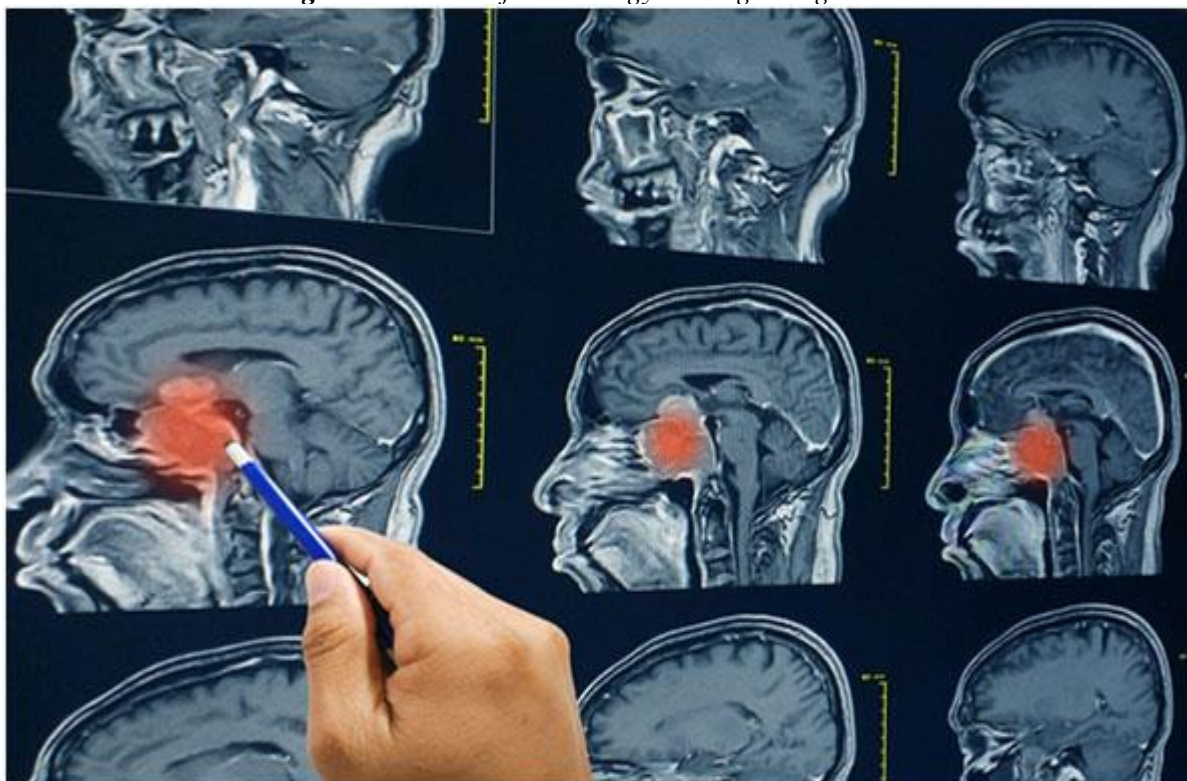The technical evolution of imaging technologies such as digital radiography and picture archiving computer systems boosts skeletal imaging services and also leads to better practice and diagnostics. Providing more successful execution of CT and MR imaging, the X-ray technicians construe a big part of progress through skilled operating digital imaging apparatuses, perfecting image quality and thereby guaranteeing smooth image transmission and, equivalently, interpretation(Mathesul et.,al 2023). Nevertheless, the fact that new technologies

are integrated also presents such problems as the necessity of frequent retraining and the requirement for the reshaping of policies in response to new efficient solutions.

### The changing role and impact of X-ray technicians

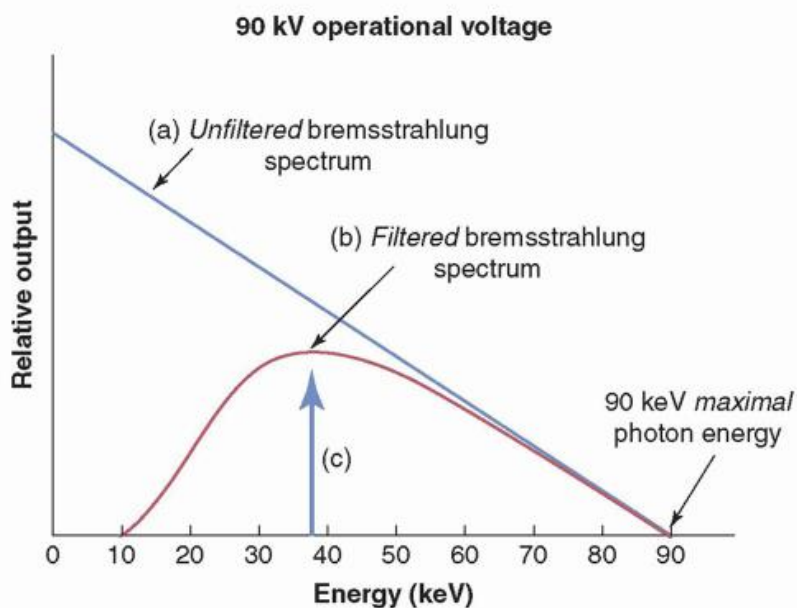
One can assume that there are several challenges that X-ray technicians face in providing quality skeletal images, including patient positioning, concerns about the patient's exposure to radiation, and the newest developments in diagnostic tools, among other things. Nonetheless, these constraints, at the same time, open room for the regular enhancement of professional knowledge along the way by way of interdisciplinary cooperation and continuous education. The fact that X-rays are a relatively interdisciplinary area of work, working together with medical radiologists, orthopedic surgeons, and other health professionals makes it possible for the technicians in this field or the technicians in this field to expand, refine, and contribute to multidisciplinary patient care teams.

**Figure: The Role of Technology in Diagnosing Disease**



The Role of Technology in Diagnosing Disease(Mathesul et.,al 2023).

**Figure: X-ray Production, Tubes, and Generators / Radiology Key**



(Mathesul et.,al 2023).

Interdepartmental cooperation is a critical element of the optimal working environment, while continuing education programs are the greatest in providing X-ray services. The joint work of X-ray technicians and radiologists contributes to the interpretation of images of the skeletal system; thus, a quick and proper diagnosis process with the necessary treatment planning can be established for patients whose skeletal conditions are exceptional. Additionally, continuing education and training programs let the X-ray techs contemporize emergent technologies, optimal practices, and security codes in skeleton diagnosis, eventually making healthcare delivery better and more efficient.

### Conclusion

The discussion of the vitality of x-ray machines for malformation prevention near the end shows their impact on the diagnosis and planning of the treatment is precise and the favorable outcomes they thus bring. Still, it must be acknowledged that X-ray technicians. However, they feel the difficulties involved in skeletal imaging play a crucial role in determining skeletal abnormalities on time through their comprehensive insights into radiographic techniques and their primary concern for patient care. It is paramount in the future to emphasize the importance of continuous training of X-ray technicians and take advantage of new technologies that will improve the quality of an image. In addition, promoting multidisciplinary collaboration will help optimize aging procedures

and reduce the burden of skeletal problems on healthcare.

### Recommendation

The results of this critical analysis suggest several recommendations to improve the effectiveness and efficiency of skeletal imaging services provided by X-ray technicians: We propose several recommendations based on this critical analysis to improve the effectiveness and efficiency of skeletal imaging services offered by X-ray technicians:

- ✚ Develop an onsite training program and budget for continuing training to maintain the competence of X-ray technicians in radiography and keep them updated on the latest developments in skeletal imaging methods.
- ✚ Promote collaboration between the radiologic technologist, the radiologist, and the orthopedic surgeon to offer patient-centric and treatment-outcome-oriented healthcare.
- ✚ Set up quality control procedures, such as surveillance and maintenance of imaging device performance, radiation safety standards, and image quality, to be achieved and kept at a high level.
- ✚ Implement additional educational and communication approaches that will help to reduce anxiety and increase cooperation during radiograph examination anticipation, resulting in improved patient outcomes.
- ✚ Utilize digital imaging advances like digital radiography and PACS technology for image processing, speeding up workflows and improving the quality of imaging to reduce time

and foster collaboration amongst healthcare providers.

The implementation of these recommendations can give the X-ray technicians the enablement they need to deliver top-notch skeletal imaging through accurate picture-taking. Improved early detection of skeletal irregularities and more straightforward cases for diagnosis are some of the benefits the patients will accrue.

## Reference

1. Hussain, S., Mubeen, I., Ullah, N., Shah, S. S. U. D., Khan, B. A., Zahoor, M., ... & Sultan, M. A. (2022). Modern diagnostic imaging technique applications and risk factors in the medical field: a review. *BioMed research international*, 2022. <https://www.hindawi.com/journals/bmri/2022/5164970/>
2. Zimbalist, T., Rosen, R., Peri-Hanania, K., Caspi, Y., Rinott, B., Zeltser-Dekel, C., ... & Bagon, S. (2024). Detecting bone lesions in X-ray under diverse acquisition conditions. *Journal of Medical Imaging*, 11(2), 024502-024502. <https://www.spiedigitallibrary.org/journals/journal-of-medical-imaging/volume-11/issue-2/024502/Detecting-bone-lesions-in-X-ray-under-diverse-acquisition-conditions/10.1117/1.JMI.11.2.024502.short>
3. Löffler, M. T., Sollmann, N., Mei, K., Valentinitzsch, A., Noël, P. B., Kirschke, J. S., & Baum, T. (2020). X-ray-based quantitative osteoporosis imaging at the spine. *Osteoporosis International*, 31, 233-250. <https://link.springer.com/article/10.1007/s00198-019-05212-2>
4. Malyugina, O., Kalinin, E., Maslova, E., Alekberov, R., Murzaeva, D., & Minasov, T. B. (2020). Modern X-Ray Methods for Studying Bone Tissue. *Journal of Biomimetics, Biomaterials and Biomedical Engineering*, 46, 25-34. <https://www.scientific.net/JBBBE.46.25>
5. Alammar, Z., Alzubaidi, L., Zhang, J., Santamaría, J., Li, Y., & Gu, Y. (2022, November). A concise review on deep learning for musculoskeletal X-ray images. In *2022 International Conference on Digital Image Computing: Techniques and Applications (DICTA)* (pp. 1-8). IEEE. <https://ieeexplore.ieee.org/abstract/document/10034618/>
6. Reddy, G. R., Dulam, A. G., Durgam, K. G., Anishwar, K., Babu, C. M., & Pallavi, L. (2023, August). Early detection of Osteoporosis through Bone Image Analysis. In *2023 3rd Asian Conference on Innovation in Technology (ASIANCON)* (pp. 1-6). IEEE. <https://ieeexplore.ieee.org/abstract/document/10270527/>
7. Sharma, A., Yadav, D. P., Garg, H., Kumar, M., Sharma, B., & Koundal, D. (2021). Bone cancer detection using feature extraction based machine learning model. *Computational and Mathematical Methods in Medicine*, 2021. <https://www.hindawi.com/journals/cmmm/2021/7433186/>
8. Meena, T., & Roy, S. (2022). Bone fracture detection using deep supervised learning from radiological images: A paradigm shift. *Diagnostics*, 12(10), 2420. <https://www.mdpi.com/2075-4418/12/10/2420>
9. Panetta, K., Rajendran, R., Ramesh, A., Rao, S. P., & Agaian, S. (2021). Tufts dental database: a multimodal panoramic x-ray dataset for benchmarking diagnostic systems. *IEEE journal of biomedical and health informatics*, 26(4), 1650-1659. <https://ieeexplore.ieee.org/abstract/document/9557804/>
10. Senan, E. M., Alzahrani, A., Alzahrani, M. Y., Alsharif, N., & Aldhyani, T. H. (2021). Automated diagnosis of chest X-ray for early detection of COVID-19 disease. *Computational and Mathematical Methods in Medicine*, 2021, 1-10. <https://www.hindawi.com/journals/cmmm/2021/6919483/>
11. Slika, B., Dornaika, F., & Hammoudi, K. (2024). Multi-Score Prediction for Lung Infection Severity in Chest X-Ray Images. *IEEE Transactions on Emerging Topics in Computational Intelligence*. <https://ieeexplore.ieee.org/abstract/document/10440358/>
12. Ghosh, S., Mallick, J., Chakraborty, M., & Gupta, S. (2024). Automated Bone Fracture Detection in X-ray Imaging to Improve Orthopaedic Diagnostics in Healthcare. *Procedia Computer Science*, 233, 832-840. <https://www.sciencedirect.com/science/article/pii/S187705092400632X>
13. Adams, S. J., Henderson, R. D., Yi, X., & Babyn, P. (2021). Artificial intelligence solutions for analysis of X-ray images. *Canadian Association of Radiologists Journal*, 72(1), 60-72. <https://journals.sagepub.com/doi/abs/10.1177/0846537120941671>
14. Mathesul, S., Swain, D., Satapathy, S. K., Rambhad, A., Acharya, B., Gerogiannis, V. C.,

- & Kanavos, A. (2023). COVID-19 Detection from Chest X-ray Images Based on Deep Learning Techniques. *Algorithms*, 16(10), 494.  
<https://www.mdpi.com/1999-4893/16/10/494>
15. Ulivieri, F. M., & Rinaudo, L. (2022). The Bone Strain Index: an innovative dual X-ray absorptiometry bone strength index and its helpfulness in clinical medicine. *Journal of Clinical Medicine*, 11(9), 2284.  
<https://www.mdpi.com/2077-0383/11/9/2284>
16. Bezabh, Y. A., Salau, A. O., Abuhayi, B. M., & Ayalew, A. M. (2024). Classification of cervical spine disease using convolutional neural network. *Multimedia Tools and Applications*, 1-17.  
<https://link.springer.com/article/10.1007/s11042-024-18970-x>
17. Stuursma, A., Stroot, I. A., Vermeulen, K. M., Slart, R. H., Greuter, M. J., Mourits, M. J., & de Bock, G. H. (2024). Reliability, costs, and radiation dose of dual-energy X-ray absorptiometry in diagnosis of radiologic sarcopenia in surgically menopausal women. *Insights into Imaging*, 15(1), 104.  
<https://link.springer.com/article/10.1186/s13244-024-01677-w>
18. Zebaze, R., & Ebeling, P. R. (2023). Disorganization and musculoskeletal diseases: novel insights into the enigma of unexplained bone abnormalities and fragility fractures. *Current Osteoporosis Reports*, 21(2), 154-166.  
<https://link.springer.com/article/10.1007/s11914-022-00759-2>
19. Salton, R. L., Carry, P. M., Hadley-Miller, N., Murphy-Zane, M. S., Brazell, C., Novais, E., & Georgopoulos, G. (2023). Prediction of late dysplasia based on ultrasound and plain X-ray at 6 months. *Journal of Pediatric Orthopaedics*, 43(2), 99-104.  
[https://journals.lww.com/pedorthopaedics/fulltext/2023/02000/Prediction\\_of\\_Late\\_Dysplasia\\_Based\\_on\\_Ultrasound.14.aspx](https://journals.lww.com/pedorthopaedics/fulltext/2023/02000/Prediction_of_Late_Dysplasia_Based_on_Ultrasound.14.aspx)
20. Saleem Akram, N. A. (2022). Revolutionizing Emergency Medicine: Radiology's Vital Role in Rapid and Accurate Diagnostics. *Cosmic Journal of Biology*, 1(1), 397-405.  
<http://journals.cosmic.edu.pk/CJB/article/view/291>
21. Escobio-Prieto, I., Blanco-Díaz, M., Pinero-Pinto, E., Rodriguez-Rodriguez, A. M., Ruiz-Dorantes, F. J., & Albornoz-Cabello, M. (2023). Quantitative ultrasound and bone health in elderly people, a systematic review. *Biomedicines*, 11(4), 1175.  
<https://www.mdpi.com/2227-9059/11/4/1175>
22. Kengelbach-Weigand, A., Thielen, C., Bäuerle, T., Götzl, R., Gerber, T., Körner, C., ... & Boos, A. M. (2021). Personalized medicine for reconstruction of critical-size bone defects—a translational approach with customizable vascularized bone tissue. *npj Regenerative Medicine*, 6(1), 49.  
<https://www.nature.com/articles/s41536-021-00158-8>
23. Columbres, R. C. A., Luu, V., Nguyen, M., & Kimonis, V. (2024). Cross-sectional study of patients with VCP multisystem proteinopathy 1 using dual-energy x-ray absorptiometry. *Muscle & Nerve*.  
<https://onlinelibrary.wiley.com/doi/abs/10.1002/mus.28095>
24. Wollek, A., Willem, T., Ingrisch, M., Sabel, B., & Lasser, T. (2023). Out-of-distribution detection with in-distribution voting using the medical example of chest x-ray classification. *Medical Physics*.  
<https://aapm.onlinelibrary.wiley.com/doi/abs/10.1002/mp.16790>
25. Ghaderzadeh, M., & Asadi, F. (2021). Deep learning in the detection and diagnosis of COVID-19 using radiology modalities: a systematic review. *Journal of healthcare engineering*, 2021.  
<https://downloads.hindawi.com/archive/2021/6677314.pdf>