



An Overview about Warts; Etiology, Pathogenesis and Presentation

Hadeer Mohamed Baiomy Ali, Soheir Ghonemy, Basma Magdy Elkholy

Dermatology, Venereology and Andrology Department, Faculty of Medicine, Zagazig University, Egypt

Email: Hadeerbaiomy38@gmail.com

Article History: Received 10th June, Accepted 5th July, published online 10th July 2023

Abstract

Background: Warts are benign lesions that occur in the mucosa and skin. Warts are caused by the human papillomavirus (HPV), with over 100 types of HPV identified. HPV may occur at any site. The primary manifestations of HPV infection include common warts, genital warts, flat warts, deep palmoplantar warts (Mycetozoa), focal epithelial hyperplasia, Epidermodysplasia verruciformis, and Plantar cysts. Warts may be transmitted by direct or indirect contact. Events that disrupt the normal epithelial barrier increase the likelihood of developing warts. Treatment may be difficult. Warts often resolve spontaneously within a few years. Some high-risk HPV subtypes are associated with malignancies, including types 6, 11, 16, 18, 31, and 35. Malignant transformation usually is seen in patients with genital warts and immunocompromised patients. HPV types 5, 8, 20, and 47 have oncogenic potential leading to epidermodysplasia verruciformis.

Keywords: Warts, Pathogenesis, Presentation

DOI:10.53555/ecb/2023.12.Si12.246

Introduction

skin condition. For both patients and practitioners, plantar warts are a source of irritation because no one treatment works for everyone. More than two years of treatment has failed to get rid of recalcitrant warts, thus they're referred to as "recalcitrant." Treating recalcitrant patients with immunotherapy and preventing its recurrence have been good outcomes. HPV is thought to be present in the bodies of 40% of the world's population. Plantar warts affect 14% of the general population each year. When it comes to plantar warts, young people are more likely to have them due to a variety of factors, the most common of which are immunodeficiency or overuse of public showers and/or public restrooms. The majority of cutaneous warts will regress spontaneously within a year or 2 from the initial infection. Reinfection with the same type of HPV virus is uncommon after complete clearance. Transmission occurs via direct skin-to-skin contact or indirectly through contaminated surfaces and objects (e.g., swimming pools, towels, etc.). Minor abrasions and breaks of skin's integrity are usually needed to expose basal keratinocytes to HPV. Autoinoculation of the virus is also a major factor of viral spreading (1).

Etiology

- 1. Human Papillomavirus Infection:** Common warts are a result of HPV infection. HPV is a group of more than 200 related viruses, and certain types within the HPV family cause warts on the skin and mucous membranes. HPV-2 and HPV-4 are commonly associated with common warts, but HPV-1, HPV-3, HPV-26, and HPV-29 can also be implicated (2).

- Transmission:** HPV is transmitted through direct contact with an infected person's skin or indirectly through contaminated objects, such as towels or shower floors. The virus enters the body through cuts, scratches, or other breaks in the skin (3).
- Risk Factors:** Certain factors can increase the risk of developing common warts, such as a weakened immune system, skin trauma, and frequent contact with contaminated surfaces. Children and teenagers are more susceptible to common warts than adults (4).

Virology and life cycle

HPV is part of the family Papillomaviridae, composed of various genera (Alpha-, Beta-, Gamma-, Nu- and Mu-papillomavirus) in which species named with correlative numbers are grouped (for example, Alphapapillomavirus has 15 species) (5).

Each species is further subdivided into genotypes (commonly known as HPV), and more than 200 different genotypes have been identified to date. They are classified according to the structure of the viral genome and human epithelial tissue tropism(2).

HPV is a non-enveloped circular virus measuring 55 nm in diameter. The capsid is icosahedral and composed of 72 capsomeres. Filamentous and tubular forms can occur as a result of aberrant maturation. ether, acid and heat (50°C,1h. Despite the fact that the family Papillomavirus is categorised by a largely heterogeneous group of viruses, they share the same structure and organisation of the genome as shown in The onset of lesions requires persistent infection, which explains why the prevalence of lesions is lower than the prevalence of infection (5).

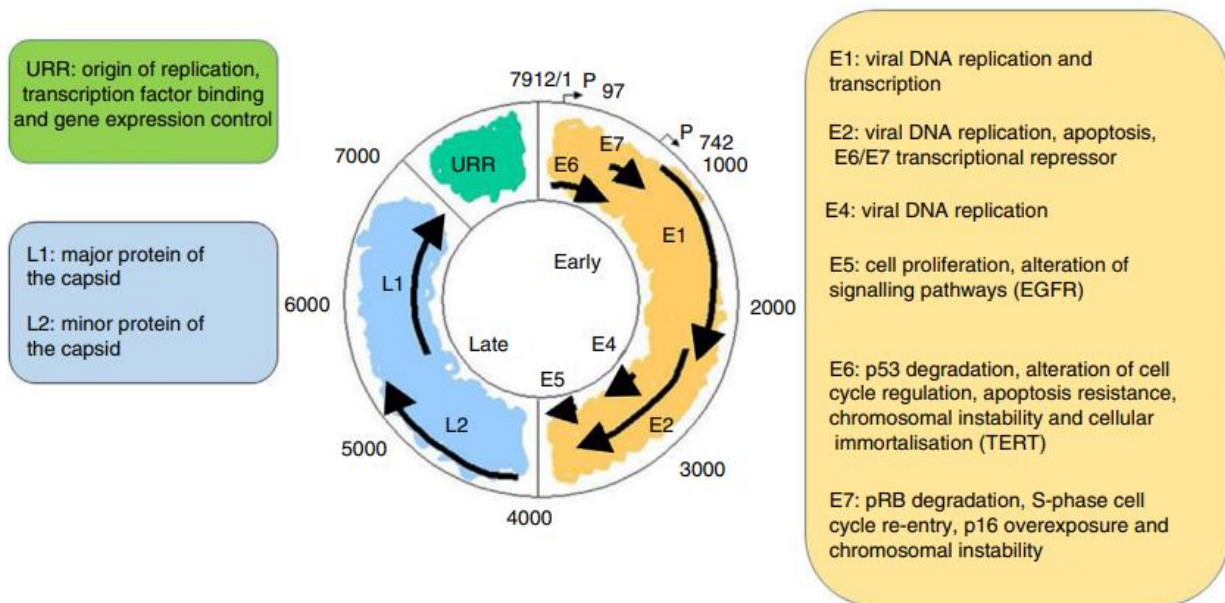


Abb :Upstream regulatory region (URR), Telomerase reverse transcriptase (TERT), Epidermal growth factor receptor(EGFR).

Figure (1) Structure and function of Human papillomavirus proteins (5).

Most mucosal HPV types such as HPV6 are also benign, but “high risk” or “oncogenic” genotypes are carcinogenic. While the majority of oncogenic HPV infections are self-limited and subject to immune clearance, persistent infections are associated with a dramatically increased risk for the development of cervical, anogenital and/or oropharyngeal cancers. HPV types 16 and 18 account for 50% and 20% of all cervical cancer cases respectively. Other high/intermediate risk types such as HPV 31, 33, 35, 39, 45, 51, 52, 56, 58, 59, and 68 constitute the remaining 30% HPV-associated malignancies and are associated with a slower onset of dysplasia (6).

<i>An Overview about Warts; Etiology, Pathogenesis and Presentation</i>	Often detectable	Rarely detectable <i>Section A*Research Paper</i>
Skin lesions		
Verrucae vulgares, verrucae palmares et plantares	1, 2, 4	26, 27, 29, 41, 57, 60, 63, 65
Verrucae planae	3, 10	28, 29
Butcher's warts	7	1, 2, 3, 4, 10, 28
Squamous cell carcinoma of the finger, Bowen's disease	16	31, 33–35, 52
Epidermodysplasia verruciformis (EV)	3, 5, 8	9, 12, 14, 15, 17, 19–25, 36–38, 46, 47, 49, 50, etc.
EV-squamous cell carcinomas	5, 8	14, 17, 20, 47
Mucosal lesions		
Condylomata acuminata	6, 11	40, 42–44, 54, 61, 70, 72, 81
High-grade squamous intraepithelial neoplasias and invasive carcinomas of the anogenital tract	16	18, 26*, 31, 33, 35, 39, 45, 51, 52, 53*, 56, 58, 59, 62, 66*, 68, 73, 82
Bowenoid papulosis, erythroplasia of Queyrat	16	
Buschke-Löwenstein tumor	6, 11	
Laryngeal papillomatosis	6, 11	
Heck's disease	13, 32	

Table (1): Clinical manifestations of warts (6).

* Potentially carcinogenic.

Life cycle of the virus

1) Entry of HPV into the basal cells of stratified epidermis

Human papillomavirus virions invade through damaged areas of the epithelium and infect the basal cells. Although the receptor for the HPV infection has not been fully characterized, the following model has been postulated; virions initially attach to the heparan sulfate proteoglycan (HSPG) on the basal membrane, and transfer to the receptor expressed on the keratinocytes moving on the basal membrane in the wound-healing process, then enter the cells (7).

2) Low-level expression of viral genes and genome maintenance in the basal layer

Following viral entry and uncoating, HPV genomic DNA is transported into the nucleus and maintained at a low-copy number in the basal cells (50 ~ 100 copies per cell; in the basal layer. Genome maintenance as episomal status is essential for the establishment of the early phase of the viral lifecycle (8).

3) Productive replication of HPV in the differentiated cells

After leaving the basal membrane, the infected cells initiate the differentiation program. Because HPV does not encode DNA polymerase activity for viral genome replication, the host DNA replication machinery

is required. However, the DNA replication activity is suppressed in the differentiated cells that exit from the cell division cycle. To ensure that the viral genome is replicated, HPV needs to reactivate cell division among the differentiation-initiated cells. E6 and E7 inactivate p53 and retinoblastoma protein (pRb), respectively, which enables the cells to maintain their DNA replication potential. In the upper layers of the stratified epithelium the expression of viral genes that are required for viral genome replication is markedly accelerated, inducing viral genome amplification to thousands of copies per cell. Following the genome amplification, in the terminally differentiated cells, the synthesis of capsid proteins is triggered. The capsid proteins assemble into virions that encapsidate viral genomic DNA. The progenitor virions are released externally with peeled keratinocytes (9).

Human Papillomavirus Evades Innate Immune Defenses

Central to this achievement of immune ignorance is the ability of HPV, particularly the high risk HPV types (HRHPVs), to compromise the role of keratinocytes as innate immune sentinels. Keratinocytes can respond to cell injury and cell stress and can sense pathogens, thus mediating immune responses. Eukaryotic cells express germ line encoded receptors of the innate immune system, pathogen recognition receptors (PRRs) that recognize invariant molecular motifs known as pathogen-associated molecular patterns (PAMPs). There are four groups of PRR: (1) Nucleotide-binding oligomerization domain-like receptors (NLRs), (2) C-type lectin receptors (CLRs), (3) Retinoic acid inducible gene 1 (RIG I)-like receptor family (RLRs), and (4) Toll-like receptors (TLRs) (9).

Humoral immunity

B-cells are responsible for humoral response, which neutralize and opsonize viral agents. Humoral immunity is stimulated by antigen presenting cells and Th2 cytokine pattern and depends on CD4 helper T cells that assist B cells to mature and produce antibodies against a specific epitope. The antibodies against HPV target mainly the L1 capsid protein although weak antibodies directing against E2, E6, E7, and L2. All TLRs except TLR3 signal via the MyD88 adaptor protein initiating a cascade of protein protein interactions, and the end result of which is the phosphorylation and activation of IRF7. TLR3 and TLR4 signals via TRIF, the cytosolic RNA sensors signal via MAVS, and the cytosolic DNA sensors via the adaptor protein STING, and the end result of which is the phosphorylation and activation of IRF3. Activated IRF3 and IRF7 homodimerise translocate to the nucleus inducing expression of type I interferons. The HRHPV early proteins, E6, E7, and E2 directly interact with components of these signaling cascades at multiple points, inhibiting signaling via PRR ligation (10).

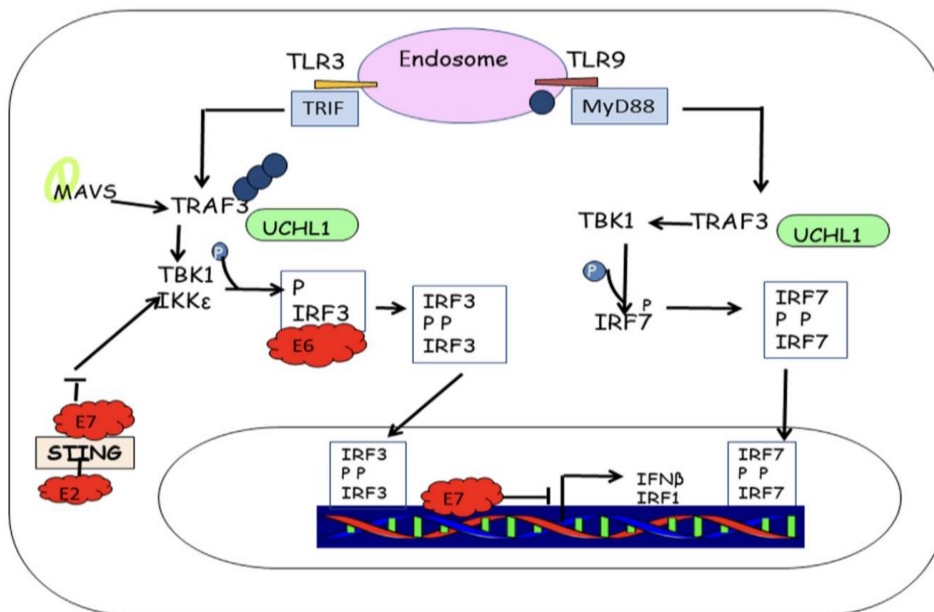


Figure (2) HPV early gene products block signaling from PRRS (10).

Immunity To Human Papillomavirus

HPVs have two central biological properties; they have a tightly restricted host range and exquisite tissue tropism productive virus growth is confined to the fully differentiating squamous epithelia of humans. HPVs are very successful infectious agents. The majority of the β, μ, and ν HPV species reside anonymously in their epidermal niches at very low copy number resulting in no overt disease until, and unless, host immunity is compromised, implying immune control in these scenarios. The α-HPVs, which include most of the types that cause clinical disease, induce chronic infections that have virtually no systemic sequelae, rarely kill the host and, over weeks and months, periodically shed large amounts of infectious virus for transmission to naive individuals (11).

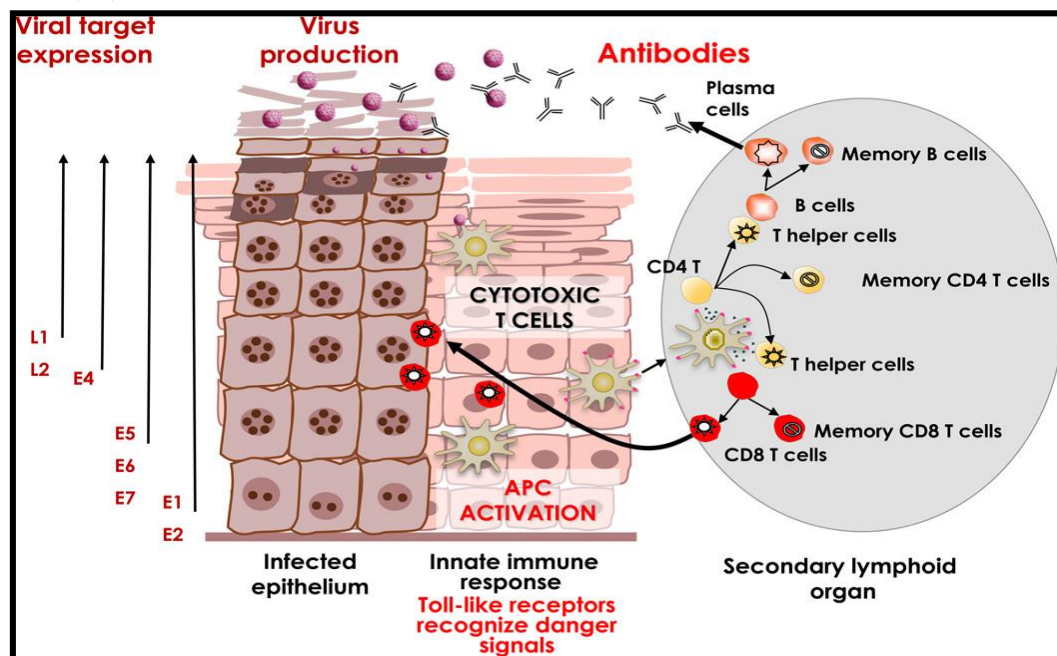


Figure (3) Natural immune control of HPV infection (12).

Diagnosis of common warts

Clinical presentation

Clinical features present in various forms depending on the type of HPV, the affected site, and the immune status of the host.

A- Cutaneous manifestations of HPV:

Type of HPV, anatomic location of the infection and importantly the immune status of the host are the three main determinants of clinical presentation of HPV infection. Cutaneous warts can be distinguished as common (*verrucae vulgares*), flat (*verrucae plana*), filiform, periungual, palmar and plantar warts (*verrucae palmares et plantares*). However, they are usually generally classified as common and plantar warts (13).

1- Common warts (*verruca vulgares*) appear in various sizes as firm, hyperkeratotic, rough papules that can form large masses by confluence. They are due mainly to HPV2. They may occur anywhere on the skin but preferably on dorsum of hands and fingers and around or beneath the nails (periungual warts). Children under 12 years of age are frequently affected. Common warts are usually asymptomatic but may be tender. Malignant transformation is extremely rare but has been reported in immunosuppressed hosts (14).

2-Plantar warts (*verruce plantaries*) are caused by HPV 1, 2, 4, 27, and 57. They first appear as small, grainy papules and soon evolve into a well-defined, rounded lesion with keratotic surface. Most of the plantar warts develop under pressure points such as the heel or the heads of the metatarsal bones. Mosaic warts are formed by the confluence of closely grouped small-size warts. The epithelial ridges of the plantar skin are not continued over the wart surface and that differs from corns (1).

3- Periungual warts: Periungual warts are typical warts that grow under the nail plate, around the nail fold, and occasionally next to the nail matrix. A potential side effect of ablative therapy on the proximal nail fold is onychodystrophy (15).

Butcher's warts are a particular kind of periungual warts that only affect those who handle animal products and are brought on by HPV-2 and -7. Ungual warts begin as rough, skin-colored papules that can develop into bigger plaques (16).

4-Plane warts (flat warts) are due mainly to HPV 3 and 10. They are small, 1–5 mm in diameter, round or polygonal, smooth, and flat papules. They can be skin colored or pigmented. The face, dorsum of hands, and shins are sites of predilection. Linear arrangement of contiguous warts is a characteristic sign. Regression is possible and usually associated with inflammation (pruritus, erythema, edema, depigmented halo around the wart). Resolution is completed within a month (17).

5-Filiform and digitate warts occur mainly in males. They appear on the face, nostrils, and neck. They can be clustered or irregularly distributed (11).

6-Epidermodysplasia Verruciformis

Usually starting in childhood, epidermodysplasia verruciformis (EV) can also develop in adults. On the dorsum of the hands, limbs, face, and neck, it appears as flat wart-like papules that coalesce to create patches and plaques. The forehead, neck, and trunk are the most common sites for verrucous and seborrheic keratosis-like lesions to develop (18).

B- Mucosal and mucocutaneous manifestation of HPV:

1-Condylomata accuminata (CA)

Anogenital HPV infections are the most common sexually-transmitted viral disease. Subclinical infections are much more common than visible warts. Condylomas can occur on the external or internal genitalia, perianally, in the anal canal (rarely beyond the dentate line), the perineum, on the mons pubis and inguinal fold. Clinical appearances often include multiple, flat or raised exophytic papillomas. Lesions may

be flesh-colored, or brown, or white and macerated (in moist regions); the keratinized surface of skin warts is absent (19).

2-Giant condyloma acuminatum (Buschke-Löwenstein tumor)

An aggressive tumour that rarely spreads outside the anogenital region is called verrucous carcinoma. Clinically, it resembles a cauliflower-like exophytic ulcerated tumour that infiltrates deeply and develops fistulas and abscesses. It is brought on by the LR HPV kinds 6 and 11, which are responsible for condylomas, but there has never been a clear explanation for why these two HPV types behave differently biologically (20).

3-Bowenoid papulosis (BP)

HPV 16 infection of the perineum and external genitalia causes bowenoid papulosis, which presents as reddish-brown papules to confluent plaques. Young, sexually active adults are typically affected. They exhibit the characteristic of resembling warts clinically but Bowen's disease (SCC in situ) histologically (21).

- Focal Epithelial Hyperplasia (Heck's disease)

A benign condition called focal epithelial hyperplasia is brought on by HPV 13 and 32. It presents as several, distinct lesions that are confined, sessile, and rounded in appearance. The tongue, buccal mucosa, and gingiva are the most frequently affected tissues (22).

4-Infection of the oral cavity

Oral warts are small soft pinkish papules. They appear on the buccal, labial, gingival or palatal mucosae. HPV6 and 11 are the usual causative genotypes. Unusually, HPV types 7, 71, 72 and 73 were found to be associated with them in AIDS patients (23).

5-Recurrent respiratory papillomatosis (RRP):

RRP is generally a benign and self-limited disease, caused by HPV and characterized by the appearance of papillomatous lesions anywhere in the aero-digestive tract (24).

Dermatoscopy of the common warts

The main dermatoscopic pattern suggestive of common warts is the presence of irregular whitish structures (mosaic pattern), typically associated with irregularly distributed, hemorrhagic reddish to black dots. In exophytic lesions, multiple papillomatous projections (finger-like) containing elongated and dilated vessels that are surrounded by whitish halos may be observed (25).

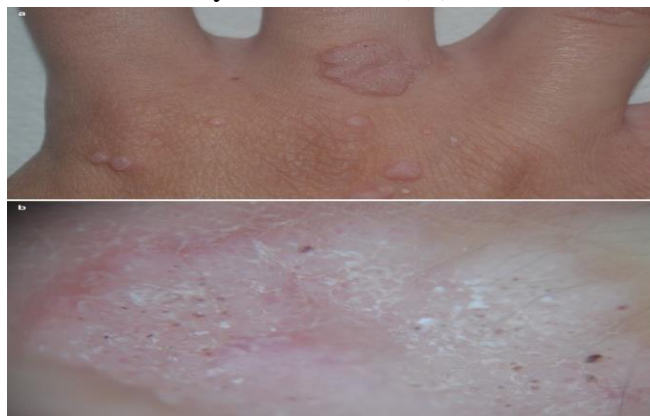

Figure (4) clinical and dermoscopic appearance of common warts (a) Clinical multiple cutaneous warts. Multiple hyperkeratotic papules, black dots and plaques on the right hand in a 9-year-old boy. (b) Dermoscopy (×10): rounded structures resembling a puzzle (*mosaic pattern*), associated with irregularly distributed, hemorrhagic reddish dots. Linear, hairpin, and coiled vessels can be found. Lesions may also reveal a daisy flower pattern consisting of radial petal-like keratotic projections with a central mass of keratin. Palmoplantar warts are characterized by the presence of verrucous, yellowish structureless areas with

multiple irregularly distributed red to brown to black dots or linear streaks due to hemorrhages. These dots are helpful criteria to distinguish plantar warts from calluses, which lack blood spots and show a translucent central core or a homogeneous opacity (26).

Skin lines are typically interrupted in plantar warts. Flat warts reveal regularly distributed, tiny red dots on a light brown to yellow background. These features are helpful to distinguish them from acne comedones, which typically reveal a central white to yellow pore corresponding to the hair follicle opening, and from verruca plana-like seborrheic keratosis which shows a brain-like appearance (27).

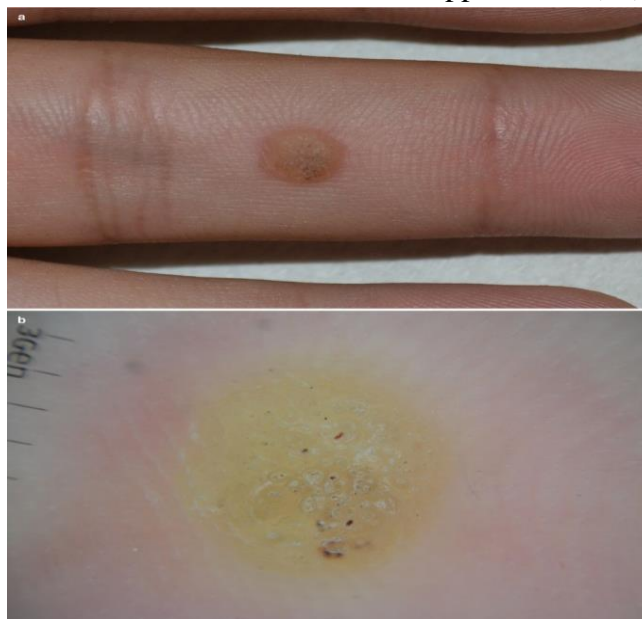


Figure (5) clinical and dermoscopic appearance of common warts (a) Palmar wart on the flexor surface of the finger. (b) Dermoscopy ($\times 10$): brownish dots and interrupted skin lines (28).

Histopathology

Histopathologically, the variable amount of acanthosis, papillomatosis, and hyperkeratosis correlates to the various dermoscopic patterns seen in cutaneous warts. The presence of elongated and tortuous vessels as well as hemorrhages/extravasation of erythrocytes corresponds to the dotted, linear, hairpin, and coiled vessels and reddish/black dots seen at dermoscopy, respectively (28).

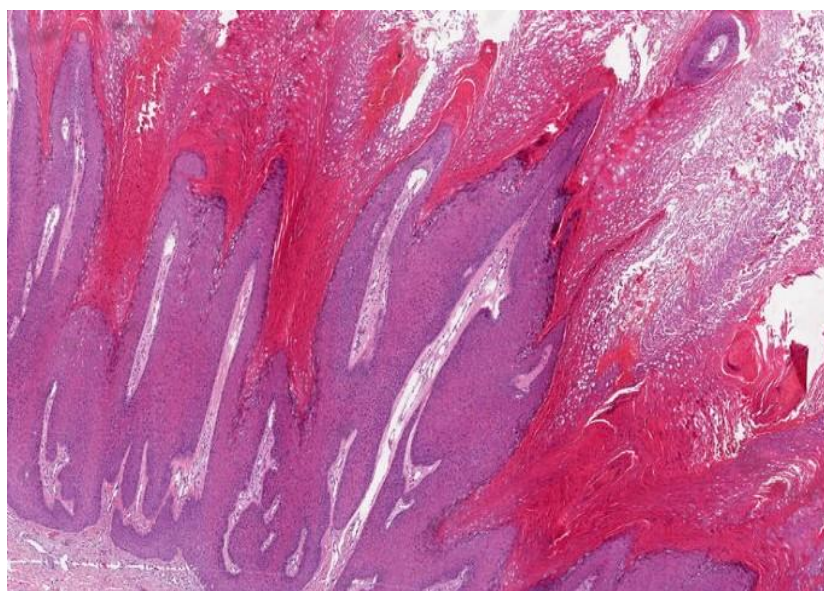


Figure (6): Histopathology of Cutaneous wart: hyperkeratosis, acanthosis, and papillomatosis with elongated vessels [H&E staining; magnification: ×100] (28).

Common warts shows koilocytes with pyknotic nuclei as a hallmark. The nucleus is surrounded by a clear halo and tiers of parakeratosis could be present. In addition, foci of keratohyalin granules are clumped (29).

Deep palmoplantar warts have a histological appearance analogous to that of verruca vulgaris, but they are characterized by endophytic epidermal proliferation with a central parakeratotic plug surrounded by multiple deep extension of acanthotic epidermis, foci of vacuolated cells. Increased density of keratohyalin granules, dilated capillaries present within the center of the wart, and a variable degree of lymphocytic infiltrate are observed. In filiform warts, the papillae are more elongated than in verrucae vulgaris. They contain dilated capillaries, and small areas of hemorrhage in the thickened horny layer at the tip of filiform wart (30).

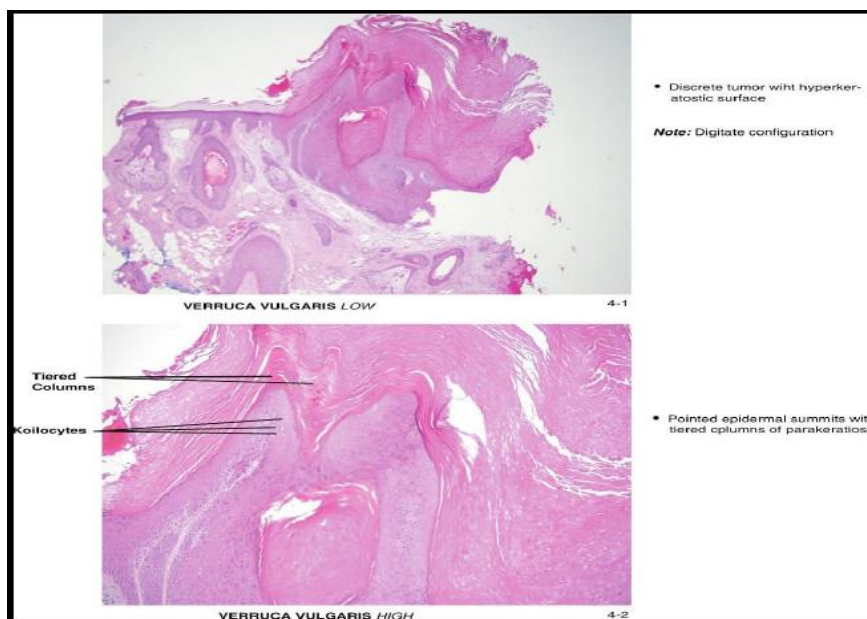


Figure (7) Histopathological picture of verruca vulgaris; (1) low magnification (2) high magnification (31).

Differential Diagnosis:

Common warts should be differentiated from seborrheic keratosis and lichen planus. Plantar warts may be confused é callus and Subungual keratoacanthoma. Plane warts should be differentiated from Molluscum contagiosum. An irritated achrochordon may resemble a wart. The extremities may demonstrate acrokeratosis verruciformis or epidermodysplasia verruciformis in the form of verrucous papules. Syphilitic condylomata must also be kept in mind in the differential diagnosis of anogenital warts (32)

Differential Diagnosis of warts (32) (Table 2):

Wart type	Differential Diagnosis	differentiating features
Common warts	Seborrheic keratosis	No hemorrhage; dermoscopy typically shows comedo_ like pseudohorn cysts .

	Lichen planus	Polygonal appearance without capillary hemorrhage both clinically and Wickham striae on dermoscopy
Plantar warts	Callus	Absence of capillary hemorrhage both clinically and on dermoscopy
	Subungual keratoacanthoma	Absence of capillary hemorrhage bleeding both clinically and on dermoscopy
Plane warts	Molluscum contagiosum	Frequently shows central indentation, umbilicated on dermoscopy
genital warts (condyloma acuminata)	Condyloma lata	Due to secondary syphilis, an infection caused by <i>Treponema pallidum</i> , and can be diagnosed with dark-field microscopy and standard serological tests for syphilis
	Molluscum contagiosum	Caused by a poxvirus, highly infectious, and common in immunodeficiency; lesions are usually umbilicated
	Pearly penile papules	Are angiofibromas that occur at the penile corona and are normal variants that require no treatment except reassurance
	Vulvar papillomatosis introitus	A normal variant in women characterized by smooth papillary projections, each arising from an individual base, near the proximal to the vaginal

References

1. Kanelleas Antonios & Nicolaidou Electra (2023) :Warts: Cutaneous and Anogenital. In European Handbook of Dermatological Treatments (pp. 1113-1121). Cham: Springer International Publishing.
2. DeVilliers EM (2013): Cross-roads in the classification of papillomaviruses. *Virology*. 445: 2-10.
3. Piaserico S, Sandini E, Pescerico A, et al. (2014).Cutaneous viral infections in organ transplant patients. *G Ital Dermatol Venereol* 2014; 149: 409–15.
4. Witchey DJ, Witchey NB, Roth-Kauffman MM, et al. (2018). Plantar Warts: Epidemiology, Pathophysiology, and Clinical Management. *The Journal of the American Osteopathic Association*, 118(2), 92–105.
5. Sendagorta-Cudós E, Burgos-Cibrián J, Rodríguez-Iglesias M (2019): Genital infections due to the human papillomavirus. *Enferm Infecc Microbiol Clin (Engl Ed)*.37(5):324-334. English, Spanish.
6. Handisurya Alessandra, Christina Schellenbacher, and Reinhard Kirnbauer(2009): Diseases caused by human papillomaviruses (HPV). *JDDG: Journal der Deutschen Dermatologischen Gesellschaft*; 7.5: 453-466.
7. Kines RC, Thompson CD, Lowy DR, et al. (2009): The initial steps leading to papillomavirus infection occur on the basement membrane prior to cell surface binding. *Proceedings of the National Academy of Sciences* 106.48: 20458-20463.
8. McBride A A, Oliveira JG & McPhillips MG. (2006). Partitioning viral genomes in mitosis: same idea, different targets. *Cell*

- cycle (Georgetown, Tex.), 5(14), 1499–1502.
9. Spurgeon, Megan E, and Paul F Lambert (2017): Human papillomavirus and the stroma: bidirectional crosstalk during the virus life cycle and carcinogenesis. *Viruses* 9.8 :219.
 10. Stanley Margaret (2020): Immune responses to human papillomavirus and the development of human papillomavirus vaccines. *Human Papillomavirus*. Academic Press, 283-297.
 11. Ankad BS, Koti VR, Nikam BP, et al. (2021): Plantar papules and plaques: a dermoscopic-histopathological correlation." *Journal of Skin and Stem Cell* 8.1.
 12. Stern PL, Van der burg SH, Hampson LN, et al. (2012): Therapy of Human papilloma virus –Related diseases. *Vaccine*; 30:f71-f82.
 13. Jablonska S, Orth G(1985): Epidermodysplasia verruciformis. *Clin Dermatol*;3(4):83-96
 14. Féliz-Sánchez M, Trösemeyer J, Bedhomme S, et al. (2015): Cancer, Warts, or Asymptomatic Infections: Clinical Presentation Matches Codon Usage Preferences in Human Papillomaviruses. *Genome Biol. Evol.*, 7(8), 2117-2135.
 15. Veitch, David, Georgios Kravvas, and Firas Al-Niaimi(2017): Pulsed dye laser therapy in the treatment of warts: a review of the literature. *Dermatologic Surgery* 43.4 :485-493.
 16. Herschthal J, McLeod MP, Zaiac M(2012): Management of ungual warts. *Dermatol Ther*;25(6):545-50.
 17. Cekala K, Debska-Slizien A, & Imko-Walczuk B. (2022): Viral Diseases. In *Atlas of Dermatologic Diseases in Solid Organ Transplant Recipients* (pp. 71-99). Cham: Springer International Publishing.
 18. Sri JC, Dubina MI, Kao GF, et al. (2012): Generalized Verrucosis: A Review of the associated diseases, evaluation, and treatments. *J Am Acad Dermatol*; 66: 292- 311.
 19. Doorbar J, Egawa N, Griffin H, et al. (2015): Human papillomavirus molecular biology and disease association. *Rev Med Virol*; 25 (Suppl.1):2-23.
 20. Da Silva Alcantara G, Morais Brilhante A, Nunes de Melo D et al. (2017): Buschke-Lowenstein Tumor. *Int. Arch. Med.*, 88(4), 10-17.
 21. Shimizu A, Kato M and Ishikawa O (2014): Bowenoid papulosis successfully treated with imiquimod 5% cream. *The Journal of Dermatology*, 41(6), 545-546.
 22. Harris Ricardo J, Carmona Lorduy M, & Díaz Caballero A (2012): Treatment of focal epithelial hyperplasia with trichloroacetic acid. *Revista clínica de periodoncia, Rev. clín. periodoncia implantol. rehabil. oral*, 5(3), 139-141.
 23. Shiboski CH, Lee A, Chen H, et al. (2016): Human papillomavirus infection in the oral cavity of HIV patients is not reduced by initiating antiretroviral therapy. *AIDS (London, England)*, 30(10), 1573.
 24. Fortes HR, von Ranke FM, Escuissato DL, et al., (2017): Recurrent respiratory papillomatosis: A state-of-the-art review. *Respir. Med.*, 126, 116–121.
 25. Silverberg JI, Silverberg NB (2013): The U.S. prevalence of common warts in childhood: a population-based study. *J Invest Dermatol*,133(12):2788-2790.
 26. Al Rudaisat M & Cheng H (2021): Dermoscopy Features of Cutaneous Warts. *International journal of general medicine*, 14, 9903–9912.
 27. Penso-Assathiany D, Gheit T, Pretet JL, et al. (2013): Presence and persistence of human papillomavirus types 1, 2, 3, 4, 27, and 57 on dermoscope before and after examination of plantar warts and after cleaning. *J Am Acad Dermatol.*;68(1):185–186.
 28. Lacarrubba F, Ardigò M, Di Stefani A, et al. (2018): Cutaneous and anogenital warts." *Atlas of Pediatric Dermatoscopy*; 35-44.
 29. Araújo MG, Magalhães GM, Garcia LC, et al. (2021): Update on human papillomavirus-Part II: complementary diagnosis, treatment and prophylaxis. *Anais Brasileiros de Dermatologia* 96 :125-138.
 30. Lipke, Michelle M. (2006): An armamentarium of wart treatments. *Clinical medicine & research* 4.4 :273-293.
 31. Morgan, M.B. (2018). Benign Epidermal Tumors. In: Morgan, M., Spencer, J., Hamill, Jr., J., Thornhill, R. (eds) *Atlas of Mohs and Frozen Section Cutaneous Pathology*
 32. Bae JM, Kang H, Kim PO, Park YM (2009): Differential diagnosis of plantar wart from corn, callus and healed wart with the aid of dermatoscopy. *Br J Dermatol*,160: 220–222.