



Type III Tibial Tubercle Fracture in Adolescents Salter-Harris Type II: Case Report

Mohammad A. Almatrafi*, Abdulaziz A. Abdulaziz

Department of Orthopaedic Surgery, Alnoor Specialist Hospital, Ministry of Health, Makkah, KSA

*Corresponding author: Mohammad Ali Almatrafi, E-Mail: m.a.almatrafi@windowslive.com

DOI: 10.48047/ecb/2023.12.5.239

Article History: Received: 05.03.2023

Revised: 07.04.2023

Accepted: 27.04.2023

ABSTRACT

Tibial tubercle fractures are uncommon fracture patterns, commonly seen in adolescents who are growing toward skeletal maturity and typically affect young males engaged in various sports. Odgen classification describes 5 types of tibial tubercle fractures. Type III is the most common. appropriate management can be guided based on the level of fracture and the presence of fragment displacement. Commonly open reduction with internal fixation by one or two screw parallel to the joint are showing satisfactory outcomes. This report highlights a 13-year-old male patient who had a history of fall down and was diagnosed with tibial tubercle fracture Ogden type III & Salter-Harris type II. He underwent Open reduction with internal fixation by one-third semi-tubular plate and screws. Patient clinical and radiographical status after 3 months follow up showed healed fracture without hardware complications and good function with no limitation in ambulation or joint range of motion. The technique used in this case appeared to be safe with an excellent functional result and has a similar outcome compared to fixation by screws.

Keywords: Tibial tubercle fracture, Adolescents, Case report.

INTRODUCTION

Tibial tubercle avulsion fractures are a rare occurrence, with a frequency of one case every four years in busy emergency centers [1]. They account for less than 1% of all physeal injuries and 3% of proximal tibial fractures [2]. The incidence of Tibial tubercle avulsion fracture is 0.25–2.7 cases yearly [3]. These fractures are most commonly seen in adolescents who are growing toward skeletal maturity and typically affect young males engaged in various sports. The highest incidence occurs in the 14 to 17 year old age group, with males being more commonly affected due to their greater participation in sports and later fusion of the physis [4].

The fracture is often associated with jumping activities in sports such as basketball [5,6,7,8]. The mechanism of injury is caused

by a combination of traction force originating from quadriceps contraction with the knee in an extension position while jumping and the passive flexion contradicting the quadriceps contraction when landing [9]. The pathophysiology behind these fractures is linked to the pattern of ossification centers in the knee joint. The proximal tibia has two ossification centers, the first site at the proximal tibial physis and the second site at the tibial tubercle or apophysis. Physeal closing progresses from posterior to anterior and proximal to distal parts of the knee.

The tibial tubercle is the last part to be closed. Particularly, where most growth plates mature under compressive dynamism, the growth plate of the tibial tuberosity closes under extensive loads [10].

The ossification center at the tibial tuberosity is associated with the metaphysis through

fibrocartilage, which is progressively substituted by columnar cartilage during the process of maturation of the skeleton [11]. The newly formed cartilage is characterized by weakness; thus it is where injury occurs in TTAFS. TTAFS often occur during sports after unexpected contraction of the quadriceps, which pulls the tibial tuberosity underside the patellar tendon. Contraction of the quadriceps sometimes can be indirect, due to eccentric contractions that oppose knee flexion while landing, or by a direct mechanism of concentric quadricep contraction to generate forceful knee extension while jumping [5]. Males have a higher risk because they have superior quadriceps strength than females [6].

CASE DESCRIPTION

A 13-year-old male slipped while playing football at the school and fall on the ground. He developed severe pain in his right knee. The patient was stable on presentation with an intact neurovascular exam in the emergency

department, he had moderate compressible swelling on the right knee with tenderness all over the tibial tubercle. He was unable to ambulate with limitation of movement of the knee joint due to pain.

Two plain x-rays were done before orthopedic consultation showed a displaced tibial tubercle fracture (Figure 1). CT was ordered to assess the personality of the fracture and the geometry which showed a transverse tibial tubercle fracture line with widening prominent anteriorly and laterally with an oblique extension below the physis to the medial side. No intra-articular extension (Figure 2). Categorized as Ogden type III, Salter-Harris type II.

The plan was discussed with the family for admission and the need for closed versus open reduction with internal fixation after the swelling resolved. A posterior splint was applied temporarily, and leg elevation and ice packs application was done for him during hospitalization.

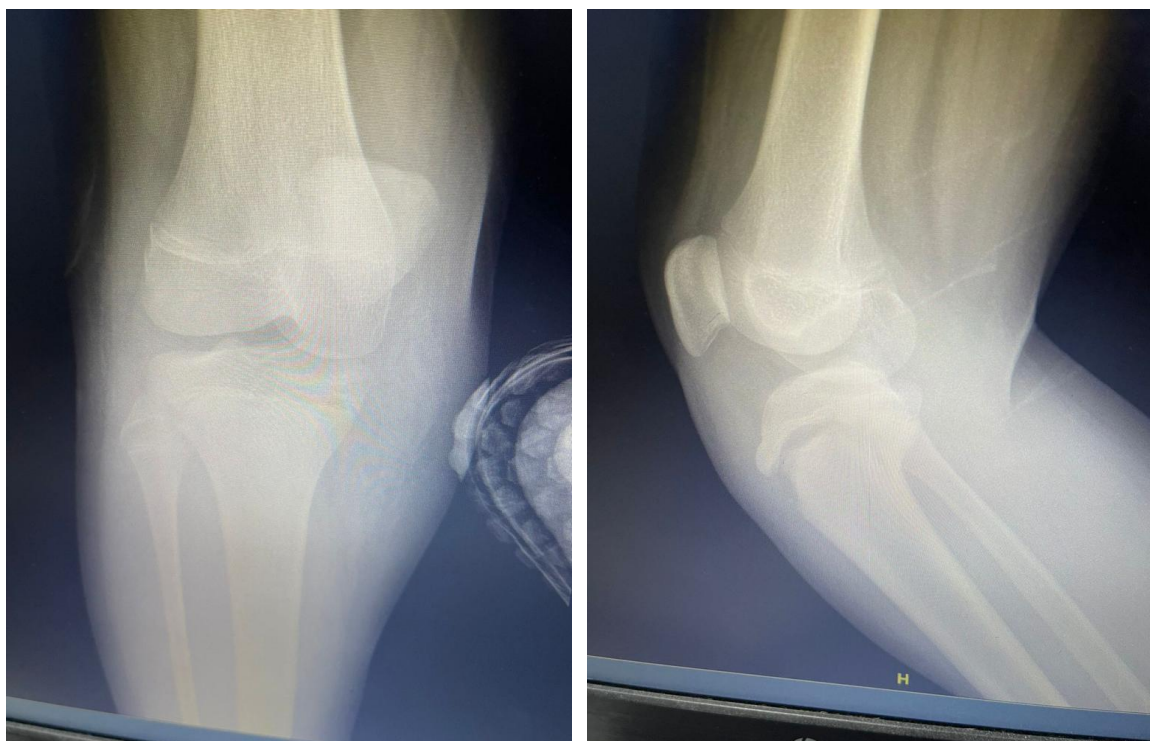


Figure (1): AP and lateral view demonstrating tibial tubercle fracture salter Harris type 2.

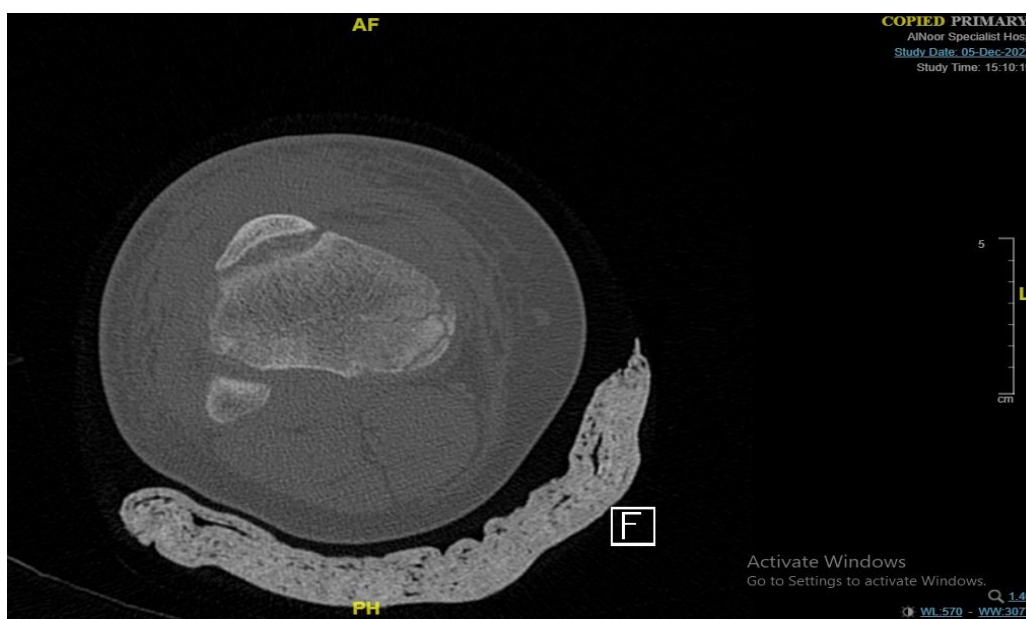
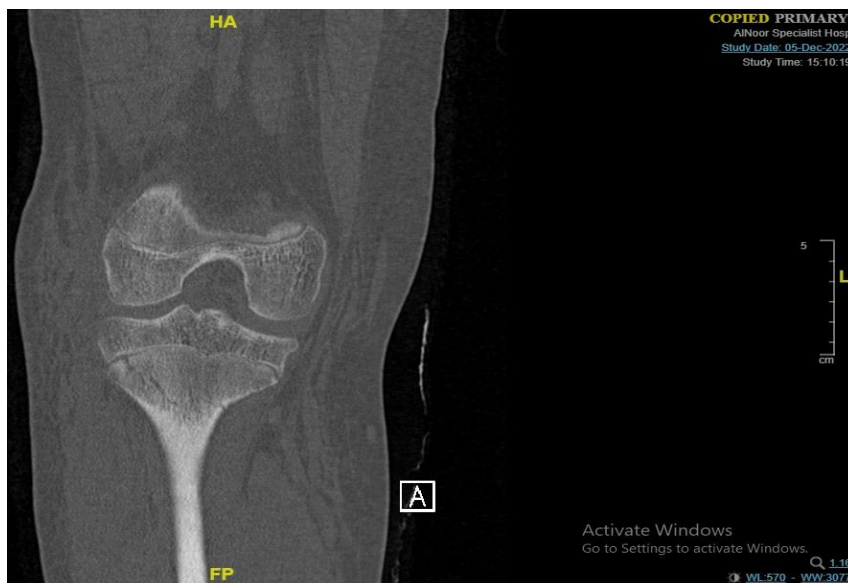
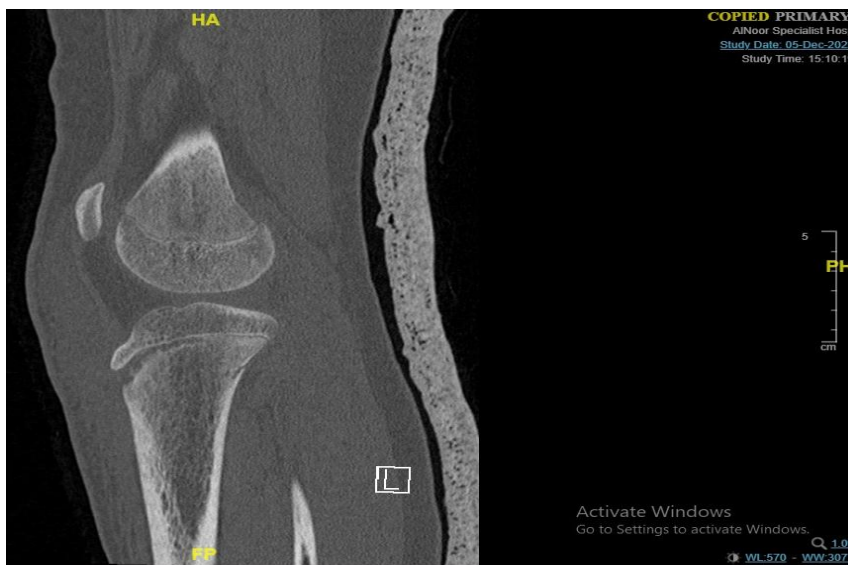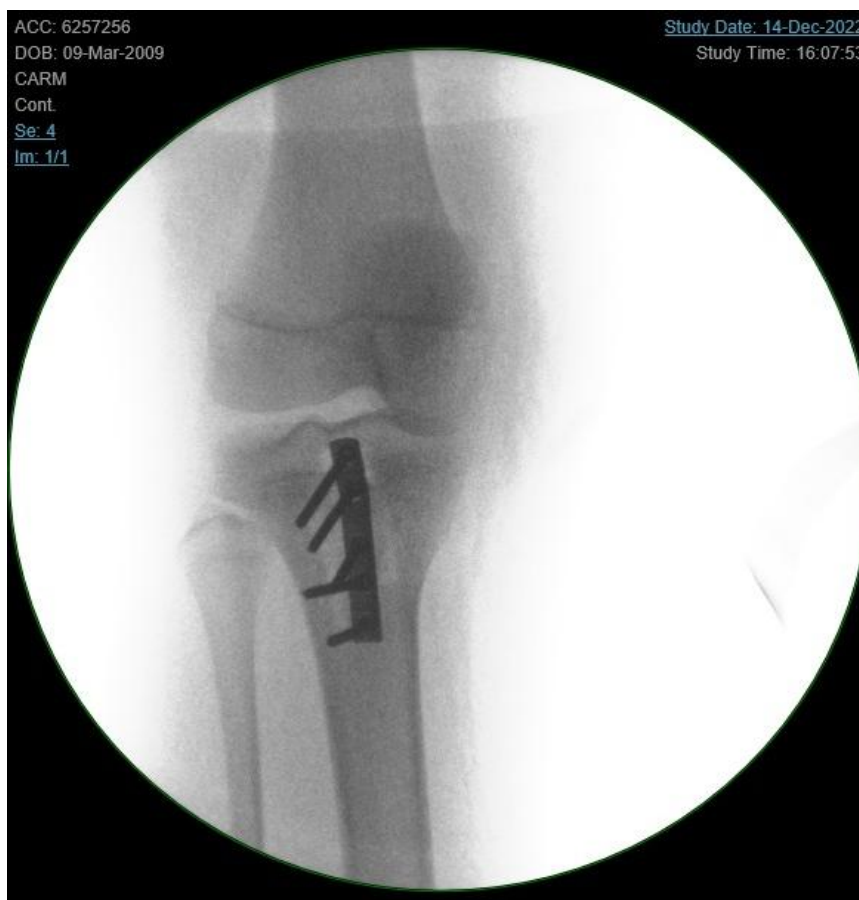Figure (2): CT scan reveal transverse tibial fracture line with widening prominent anteriorly and laterally with oblique extension. No intra-articular extension.

OPERATION

Fractures classified as Ogden types II-V usually require surgical treatment [11,12]. Almost 88% of TTAF cases require surgery [13]. ORIF with compression screws or closed reduction and percutaneous pinning are common surgical options. The ORIF procedure typically involves a midline incision in the knee for better access to the fracture site.[14]. To achieve anatomical reduction, direct inspection and debridement of the fracture site and the removal of interpositional soft tissue are crucial. Ideal compression during internal fixation is recommended using cancellous partially threaded 4.0 screws, which must be positioned parallel to the joint surface, avoiding the growth plate and residual attached to the posterior cortex. Another surgical technique that uses cannulated screws to fix the intra-articular fragment with one or two screws reliant on the size of the fragment.

The fragment between the physis and metaphysis should be fixed, inserting screws across the tubercle physis but not through the proximal tibial physis [15]. They stressed that avoiding implant prominence was a keyway to moderate the risk of hardware removal. The ultimate goal of the open reduction procedure is to achieve the anatomic reconstruction of the joint surface and stabilize the fixation. Some authors prefer to use a tension band. [6,4,9,16,17].

In our case we did mid-line longitudinal incision and medial parapatellar approach for the right knee, Trial of fixation was done by a partial threaded cancellous screw with a washer but the fracture wasn't stable while flexion of the knee due to the comminution and the type of the fracture so open reduction with internal fixation by 1/3 semi-tubular plate with 5 cortical full threaded screws (Figure 3).



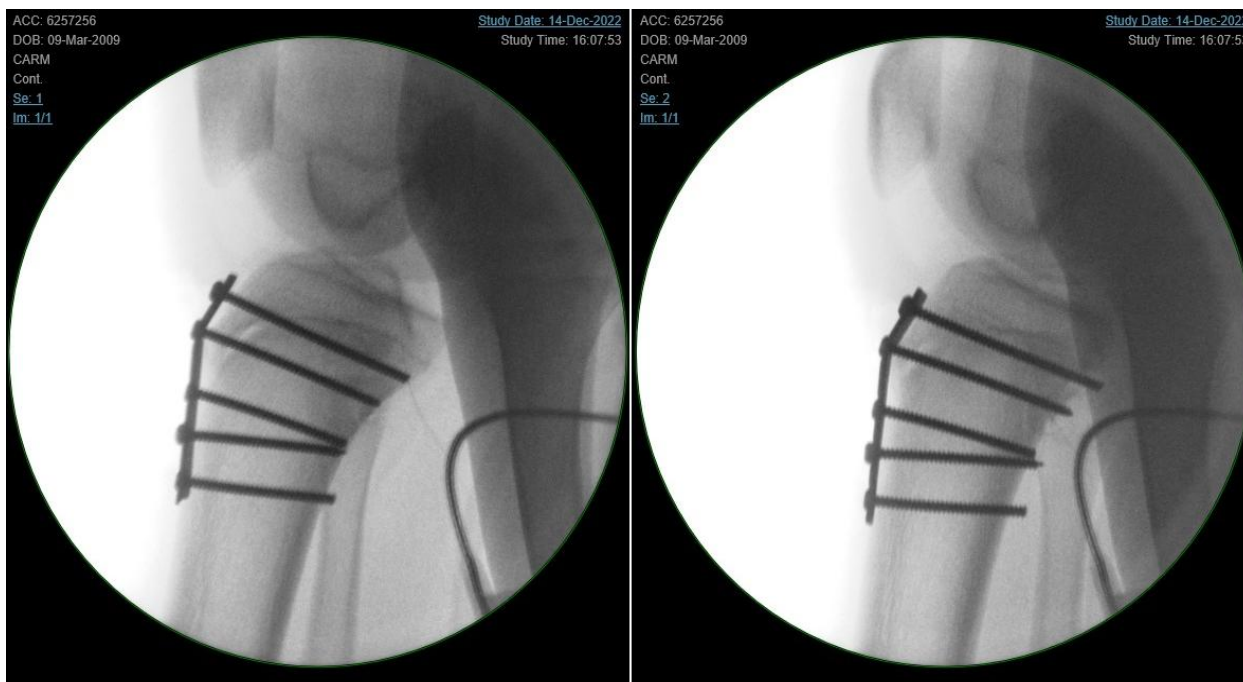


Figure (3): AP and lateral intraoperative images after ORIF by plate and screws.

FOLLOW UP

At 3 weeks and 3 months follow-up visit after discharge, the Patient was improved with no pain, healed wound, and full active and passive range of motion of the knee (Figure 4, 5).

So the outcome from our patient showed that fixation with screws and plate is safe with an excellent functional result and has a similar outcome compared to fixation by screws.

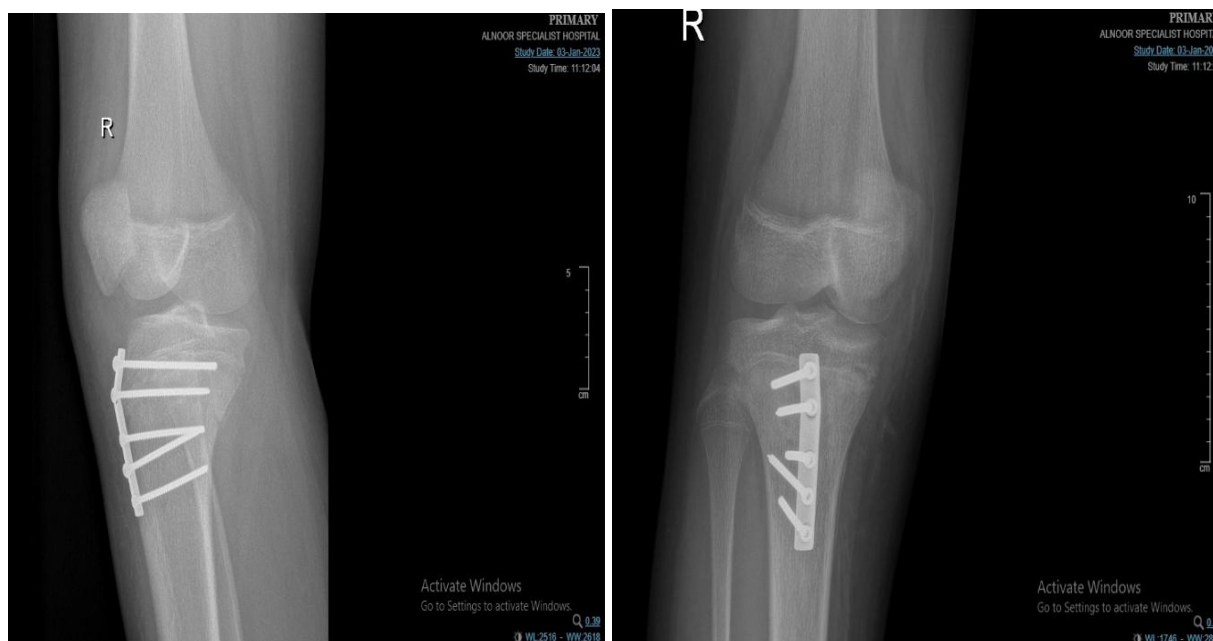

Figure (4): AP and lateral view at 3 weeks follow up visit.

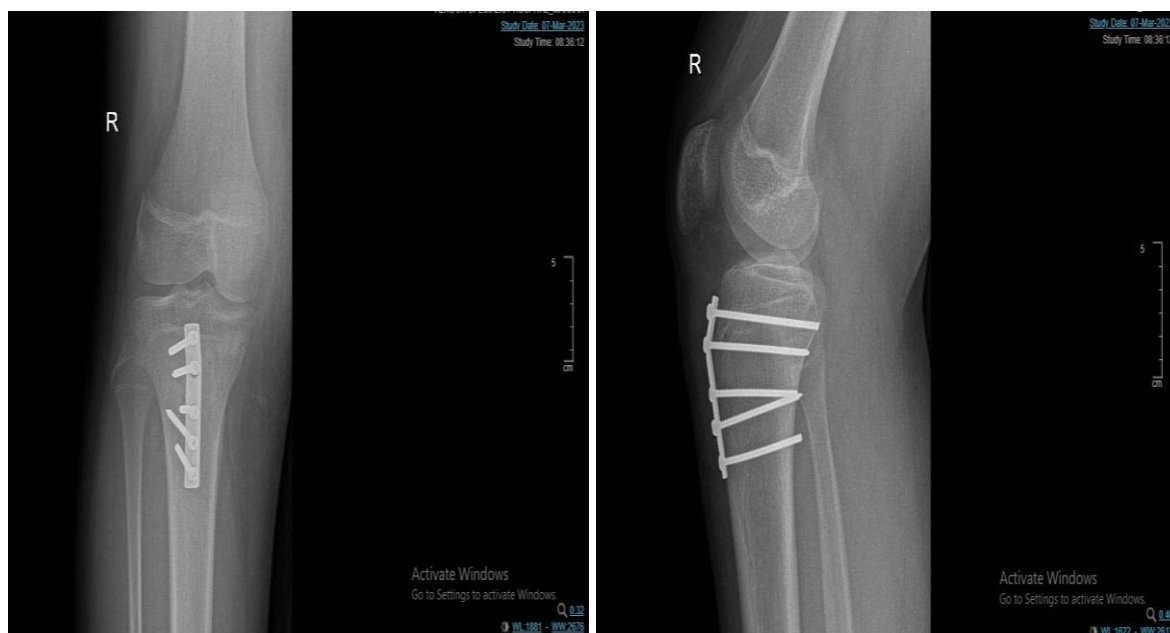

Figure (5): AP and lateral view at 3 months follow up visit.

REFERENCES

- Shelton WR, Canale ST. Fractures of the tibia through the proximal tibial epiphyseal cartilage. *J Bone Joint Surg* 1979; 61-A : 167-173.
- Hand W, Hand C, Dunn A. Avulsion fractures of the tibial tubercle. *J Bone Joint Surg Am* 1971; 53:1579–1583.
- Hamilton S, Gibson P. Simultaneous bilateral avulsion fractures of the tibial tuberosity in adolescence: a case report and review of over 50 years of literature. *Knee* 2006; 13:404–407.
- Chow SP, Lam JJ, Leong JC. Fracture of the tibial tubercle in the adolescent. *J Bone Joint Surg* 1990; 72 : 231-234.
- Ares-Rodriguez O, Seijas R, Nu ez-Pereira S, Aguirre- Canyadell M. type iii fractures of the anterior tibial tuberosity in adolescents : two case reports. *Europ J Orthop Surg Trauma* 2008; 18 : 399-403.
- Bolesta MJ, Fitch RD. tibial tubercle avulsions. *J Pediatr Orthop* 1986; 6 : 186-192.
- Yoo JH, Hahn SH, Yang BK et al. An en bloc avulsion fracture of tibial tuberosity and Gerdy's tubercle in an adolescent basketball player : a case report. *Knee Surg Sports Traumatol Arthrosc* 2007 ; 15 : 781-785.
- Zrig M, Annabi H, Ammari T et al. Acute tibial tubercle avulsion fractures in the sporting adolescent. *Arch Orthop Trauma Surg* 2008 ; 128 : 1437-1442.
- McKoy BE, Stanitski CL. Acute tibial tubercle avulsion fractures. *Orthop Clin North Am* 2003 ; 34 ; 397-403.
- Ogden J, Southwick W. Osgood-Schlatter's disease and tibial tuberosity development. *Clin Orthop Relat Res* 1976; 116:180–189.
- Polakoff D, Bucholz R, Ogden J. Tension band wiring of displaced tibial tuberosity fractures in adolescents. *Clin Orthop Relat Res* 1986; 209:161–165.
- Zrig M, Annabi H, Ammari T, et al. Acute tibial tubercle avulsion fractures in the sporting adolescent. *Arch Orthop Trauma Surg* 2008; 128:1437–1442.
- Schiller J, DeFroda S, Blood T. Lower extremity avulsion fractures in the pediatric and adolescent athlete. *J Am Acad Orthop Surg* 2017; 25:251–259.
- Pretell-Mazzini J, Kelly D, Sawyer J, et al. Outcomes and complications of tibial tubercle fractures in pediatric patients: a systematic review of the literature. *J Pediatr Orthop* 2016; 36:440–446.
- Ares O, Seijas R, Cugat R, et al. Treatment of fractures of the tibial tuberosity n adolescent soccer players. *Acta Orthop Belg* 2011; 77:78–82.
- Henard DC, Bobo RT. Avulsion fractures of the tibial tubercle in adolescents. A report of bilateral fractures and a review of the literature. *Clin Orthop Relat Res* 1983 ; 177 : 182-187.
- Lubojacky J. tibial tubercle avulsion fracture – an original method of fragment fixation by K-wires. *Acta Chir Orthop Traumatol Cech* 2006 ; 73 : 403-404.