



## Common Bile Duct Stenting in Management of Choledocholithiasis

Amr Talaat EL Hawary, Ahmad Ismail Ahmad Hassan, Osama.M.NA.Saidoun,  
Tarek.M.H.Ibrahim

Internal Medicine Department, Faculty of Medicine, Zagazig University

\*Corresponding author: Osama.M.NA.Saidoun

**Email:** osamoa.saidun@gmail.com **Mobile:** 00218922192416-00201555894418

---

**Article History: Received:** 10.06.2023

**Revised:**02.07.2023

**Accepted:** 15.07.2023

---

### Abstract:

Endoscopic retrograde cholangiopancreatography (ERCP) is the treatment of choice for the management of choledocholithiasis. Biliary stenting facilitates repeated attempts at stone extraction.

**Keywords:** Common Bile Duct, Stenting, Choledocholithiasis.

**DOI:** 10.53555/ecb/2023.12.1135

### Introduction:

Causes of benign obstructive jaundice include acute and chronic pancreatitis, choledocholithiasis, primary sclerosing cholangitis, AIDS cholangiopathy, strictures after invasive procedures, certain parasitic infections as in *Ascaris lumbricoides*, *Clonorchis sinensis* (Chinese liver fluke), *Fasciola hepatica* and other liver flukes. Causes of malignant obstructive jaundice include pancreatic cancer, cholangiocarcinoma, and metastatic disease. (1).

Gallstones (cholelithiasis) are masses in the gallbladder or biliary tract that are caused by abnormally high levels of either cholesterol or bilirubin (a breakdown product of haem) in bile. Gallstones are common (~10–20% of the global adult population), and >20% of people with

gallstones will develop symptoms in their lifetime (including biliary colic or infections), usually in adulthood. Gallstone disease is defined by the occurrence of symptoms or complications caused by gallstones in the gallbladder and/or the bile ducts. From a clinical perspective and in treatment algorithms, those with asymptomatic stones are not generally classified as having gallstone disease. Gallstone disease is among the gastrointestinal conditions associated with the highest socioeconomic costs (2).

Biliary drainage can be either percutaneous transhepatic biliary drainage (PTBD) or endoscopic biliary drainage (EBD). EBD is of 2 types: external drainage which is endoscopic nasobiliary drainage (ENBD) and internal drainage which is stent placement. Endoscopic drainage is superior to percutaneous drainage because of less complication rate (2).

PTBD is done as an interventional radiology procedure. This access may be used in the future for biliary interventions such as stone removal with a choledochoscope, placement of biliary stents, and treatment of biliary strictures. Both PTBD and ENBD have several complications and disadvantages including self-extraction, dislodgment, twisting, and collapse of the tube, patient discomfort and electrolyte abnormalities secondary to loss of bile and its contents. Other complications related to PTBD include bile leakage and pneumothorax. Bile cultures can be done, if needed, through these 2 approaches. On the other hand, endoscopic biliary drainage has the advantage of lack of discomfort for the patient and no loss of electrolytes or fluid (3).

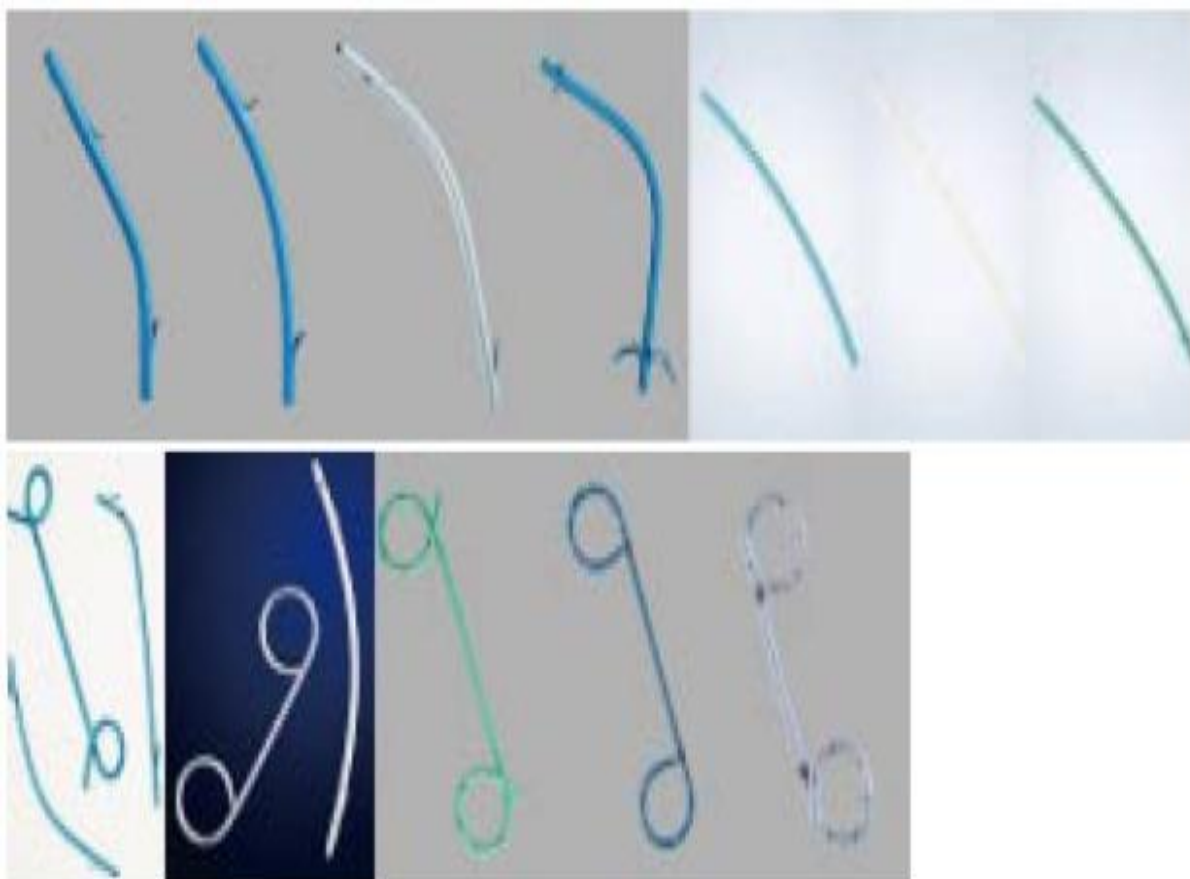
### **Types Of Biliary Stents**

Biliary stents are made of plastic or metal. Biliary sphincterotomy is not required for inserting a single plastic stent or self-expanding metal stent (SEMS), but if indicated, blended electrosurgical current needs to be used. The French (Fr) is the unit of measurement of the external diameter of biliary stents and is equal to one third of a millimeter. Most standard duodenoscopes have working channels that are 4.2 mm in diameter, which makes it impossible to introduce larger plastic stents through. The stent length is usually the distance between the proximal and distal flaps of the stent (1).

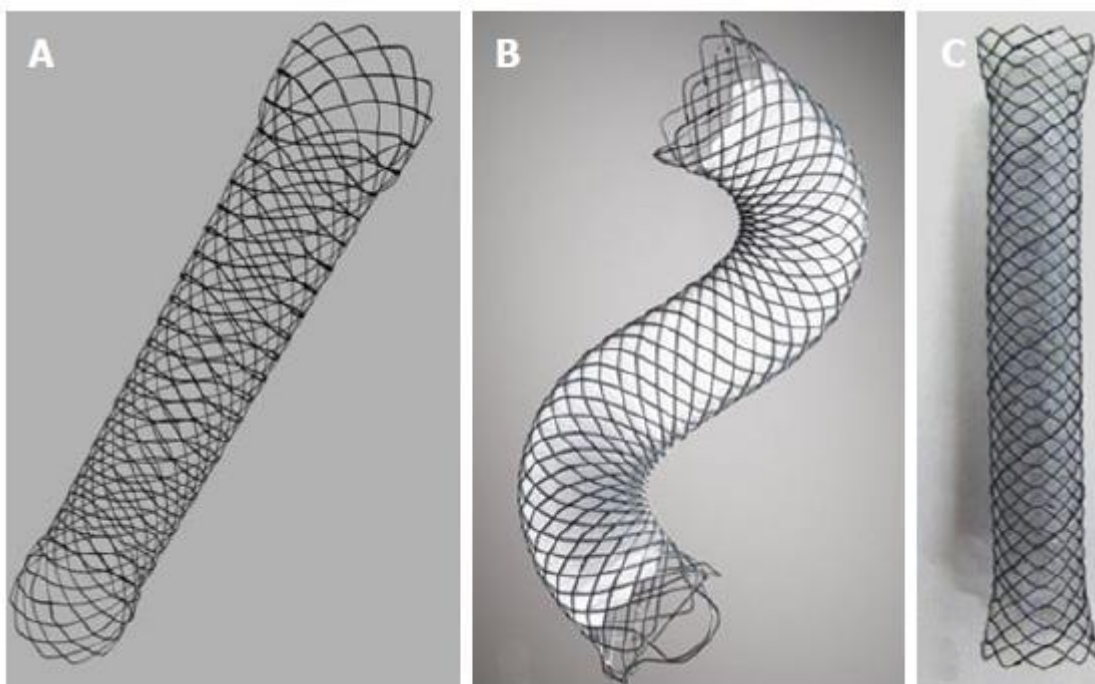
For palliation of malignant biliary obstruction, endoscopic biliary stenting carries a lower morbidity than surgery. Generally speaking, SEMSs are preferred to plastic stents because of decreased incidence of stent obstruction at 4 months. Therefore, in these patients, if life expectancy is less than 4 months, plastic stents are indicated as this would be more cost-effective, especially those measuring 10 Fr in diameter. If life expectancy is longer than 4 months, SEMSs are recommended. On the other hand, if the malignant stricture is resectable, surgery within a week (to insert a plastic biliary stent for biliary drainage preparing for delayed surgery) is recommended, as it carries less morbidity. Preoperative drainage of potentially resectable biliary obstruction is recommended only in patients with severe itching and delayed

surgery, in patients with acute cholangitis, or in patients who would undergo neoadjuvant therapies. (1).

Plastic biliary stents differ in length, diameter, shape, material, and price. They range from 1 to 25 cm in length, but standard models range from 5 to 18 cm. Longer models are used in liver transplant patients. They range from 3 to 11.5 Fr in diameter. Standard external diameters of plastic biliary stents are 7.0, 8.5, 10.0, and 11.5 Fr. They can be straight, curved, wedge, angled, winged, with single or double pigtail (rarely used), and with center bend and/or duodenal bend. Wedge stents have no flaps. Other stents have flaps which can be external or internal, with single, two or four flaps, to prevent dislocation. S-shaped plastic stents are particularly designed to drain the left biliary tree. The stents are made up of polyethylene (most common), polyurethane, polyethylene/polyurethane blend, Teflon or soft polymer blend. Some types of stents are made of an inner layer of Perfluoro, a middle layer of stainless steel and an outer layer of polyamide elastomer. European Society of Gastrointestinal Endoscopy (ESGE) recommends against Teflon stents as they are not as soft as Polyethylene stents (1).



**Figure 1: A display of different types of biliary plastic stents available (4).**



**Figure 2:** A display of different types of biliary self-expandable metal stents available. The Evolution (A) uncovered stent, Cook Endoscopy, the Wallflex (B) partially covered stent, Boston Scientific, and the SHC (C) fully covered stent, Hanaro MI Tech(4).

### Technique of Stent Insertion

Materials required for plastic stent insertion include radiopaque guidewire, stent insertion system and dilators. The guide wire most often has a stiffer shaft and a hydrophilic tip to make passage of strictures easier. Guidewire systems have a locking mechanism to prevent the wire from slipping during exchange procedures. They may have intraductal exchange that allows for removing the catheter while leaving the guide wire in the biliary tract, thus insertion of multiple plastic stents would be feasible. Stent insertion system consists of a plastic guiding catheter (with radiopaque markers), stent, and pusher tube. A guiding catheter is not required for 7 Fr stents. A balloon catheter or bougie is used to overcome a stricture (4).

The required stent length is assessed based on cholangiography and should be the shortest possible that allows adequate drainage. One end of the stent should be 1 to 2 cm beyond the proximal biliary obstacle and the other end should be 1 cm into the duodenum. If the intraduodenal portion of the stent is long, perforation or bleeding ulcer may happen. The stent is loaded onto the guiding catheter, which is flushed with saline. The stent insertion system is introduced into the working channel of the duodenoscope. The guiding catheter is then disconnected from the pusher tube after going past the stricture and the stent is progressively inserted. Stent insertion is made easier through anticlockwise rotation and pulling of the

endoscope. The endoscope has to be near the papilla throughout the procedure to avoid looping of the insertion system in the duodenum. When the stent is in the proper position, the guide wire and the guiding catheter are withdrawn leaving the pusher tube in contact with the stent to prevent dislocation. An X-ray is obtained to verify patency. The upper end of the stent should be below the cystic duct. Long plastic stents can be shortened by a snare wire of a lithotripter. Insertion of SEMS is done under fluoroscopy. Long SEMSs may be trimmed using argon plasma coagulation (5).

Early complications of biliary stenting include infection, bleeding, and pancreatitis. Complications of biliary stents include occlusion caused by sludge in both types of stents or by tissue overgrowth. Dislodgment happens more frequently at 20% of the time with fully covered SEMSs, followed by plastic stents and partially covered SEMSs approximately 5% of the time. This complication is not as frequent with uncovered SEMSs with a rate of 1%. Dislodgment happens with benign biliary strictures more often than with malignant strictures (6).

**ASGE Guideline on The Role of Endoscopy in The Evaluation and Management of Choledocholithiasis (12).**

1. In patients with intermediate risk (10%-50%) of choledocholithiasis, we suggest either EUS or MRCP given high specificity; consider factors including patient preference, local expertise, and availability
2. In patients with gallstone pancreatitis without cholangitis or biliary obstruction/choledocholithiasis, we recommend against urgent (<48 hours) ERCP.
3. In patients with large choledocholithiasis, we suggest performing large-balloon dilation after sphincterotomy rather than endoscopic sphincterotomy alone.
4. For patients with large and difficult choledocholithiasis, we suggest intraductal therapy or conventional therapy with papillary dilation. This may be impacted by local expertise, cost, and patient and physician preferences.
5. Same-admission cholecystectomy is recommended for patients with mild gallstone pancreatitis
6. In order to minimize the risk of diagnostic ERCP, we suggest the following HIGH-RISK criteria to directly prompt ERCP for suspected choledocholithiasis:
  - (1) CBD stone on ultrasound or cross-sectional imaging or (2) Total bilirubin >4 mg/dL AND dilated common bile duct on imaging (>6 mm with gallbladder in situ)\* or
  - (3) Ascending cholangitis. In patients with INTERMEDIATE-RISK criteria of abnormal liver tests or age >55 years or dilated CBD on ultrasound, we suggest EUS, MRCP, laparoscopic intraoperative cholangiography (IOC), or laparoscopic intraoperative ultrasound for further evaluation For patients with symptomatic cholelithiasis without any of these risk factors, we suggest cholecystectomy without IOC.

7. We suggest that pre-operative or post operative ERCP or laparoscopic treatment be performed for patients at high risk of choledocholithiasis or positive intraoperative cholangiopancreatography depending on local surgical and endoscopic expertise.
8. For patients with Mirizzi syndrome, per-oral cholangioscopic therapy may be an alternative to surgical management depending on local expertise; however, gallbladder resection is needed regardless of strategy. For hepatolithiasis we suggest a multidisciplinary approach including endoscopy, interventional radiology, and surgery.
9. Plastic and covered metal stents may facilitate removal of difficult choledocholithiasis but require planned exchange or removal.

### **ESGE recommendations for Failed extraction of biliary stones**

- ESGE suggests endoscopic placement of a temporary biliary plastic stent in patients with irretrievable biliary stones. Weak recommendation, moderate quality evidence (1).

If CBD stones cannot be removed during ERCP because of patient condition or technical factors, a biliary stent may be inserted to both drain the bile ducts and facilitate delayed stone extraction, as stone size will decrease by a mean of 50% in 2 – 6 months (7).

An RCT in 86 frail patients has shown that shortterm complications tend to be less frequent with this strategy compared with attempted CBD stone removal (8).

Plastic stents have been used in most studies and no comparison between the different types and diameters is available. A meta-analysis (6 studies, 885 patients) showed that the risk of cholangitis is highly increased with permanent stenting vs. elective stent exchange (OR 5.32, 95%CI 2.23 – 12.68) (7).

Therefore, stenting for biliary stones should be considered a temporary measure until bile duct clearance is achieved. The ideal timeframe for stent exchange has not been defined. An RCT (78 patients) has reported a lower incidence of cholangitis following the insertion of a 10-Fr stent if the stent was exchanged every 3 months vs. on demand (9).

These findings are in line with a retrospective study (64 patients) that reported a higher stent patency rate at 3 months with two plastic stents vs. one (10).

FCSEMSs have been used in six retrospective series (total 160 patients) and stones were successfully removed in 127 of 144 attempted cases (88%), most often with a simple balloon sweep. Adverse events were noted in 29 cases (18 %) and the cost-effectiveness has not been compared with that of plastic stents (11).

**ESGE recommendations for benign biliary strictures (1).**

- I. ESGE recommends temporary insertion of multiple plastic stents or of a fully covered SEMS for treatment of benign biliary strictures. Strong recommendation, moderate quality evidence. The choice between the two strategies depends on the etiology of the stricture, its location, the CBD diameter, and endoscopist experience.
- II. ESGE suggests the temporary insertion of multiple plastic stents or of an FCSEMS for treating benign biliary strictures related to chronic pancreatitis. Weak recommendation, moderate quality evidence.
- III. ESGE suggests temporary insertion of multiple plastic stents for the treatment of benign anastomotic biliary strictures following orthotopic liver transplantation pending further evidence about FCSEMS. Weak recommendation, moderate quality evidence.
- IV. ESGE recommends endoscopic placement of plastic stent(s) to treat bile duct leaks that are not due to transection of the common bile duct or common hepatic duct. Strong recommendation, moderate quality evidence. SEMS may be valuable in the case of refractory bile leak. ESGE does not recommend a primary endoscopic approach to drain bilomas. Strong recommendation, low quality evidence.

**References:**

1. Dumonceau, J. M., Tringali, A., Papanikolaou, I. S., Blero, D., Mangiavillano, B., Schmidt, A., ... & van Hooft, J. E. (2018). Endoscopic biliary stenting: indications, choice of stents, and results: European Society of Gastrointestinal Endoscopy (ESGE) Clinical Guideline—Updated October 2017. *Endoscopy*, 50(09), 910-930.
2. Teoh, A. Y., Dhir, V., Kida, M., Yasuda, I., Jin, Z. D., Seo, D. W., ... & Ho, L. K. Y. (2018). Consensus guidelines on the optimal management in interventional EUS procedures: results from the Asian EUS group RAND/UCLA expert panel. *Gut*, 67(7), 1209-1228.
3. Zhang, X., Wang, X., Wang, L., Tang, R., & Dong, J. (2018). Effect of covered self-expanding metal stents compared with multiple plastic stents on benign biliary stricture: A meta-analysis. *Medicine*, 97(36).
4. Mangiavillano, B., Pagano, N., Baron, T. H., Arena, M., Iabichino, G., Consolo, P., ... & Luigiano, C. (2016). Biliary and pancreatic stenting: Devices and insertion techniques in therapeutic endoscopic retrograde cholangiopancreatography and endoscopic ultrasonography. *World journal of gastrointestinal endoscopy*, 8(3), 143.
5. Meseeha, M., & Attia, M. (2021). Biliary stenting. In *StatPearls* [Internet]. StatPearls Publishing.
6. Catalano, O., De Bellis, M., Sandomenico, F., de Lutio di Castelguidone, E., Delrio, P., & Petrillo, A. (2012). Complications of biliary and gastrointestinal stents: MDCT of the cancer patient. *AJR-American Journal of Roentgenology*, 199(2), W187.

7. Mohammed, N., Pinder, M., Harris, K., & Everett, S. M. (2016). Endoscopic biliary stenting in irretrievable common bile duct stones: stent exchange or expectant management—tertiary-centre experience and systematic review. *Frontline Gastroenterology*, 7(3), 176-186.
8. Chopra, K. B., Peters, R. A., O'Toole, P. A., Williams, S. G., Gimson, A. E., Lombard, M. G., & Westaby, D. (1996). Randomised study of endoscopic biliary endoprosthesis versus duct clearance for bile duct stones in high-risk patients. *The Lancet*, 348(9030), 791-793.
9. Di Giorgio, P., Manes, G., Grimaldi, E., Schettino, M., D'Alessandro, A., Di Giorgio, A., & Giannattasio, F. (2013). Endoscopic plastic stenting for bile duct stones: stent changing on demand or every 3 months. A prospective comparison study. *Endoscopy*, 45(12), 1014-1017.
10. Ye, X., Huai, J., & Sun, X. (2016). Effectiveness and safety of biliary stenting in the management of difficult common bile duct stones in elderly patients. *Turk J Gastroenterol*, 27(1), 30-6.
11. Hartery, K., Cullen, G., & Mulcahy, H. E. (2017). Do we really need a fully covered self-expanding metal stent for the treatment of difficult common bile duct stones? Response. *GASTROINTESTINAL ENDOSCOPY*, 86(4), 746-747.
12. Buxbaum, J. L., Fehmi, S. M. A., Sultan, S., Fishman, D. S., Qumseya, B. J., Cortessis, V. K., ... & ASGE Standards of Practice Committee. (2019). ASGE guideline on the role of endoscopy in the evaluation and management of choledocholithiasis. *Gastrointestinal endoscopy*, 89(6), 1075-1105.