



Cracked Tooth Syndrome

Dr. Pauravi Prithviraj Hegde, Senior Lecturer, Department of Conservative Dentistry & Endodontics, DY Patil University School of Dentistry, Navi Mumbai

Dr. Sandya Kini, Professor & Head of the Department, Department of Conservative Dentistry & Endodontics, Manipal College of Dental Sciences, Manipal Academy of Higher Education, Manipal, Karnataka

Dr. Shashi Rashmi Acharya, Professor, Department of Conservative Dentistry & Endodontics, Manipal College of Dental Sciences, MAHE, Manipal, Karnataka, India

Dr. Krishnaraj Somayaji, Associate Professor, Department of Conservative Dentistry & Endodontics, Manipal College of Dental Sciences, MAHE, Manipal, Karnataka, India

Dr. Sonia Gupta, Post Graduate Student, Department of Conservative Dentistry & Endodontics, Manipal College of Dental Sciences, MAHE, Manipal, Karnataka, India

Corresponding author: Dr. Sandya Kini, Professor & Head of the Department, Department of Conservative Dentistry & Endodontics, Manipal College of Dental Sciences, Manipal Academy of Higher Education, Manipal, Karnataka

Abstract: Cracked tooth syndrome is termed as a plane of fracture of variable depth that has its origin in the crown, after which it gorges through the tooth structure and extends below the gingiva, while traversing through to form a link with the underlying pulp space and periodontal ligament. Although a dilemma, a thorough and detailed dental history and diagnostic aids help in the detection of cracked tooth syndrome. Early diagnosis is of great importance in the treatment of fracture in order to prevent the progress of the crack and consequent microleakage. This paper highlights the readers the importance of prevention, diagnosis and management of cracked tooth syndrome.

Keywords: Tooth fracture, Crack, Craze lines, Transillumination

Cracked Tooth Syndrome Introduction: Cracked tooth syndrome is described as a plane of fracture of variable depth, it has its origin in the crown, after which it passes through the tooth structure and extends beneath the gingiva, while traversing through to form a link with the underlying pulp space and periodontal ligament [1,2]. Cameron suggested the name

cracked tooth syndrome. This condition has been found to be occurring mainly in middle aged patients approximately 40 – 49 years of age. [6,7] Males and females are equally affected.[8] Among the different teeth in the dentition the most frequently fractured teeth are the lower molars, [6].

Geurtsen [14] had shown that when undue forces were applied to a sound tooth or physiologically applied forces on a debilitated tooth resulted in an incomplete fracture of the enamel or dentine. Lynch and McConnell [11] subdivided the aetiology into four major categories which were - restorative procedures, occlusal factors, developmental factors, and miscellaneous factors. Currently, common etiological factors are inclusive of biting on a hard, rigid object with unusually high force, [9,2] or removal of too much tooth structure in the process of cavity preparation.[16] Parafunctional habits such as involuntary bruxing of teeth are also found in relation with the development of this condition. [3,16] Undue condensation pressures, expansion of some of the poor quality amalgam alloys as a result of moisture contamination, placement of retentive pins,[9] and full-fledged composite restorations placed devoid of proper care [9] predisposes to the formation of a crack.

Incidence of Cracked Tooth Syndrome in the lower second molars may occur as a result of their propinquity to the TMJ,[3,4,6] based on the principle of the “lever” effect — the mechanical force applied on an object increases as the distance to the fulcrum decreases.[10] The disto-lingual cusp of mandibular molars is the most commonly affected cusp for fracture. Non-functional cusps may be more prone to fracture than functional cusps [14,20,21]. While functional cusps are supported on their inner and outer aspects by the tooth in the opposite arch, non-functional cusps tend to be more prone to fracture from lateral excursive occlusal forces due to the lack of support from the outer aspect. [21].

Classification

American Association of Endodontists Classification of Cracked Tooth

Craze lines are visible fractures and located within the enamel. In posterior teeth, craze lines are usually seen traversing the marginal ridges and/or progressing along the buccally and lingually on the respective surfaces. Longer vertical craze lines typically occur in anterior teeth.

Fractured Cusps have their origin in the tooth crown, extending into dentin, and ending in the cervical portion of the tooth. They result detection of unsupported enamel

Cracked Tooth is an indication that the crack is extending from the occlusal surface of the tooth in an apical direction devoid of partition of the two fragments. The crack is generally located at the centre of the tooth in a mesiodistal direction and may involve one or both marginal ridges

Split Tooth is an indication of the crack outspreading through both marginal ridges usually in a mesiodistal direction disjoining it wholly into two individual fragments. The crack is generally situated at the centre of the tooth.

Vertical root fractures have their origin in the root generally progress bucco-lingually. The crack is generally complete though at times it may be incomplete and involve only one surface. The crack may involve either the entire root or only a part of the root

According to Luebke: [13]

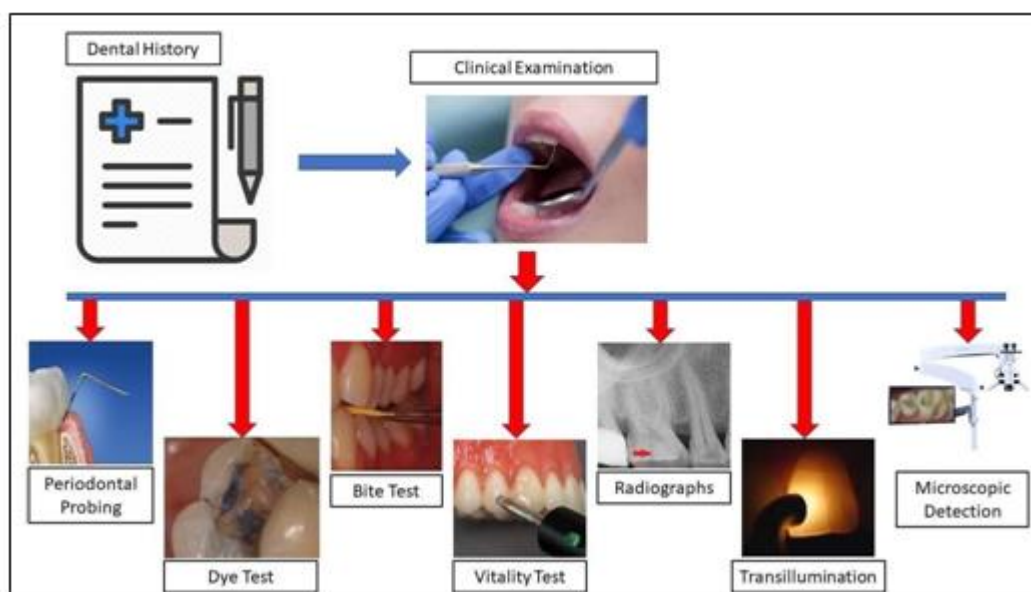
Class 1 – Incomplete, Supra-osseous with no periodontal defect

Class 2 – Incomplete, Intra-osseous with minor periodontal defect

Class 3 – Complete or Incomplete intra-osseous with major periodontal defect

Diagnosis

Dental History:

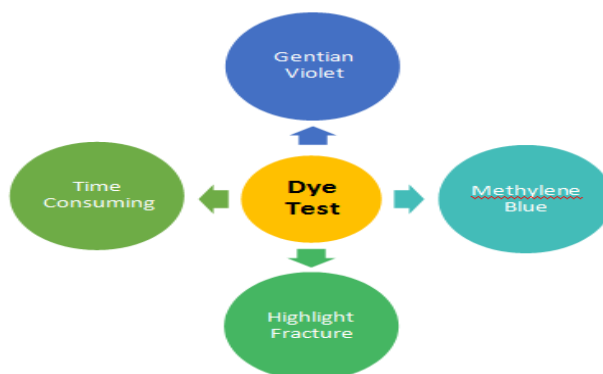


A thorough and detailed dental history may help in the detection of certain distinct indicators.

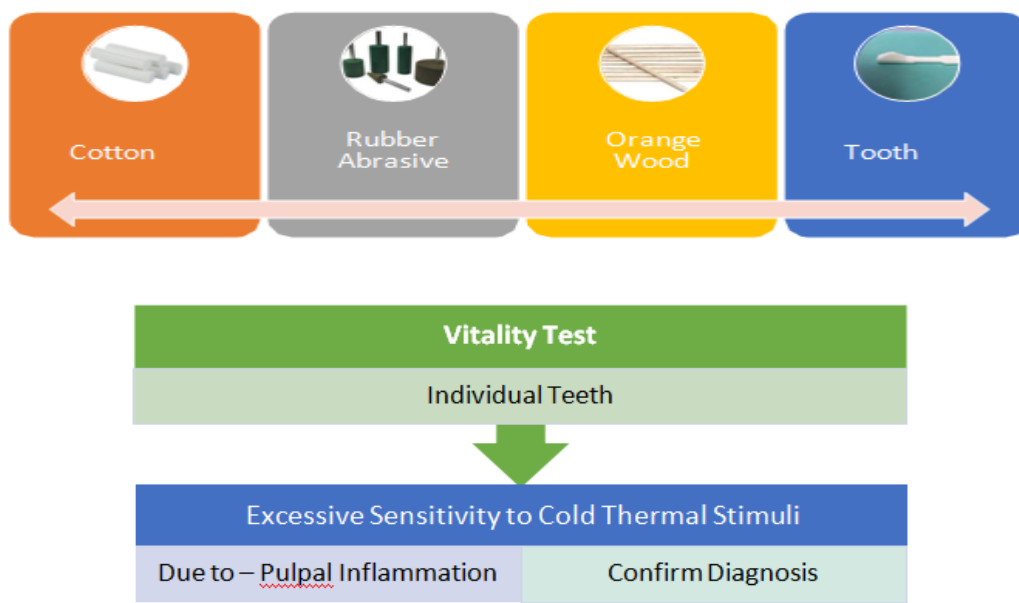
[11] The patient may have a history of long term dental treatment, multiple replacements of restorations, and occlusal adjustments. [24] History of sensitivity to cold and sharp pain that arises as a result of biting on hard or tough foods which diminishes when the pressure is released is an important factor to be considered. [14] Cracked teeth are most often devoid of symptoms. The signs associated with pain shown are not exclusively found in association with cracked teeth but can occur in relation to other causes of tooth pain, that include caries, pulpal pathology, or periodontal disease. Sensitivity to percussion, could be an indication that the tooth may be associated with irreversible pulpitis or an abscess. A cracked tooth may not exhibit temperature sensitivity if the crack has resulted in necrosis of the pulp or exhibit sharp pain on occluding on a device that has been placed on a suspected cusp that has cracked. [11]

Clinical Examination: The utilization of certain instruments such as a probes on the margins of the over-filled tooth may give rise to sharp pain, which is an indication of the presence of underlying crack. On removal of the previous fillings, may result in the revealing of the fracture lines. It may also reveal the occurrence of localized periodontal defects extending below the gingiva. The use of materials such as rubber dam helps in improving the visualization of these cracks, highlighting the crack with a distinct background, free of salivary contamination.

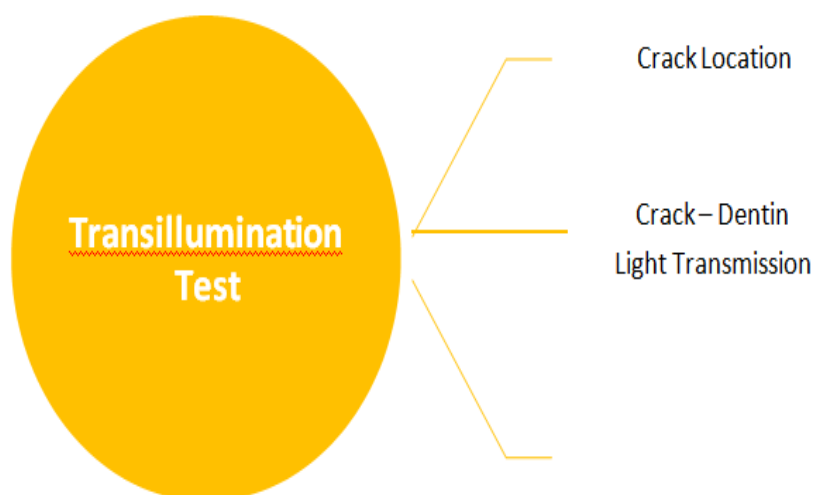
	Cracked Tooth	Split Tooth
Periodontal Probing	Careful Probing to detect periodontal pocket	Isolated periodontal pocket detected

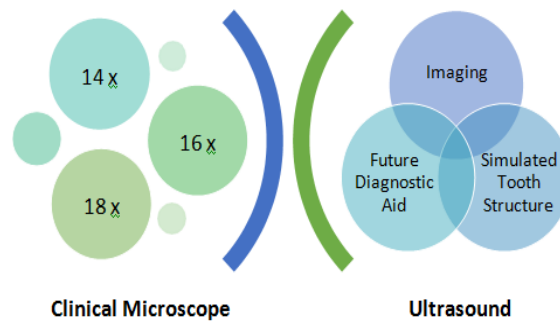


Bite Tests: Pain that occurs on biting and diminishes after the pressure has been withdrawn is a distinctive sign. Symptoms may be provoked when pressure is exerted on an individual cusp.[2,9,16] This forms the basis of so-called “bite tests.”



Radiographs: Radiographic diagnosis of cracked teeth is usually doubtful. [11] Fractures that occur in a bucco-lingual direction are more frequently encountered on radiographs. They may play a role in evaluation of the status of the pulp and periodontal tissues. [8]



Microscopic detection:

Indirect diagnostic measures, such as the copper rings and acrylic provisional crowns can also be used for the detection of a cracked tooth syndrome.[4]

Another indirect diagnostic method is an unauthenticated technique by Banerji *et al.* [12] Composite resin is placed over the tooth without performing the etching and bonding procedures. The patient feels marked improvement in the previously occurring discomfort on biting, as the material will act as a splint.

Management

Coronal fracture: Treatment of cracked teeth should involve identification of prompting factors, identification of signs and symptoms and the provision of a strong restorations that is responsible for the protection of the tooth from fracture. Prompt diagnosis is of great importance during treatment of fracture in order to hinder the progress of the crack, consequent microleakage and contribution of the pulpal and periodontal tissues. [3,4,6] The treatment required for a cracked tooth is affected by the location and spread of the fracture. [4,14] Cracks that gain entry into the pulpal tissue indicate the need for a endodontic therapy though Bader *et al* [26] reported that the most of the tooth fractures can be managed successful manner in a single sitting by means of direct restorative materials. A multi-disciplinary approach along with surgical intervention may be required. Teeth consisting of cracks that are intraosseous with pain of periodontal type often involving the mesial and distal aspects of the tooth and the cavity floor have a hopeless prognosis. Initial treatment involves the removal of all existing restorations to fully evaluate the area involving the fracture. Transillumination is a useful guide. [17] In the initial diagnostic phase, the use of copper or stainless-steel bands, [4,14,24]stainless steel crowns, [25] and acrylic resin crowns [28] have been advocated. Placement of a sedative provisional restoration is not advisable as

this approach will not stabilize the fracture leaving the tooth susceptible for further progression of the crack. [29]

Definitive treatment has included pin retained amalgams, bonded amalgams, [18,19] bonded composites, [20] cusp overlay restorations, [30-32] and full coverage crowns. [4,10,14,28]

Clark & Caughman [27] have categorized the prognosis of cracked teeth as follows:

1. Excellent:

(a) Cuspal fracture localised within the dentin.

(b) Horizontal fracture of a cusp without involvement of the pulp.

2. Good: A coronal vertical fracture that traverses mesio-distally into the dentin but not into the pulp tissue.

3. Poor: A coronal vertical fracture that traverses mesio-distally into the dentin and pulp but is localized within the crown.

4. Hopeless: A coronal vertical fracture that runs in a mesio-distal direction through the pulp and extends into the root.

Vertical root fracture: Single-rooted teeth that are fractured should be extracted as soon as is practical to prevent further bone loss. Multi-rooted teeth can often be successfully treated by resecting the fractured root, either by root amputation or hemi-section. [33] Studies of root resected teeth have reported 5-year retention rates of 94% [34] and 10-year retention rates of 68%. [35] However, the desire to retain part of a root fractured tooth should be carefully considered against extraction and replacement with a denture, bridge or implant.

Conventional treatments for CTS reported in the literature involve some form of protective cuspal coverage restoration. The specific treatment protocol suggested is to remove any existing restoration, evaluate the health of the pulp and remaining coronal tooth structure, and if indicated, restore with a full crown. Any tooth with irreversible pulpitis or a necrotic pulp should have RCT prior to crown placement. [15, 17, 36] Cast gold partial or complete tooth coverage, porcelain fused to metal full coverage, and all porcelain full coverage have all been used. [14, 37, 39] Some authors advocate removing the existing restoration, placing a sedative filling (for example IRM, a zinc oxide eugenol restorative material), and cementing an orthodontic band for stabilization. Once symptoms have resolved

and the tooth has been deemed restorable, a build-up and full coverage restoration is placed. [13, 38] Other authors advocate occlusal adjustment in addition to crown placement.

Direct versus Cuspal Coverage Restoration of Cracked teeth: If a dentist decides to permanently restore a cracked tooth with a direct restoration, [19, 40 -43] the dentist may want to adjust [44 - 45] the bio-mechanical circumstances of the tooth to increase the tooth's resistance to further cracking. If the dentist decides to crown [46] the tooth, the dentist may also want to adjust the tooth to stabilize the tooth bio-mechanically in the days or weeks prior to the crown preparation appointment. Such stabilization may be accomplished by reducing, on the cracked tooth, the steep inclines [47] of any non-functional or guiding cusps that are in deep overbite with opposing teeth (ideally without exposing dentin), or smoothing the pointy plunger cusps of opposing teeth that are occluding into the cracked tooth, to reduce tensile forces on the tooth. The dentist should maintain the overjet of the maxillary posterior buccal cusps with the mandibular posterior buccal cusps, to prevent cheek-biting that may result from lack of overjet. Ideally, centric contacts should not be removed with such adjustments since this may result in other teeth in the arch re-equilibrating to a different occlusal force distribution.

Furthermore, if the opposing tooth occludes only into the cracked tooth, removing centric contacts may induce the opposing tooth to extrude back into occlusion with the cracked tooth. If a partially fractured tooth is not in occlusion or is opposed by a denture tooth, the tooth may last indefinitely. If the patient is young, relatively few years may have been required until an observed fracture plane developed, implying a faster rate of fracture propagation, [46] potentially justifying crown treatment.

A tooth may present with a cusp fractured off and a large restoration that occupies most of the marginal ridge areas and the tooth structure occlusal to the pulp chamber roof. Here, the natural tooth structure was unable to accept the force load of retaining the restoration without developing a cusp fracture; with the cusp gone, the remainder of the tooth must now accept a larger force load to retain the restoration, which may eventually result in another cusp fracture. The apical aspect of the void left by the fractured cusp may slope to a thin edge towards the apical lateral direction, which hinders preparation of a flat preparation

margin, using a 33½ bur, to provide compression support for the next. A radiograph may show a restoration that is deep in an occlusal-to-apical direction, where there is minimal height of tooth structure from the gingival interface level of the tooth to the apical level of the restoration. A crown and possibly a post may be needed to retain the supra-gingival restoration.

Conclusion: The present article has highlighted the different categories for a cracked tooth, methods for diagnosis of a cracked tooth as well as the treatment modalities for a cracked tooth. There is however a lack of knowledge with regard to the treatment of different categories of cracked teeth. Hence further advent into the treatment modalities for the different categories of cracked teeth could lead to an improvement in the patient management and care.

References

1. Hasan S, Singh K, Salati N. Cracked tooth syndrome: Overview of literature. *Int J App Basic Med Res* 2015; 5:164-8.
2. Gibbs JW. Cuspal fracture odontalgia. *Dent Dig* 1954; 60:158- 60.
3. Cameron CE. Cracked- tooth syndrome. *J Am Dent Assoc* 1964; 68:405- 11
4. Ehrmann EH, Tyas MT. Cracked tooth syndrome: diagnosis, treatment and correlation between symptoms and post-extraction findings. *Aust Dent J* 1990; 35(2):105-12. 4
5. Mittal N, Sharma V, Minocha A. Management of cracked teeth - a case report. *Endodontology* 2007; 19 (1). 5
6. Hiatt WH. Incomplete crown-root fracture in pulpal-periodontal disease. *J Periodontol* 1973; 44(6):369-79. 6
7. Ellis SG, Macfarlane TV, McCord JF. Influence of patient age on the nature of tooth fracture. *J Prosthet Dent* 1999; 82(2):226-30. 7
8. Türp JC, Gobetti JP. The cracked tooth syndrome: an elusive diagnosis. *J Am Dent Assoc* 1996; 127(10):1502-7. 8
9. Rosen H. Cracked tooth syndrome. *J Prosthet Dent* 1982; 47(1):36-43. 9
10. Cameron CE. The cracked tooth syndrome: Additional findings. *J Am Dent Assoc* 1976; 93:971- 5. 10

11. Lynch CD, McConnell RJ. The cracked tooth syndrome. *J Can Dent Assoc* 2002; 68:470- 5. 11
12. Banerji S, Mehta SB, Millar BJ. Cracked tooth syndrome. Part 1: Aetiology and diagnosis. *Br Dent J* 2010; 208:459-63.
13. Luebke RG. Vertical crown-root fractures in posterior teeth. *Dent Clin North Am* 1984; 28:883-894. 12
14. Geurtsen W. The cracked- tooth syndrome: Clinical features and case reports. *Int J Periodontics Restorative Dent* 1992; 12:395- 405. 13
15. Ritchey B, Mendenhall R, Orban B. Pulpitis resulting from incomplete tooth fracture. *Oral Med Oral Surg Oral Pathol* 1957; 10(June):665-70. 14
16. Bales DJ. Pain and the cracked tooth. *J Indiana Dent Assoc* 1975; 54(5):15-8. 15
17. Abou-Rass M. Crack lines: the precursors of tooth fractures — their diagnosis and treatment. *Quintessence Int* 1983; 14(4):437-47. 16
18. Trushkowsky R. Restoration of a cracked tooth with a bonded amalgam. *Quintessence Int* 1991; 22(5):397-400. 17
19. Bearn DR, Saunders EM, Saunders WP. The bonded amalgam restoration — a review of the literature and report of its use in the treatment of four cases of cracked-tooth syndrome. *Quintessence Int* 1994; 25(5):321-6. 18
20. Eakle WS. Increased fracture resistance of teeth: Comparison of five bonded composite resin systems. *Quintessence Int* 1986; 17:17-20. 19
21. Cavel WT, Kelsey WP, Blankenau RJ. An *in vivo* study of cuspal fracture. *J Prosthet Dent* 1985; 53:38-41. 20
22. Khera SC, Carpenter CW, Vetter JD, Staley RN. Anatomy of cusps of posterior teeth and their fracture potential. *J Prosthet Dent* 1990; 64:139 147. 21
23. Schneider AR, Binder H. Periodontal considerations relevant to treating the fractured tooth. *J Prosthet Dent* 1984; 51:624- 7. 22
24. Homewood CI. Cracked tooth syndrome – incidence, clinical findings and treatment. *Aust Dent J* 1998; 43:217- 22.
25. Chong BS. Bilateral cracked teeth: A case report. *Int Endod J* 1989;22: 193-196.
26. Bader JD, Shugars DA, Sturdevant JR. Consequences of posterior cusp fracture. *Gen Dent* 2004; 63:128-131.

27. Clark LL, Caughman WF. Restorative treatment for the cracked tooth. *Oper Dent* 1984; 9:136-142.
28. Guthrie C, Difiore PM. Treating the cracked tooth with a full crown. *J Am Dent Assoc* 1991; 122:71-73.
29. Ailor JE. Managing incomplete fractures. *J Am Dent Assoc* 2000;131: 1168-1174.
30. Hansen EK, Asmussen E, Christiansen NC. *In vivo* fractures of endodontically treated posterior teeth restored with amalgam. *Endod Dent Traumatol* 1990; 6:49-55.
31. Linn J, Messer HH. Effect of restorative procedures on the strength of endodontically treated molars. *J Endod* 1994; 20:479-485.
32. Panitvisai P, Messer HH. Cuspal deflection in molars in relation to endodontic and restorative procedures. *J Endod* 1995; 21:57-61.
33. Korte PF, Carr JG, Cohen J. Vertical root fracture and its relationship to the periodontium. *J Mich Dent Assoc* 1980; 62:387-389.
34. Langer B, Stein S, Wagenberg B. An evaluation of root resections. A ten-year study. *J Periodontol* 1981; 52:719-722.
35. Buhler H. Evaluation of root-resected teeth. Results after 10 years. *J Periodontol* 1988; 59:805-810.
36. Kahler B, Stenzell D, Moule A. Bacterial contamination of cracks in symptomatic vital teeth. *Aust Endod J* 2000; 26:115-117.
37. Griffin JD. Efficient, conservative treatment of symptomatic cracked teeth. *Compend Contin Educ Dent* 2006;27: 93–102.
38. Geurtsen W, Schwarze T, Gunay H. Diagnosis, therapy, and prevention of the cracked tooth syndrome. *Quintessence Int* 2003; 34:409–17.
39. Snyder DE. The cracked-tooth syndrome and fractured posterior cusp. *Oral Surg Oral Med Oral Pathol* 1976; 41(6):698-704.
40. Eakle WS. Increased fracture resistance of teeth: Comparison of five bonded composite resin systems. *Quintessence Int* 1986; 17:17-20.
41. Baxter PW. Management of vertical fractures of posterior teeth with composite resin. *Br Dent J* 1987; 162:219-220.
42. Davis R, Overton JD. Efficacy of bonded and nonbonded amalgam in the treatment of teeth with incomplete fractures. *J Am Dent Assoc* 2000; 131:469- 78.

43. Opdam NJ, Roeters JJ, Loomans BA, Bronkhorst EM. Seven-year clinical evaluation of painful cracked teeth restored with a direct composite restoration. *J Endod* 2008; 34:808- 11.
44. Reeh ES, Messer HH, Douglas WH. Reduction in tooth stiffness as a result of endodontic and restorative procedures. *J Endod* 1989; 15:512- 6.
45. Ito K, Nanba K, Akashi T, Murai S. Incomplete fractures in intact bilateral maxillary first molars: A case report. *Quintessence Int* 1998; 29:243- 8.
46. Lin CL, Chang YH, Hsieh SK, Chang WJ. Estimation of the failure risk of a maxillary premolar with different crack depths with endodontic treatment by computer-aided design/computer-aided manufacturing ceramic restorations. *J Endod* 2013; 39:375- 9.
47. Qian Y, Zhou X, Yang J. Correlation between cuspal inclination and tooth cracked syndrome: A three-dimensional reconstruction measurement and finite element analysis. *Dent Traumatol* 2013; 29:226-33.