



Role of vacuum assisted closure therapy in the management of chronic wounds

¹Dr. Manasi Birmole, ²Dr. Nitin Nangare, ³Dr. Aditya Patel

^{1,3}Resident, ²Professor, Department of General Surgery, Krishna Vishwa Vidhyapeeth, Karad, Maharashtra, India

Corresponding author: Dr. Manasi Birmole, Resident, Department of General Surgery, Krishna Vishwa Vidhyapeeth, Karad, Maharashtra, India

Email: manasibirmole100@gmail.com

ABSTRACT

Background: Post-operative wound infection is a very serious problem, leading to a risk of significant morbidity which may even lead to prolonged hospitalization. The present study was conducted to evaluate role of vacuum assisted closure therapy in chronic wounds.

Materials & Methods: 80 patients of chronic wounds of both genders were selected. A thorough local examination was carried out. Procedure involves wound preparation, placement of white foam (PVA - Polyvinyl alcohol) & black foam; sealing with drapes and application of pressure. Parameters such as size of wound, etiology, Gustilo Anderson classification and bacterial growth was recorded.

Results: Out of 80 patients, males were 50 and females were 30. The size of wound was 1-4.9 mm in 20, 5-9.9 mm in 35 and >10 mm in 19 patients. Etiology was RTA in 52, machinery injury in 15 and fall from height in 7 cases. Gustilo Anderson classification grade IIIb was seen in 41, grade IIIc in 25, grade IIIa in 5 and grade II in 3 cases. Bacterial growth on day 0 was seen in 74, on day 4 in 56 and on day 8 in 28 patients. The difference was significant ($P < 0.05$).

Conclusion: Vacuum assisted closure therapy is preferred treatment of wounds. It has less overall morbidity with decreased hospital stay.

Key words: Bacteria, vacuum assisted closure therapy, wound

Introduction

A wound is defined as damage or disruption to the normal anatomical structure and function.¹ This can range from a simple break in the epithelial integrity of the skin or it can be deeper, extending into subcutaneous tissue with damage to other structures such as tendons, muscles, vessels, nerves, parenchymal organs and even bone. Wound healing remains a challenging clinical problem and correct, efficient wound management is essential.²

Post-operative wound infection is a very serious problem, leading to a risk of significant morbidity which may even lead to prolonged hospitalization.³ Delayed wound healing

particularly in difficult wounds and in elderly with co morbidities is a major concern. It leads to the pain, morbidity, prolonged treatment, and require major reconstructive surgery which imposes enormous social and financial burden.⁴

Vacuum Assisted Closure (VAC) is a non- invasive therapeutic technique using a vacuum dressing to promote healing in acute or chronic and enhance healing of first & second degrees burns.⁵ It involves controlled application of subatmospheric pressure to local wound environment, using a sealed wound dressing connected to a vacuum pump. It uses vacuum assisted drainage to remove blood or serous fluid from operative site. It promotes dry surgical field & control blood flow.^{6,7} The present study was conducted to evaluate role of vacuum assisted closure therapy in chronic wounds.

Materials & Methods

The present study comprised of 80 patients of chronic wounds of both genders. All gave their written consent for participation in the study.

Data such as name, age, gender etc. was recorded. In all patients, wound preparation, placement of white foam & black foam; sealing with drapes and application of pressure was performed. Parameters such as size of wound, etiology, Gustilo Anderson classification and bacterial growth was recorded. Data thus obtained were subjected to statistical analysis. P value < 0.05 was considered significant.

Results

Table I Distribution of patients

Total-80		
Gender	Males	Females
Number	50	30

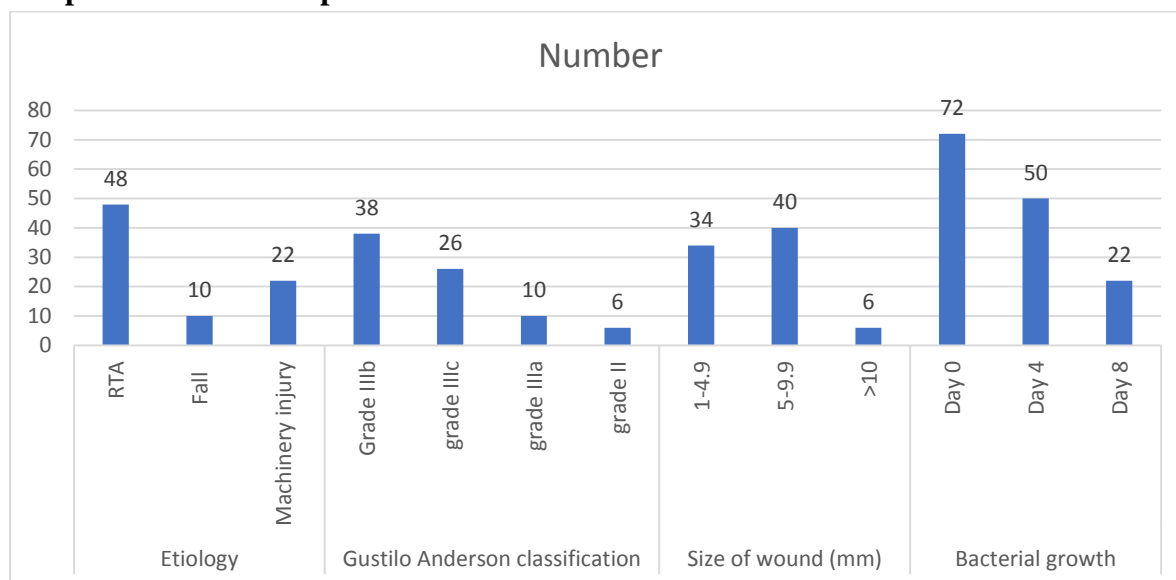
Table I shows that out of 80 patients, males were 50 and females were 30.

Table II Assessment of parameters

Parameters	Variables	Number	P value
Etiology	RTA	48	0.02
	Fall	10	
	Machinery injury	22	
Gustilo Anderson classification	Grade IIIb	38	0.04
	grade IIIc	26	
	grade IIIa	10	
	grade II	6	
Size of wound (mm)	1-4.9	34	
	5-9.9	40	
	>10	6	
Bacterial growth	Day 0	72	0.05
	Day 4	50	
	Day 8	22	

Table II, graph I shows that size of wound was 1-4.9mm in 20, 5-9.9mm in 35 and >10mm in 19 patients. Etiology was RTA in 52, machinery injury in 15 and fall from height in 7 cases. Gustilo Anderson classification grade IIIb was seen in 41, grade IIIc in 25, grade IIIa in 5 and grade II in 3 cases. Bacterial growth on day 0 was seen in 74, on day 4 in 56 and on day 8 in 28 patients. The difference was significant ($P < 0.05$).

Graph I Assessment of parameters



Discussion

Various surgical methods have been developed to obtain coverage in these difficult situations. These include skin grafts, local rotation flaps, and myocutaneous or fasciocutaneous tissue transfers.⁸ Although skin grafts are readily obtainable, they are dependent on the vascularity of its recipient bed and may be contraindicated when exposed bone, cartilage, tendons, or surgical implants exist.⁹ Normal dermal healing in healthy subjects restores the functional integrity of the skin. However, in some patients the healing process may be compromised by extensive tissue loss, co-morbidities, concomitant medication or other factors such as smoking, poor nutrition, or ageing.¹⁰ In recent years our understanding of both the healing process and the defects that occur in delayed healing has allowed the development of a number of new treatments for difficult-to-heal wounds. VAC is the name adopted for a commercially available system that applies topical negative pressure to promote wound healing.¹¹ This is achieved by applying a reticulated, open-pore structured, polyurethane foam to the wound.¹² The present study was conducted to evaluate role of vacuum assisted closure therapy in chronic wounds.

We found that out of 80 patients, males were 50 and females were 30. Fang et al¹³ in their study of effects of different levels of negative pressure (10–175 mmHg) in different wounds showed that the level of negative pressure should be tailored according to the wound types. Acute traumatic wounds requires negative pressure of 125 mm Hg and for chronic non healing venous ulcer the optimum pressure is 50 mm Hg at intermittent cycles.

We found that size of wound was 1-4.9mm in 20, 5-9.9mm in 35 and >10mm in 19 patients. Etiology was RTA in 52, machinery injury in 15 and fall from height in 7 cases. Gustilo Anderson classification grade IIIb was seen in 41, grade IIIc in 25, grade IIIa in 5 and grade II in 3 cases. Bacterial growth on day 0 was seen in 74, on day 4 in 56 and on day 8 in 28 patients. Morykwas et al¹⁴ in their study three hundred wounds were treated- 175 chronic wounds, 94 subacute wounds, and 31 acute wounds. 296 wounds responded favorably to sub-atmospheric pressure treatment, with an increased rate of granulation tissue formation. Wounds were treated until completely closed, were covered with a split-thickness skin graft, or a flap was rotated into the healthy, granulating wound bed. The technique removes chronic edema, leading to increased localized blood flow, and the applied forces result in the enhanced formation of granulation tissue. Vacuum-assisted closure is an extremely efficacious modality for treating chronic and difficult wounds. Gupta et al¹⁵ evaluated the results of vacuum assisted wound therapy in patients with chronic non healing ulcer. Out of 10 wounds taken in the study, 7 wounds reduced in area & were resurfaced with split thickness skin grafting and 3 wounds showed reduction in area & were subjected to secondary closure.

Kale et al¹⁶ reviewed the use of the indigenous VAC in the management of deep infections after spinal instrumentation surgery. 12 out of 514 patients who developed a deep infection after spinal surgery, were selected and reviewed retrospectively at multiple centers. Out of 12 patients, one of the patients needed a partial implant exchange although none of the cases needed complete implant removal. All patients had achieved clean closed wounds along with a retention of the instrumentation. There was no need for flap surgery to cover wound defect in any case. However, antibiotic treatment was necessary in all cases. None of the patients showed a new infection after the treatment.

The limitation the study is small sample size.

Conclusion

Authors found that vacuum assisted closure therapy is preferred treatment of wounds. It has less overall morbidity with decreased hospital stay.

References

1. Cohen IK, Diegelmann RF, Lindblad WJ. Wound Healing: Biochemical and Clinical Aspects, WB Saunders, Philadelphia, Pa, USA. 1992;31(90):926.
2. Pham CT, Middleton P, Maddern G. Vacuum-assisted closure for the management of wounds: an accelerated systematic review. ASERNIP-S Report No.37. 2003. Accessed 12 April 2016.
3. Geishauser M, Staudenmaier RW, Biemer E. Donor-site morbidity of the segmental rectus abdominis muscle flap. British Journal of Plastic Surgery. 1998;51(8):603–7.
4. Kelly M, Searle A. Improving the donor site cosmesis of the latissimus dorsi flap. Annals of Plastic Surgery. 1998;41(6):629–32.
5. Heng MCY. Topical hyperbaric therapy for problem skin wounds. Journal of Dermatologic Surgery and Oncology. 1993;19(8):784–93.

6. Clarke RAF, Henson PM. *The Molecular and Cellular Biology of Wound Repair*. Plenum Press, New York, NY, USA. 1988;1;3-50.
7. Blackburn JH, Boemi L, Hall WW, Jeffords K, Hauck RM, Banducci DR, et al. Negative-pressure dressings as a bolster for skin grafts. *Ann Plast Surg*. 1998;40(5):453–457.
8. Avery C, Pereira J, Moody A, Whitworth I. Negative pressure wound dressing of the radial forearm donor site. *Int J Oral Maxillofac Surg*. 2000;29(3):198–200.
9. Andrabi IH, Ahmad J, Rathore MA, Yousaf M. Vacuum assisted closure of laparostomy wounds a novel technique. *J Ayub Med Coll Abbottabad*. 2007;19(3):89–91.
10. Obdeijn MC, de Lange MY, Lichtendahl DH, de Boer WJ. Vacuum-assisted closure in the treatment of poststernotomy mediastinitis. *Ann Thorac Surg*. 1999;68(6):2358–2360.
11. Vikatmaa P, Juutilainen V, Ukasjarvi P, Malmivaara A. Negative pressure wound therapy: a systematic review on effectiveness and safety. *Eur J VascEndovasc Surg*. 2008;36(4):438–448.
12. Smith LA, Barker DE, Chase CW, Somberg LB, Brock WB, Burns RP. Vacuum pack technique of temporary abdominal closure: A four-year experience. *Am Surg*. 1997;63(12):1102–1107.
13. Fang R., Dorlac W.C., Flaherty S.F. Feasibility of negative pressure wound therapy during intercontinental aero medical evacuation of combat casualties. *J Trauma*. 2010;69(suppl 1):S140–S145.
14. Morykwas MJ, Argenta LC. Vacuum-assisted closure: a new method for wound control and treatment: clinical experience. *Annals of Plastic Surgery*. 1997;38(6):563–77.
15. Gupta S, Shaikh TP, Wani JB, Gujar A, Bagul A, Gautam R, et al. Role of vacuum assisted closure therapy in chronic wounds: for some cases in Navi Mumbai. *Int J Res Med Sci* 2016;4:95- 9.
16. Kale M, Padalkar P, Mehta V. Vacuum-assisted closure in patients with post-operative infections after instrumented spine surgery: a series of 12 cases. *Journal of Orthopaedic Case Reports*. 2017 Jan;7(1):95.