



OVERVIEW OF NO-REFLOW PHENOMENON: CLINICAL IMPACT, DIAGNOSIS, AND MANAGEMENT

Tarek A. Abd-Elaziz¹, Mohamed Abd-Elaziz Attia^{2*}, Nader T. Kandil³, Ahmed S. El-damhory⁴

Article History: Received: 16 Dec 2022, Accepted: 31 Dec 2022, Published online: 21 Jun 2023

ABSTRACT

All efforts are focused on reducing the length of coronary blockage and myocardial ischemia in order to lessen myocardial necrosis in the era of prompt reperfusion for patients with acute myocardial infarction. Despite all these efforts, there is still a residual risk of myocardial ischemia which emerged under the title of no-reflow phenomenon. No-reflow phenomenon represents myocardium hypoperfusion in the setting of a patent epicardial coronary artery. It is usually backed to microvascular obstruction, which may be produced by various mechanisms. This article aimed to review clinical Impact, diagnosis, and the possible management of No-reflow phenomenon.

Keywords: No-Reflow Phenomenon; Clinical Impact, Management

^{1*,2,3,4}Cardiology Department, Faculty of Medicine, Zagazig University, Egypt.

***Corresponding author: Mohamed A. Attia,**

*Cardiology Department, Faculty of Medicine, Zagazig University, Egypt.

Email: mohamedzizou2200@gmail.com,

DOI: - 10.53555/ecb/2023.12.Si13.295

Introduction

No-reflow phenomenon has various definitions in the literature. Classically, no-reflow phenomenon has been defined in 2001 by Eeckhout and Kern as inadequate myocardial perfusion through a given segment of the coronary circulation without angiographic evidence of mechanical vessel obstruction in the setting of primary percutaneous coronary intervention (PPCI) (1). Recently in more details, no-reflow has been considered in the setting of reduction in antegrade blood flow (Thrombolysis In Myocardial Infarction [TIMI]) flow (0 or 1) after stent deployment that was not secondary to abrupt closure, spasm or significant stenosis of the original target lesion (2).

No-reflow incidence varies according to the clinical setting, being as low as 2% in elective native coronary percutaneous coronary interventions (PCI), 20% in saphenous venous graft (SVG) intervention and up to 26% in primary PCI in acute myocardial infarction (AMI) (3). According to an article published in European heart journal, no-reflow has been described in up to 60% of STEMI patients undergoing primary PCI even after optimal coronary vessel reperfusion (4).

The mechanism of no-reflow is complex, multifactorial and the following theories could partially explain it:

A) Ischemia injury:

No-reflow starts to develop with occurrence of myocardial ischemia, which is defined as myocardial tissue blood flow less than 40 mL/min for 100 g of tissue and this in turn leads to irreversible cardiomyocyte and endothelial damage (5). At the endothelial level, bleb formation and endothelial protrusion are well seen and those obstruct the microcirculation. In some cases, extravasation of erythrocytes (microvascular hemorrhage), deposits of fibrin, clumping of platelets, white blood cells and rouleaux formation of red blood cells are also observed (6).

On the other hand, endothelial cell necrosis leads to loss of vascular integrity which in turn leads to extravascular accumulation of fluid and blood

cells. This extravascular expansion provokes vascular compression and a reduction in the micro vessel lumen (7).

B) Reperfusion injury:

This is caused by the restoration of normal blood supply which is 100 mL/min for 100 gram to damaged microcirculation which in turn accelerates myocardial swelling, tissue edema, endothelial disruption and inflammation. Activated neutrophils releasing oxygen free radicals and pro-inflammatory mediators are another pathway in reperfusion injury. Also, damaged endothelial cells, neutrophils, and platelets contribute to sustained vasoconstriction of coronary microcirculation. Autonomic dysfunction as well plays a role in development of no-reflow with alpha adrenergic receptor mediated vasoconstriction of coronary microcirculation (8).

C) Endothelial injury:

Endothelial injury is regulated by several growth factors but the most important one is the vascular endothelial growth factor (VEGF). Myocardial ischemia dissociates the VEGF receptor 2/ VE-cadherin complex, leading to an increase in endothelial permeability. In experimental models, vascular permeability plays main role in development of no-reflow (9).

D) Distal atherothrombotic embolization:

Primary PCI is usually performed in setting of high thrombus burden and manipulations during the procedure leads to distal embolization of microthrombi and plaque components (10). Distal embolization is one of the main contributing factors for development of no-reflow. As a result, use of aspiration catheters and thrombectomy devices is one of the protective mechanisms specially in presence of high thrombus burden (11).

Therefore, based on these underlying mechanisms, no-reflow can be classified into two main categories, structural and functional no-reflow (Figure 1) (12).

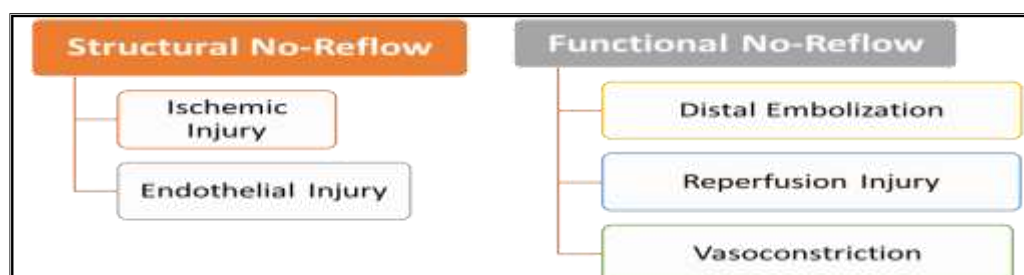


Figure (1): Classification of different types of no-reflow (12).

Several studies have been conducted before to identify the risk factors and predictors for development of no-reflow phenomenon (13). They showed that age >65 years, reperfusion time >6 hours, SBP on admission <100 mmHg, IABP use before PCI, a low initial TIMI flow (≤ 1), a high thrombus burden and a long target lesion were all independent predictors of the no-flow phenomenon.

Risk scoring system has been proposed as a predictor for development of the no-reflow during primary PCI. Parameters that were included in the model were age, no use of ACEI/ARB, collateral circulation, thrombus burden, diameter of target lesion, and blood glucose (14).

The renin-angiotensin system activation increases production of angiotensin II which in turn increases the vascular resistance and myocardial oxygen demand. Accordingly, Use of ACEI and ARBs inhibits these downstream hazardous pathways (15).

Clinical Impact of no-reflow phenomenon:

Considerable number of patients with ST elevation has impaired myocardial reperfusion despite opening the culprit vessel, restoration of epicardial blood flow and absence of in situ thrombosis or vasospasm (16). The persistence of systolic dysfunction despite opening the epicardial vessel and establishment of TIMI 3 flow after pharmacological and/or mechanical intervention for acute myocardial infarction may be explained by irreversible injury (myocardial necrosis) or by reversible injury (myocardial stunning) or a combination of both (17).

Development of no-reflow carries a poor prognosis and is associated with depressed left ventricular (LV) ejection fraction and adverse LV remodeling (18).

The phenomenon known as "No-reflow" occurs when myocardial tissue perfusion is not always restored following successful reperfusion of an infarct-related coronary artery through primary percutaneous intervention or fibrinolysis during acute ST-elevation myocardial infarction (STEMI) (16).

On short term follow up, no-reflow phenomenon has been associated in different studies with increased duration of hospitalization compared with patients without no-reflow (19). In a large study conducted on 1140 patients, no-reflow after primary PCI was associated with reduced myocardial salvage, larger infarct size, worse left ventricular ejection fraction at 6 months, and increased risk of 1 year mortality (20).

On long term follow up, development of no-reflow phenomenon during primary PCI has been

found to be a strong predictor of 5-years mortality (18).

Diagnosis of no-reflow :

Diagnosis of no-reflow starts from the clinical scenario and pass through various diagnostic modalities. Clinical presentation of the no-reflow phenomenon varies greatly depending on the clinical situation. In the catheterization laboratory, the clinical presentation of no-reflow is often sudden and dramatic where the patient complains of severe agonizing chest pain together with hemodynamic instability (21).

A) Coronary Angiography

The no-reflow phenomenon should be suspected in any situation of impaired TIMI flow after ruling out of similar situations. Spasm of the epicardial coronary arteries should be excluded by the administration of intracoronary nitroglycerine boluses (22).

In fact, the term no-reflow phenomenon emerged after observation of absence of coronary flow despite deployment of a coronary stent and opening the occluded coronary vessel. TIMI flow scale has been developed for evaluation of different coronary flow grades during PCI procedures. Flow in coronary arteries is classified as following: Grade 0 (no flow); Grade 1 (penetration without perfusion); Grade 2 (partial perfusion); Grade 3 (complete perfusion) which requires that antegrade flow distally be as rapid as antegrade flow proximally (23).

B) Cardiac magnetic resonance imaging (CMR)

Cardiac magnetic resonance imaging with gadolinium administration is the gold standard non-invasive technique for assessing microvascular obstruction (MVO) (23). Up till now, no specific guideline recommendations for the best timing or type of sequence to assess MVO by CMR are available. However, in most of the studies, CMR assessment after STEMI was usually performed between 2 and 9 days post primary PCI, as the extent of both MVO and infarction significantly increases in the first 48 hours post reperfusion. The distribution of extracellular contrast agent (gadolinium chelate) after injection reflects the state of coronary microcirculation (24).

The addition of CMR T2 weighted sequences provides important data about tissue oedema and intramyocardial hemorrhage (25). In homogenous study among STEMI patients treated with primary PCI, it has been found that late MVO was the most powerful predictor of regional and global

Left ventricular functional recovery compared with early MVO (26).

C) Other Techniques

Other diagnostic techniques may be used to confirm no-reflow diagnosis such as the

electrocardiogram, contrast echocardiography and nuclear imaging (Table 1) but because of their low sensitivity, they are rarely used in clinical practice in diagnosis of no-reflow (27).

Table (1): Other diagnostic modalities for no-reflow phenomenon:

Diagnostic Modalities for diagnosis of No-reflow phenomenon	Findings
Electrocardiography post intervention	Persistent ST-segment elevation
Dual Myocardial scintigraphy	Uptake perfusion mismatch
Myocardial Tc-99m sestamibi scintigraphy	No-reflow zone
Myocardial contrast echocardiography	Echocardiograms are obtained after IV or IC of sonicated microbubbles. The lingering of microbubbles within the myocardium indicates no-reflow.

Management of No-reflow phenomenon:

Several studies and meta-analysis have addressed the different therapeutic approaches for management of no-reflow phenomenon. However, up till now there is no universal agreement on a certain approach for management of no-reflow phenomenon. Euro Intervention has proposed an

algorithm to deal with no-reflow phenomenon in cath. lab (Fig. 2). The 2011 American guidelines for percutaneous coronary intervention is the only guidelines which have made a specific recommendations for management of this catastrophic complications (28).

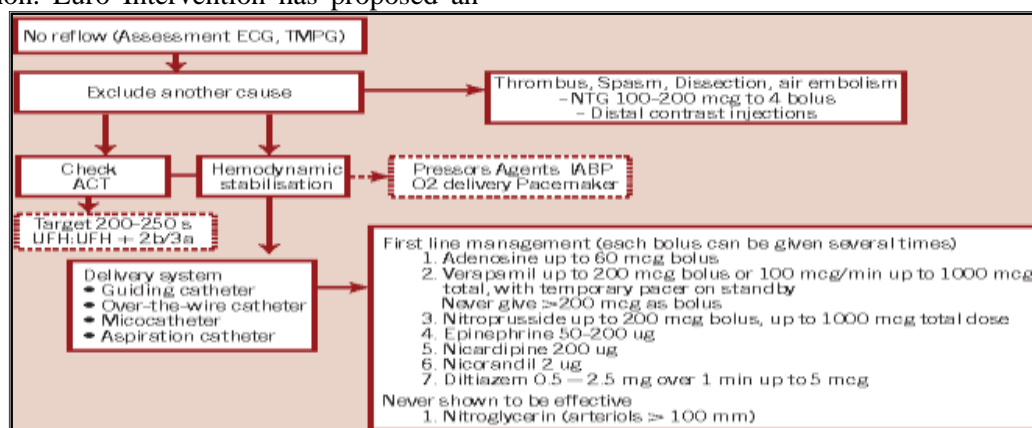


Figure (2): Check-list for management of no-reflow phenomenon (28).

Management of no-reflow starts by precautions that should be undertaken to prevent rather than treat no-reflow phenomenon. Shorter door to balloon time, optimal blood glucose and optimal blood pressure are the first steps that should be achieved to prevent no-reflow phenomenon (21).

1-Thrombus Aspiration

Thrombus aspiration has been suggested as potential solution to reduce the risk of distal embolization involved no-reflow pathophysiology. In different studies, thrombus aspiration before PCI resulted in reduction of no-reflow incidence and as a result better clinical outcomes (29). Consequently, thrombus aspiration became a routine step in primary PCI procedures until 2017 ESC guidelines for STEMI which showed that Routine use of thrombus aspiration is not recommended (Class III) (17). This

recommendation was based on Taste and TOTAL trials results which showed that only 1–5% of randomized patients crossed over from PCI alone to thrombus aspiration.

Accordingly, routine thrombus aspiration is not recommended any more. However, in cases of large residual thrombus burden after opening the vessel with a guide wire or a balloon, thrombus aspiration may be considered (28).

2-Glycoprotein IIb/IIIa inhibitors

Glycoprotein IIb/IIIa inhibitors are antiplatelets that reduce thrombotic events by inhibiting platelet aggregation and vascular clotting. INFUSE-AMI trial which was conducted on STEMI patients undergoing primary PCI showed that intracoronary injection of abciximab significantly reduced infarct size at 30 days post-MI as demonstrated by Cardiac MRI (16). On the

other hand, due to high bleeding risk, the use of Glycoprotein IIb/IIIa inhibitors should be weighted in terms of benefit and hazards. Accordingly, the 2017 ESC guidelines for STEMI stated that GP IIb/IIIa inhibitors should be considered for bailout if there is evidence of no-reflow or a thrombotic complication (Class IIa recommendation) (17).

3-Nitroprusside

The 2011 ACC PCI guidelines give a class IIa recommendation for administration of an intracoronary vasodilator (specifically, adenosine, calcium channel blocker or nitroprusside) to treat PCI-related no-reflow that occurs during primary or elective PCI (18).

Nitroprusside is one of the agents that could abort no-reflow by activation of guanylate cyclase, resulting in smooth muscle relaxation and vasodilation. Local distal administration of nitroprusside usually doesn't affect systemic blood pressure with a significant improvement in coronary flow and myocardial blush. In a small study comparing effect of nitroprusside versus nicorandil in treatment of no-reflow in patients with acute myocardial infarction, TIMI frame count was statistically significant lower in nitroprusside arm (17).

A meta-analysis published in 2014 showed that intracoronary sodium nitroprusside reduces corrected TIMI frame count, improves left ventricular function and significantly reduces incidence of MACE (28).

4-Calcium channel blockers

Verapamil therapy was beneficial in restoring coronary perfusion in animal models with coronary ischemia (18). A recent meta-analysis showed that intracoronary verapamil injection reduced the 2-month rate of major adverse events in patients who underwent PCI (29).

In particular, nicardipine was beneficial in prevention of no-reflow during rotational atherectomy and percutaneous interventions in venous grafts (28). However, up till now, published data are insufficient to validate use of calcium channel blocker as standard treatment for no-reflow and larger randomized controlled trials are still needed.

5-Adenosine

Adenosine is one of the agents recommended by ACC guidelines for management of no-reflow phenomenon. It exerts its effect through smooth muscle relaxation in the coronary microcirculation beside having antiplatelet properties (21). The beneficial effect also extended beyond

vasodilatation to a decrease in neutrophil count in the ischemic zone and relative preservation of endothelial integrity in the same areas (30).

The evidence behind use of adenosine in management of no-reflow came from AMISTAD-II trials that demonstrated a significant reduction in infarct size with high-dose adenosine (70 mg/kg/min infused for 3 h). Also, the REOPENAMI (Intracoronary Nitroprusside versus Adenosine in Acute Myocardial Infarction) trial found that ST-segment resolution at 90 minutes was markedly better in the adenosine group but not with intracoronary nitroprusside (28).

Dilemma about need for a new agent:

On the other hand, a limitation of adenosine is that it has a very short half-life. Recent data from animal models showed that a 2-h intracoronary adenosine infusion is superior to an adenosine bolus in ameliorating no-reflow. The primary concern surrounding use of adenosine is that infusion into the arterial bed supplying conduction system may result in atrioventricular block. Accordingly, adenosine can't be used in the setting of heart block, sinus bradycardia and junctional rhythm which are not uncommon during STEMI and primary PCI (28).

In addition, despite different agents used, refractory no-reflow which is defined as no-reflow that don't resolve even after using at least two agents of adenosine, verapamil and glycoprotein IIb / IIIa inhibitors still exists in large percentage among primary PCI patients.

Accordingly, the need for a new agent to be used in management of refractory no-reflow phenomenon and in the situations where adenosine is contraindicated urged many investigators to study the effect of epinephrine in no-reflow. Although epinephrine has been used clinically to treat cardiopulmonary arrest, there is a paucity of published data regarding its effectiveness in coronary no-reflow (31).

CONCLUSION

No-reflow is truly a dynamic phenomenon, delayed evaluation of MVO by CMR several days after index infarct appears to be a more valuable tool in assessing no-reflow and predicting prognosis.

Pharmacotherapy for the treatment of no-reflow had focused primarily on two strategies including local vasodilator therapy and local antiplatelet therapy.

Hence, no-reflow potentially presents an important target for investigators interested in improving outcomes in STEMI.

Conflict of interest: The authors declare no conflict of interest.

Author contribution: Authors contributed equally in the study.

References:

- 1- Scarpone, M., Cenko, E., & Manfrini, O. (2018). Coronary no-reflow phenomenon in clinical practice. *Current pharmaceutical design*, 24(25), 2927-2933.
- 2- Reffemann, T., & Kloner, R. A. (2002). The “no-reflow” phenomenon: basic science and clinical correlates. *Heart*, 87(2), 162-168.
- 2- Annibali, G., Scrocca, I., Aranzulla, T. C., Meliga, E., Maiellaro, F., & Musumeci, G. (2022). “No-reflow” phenomenon: a contemporary review. *Journal of Clinical Medicine*, 11(8), 2233.
- 3- Bouleti, C., Mewton, N., & Germain, S. (2015). The no-reflow phenomenon: state of the art. *Archives of cardiovascular diseases*, 108(12), 661-674.
- 4- Giammalva, G. R., Maugeri, R., Graziano, F., Guli, C., Giugno, A., Basile, L., & Iacopino, D. G. (2017). White cord syndrome after non-contiguous double-level anterior cervical decompression and fusion (ACDF): a “no reflow phenomenon”? *Interdisciplinary Neurosurgery*, 7, 47-49.
- 5- Reffemann, T., & Kloner, R. A. (2004). Microvascular alterations after temporary coronary artery occlusion: the no-reflow phenomenon. *Journal of cardiovascular pharmacology and therapeutics*, 9(3), 163-172.
- 6- Galasso, G., Schiekofer, S., D’Anna, C., Gioia, G. D., Piccolo, R., Niglio, T., ... & Trimarco, B. (2014). No-reflow phenomenon: pathophysiology, diagnosis, prevention, and treatment. A review of the current literature and future perspectives. *Angiology*, 65(3), 180-189.
- 7- Karimianpour, A., & Maran, A. (2018). Advances in coronary no-reflow phenomenon—a contemporary review. *Current Atherosclerosis Reports*, 20, 1-11.
- 8- Oikonomou, E., Mourouzis, K., Vogiatzi, G., Siasos, G., Deftereos, S., Papaioannou, S., ... & Tousoulis, D. (2018). Coronary microcirculation and the no-reflow phenomenon. *Current pharmaceutical design*, 24(25), 2934-2942.
- 9- Durante, A., & Camici, P. G. (2015). Novel insights into an “old” phenomenon: the no reflow. *International journal of cardiology*, 187, 273-280.
- 10- Vrints, C. J. (2009). Pathophysiology of the no-reflow phenomenon. *Acute Cardiac Care*, 11(2), 69-76.
- 11- Kloner, R. A. (2011). No-reflow phenomenon: maintaining vascular integrity. *Journal of cardiovascular pharmacology and therapeutics*, 16(3-4), 244-250.
- 12- Caiazzo, G., Musci, R. L., Frediani, L., Umińska, J., Wanha, W., Filipiak, K. J., ... & Navarese, E. P. (2020). State of the art: no-reflow phenomenon. *Cardiology Clinics*, 38(4), 563-573.
- 13- Ito, H. (2006). No-reflow phenomenon and prognosis in patients with acute myocardial infarction. *Nature clinical practice Cardiovascular medicine*, 3(9), 499-506.
- 14- Rezkalla, S. H., & Kloner, R. A. (2002). No-reflow phenomenon. *Circulation*, 105(5), 656-662.
- 15- Kloner, R. A., King, K. S., & Harrington, M. G. (2018). No-reflow phenomenon in the heart and brain. *American Journal of Physiology-Heart and Circulatory Physiology*, 315(3), H550-H562.
- 16- Kaul, S. (2014). The “no reflow” phenomenon following acute myocardial infarction: mechanisms and treatment options. *Journal of Cardiology*, 64(2), 77-85.
- 16- Ito, H. (2011). The no-reflow phenomenon associated with percutaneous coronary intervention: its mechanisms and treatment. *Cardiovascular intervention and therapeutics*, 26, 2-11.
- 17- Galiuto, L., & Crea, F. (2006). No-reflow: a heterogeneous clinical phenomenon with multiple therapeutic strategies. *Current pharmaceutical design*, 12(29), 3807-3815.
- 18- Butler, M. J., Chan, W., Taylor, A. J., Dart, A. M., & Duffy, S. J. (2011). Management of the no-reflow phenomenon. *Pharmacology & therapeutics*, 132(1), 72-85.
- 19- Ndrepepa, G., Tiroch, K., Fusaro, M., Keta, D., Seyfarth, M., Byrne, R. A., ... & Kastrati, A. (2010). 5-year prognostic value of no-reflow phenomenon after percutaneous coronary intervention in patients with acute myocardial infarction. *Journal of the American College of Cardiology*, 55(21), 2383-2389.
- 20- Wong, D. T., Puri, R., Richardson, J. D., Worthley, M. I., & Worthley, S. G. (2013). Myocardial ‘no-reflow’—diagnosis, pathophysiology and treatment. *International journal of cardiology*, 167(5), 1798-1806.

- 21- Eeckhout, E., & Kern, M. J. (2001). The coronary no-reflow phenomenon: a review of mechanisms and therapies. *European heart journal*, 22(9), 729-739.
- 22- Grayburn, P. A., & Choi, J. W. (2008). Advances in the assessment of no-reflow after successful primary percutaneous coronary intervention for acute ST-segment elevation myocardial infarction: now that we can diagnose it, what do we do about it?. *Journal of the American College of Cardiology*, 51(5), 566-568.
- 23- Pantea-Roşan, L. R., Bungau, S. G., Radu, A. F., Pantea, V. A., Moisi, M. I., Vesa, C. M., ... & Bustea, C. (2022). A narrative review of the classical and modern diagnostic methods of the no-reflow phenomenon. *Diagnostics*, 12(4), 932.
- 24- Wong, D. T., Puri, R., Richardson, J. D., Worthley, M. I., & Worthley, S. G. (2013). Myocardial 'no-reflow'—diagnosis, pathophysiology and treatment. *International journal of cardiology*, 167(5), 1798-1806.
- 25- Marra, M. P., Cacciavillani, L., Corbetti, F., Tarantini, G., Ramondo, A. B., Napodano, M., ... & Iliceto, S. (2010). The Contribution of Intramyocardial Hemorrhage to the "No-Reflow Phenomenon": A Study Performed by Cardiac Magnetic Resonance. *Echocardiography*, 27(9), 1120-1129.
- 26- Niccoli, G., Cosentino, N., Spaziani, C., Fracassi, F., Tarantini, G., & Crea, F. (2013). No-reflow: incidence and detection in the cath-lab. *Current pharmaceutical design*, 19(25), 4564-4575.
- 27- Ripley, D. P., Musa, T. A., Dobson, L. E., Plein, S., & Greenwood, J. P. (2016). Cardiovascular magnetic resonance imaging: what the general cardiologist should know. *Heart*, 102(19), 1589-1603.
- 28- Rezkalla, S. H., Stankowski, R. V., Hanna, J., & Kloner, R. A. (2017). Management of no-reflow phenomenon in the catheterization laboratory. *JACC: Cardiovascular Interventions*, 10(3), 215-223.
- 29- Villari, B., Ambrosio, G., Golino, P., Ragni, M., Focaccio, A., Tritto, I., ... & Chiariello, M. (1993). The effects of calcium channel antagonist treatment and oxygen radical scavenging on infarct size and the no-reflow phenomenon in reperfused hearts. *American Heart Journal*, 125(1), 11-23.
- 30- Grygier, M., Araszkiwicz, A., Lesiak, M., & Grajek, S. (2013). Role of adenosine as an adjunct therapy in the prevention and treatment of no-reflow phenomenon in acute myocardial infarction with ST segment elevation: review of the current data. *Kardiologia Polska (Polish Heart Journal)*, 71(2), 115-120.
- 31- Caixeta, A., Ybarra, L. F., Latib, A., Airolidi, F., Mehran, R., & Dangas, G. D. (2017). Coronary artery dissections, perforations, and the no-reflow phenomenon. *Interventional Cardiology: Principles and Practice*, 248-266.