



A REVIEW ON HERBAL AND ALLOPATHY LASER TREATMENT ON PERI ORBITAL DARK CIRCLES

Bijaya Laxmi Kand^{1*}, Swati Mishra², Sruti Ranjan Mishra³, Rama Prasad Padhy⁴, Mahendra Kumar Panigrahi⁵, Boi Basant Kumar Reddy⁶, Sitakant Patnaik⁷, Sabyasachi Samantaray⁸, M Gyanaranjan⁹

¹Assistant Professor, Department of Pharmaceutics, Danteswari college of Pharmacy, Borpadar, Raipur Road, Jagdalpur, Chhattisgarh, India

²Assistant Professor, Department of Pharmaceutics, Danteswari college of Pharmacy, Borpadar, Raipur Road, Jagdalpur, Chhattisgarh, India

³Professor cum Principal, Department of Pharmaceutics, Danteswari college of Pharmacy, Borpadar, Raipur Road, Jagdalpur, Chhattisgarh, India

⁴Professor cum Vice Principal, Department of Pharmachemistry, Danteswari college of Pharmacy, Borpadar, Raipur Road, Jagdalpur, Chhattisgarh, India

⁵Professor, Department of Pharmacognosy, Danteswari college of Pharmacy, Borpadar, Raipur Road, Jagdalpur, Chhattisgarh, India

⁶Assistant Professor, Department of Pharmaceutics, Danteswari college of Pharmacy, Borpadar, Raipur Road, Jagdalpur, Chhattisgarh, India

⁷Assistant Professor, Department of Pharmacognosy, Danteswari college of Pharmacy, Borpadar, Raipur Road, Jagdalpur, Chhattisgarh, India

⁸Assistant Professor, Department of Pharmaceutics, Danteswari college of Pharmacy, Borpadar, Raipur Road, Jagdalpur, Chhattisgarh, India

⁹Assistant Professor, Department of Pharmacognosy, Danteswari college of Pharmacy, Borpadar, Raipur Road, Jagdalpur, Chhattisgarh, India

* Corresponding Author Email id: bijayalaxmikand0622@gmail.com

Article History: Received: 10/04/23

Revised & Accepted: 25/05/23

Published: 25/05/23

ABSTRACT:

Dark circles indicate the pigment muscle below the eye. Due to the thin layer of skin tissues around the eye and its significant cosmetic problem that concern for both the male and female patients is the reason for dark circles. Hyper pigmentation, Dermal melanin deposition, Periorbital edema, Superficial location of vasculature, hypersensitive contact dermatitis Tear trough depression are the reason for dark circles. laser therapy, Hyaluronic acid soft-tissue fillers, Fat autologous muscle injection, chemical peels, bleaching creams, topical retinoic acid, a large amount of topical therapy and creams to relieve dark circles are available for treating of dark circle. Many dosage form are available cream, gel, patches, emulsion many herb are also used for the treatments for periorbital dark circles.

Keyword: Dark circle, Hyperpigmentation, Dermal Melanin Deposition, Herbal Treatment, Hyaluronic acid soft tissue-filler, Laser technique.

DOI: 10.48047/ecb/2023.12.Si8.818

INTRODUCTION:

The term “dark circles under the eyes” is non a remedial term, but it is commonly use by many persons to refer to the pigmented muscles under the eyes (1). The membrane around the senses appears dark as the skin tissue below and upper the eyes is more tinny. As the skin aged, the fat layer below the eyes drops and swells, creating dark circles and darkening the eye area (2). Dark circles around the eye socket, specifically a condition in which darkening under the eyes is observed. It is an aesthetic problem that affects both male and female patients of all ages and ethnicities (3) Peri orbital dark circle involves that the relative darkness around the eyelids. Peri orbital dark circles is significant a cosmetic complication and for this many individual treatments look for condition (4). Cosmetic complication that are not a health threatening condition but it’s associated with remarkable morbidity that personality’s emotive effect life the gain increase attention. peri orbital dim loop is a order that significant female patients for beautifying concern (5). The circumstances that create dark circles under the eyes result in a worn-out, down or hungover appearance. Generally weakness and nonexistence of sleep make dim loop worse (6). There are many periorbital complications: dark circles under the eyes, lower eyelid swelling, infraorbital darkening, periorbital hyperpigmentation, melanotic deposits around the eyes and periorbital excessive colouration is a communal skin state that manifests as a dim area around the orbit below the inferior eyelids (7). This condition is identified by cutaneous melanotic incontinence, hyper melanized basal and inferior malphygia with improved melanin granules, perivascular lymphocytic infiltration, and diffuse cutaneous melanophages. In maximum cases, hemispherical, homogeneous, dim brown spots and spots appear near the orbits, but sometimes they are enlarged toward the superior eye lids, eye brows, and cheek region(8).Near 78 percentage of the world's people suffer from periorbital hyperpigmentation. A large number of cases occur in African and Asian countries (9).



Fig.1 (10)

Characteristics of the extent of dark circles below the eyes (0-5)

0: periorbital hyper pigmentation is not visible.

- 1: In the front of eye and below the eyes observed Faint purple colour. When the dermal under eye is drawn with hand the colour of under eye darkens and cause dark circles.
- 2: If the skin is not drawn with hand, A purple colour is visible visibly and Minor hyper coloration may be situated.
- 3: Under the eye show deep purple shadows and moderate pigmentation.
- 4: unchanging and darken colouration is show and irregularly both the upper and under the eyes.
- 5: upper and below the eyes is observed Uniform and very dark pigmentation (11).

CAUSES:

Peri orbital appear due to overweening shade owing to melanin precipitate, vasodilation and arterial balance, thin membrane of the eyelids and organizational features of the eye area (12,13,14). It can be shown by the elderly process, because when the skin age thinner and altered subcutaneous fat distribution Peri orbital appear owing to extreme tone melanin sediment, vasodilation and blood balance, thin membrane of the eyelids and organizational features of the eye zone. It can be shown by the elderly development, because when the skin aging thinner and changed subcutaneous fatty distribution (3,10,12,13,14,15,16)

Hyper pigmentation

Deep coloration is an sunshade term that contains multicoloured skin staining, colouration and dark allied complaints. excitable shade is a skin related condition. Where the colouration of the membrane normally becomes over shadow. Due to the internal changes and external changes like hormonal changes, swelling, scratch, acne, eczema, certain medicaments, tanning exposure(17). the skin colouring can be changed by consanguineous process The Skin shade and colouration are governed and it's relating the yield of the membrane stain called melanin produced through melanocytes in multicoloured coatings of skin. The produce of melanocytes difference and melanin distribution cause hyperpigmentation ailments in the skin (18) The multi colouration is common observance of hyperpigmentation conditions include Constitutional, post incendiary hyperpigmentation, Vascular, Shadow effect, mixed (19,20).

Constitutional- These include the observation of a dim brown toward dark curved band in the membrane of the inferior eyelids, approximating in shape the orbital rims, and often associated with the fusion of the upper eyelids (21).

Post inflaming- It involve the existence of unbalanced patches of dim brown or grey patches on epidermis and subcutaneous tissue of both eyelids with lichenified eczema around the eye zones. it is a common type of pigmentation and America and European countries 38.31 percentages of hyper pigmentation is found (21,22).

Vascular- vascular pigments cause the formation of bluish stain under eyelids and appear green-blue veins appear that which are due to excess prominent on stretching on the upper part of skin around the eye (23). erythema mainly affecting the innermost surface of inferior eyelids, with prominent tubes or telangiectasia. with a tinny and radiant membrane and cause dark

circles. vascular type of pigmentation 42.3% percentages is found in two countries African and Asian (21,22).

Shadow - The shadow consequence is involving in the occurrence of a broad lacrimal depression on the medial side of orbital below the edge, which disappears in presence of direct illumination. There is a darken effect due to organizational anatomical factors like loose tarsal muscle, sense bags or large lacrimal grooves the darken effect arise (21,22).

Mixed- It include the existence of dark circles under eye with colour of blue, purple or brown of puffiness connect with the palpebral bags, blepharoptosis that loss of fat in the bony fame (22).

Others - Some other hyperpigmentation are Internal disorders, skin disease and Drugs the Internal disorders like as low blood, hormonal altercation, nutrient lack. skin disease such as Acanthosis nigricans, skin sagging, nevus octa, nevus hori, erythema dyschromic persistents, static medication eruption Medications like latanoprost and bimatoprost eye drops (21).

Dermal melanin deposition

Puffiness is cause by the thickness of the dermis, which heightened incidence of stray light that replication from the pigments, resulting the darkness is improved below the skin under eyelids. have positively treated of periorbital pigmentation with a carbon dioxide laser, with no any consistent upgrading in melanin spectrometry interpretations. the effectiveness of the carbon dioxide laser depend on the skin narrowing of dermal tissues and development of the skin superficial texture, causing the Tyndall outcome below the eye zones (24).

Periorbital edema

The lid zone should have a spongy characteristics which is said to supports the fluid accumulation in systemic or local edema states. The Analytical identify that the junction of eyelid fluid include a dropping in the morning or later a briny meal, the purple colour, and the approximate curvatures of the fatty area complements. history of inconsistency over the strength and expansion are necessary to categorized about the effect of edema . a comparison to a normal orbital fat, and puffiness the puffiness is still existent downcast gaze and does not changing when looking up-gaze(25).

Allergic contact dermatitis

On contact with an allergic dark circles appear under the eye zones .it is individually prevalent allergic are thought to cause by the population. Rubbing and scraping of the membrane of the eye socket due to fluid developments is presence of facial allergy(26,27).

Shallow location of vasculature

As patients grownup, damage of the periorbital subcutaneous fatty and membrane atrophy can lead to opening of the detour vasculature. The blue colour is inferior part to the skin perceptible dermal vessel chain and cause dark circles below the eye zones (28).

Tear troughing depression

The lacrimal depression is the depression in the medial of the inferior rim orbital middles. in older patients lacrimal depression grow because the fatty area of eye is expatriate anteriorly, creating shadow is created and the depend on the light conditions (29).The condition intensifies with aging of the upper and lower eyelid and midline face ,so that there is harm of subcutaneous overweight with tinny of the skin under eye marginal ligaments which joint with buccal depression gives the orbital area a darken appear (25).

Shadowing Outcome

Laxity and capacity loss of the Periorbital skin with atrophy of the subcutaneous fat that from early age accumulation and chronic photodamage. These features, together with the oblique oculi muscles hypertrophy, pseudo herniation of sub oblique ocular fibroadipose muscle, and the capacity damage of the malar audacity, produce a shadow effect on the lacrimal. This shadow is depend on the lighting, the mask with the application of direct flash pictures(30).

Dark circles also caused by blood leakage in the capillaries under the eyes. Because the skin of the eye is very soft and tinny, leakage blood from the capillaries forms a clot below the eye and becomes prominent. But the body has a protective mechanism to get rid of this fragment. It is very difficulty to treat this condition because many factors are include to worse. Like increasing age, this condition becomes serious. As a result the dark circles patients look sad, tired that will affect their personality. there are so Many possible factors that can cause peri orbital dark circles, infections, hyper sensitive blood, dermal melanin deposition. Physical stress and mental stress, involves menstrual periods and, excessive pigmentation, inflammation, lifestyle elements, observation due to tear troughing, shade due to infraorbital laxity and wrinkles, congestion of the eyelid, excessive sunlight exposure, poor diet, lack of sleep, mental stress, excessive rubbing, due to deficiency of pregnancy, It may lead to dark circles obtain under the eye (31,32).

TREATMENT AVAILABLE:

The first step of the therapy is based on the pass medicinal and medical examination to detect the components or reason of dark circles.

A Figure of treatment and medication are applicable for treating peri orbital dark circles, The therapeutic modalities depend up on the cause as peri orbital dim loop are cause due to the numerous reasons(33). The availability treatment of dark circles are laser therapy, chemical peels, bleaching creams, topical retinoic acid (34). There are a large numeral of topical medications and emulsions to decrease dim loops are available (28).

In Topical Therapy: The Topical agents are broadly used for therapy or manage of hyper pigmentation and various formulated topical dosage forms are available likes creams, gels, etc (35). Oral Treatments is a another treatment for excessive pigmentation and Tranexamic acid (36,37). Minifat, emulsifie fat, nanofat, and nano gel fat are the end products formulation which applicable in the treating of dark circles (38).

Chemical agent Peeling

Chemical agents peeling is known as the applicable of additional reagents that lead to control the destruction of membrane, that remove of dark circles which located in the lower dermis or in the superior dermis. This care can be fewer or more depend according to the healing intent and the kind of reagents peeling used. reagent Peels can accessible in shallow, medium, or bottomless (39).

Hyaluronic acid soft-tissue fillers

Hyaluronic acid soft fillers are a injectable marketed which stays to expand quickly. Accordance to the American Civilization of Dermatologic Surgery ,In 2012 approximately 1 million filler mainly Hyaluronic acid technique performed by dermatological surgeons, 10.4 percentage increase over the last 40 year. The use case minimal occurrence of difficulties, and down time connected with these products that build them model for treatment peri orbital volume damage. The biocompatibility Hyaluronic acid of across all species also protections in contradiction of hypersensitivity reactions. Hyaluronic acid base soft fillers have demonstrat 85% to 89% shown in patient fulfilment after 1 to 3 sessions (41,42).

Laser technique



Fig. 2 Improvement of laser techniques (43).

Laser technique is most effective therapy for removing of dim colour under the eye skin dark circle. The various factors of dark circles are excessive melanin secretion, ridge, and fine lines these all problem can be treated by using laser technique. The most physician prefer this technique of removing dark circles. There are different types of laser therapy are available for peri orbital are Q switched laser, fractional laser, radiofrequency devices, and pulse-dye lasers. There are multiple Q switched lasers available for removal dark circles (43).

Fat autologous muscle injection

Autologous muscles fat injection is involve in injecting slight amount of fat within or attached facial muscles to facial transformation this is a process called as injection an autologous fat implant muscle (44). After fat grafting the cosmetic results are likely to be a mixture of adipocyte existence in the interior high circulating recipient locations system and hypodermal fibrosis in response to the graft adipose tissue (45). The result, which shown in 10 patients with fatty tissue carry in the below of eye loops due to thin, glowing skin showed an average 78% development in inferior eye zone stain and curve (46). Naturally approximately about 1 to 1.5 ml of centrifuged fat is mandatory for each infra orbital area. Autologous fat transfer, though while effect, it has a detrimental effect on variable taken of the inserted fat tissue. This can lead to excess fat around the eye, which resulting clinically palpable or perceptible swellings. In addition of transfer fat can be classified as

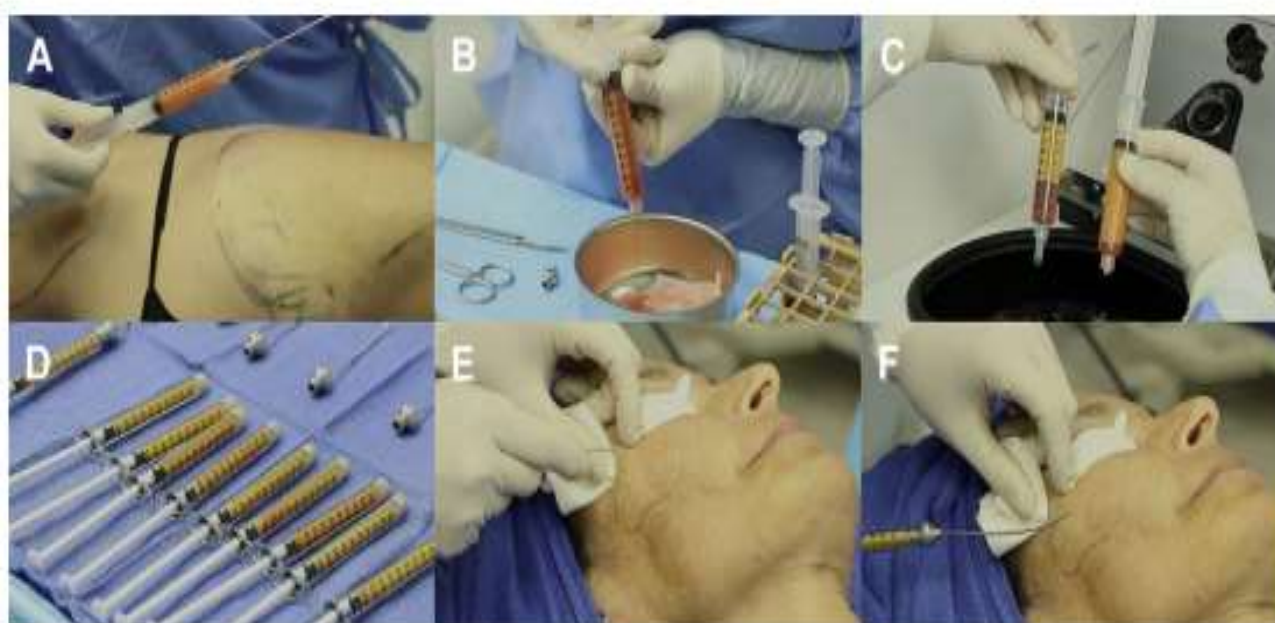


Fig. 03(Fat harvester) (47).

(A) Extra weight is collected from the completely tumesced fat contributor by applying a 12-gauge Klein finesse needle attached to a 10 ml syringe, negative compression is created physically by pull back on the plunger.

(B) Fatty hypodermic syringes are taken to allow the separation of the liquid fat from the scraped fat and oil fractions,

(C) Then centrifuge the fat for 3 minutes at 3600 revolutions per minute and discard the supernatant.

(D) Fatty amount was transferred to 1 ml syringes.

(E) The puncture site with an awl or non-coring pointer on the side midline of the cheek at the bony detour rim is preferred to target the peri-orbital part of the oblique oculi muscle located

in the upper and below eyelids and the overlying subcutaneous plane. The initial treatment of nerve fibers piece are take place at rank of the peri orbital opening.

(F) Aliquot part of fat are injected in backward mode at low injection compression by using a curve, blunt tip cannula. (47).

HERBAL TREATMENTS:

Hyaluronic acid

Hyaluronic acid is an extract on lotus root, carrots, potatoes. In 2019 Agarwal was conducted a dual-blind, controlled clinical trial by taking 12 patients with hyper pigmentation. The patients were instructed to topically applying 1 percentage hyaluronic acid gel topically two time regularly for four weeks. They were subsequent notice and identify the change in colour, light lines and skin discolouration by using ten point scale. This therapy was result that reduced the peri orbital dark circles and shadow light lines, ridge with first healing of injure and first rate tear contour outline improvement in all patients, 26 percentage dark circles development can be observed under differentiate to the base line readings (48). Hyaluronic Acid has been detail to improve dim skin and favorable for all dermis types, that include hyper sensitive skin, prone redness of skin and skin liable to blemished (49).

Alpha-Arbutin

Alpha Arbutin can be extract from the bear berry shrub, cran berry and blue berry. In 2008 Ertam et al was conducted A arbitrary, prospective, open-docket study. on 10 melasma subjects taken. 3% of them is alpha arbutin gel was appeal over the skin to 5 patients to gel placebo are Apply to last 5 patients. The performance of placebo gels are apply one time in a day for 1 month. It should be notice the evaluated of change in skin colourance, presence of hyper pigmentation by using Mexamerica index at the final point of therapy period. significantly About 3 percentages arbutin gel reduced the discolouration as 43.5% comparism to 7.1% in placebo group It was found in the Therapy (50). The combination of α -arbutin with vitamin c contain compound are more affectable for the visibility of bright the look of skin(51)

Tyrosinase inhibitor

Azelaic acid can be gained from cereal, wheat and rye whiskey grain. In 2011 kircik conducted a clinical trial study.A randomized dual-blind study in where 30 adults moderate were taken to severe melasma, 15 of them received 15% w/v gel azelaic acid and the remain 15 patient 4% gel hydroquinone. The performance gel placebo were used topically two time per day for four months. by using of Melasma zone and Severity Index , evaluate the patient at break of one month. It indicate that therapy with 15 percentage of gel azelaic acid which improved the MASI score 48.4% compare toward 46.7% in gel hydroquinone treatment group (52).

Turmeric

from turmeric the Curcumin is obtained. In 2010 Majeed was conducted A randomized, dual-shade, placebo-control comparative learning by taking 50 pateint with post-inflammatory disorders, excessive pigmentation, wherein 0.25% turmeric cream 25 subjects and 4% cream

hydroquinone 25 subjects were topically apply two time daily for four weeks. by Mexamerica index They were evaluated. The result indicate that cream curcumin reduced the dark as different to hydroquinone cream healing group. Cream Turmeric was resulted to reduce inflammation, discoloration and lines on the rough skin (53).

Tomato

Lycopene is a tomato extract. In 2011 Wanick et al was a clinical trial study. while 68 patients were taken of burning induced melasma capsules they receive lycopene 5 percentage to be taken two time in every day for 12 weeks.as a result that Lycopene has been found to the develop skin hydration ,texture and resistance of the skin . Intracellular organelles transfer inhibitor- the inhibits that transport of melanosome build from melanocytes to keratinocytes, where stain deposition is reducing the in keratinocytes so that the pigmentation change (54).

Niacinamide

Niacinamide is found in pumpkin and peanuts. In year 2002 Hakozaiki organized an open-label study, in which 18 patient were selected with pigmentation and treated them topically application of 5% niacinamide cream for four weeks and notice the colour changes (55).

Retinoic acid

Retinoic acid is found in meat protein fish, eggs, full-fat milk and avocado oil. In 2006 Ortonne conducted a study on the brightness of retinoic acid (56).

Beta-carotene pigment

Beta-carotene pigment is found in fruit and vegetables like carrot, seed of sunflower , seaweed, chicory root and mango butter.in 2002 The Kar was direct An open clinical trial. where 26 ladies and 5 adult males were taken with reasonable to severe melasma. Beta-carotene lessen flakes, restore flexibility and develop the appearance of harm dermic noted (57).

Conclusion

The multifactor are reason behind Dark circles under the eye zone so it is mandatory identify the reason previously treatment and chosen a simplified way To accurate diagnosis to get a good, safe, and actual treatment. There are different therapy are available for the therapy of blue, black, brown, purple appear below the eye. peels a topical bleaching agent,surgery, chemical laser therapy, fat injection, or fillers can used to develop this condition. Many dosage form are available for its treatments herbal therapy also to lighting the skin below eye.it is clinically proved that many herbal product lighting the skin.

REFERENCES

1. Watanabe S, Nakai K, Ohnishi T. Condition Known as “Dark Rings Under the Eyes” in the Japanese Population is a Kind of Dermal Melanocytosis Which can be Successfully Treatedby Q-Switched Ruby Laser. *Dermatologic surgery*. 2006 Jun;32(6):785-9.
2. Roh MR, Chung KY. Infraorbital dark circles: definition, causes, and treatment options. *Dermatologic surgery*. 2009 Aug;35(8):1163-71.

3. Friedmann DP, Goldman MP. Dark circles: etiology and management options. *Clinics in plastic surgery*. 2015 Jan 1;42(1):33-50.
4. Yaar M, Gilchrist BA. Skin aging: postulated mechanisms and consequent changes in structure and function. *Clinics in geriatric medicine*. 2001 Nov 1;17(4):617-30.
5. Balkrishnan R, McMichael AJ, Camacho FT, Saltzberg F, Housman TS, Grummer S, Feldman SR, Chren MM. Development and validation of a health-related quality of life instrument for women with melasma. *British Journal of Dermatology*. 2003 Sep 1;149(3):572-7.
6. Freitag FM, Cestari TF. What causes dark circles under the eyes?. *Journal of cosmetic dermatology*. 2007 Sep;6(3):211-5.
7. Roh MR, Chung KY. Infraorbital dark circles: definition, causes, and treatment options. *Dermatologic surgery*. 2009 Aug;35(8):1163-71.
8. Sarkar R, Ranjan R, Garg S, Garg VK, Sonthalia S, Bansal S. Periorbital hyperpigmentation: a comprehensive review. *The Journal of clinical and aesthetic dermatology*. 2016 Jan;9(1):49.
9. Kumar R, Sharma MK, Jain SK, Yadav SK, Singhal AK. Cutaneous manifestations of chikungunya fever: observations from an outbreak at a tertiary care hospital in Southeast Rajasthan, India. *Indian dermatology online journal*. 2017 Sep;8(5):336.
10. Park SR, Kim HJ, Park HK, Kim JY, Kim NS, Byun KS, Moon TK, Byun JW, Moon JH, Choi GS. Classification by causes of dark circles and appropriate evaluation method of dark circles. *Skin Research and Technology*. 2016 Aug;22(3):276-83.
11. S. R. Park¹, H. J. Kim¹, H. K. Park¹, J. Y. Kim¹, N. S. Kim¹, K. S. Byun¹, T. K. Moon¹, J. W. Byun², J. H. Moon² and G. S. Choi² ¹ Ellead Skin and Bio Research, Gyeonggi-do, Korea and ² Department of Dermatology, Inha University College of Medicine, Incheon, Korea
12. Mac-Mary S, Zornoza Solinis I, Predine O, Sainthillier JM, Sladen C, Bell M, O'Mahony M. Identification of three key factors contributing to the aetiology of dark circles by clinical and instrumental assessments of the infraorbital region. *Clinical, Cosmetic and Investigational Dermatology*. 2019 Dec 18:919-29.
13. Matsui MS, Schalka S, Vanderover G, Fthenakis CG, Christopher J, Bombarda PC, Bueno JR, Viscomi BL, Bombarda Júnior MS. Physiological and lifestyle factors contributing to risk and severity of peri-orbital dark circles in the Brazilian population. *Anais brasileiros de dermatologia*. 2015 Jul;90:494-503.
14. Agrawal S. Periorbital hyperpigmentation: Overcoming the challenges in the management. *Nepal Journal of Dermatology, Venereology & Leprology*. 2018 Mar 29;16(1):2-11.
15. Vrcek I, Ozgur O, Nakra T. Infraorbital dark circles: a review of the pathogenesis, evaluation and treatment. *Journal of cutaneous and aesthetic surgery*. 2016 Apr;9(2):65.
16. Huang YL, Chang SL, Ma L, Lee MC, Hu S. Clinical analysis and classification of dark eye circle. *International journal of dermatology*. 2014 Feb;53(2):164-70.
17. Perez-Bernal A, Munoz-Perez MA, Camacho F. Management of facial hyperpigmentation. *American journal of clinical dermatology*. 2000 Sep;1:261-8.

18. Rossi AM, Perez MI. Treatment of hyperpigmentation. *Facial Plastic Surgery Clinics*. 2011 May 1;19(2):313-24.
19. Katsambas A, Antoniou CH. Melasma. Classification and treatment. *Journal of the European Academy of Dermatology and Venereology*. 1995 Jun 1;4(3):217-23.
20. Handel AC, Miot LD, Miot HA. Melasma: a clinical and epidemiological review. *Anais brasileiros de dermatologia*. 2014 Sep;89:771-82.
21. Handel AC, Miot LD, Miot HA. Melasma: a clinical and epidemiological review. *Anais brasileiros de dermatologia*. 2014 Sep;89:771-82.
22. Bobdey S, Jain A, Balasubramaniam G. Epidemiological review of laryngeal cancer: An Indian perspective. *Indian Journal of Medical and Paediatric Oncology*. 2015 Jul;36(03):154-60.
23. Sarkar R, Ranjan R, Garg S, Garg VK, Sonthalia S, Bansal S. Periorbital hyperpigmentation: a comprehensive review. *The Journal of clinical and aesthetic dermatology*. 2016 Jan;9(1):49.
24. West TB, Alster TS. Improvement of infraorbital hyperpigmentation following carbon dioxide laser resurfacing. *Dermatologic surgery*. 1998 Jun;24(6):615-6.
25. Goldberg RA, McCann JD, Fiaschetti D, Simon GJ. What causes eyelid bags? Analysis of 114 consecutive patients. *Plastic and reconstructive surgery*. 2005 Apr 15;115(5):1395-402.
26. Marks MB. Recognizing the allergic person. *American Family Physician*. 1977 Jul 1;16(1):72-9.
27. Marks MB. Allergic shiners: dark circles under the eyes in children. *Clinical pediatrics*. 1966 Nov;5(11):655-8.
28. Manuskiatti W, Fitzpatrick RE, Goldman MP. Treatment of facial skin using combinations of CO₂, Q-switched alexandrite, flashlamp-pumped pulsed dye, and Er: YAG lasers in the same treatment session. *Dermatologic surgery*. 2000 Feb;26(2):114-20.
29. Kane MA. Treatment of tear trough deformity and lower lid bowing with injectable hyaluronic acid. *Aesthetic plastic surgery*. 2005 Oct;29:363-7.
30. Sadick NS, Bosniak SL, Cantisano-Zilkha M, Glavas IP, Roy D. Definition of the tear trough and the tear trough rating scale. *Journal of Cosmetic Dermatology*. 2007 Dec;6(4):218-22.
31. Freitag FM, Cestari TF. What causes dark circles under the eyes?. *Journal of cosmetic dermatology*. 2007 Sep;6(3):211-5.
32. Roh MR, Chung KY. Infraorbital dark circles: definition, causes, and treatment options. *Dermatologic surgery*. 2009 Aug;35(8):1163-71.
33. Roh MR, Chung KY. Infraorbital dark circles: definition, causes, and treatment options. *Dermatologic surgery*. 2009 Aug;35(8):1163-71.
34. West TB, Alster TS. Improvement of infraorbital hyperpigmentation following carbon dioxide laser resurfacing. *Dermatologic surgery*. 1998 Jun;24(6):615-6.
35. Haddad AL, Matos LF, Brunstein F, Ferreira LM, Silva A, Costa Jr D. A clinical, prospective, randomized, double-blind trial comparing skin whitening complex with

- hydroquinone vs. placebo in the treatment of melasma. *International journal of dermatology*. 2003 Feb;42(2):153-6.
36. Cho HH, Choi M, Cho S, Lee JH. Role of oral tranexamic acid in melasma patients treated with IPL and low fluence QS Nd: YAG laser. *Journal of Dermatological Treatment*. 2013 Aug 1;24(4):292-6.
 37. Kato H, Araki J, Eto H, Doi K, Hirai R, Kuno S, Higashino T, Yoshimura K. A prospective randomized controlled study of oral tranexamic acid for preventing postinflammatory hyperpigmentation after Q-switched ruby laser. *Dermatologic surgery*. 2011 May;37(5):605-10.
 38. Vestita M, Bonamonte D, Ciancio F, Perrotta R, Nacchiero E, Giudice G. Nanofat+ Prp Vs Prp in Androgenic Alopecia. An Intra-Patient Case-Control Study. *Plastic and Reconstructive Surgery–Global Open*. 2018 Sep 1;6(9S):42-3.
 39. Taylor SC. Skin of color: biology, structure, function, and implications for dermatologic disease. *Journal of the American Academy of Dermatology*. 2002 Feb 1;46(2):S41-62.
 40. Sarwer DB, Spitzer JC, Sobanko JF, Beer KR. Identification and management of mental health issues by dermatologic surgeons: a survey of American Society for Dermatologic Surgery members. *Dermatologic Surgery*. 2015 Mar 1;41(3):352-7.
 41. Goldberg RA, Fiaschetti D. Filling the periorbital hollows with hyaluronic acid gel: initial experience with 244 injections. *Ophthalmic Plastic & Reconstructive Surgery*. 2006 Sep 1;22(5):335-41.
 42. Morley AM, Malhotra R. Use of hyaluronic acid filler for tear-trough rejuvenation as an alternative to lower eyelid surgery. *Ophthalmic Plastic & Reconstructive Surgery*. 2011 Mar 1;27(2):69-73.
 43. Park JM, Tsao H, Tsao S. Acquired bilateral nevus of Ota-like macules (Hori nevus): etiologic and therapeutic considerations. *Journal of the American Academy of Dermatology*. 2009 Jul 1;61(1):88-93.
 44. Butterwick KJ. Fat autograft muscle injection (FAMI): new technique for facial volume restoration. *Dermatologic surgery*. 2005 Nov;31:1487-95.
 45. Butterwick KJ, Nootheti PK, Hsu JW, Goldman MP. Autologous fat transfer: an in-depth look at varying concepts and techniques. *Facial Plastic Surgery Clinics*. 2007 Feb 1;15(1):99-111.
 46. Roh MR, Kim TK, Chung KY. Treatment of infraorbital dark circles by autologous fat transplantation: a pilot study. *British Journal of Dermatology*. 2009 May 1;160(5):1022-5.
 47. Mandal S, Vishvakarma P. Nanoemulgel: A Smarter Topical Lipidic Emulsion-based Nanocarrier. *Indian J of Pharmaceutical Education and Research*. 2023;57(3s):s481-s498.
 48. Mandal S, Jaiswal DV, Shiva K. A review on marketed Carica papaya leaf extract (CPL) supplements for the treatment of dengue fever with thrombocytopenia and its drawback. *International Journal of Pharmaceutical Research*. 2020 Jul;12(3).
 49. Donofrio LM. Technique of periorbital lipoaugmentation. *Dermatologic surgery*. 2003 Jan;29(1):92-8.

50. Agarwal M. Treatment of dark circles with the new 15 mg/ml hyaluronic acid filler with lidocaine. *Indian Dermatology Online Journal*. 2019 Jul 1;10(4):471-2.
51. Sarkar R, Ranjan R, Garg S, Garg VK, Sonthalia S, Bansal S. Periorbital hyperpigmentation: a comprehensive review. *The Journal of clinical and aesthetic dermatology*. 2016 Jan;9(1):49.
52. Ertam I, Mutlu B, Unal I, Alper S, Kivcak B, Ozer O. Efficiency of ellagic acid and arbutin in melasma: A randomized, prospective, open-label study. *The Journal of dermatology*. 2008 Sep;35(9):570-4.
53. Roh MR, Chung KY. Infraorbital dark circles: definition, causes, and treatment options. *Dermatologic surgery*. 2009 Aug;35(8):1163-71.
54. Kircik LH. Efficacy and safety of azelaic acid (AzA) gel 15% in the treatment of post-inflammatory hyperpigmentation and acne: a 16-week, baseline-controlled study. *Journal of drugs in dermatology: JDD*. 2011 Jun 1;10(6):586-90.
55. JOHANNES dAyRIT MD, MD CA. A randomized, double-blind, placebo-controlled, comparative study.
56. Wanick FB, Zink BS, Lopes RF. Efficacy of lycopene, beta-carotene and *Lactobacillus johnsonii* in the maintenance treatment of melasma during the summer. *Surg Cosmet Dermatol*. 2011;3(4):297-301.
57. Wanick FB, Zink BS, Lopes RF. Efficacy of lycopene, beta-carotene and *Lactobacillus johnsonii* in the maintenance treatment of melasma during the summer. *Surg Cosmet Dermatol*. 2011;3(4):297-301.
58. Ortonne JP. Retinoid therapy of pigmentary disorders. *Dermatologic therapy*. 2006 Sep;19(5):280-8.
59. Kar HK. Efficacy of beta-carotene topical application in melasma: an open clinical trial. *Indian journal of dermatology, venereology and leprology*. 2002 Nov 1;68:320.