



## AN OVERVIEW ABOUT INTRAVENOUS DRUG ABUSE INFECTIVE ENDOCARDITIS

Ahmed Said Eldamanhory, Abdelsalam Elsayed Hussin Sherif, Ahmed Morsi  
Hasan Salamah, Mahmoud Abdelaziz Abdelrashid

Cardiology Department, Faculty of Medicine, Zagazig University

Email: [ahmedmoursiafifi@gmail.com](mailto:ahmedmoursiafifi@gmail.com)

**Article History:** Received 10<sup>th</sup> June, Accepted 5<sup>th</sup> July, published online 10<sup>th</sup> July 2023

---

### Abstract

Infective endocarditis is defined as infection of the cardiac endothelium, seen as vegetations that threatens life despite the progress of modern medical and surgical therapy. The mortality rates of this disease ranges from 20% to 30% for both native and prosthetic valve endocarditis (PVE) and may increases to reach 70% in certain high-risk patients. The clinical diagnosis based on multiple elements, and best managed via collaboration among cardiologists, cardiothoracic surgeons, and infection disease specialists. The diagnosis of infectious endocarditis requires multiple clinical, laboratory, and imaging findings. The widely accepted Duke criteria use a set of major and minor clinical and pathologic criteria to classify infectious endocarditis as definite, possible, or rejected. IE is one of the life-threatening complications of parenteral drug abuse as it affects intravenous drug abusers (IVDUs) by a ratio ranging from 2% to 5% annually. In addition, it is the reason for 5% to 20% of hospitalized cases and 5% to 10% of the overall mortality rate. IVDUs often develop recurrent IE. Right side infective endocarditis has been mainly defined among IVDUs. The infective endocarditis epidemiology has changed recently, which reflects the social climate of IV drug use. This changing epidemiology changed in turn the standard treatments for this type of infection. It requires a more holistic study to shed light on the diverse needs of this clinical population. The rate of right-heart IE occurrence among IVDU may vary from 0.7 to 13/1000 patient annually.

**Keywords:** Intravenous Drug Abuse, Infective Endocarditis

---

**DOI:** - 10.53555/ecb/2023.12.Si12.288

IE is one of the life-threatening complications of parenteral drug abuse as it affects intravenous drug abusers (IVDUs) by a ratio ranging from 2% to 5% annually. In addition, it is the reason for 5% to 20% of hospitalized cases and 5% to 10% of the overall mortality rate. IVDUs often develop recurrent IE. Right side infective endocarditis has been mainly defined among IVDUs. (1) Approximately 41% of IVDUs with bacteremia will develop IE. (2)

### Epidemiology

The infective endocarditis epidemiology has changed recently, which reflects the social climate of IV drug use. This changing epidemiology changed in turn the standard treatments for this type of infection. It requires a more holistic study to shed light on the diverse needs of this clinical population. The rate of right-heart IE occurrence among IVDU may vary from 0.7 to 13/1000 patient annually. Noticed the increasing number of hospital admissions of IVDU with IE. (3), but the last decade witnessed a decrease in this rate. Nowadays, IVDU causes one third of all right-heart IE and less than 5% of all IE patients. Right-heart IE in IVDU is more frequent in the young patients with immunodeficiency virus seropositive and immunosuppress.

The highest rate appeared mainly in males. To further characterize, IDUs may present in 86% cases right-sided IE, whereas 14% have left-sided IE with or without right-sided IE. (4)

### **Microbiology:**

According to current evidence, IE among IDUs presents a large spectrum of microbial pathogens (5)

The most common etiology of IE in IDUs is *Staphylococcus aureus* (*Staph. aureus*) in about 75% followed by streptococci, Gram-negative bacilli, and fungi. *Staphylococcus aureus* (*Staph. aureus*) is the most common cause of tricuspid valve endocarditis regardless of associated risk factors in IDUs. (6)

Pathogens as *Pseudomonas aeruginosa*, other gram-negative microorganisms, fungi, enterococci, streptococci, and polymicrobial infections occur less frequently. Importantly, other pathogens noted in IDUs are oral bacteria such as *Prevotella intermedia*, *Haemophilus parainfluenzae*, *S. constellatus*, and *E. corrodens*. (7)

The negative blood cultures rate of occurrence ranges from 2.5 to 31%. It is associated with delayed diagnosis and treatment as well as large vegetations. Therefore, they are marked with highest morbidity and mortality. (8).

Polymicrobial endocarditis distinguishes IDUs and may involve microorganisms such as *Bartonella* spp., *Candida* spp., or *Tropheryma whippelii*. (6) The presence of *E. corrodens* should aware the likelihood of polymicrobial IE with embolic complications and relapses. In fact, there is a synergism between streptococci and *E. corrodens*. (9)

**Table (1): Show pathogens among IDUs**

- |  |
|--|
| <ul style="list-style-type: none"> <li>• <i>Staphylococcus aureus</i> and coagulase-negative staphylococci,</li> <li>• group A streptococci,</li> <li>• <i>P. aeruginosa</i>,</li> <li>• HACEK organisms (<i>Haemophilus aphrophilus</i>, <i>Actinobacillus actinomycetemcomitans</i>, <i>Cardiobacterium hominis</i>, <i>Eikenella corrodens</i>, and <i>Kingella kingae</i>),</li> <li>• Tetanus (<i>Clostridium tetani</i>),</li> <li>• Anthrax (<i>Bacillus anthracis</i>),</li> <li>• wound botulism (<i>Clostridium botulinum</i>),</li> <li>• tuberculosis,</li> <li>• diphtheria (<i>Corynebacterium diphtheriae</i>),</li> <li>• viruses (HIV, HBV with HDV, HCV, and HTLV),</li> <li>• fungal infections (<i>Candida</i> spp. and <i>Aspergillus</i> spp.),</li> <li>• parasitic infections (malaria and leishmaniasis)</li> <li>• other pathogens noted in IDUs are oral bacteria such as <i>Prevotella intermedia</i>, <i>Haemophilus parainfluenzae</i>, <i>S. constellatus</i> and <i>E. corrodens</i>.</li> </ul> |
|--|

### **Diagnosis:**

IE in an active intravenous drug user can be classified according to different scenarios whether they are Right-sided endocarditis or left-sided endocarditis.

Right-sided endocarditis is the most prevalent as it can be detected in about 70% of all cases. It involves the tricuspid valve, and a murmur is not always present. As for the symptoms, they are non-specific and include fever, pleuritic chest pain, dyspnea, and non-productive cough. Its symptoms and outcomes can be forecasted well and its survival rate surpasses 95%.

Left-sided endocarditis is very similar to disease in non-IV drug users, but it can be associated with systemic manifestations from embolic events. Special attention is necessary to renal, splenic and central nervous system involvement, as they can mask the initial presentation.

Clinical manifestations are usually limited in the early IE of IDUs. Right-sided IE mainly present fever, cough, hemoptysis, dyspnea caused by pulmonary emboli, anemia, and no systemic emboli. It does not develop immunological vascular phenomena (splinter hemorrhages, Roth spots, and glomerulonephritis) and the peripheral emboli (10)

The RSIE is often associated with septic pulmonary emboli. (10) The diagnosis is determined according to the relationships between clinical findings, positive blood cultures, and positive echocardiography. (11) As for the widespread complications of RSIE, they are valvular regurgitations, cardiac abscess, and septic pulmonary emboli. (12). Relapse and reinfection are two types of recurrence(8). Basically, recurrence within 6 months of same IE produced by same microorganisms is termed relapse. (12) Reinfection or recurrent IE refers to the recurrence of same IE with same microorganisms after 6 months from initial episode Bai Z.,et al.2015. Recurrent IE is highly associated with IDUs with increased valve replacement (8).

**Echocardiography** is the essential element in diagnosing infective endocarditis (8). (TTE) and/or (TOE) are vital in the diagnosing any IE (8). **TTE** is the first line recommendation either for native valve endocarditis or for prosthetic valve endocarditis. In case of suspected native valve endocarditis, TTE has a sensitivity of 50–90% and a specificity of 90% (13). For suspected prosthetic valve endocarditis, TTE has a reduced sensitivity of 40–70%. However, TTE comes up with significant information regarding ventricular size and function, and “hemodynamic severity of valve lesions. Major criteria in the diagnosis of IE are represented by three echocardiographic features: vegetation, abscess or pseudoaneurysm, and prosthetic valve with new dehiscence. (8).

In addition, TTE helps in the diagnosis of anterior prosthetic aortic valve abscesses, which are difficult to be seen on TEE. (13).

TOE should be done in case of facing difficulty diagnosing TTE. It is recommended also if it is accompanied with positive, suspected complications, or in presence of intracardiac device (13). In case of native valve endocarditis, TOE has a sensitivity of 90–100% and a specificity of 90% for detecting vegetation. Hence, TOE is better than TTE in detecting abscesses, perforations, and fistulae as well as the pulmonary vegetations. (14)

When clinical manifestations sustain IE with negative or unclear TTE, TOE has higher sensitivity (>90%) and may reveal: (1) vegetations; (2) paravalvular or intracardiac abscess, (3) new valvular regurgitations, and (4) prosthetic valve dehiscence (15).

There are some other techniques used in imaging and diagnosing IE these include: magnetic resonance imaging (**MRI**), multi-slice computed tomography (**MSCT**), and 18F-fluorodeoxyglucose (**FDG**) positron emission tomography (**PET**)/computed tomography (**CT**). They, with cardiac CT, are valuable as they can provide greater information on paravalvular anatomy or complications (e.g. mycotic aneurysms, paravalvular abscesses) with lesser prosthetic valve artifacts (13), when compared with TEE. Currently, using CT imaging in the diagnosis of paravalvular lesions is a major criterion in the 2015 ESC guidelines on IE. (8).

Although 2015 ESC Guidelines for the management of infective endocarditis reviewed and adopted Modified Duke criteria (2000) for diagnostic classification, they have poorer diagnostic precision in the early diagnosis of IE from IDUs, which present fewer typical clinical manifestations (8). So, some imagistic techniques such as cardiac/whole-body CT scan, cerebral MRI, (16). F-FDG PET/CT, and radiolabelled leucocyte SPECT/CT may be added to increase the accuracy of the modified Duke criteria in IVDUs. (8).

#### **Management of IE and Outcomes:**

Treatment of Infective Endocarditis in IVDU requires a multidisciplinary team and various sources in order to provide all necessary help to the patients. This team should consist of professionals in cardiology, cardiac surgery, and infectious disease. Moreover, other resources should take part in addressing recidivism with psychiatric support and social services. The management must include eradication of the pathogenic organism, the reversal of the cardiac and systemic manifestations of the infection, and the return to baseline cardiac and physical function if possible.

#### **Medical treatment:**

According to the published data, the initial treatment of IE is empirical (17), in most cases. It should be considered that medical therapy is the main effective treatment, while surgery is a choice in smaller cases (8). Hence, medical treatment in RSIE of IVDUs is usually effective with good prognosis up to 80% cases. (8).

Staph. aureus is the most frequent cause of IE in IVDUs and consequently, this pathogen should be treated medically (8). Short courses of antimicrobial therapy in right-sided IE with S. aureus in IVDUs assure high cure rates (>85%) (10). A short course (2 weeks) with **oxacillin** or **cloxacillin** is mainly sufficient. (8). Initial therapy comprises penicillinase-resistant penicillins, vancomycin, or daptomycin in combination with gentamicin. (8). Short course (2 weeks) with oxacillin or cloxacillin is mainly efficient for isolated tricuspid IE with good compliance to therapy, vegetation <20 mm, MSSA, without empyema or other metastatic sites of infection, without prosthetic valve or left-sided IE, without cardiac/extracardiac complications and without severe immunosuppression (<200CD4cells/ $\mu$ L) with/without AIDS. Anti-pseudomonas agent should be added in pentazocine addict. (18) Antifungal therapy for Candida spp. is added when an IVDU utilizes brown heroin combined with lemon juice.

There are some traditional approaches for treating RSIE.

The first is formed from gentamicin with nafcillin or oxacillin.

The second included the use of IVDUs with right-sided Staph. aureus IE and no other complications (e.g. aortic or mitral valve involvement, extra pulmonary infections or meningitis, renal failure, MRSA infection) is the antimicrobial coverage with short-course (2 weeks) of beta-lactam plus aminoglycoside that may be greatly successful (19). It is currently recommended to use gentamicin, but some available data suggest that it might be unnecessary. (20)

Moreover, Staph. aureus bacteremia or right-sided Staph. aureus IE can be addressed using the approved approach of daptomycin monotherapy. (20)

In conclusion, it is controversial to treat IE in IVDUs due to the frequent exposures to virulent microorganisms; poor compliance with the therapy; illegal drug use or withdrawal manifestations during hospitalization; opioid maintenance therapy; and early self-discharge or long hospitalization. (21). Regardless of correct antimicrobial therapy, IDUs develop relapsing IE.

### **Surgery:**

Surgery can also be used as a treatment solution for IVDUs with IE, despite its complex indications that are based on the clinical manifestations. Surgery is associated with some risk factors (e.g. age, microorganisms, size of vegetation, perivalvular infection, embolism, heart failure, and other associated comorbidities) and the expertise of surgery team. (10). A multidisciplinary team or the "Endocarditis team" with knowledge in cardiology, infectious diseases, microbiologists, imaging, neurologists, neurosurgeons, and cardiothoracic surgery should provide decisions regarding the indication and timing of surgery. (10). Cardiac surgery in IVDUs with IE aims to remove infection with hemodynamics stabilization hemodynamic may be suggested for IDUs (22)

IN case of receiving surgery, patients with right-sided IE show better outcomes than those with left-sided IE **Lee MR et al.,(19)**. IVDUs with right-sided IE is better treated according to the general approach of medical therapy and it is preferred to delay the use of valve prostheses as much as possible (19)

**indications of Surgical treatment for right-sided IE are following: (19)**

- TV vegetations >20 mm after recurrent septic pulmonary emboli with or without right heart failure;
- Severe tricuspid regurgitation with right heart failure unresponsive to medical therapy.
- IE with fungi or persistent bacteremia with virulent microorganisms for at least 7 days (e.g., Staph. aureus, P. aeruginosa) regardless of the antimicrobial therapy.

### **Timing of surgery**

Surgery can be employed in a small rate (5–16%) of IVDUs. (23). Despite it is recommended to perform early surgery for cases with left-sided IE, the indications for performing early surgery in right-sided IE are not established yet. (23).

It is highly recommended to delay surgery until completing the microbial therapy, which may decrease morbidity and mortality rates significantly. Previous researches maintained that early surgery is a choice in case of IE with Staphylococcus aureus or fungal infection (1). Early surgery of tricuspid valve IE is a choice if it is associated with (1) atrial septal defect; (2) prosthetic valve endocarditis; (3) infected pacing leads; (4)

indwelling catheters; and (5) simultaneous left-sided IE. (18) Additionally, development of bacteremia or pulmonary septic emboli also has early surgery.

### **Surgical techniques**

Making surgery for tricuspid valve IE consists principally of removal of infected tissue; excision of vegetations with conserving or repairing the valve. It also implies the TV removal with its replacement. (24). In case of native pulmonary valve, its preservation is usually recommended. If pulmonary replacement is mandatory, it is preferred to use a homograft or xenograft.

Various techniques that are used in cardiac surgery for right-sided IE. (24).

- vegetectomy (excision of vegetations)
- valve replacement (bioprosthetic, mechanical prostheses).
- valvectomy (total removal of valve leaflets and chordate tendineae)
- valvectomy (valve excision)
- reconstruction of the cusps (e.g. bicuspidization or conversion to a bicuspid valve)
- pericardial patch augmentation
- annuloplasty ring implantation

**It is important to take into consideration that (Class Ia) of the ESC and EACTS (European Association for Cardio-Thoracic Surgery) in IE for IVDUs is vegetectomy and valve repair.**

**Valve repair:** is mainly achieved with autologous pericardial patch, artificial chordae, and simple annuloplasty with sutures. Ruptured chordae may be restored with polytetrafluoroethylene neo-chordae.

### **Valve Repair Surgery**

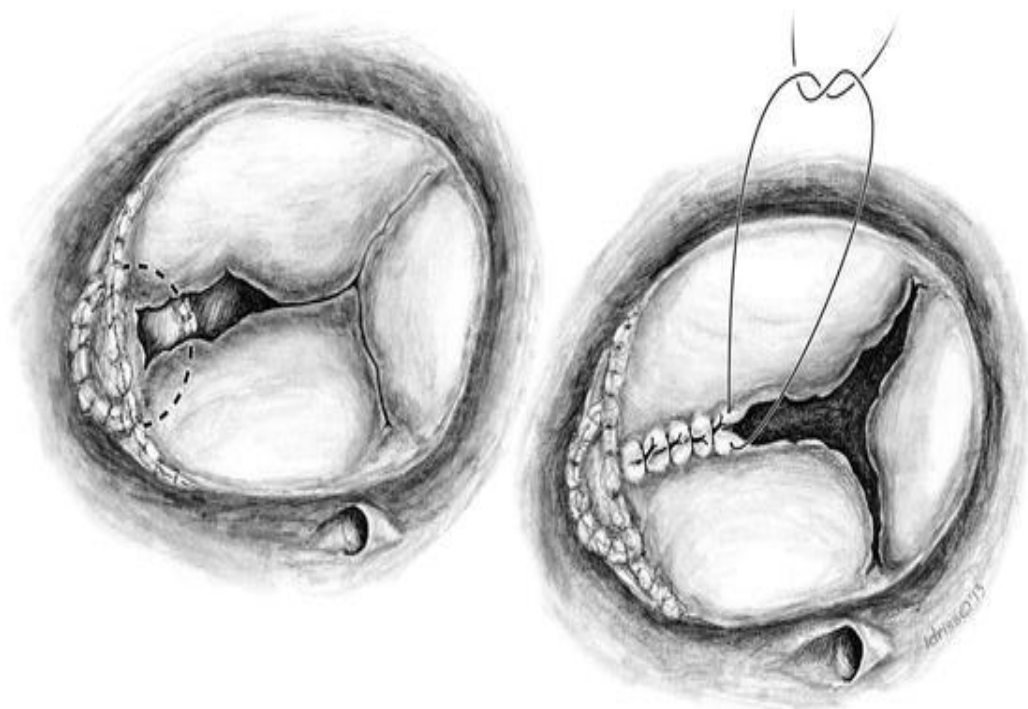
**The second line recommendation (Class IIa) is tricuspid valve replacement. Bioprosthesis is the principal choice in TV replacement in IVDUs, because mechanical valve needs long life anticoagulation.**

**Valve replacement:** Valve replacement is required in case of a large destroyed valve with increased pulmonary pressures and pulmonary vascular resistance. (24). It also requires the absence of drug addiction during surgery and after surgery. Presently, it is recommended tricuspid valve excision for right-sided IE in IVDUs. (25).

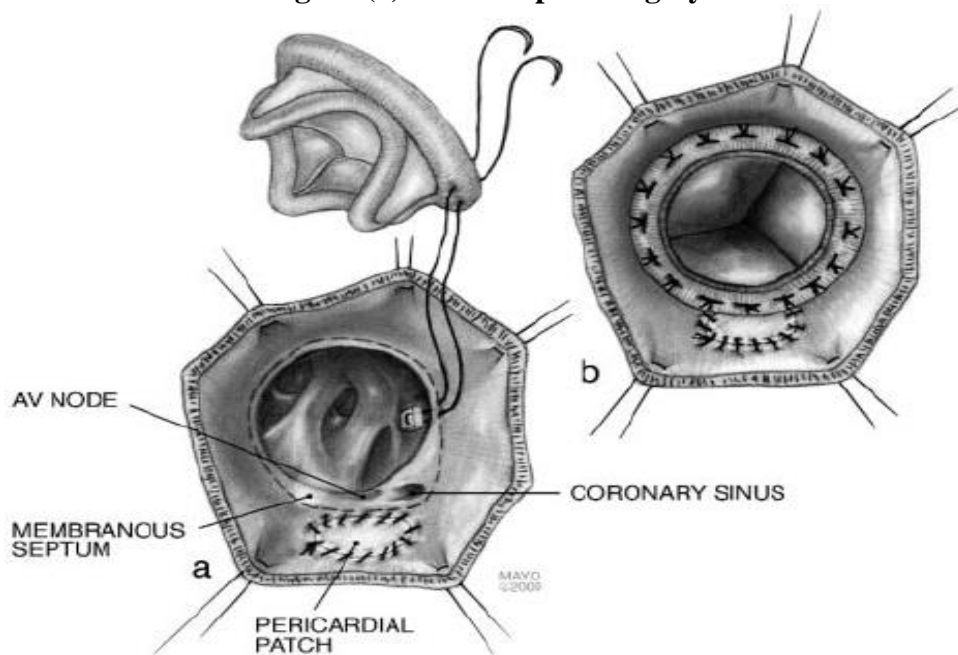
Valve replacement in IVDUs is correlated with greater risk for recurrent infection and redo surgery (re-operation). (22)

IVDUs record more deaths than the general population. (25). However, right-sided IE that received surgical intervention has good outcomes in the early, mid and long-term. The prominent factors of risk for poor prognosis in IVDUs treated surgically are interrelated with the *Staphylococcus aureus* and fungi or polymicrobial IE, late presentation in critical condition, with the vegetation size, and with left-sided IE. (26)

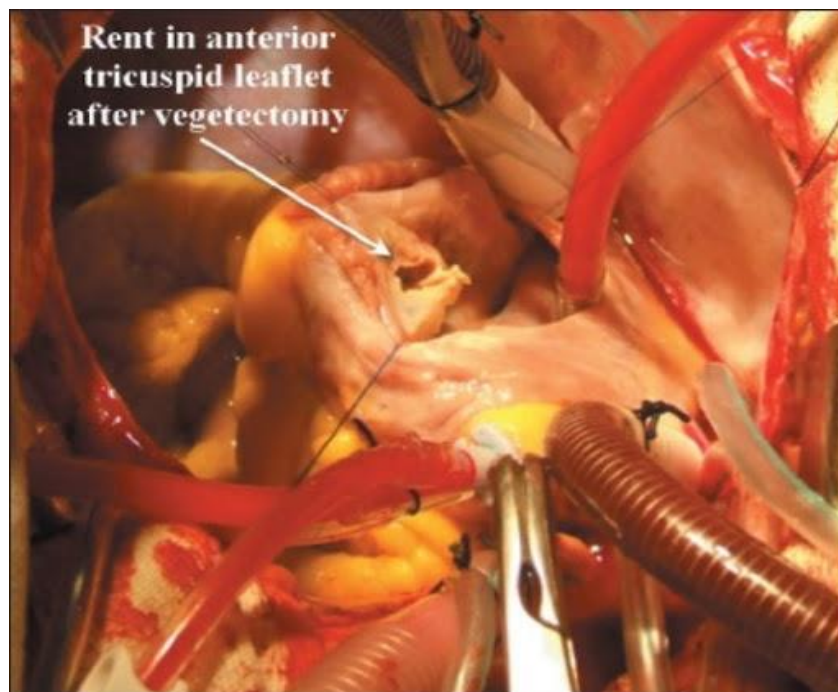**Valvectomy:** is the last choice to valve repair or valve replacement in IDUs with greater risk of recurrent infection. Recurrence of IE is characteristically for IVDUs **Georges H** et al.,2018. However, the best indication and timing of surgery are debatable. (27)



**Figure (1): Valve repair surgery**



**Figure (2): Tricuspid valve replacement surgery**



**Figure (3): Vegetectomy**

#### **Recurrent infective endocarditis in a drug addict:**

Recurrent infective endocarditis (IE) are a relatively common disease in some population of patient, such as IV drug-addicted ones. In the context of recurrent IE we can distinguish: relapse IE, caused by the same bacterial, less than 6 months after the previous episode, and the reinfections, caused by a different bacterial or by the same one, more than 6 months after the previous episode. (28). Multiple episodes of recurrent IE occurred in habitual drug abusers.

Habitual drug abuse is such an important risk factor of IE and recurrent IE that was even included in the minor diagnostic criteria (modified Dukes criteria) of last IE ESC guidelines (2015). (18)

Endocarditis is a disease that causes a high-rate of mortality as patients with repeat IE are exposed to higher one-year mortality rate (20%) than those with a single episode (9%). (29). In addition, the IE episodes involving a prosthetic valve have a worse prognosis as the mortality rate reaches 45% per single episode.

There are various ethics in the surgery of repeat heart valve replacement, which makes it a controversial issue. Treating (IVDU) patients includes many interventions. These include the normal medications, psychiatric rehabilitation, and surgical interventions, especially for mortal complications. However, such surgical interventions remain the surgeons' and healthcare team responsibility as their treatment decisions are influenced by several medical factors, unfortunately not without bias. The stigma associated with substance use disorder is prevalent, especially toward IVDU, which leads to significant biases, even in the healthcare system. (29). This bias comes to the surface in case of determining the IVDU patients requiring multiple or repeat valve replacement surgeries for IE due to continued drug use, which can be quite costly for healthcare institutions. (29).

On the whole, many surgeons maintain that repeat valve replacement surgery is non-beneficial for patients with IVDU. Hence, they refuse or are reluctant to offer this solution or refer patients to other professionals who are willing to treat these patients. These reluctant surgeons and healthcare team may refuse performing the valve replacement operation even if it may provide some benefit or improve the patients' life-quality for some years because they consider the financial burdens to patients and healthcare institutions. They find it a reasonable justification for not replacing infected valves. This applies certainly in the presence of high relapse rates for IVDU and readmission with active IVDU.

Moreover, these professionals refuse performing these operations because the IVDU patients contribute to increased unemployment and reliance on publicly funded insurance (30). SO, they may feel it is a duty to the community not to prolong the lives of patients with IE secondary to IVDU. They may feel that such surgical intervention adds more financial burdens on communities and the already resource-limited health system.

The Code of Medical Ethics developed by the American Medical Association's stated that physicians are obliged ethically "to place patients' welfare above their own self-interest and above obligations to other groups as they have to advocate for their patients. (14) They have to promote their patients' the health through comprehensive, beneficial treatment based on evidence-based medicine, and to respect them as persons with dignity. Physicians also have to be uninfluenced by social stigma and clinical bias. (30).

Concerning patients with IE secondary to IVDU, it is important to treat both the psychiatric, social and infectious conditions. These include the substance use disorder, homelessness, and food insecurity, as well as the IE, along with any additional comorbidities associated with worse health outcomes, more complex clinical management, and increased health care costs. Although every patient with IE secondary to IVDU differs in the severity of presentation and comorbid conditions, patients with a positive prognosis should have the opportunity to achieve health and life with medical assistance. (30).

### **Prognosis:**

Prognosis of IE in IVDUs has good outcomes with mortality less than 5%. Right-sided IE has a good prognosis with lower mortality and lower morbidity in hospitalized cases than left-sided IE but with greater early mortality rate.

Higher mortality in IVDUs with right-sided IE is associated with vegetations greater than 20mm, fungal endocarditis, bacteremia, and older age. In conclusion, the early and complete surgical debridement of infected tissue together with microbial therapy assure a good prognosis on the long run. (27)

### **References**

1. Starakis I, Mazokopakis EE. Injecting illicit substances epidemic and infective endocarditis. *Infectious Disorders Drug Targets*. 2010;10(1):22-26.
2. Axelsson A, S holm H, Dalsgaard M, et al. Echocardiographic findings suggestive of infective endocarditis in asymptomatic Danish injection drug users attending urban injection facilities. *Am J Cardiol*. 2014;114(1):100-4.
3. Ortiz C, L pez J, Garc a H, et al. Clinical classification and prognosis of isolated right-sided infective endocarditis. *Medicine*. 2014;93(27):e137.
4. Chu VH, Park LP, Athan E, et al. Association between surgical indications, operative risk, and clinical outcome in infective endocarditis: A prospective study from the international collaboration on endocarditis. *Circulation*. 2015; 131:131-140
5. Ternhag A, Cederstrom A, Torner A, et al. A nationwide cohort study of mortality risk and long-term prognosis in infective endocarditis in Sweden. *PLoS One*. 2013;8:e67519
6. Baraki H, Saito S, Al Ahmad A, et al. Surgical treatment for isolated tricuspid valve endocarditis- long-term follow-up at a single institution. *Circulation Journal*. 2013; 77: 2032-2037.
7. Deutscher M, Perlman DC. Why some injection drug users lick their needles: A preliminary survey. *The International Journal on Drug Policy*. 2008;19(4):342-345.
8. Murdoch DR, Corey GR, Hoen B, et al. Clinical presentation, etiology, and outcome of infective endocarditis in the 21st century: the International Collaboration on Endocarditis-Prospective Cohort Study. *Arch Intern Med* 2009; 169:463-73.
9. Akinosoglou K, Apostolakis E, Koutsogiannis N, et al. Right-sided infective endocarditis: Surgical management. *European Journal of Cardio-Thoracic Surgery*. 2012 Sep;42(3):470-479.
10. Miro JM, del Rio A, Mestres CA. Infective endocarditis and cardiac surgery in intravenous drug abusers and HIV-1 infected



- patients. *Cardiology Clinics*. 2003;9:167-184.
11. Yuan S-M. Right-sided infective endocarditis: recent epidemiologic changes. *Int J Clin Exp Med*. 2014; 7(1):199–218.
  12. Welton DE, Young JB, Gentry WO. Recurrent infective endocarditis. Analysis of predisposing factors and clinical features. *The American Journal of Medicine*. 1979;66(6):932-938
  13. Winslow T, Foster E, Adams JR, et al. Pulmonary valve endocarditis: Improved diagnosis with biplane transesophageal echocardiography. *Journal of the American Society of Echocardiography*. 1992;5:206-210
  14. Cahill TJ, Baddour LM, Habib G, Hoen B, et al. Challenges in infective endocarditis. *Journal of the American College of Cardiology*. 2017;69(3):325-344.
  15. Westling K, Aufwerber E, Ekdahl C, et al. Swedish guidelines for diagnosis and treatment of infective endocarditis. *Scandinavian Journal of Infectious Diseases*. 2007;39:929-946.
  16. Werner GS, Schulz R, Fuchs JB, et al: Infective endocarditis in the elderly in the era of transesophageal echocardiography: clinical features and prognosis compared with younger patients. *Am J Med* 1996; 100:1.
  17. Kupferwasser LI, Hafner G, Mohr-Kahaly S, et al. The presence of infection-related antiphospholipid antibodies in infective endocarditis determines a major risk factor for embolic events. *J Am Coll Cardiol*. 1999;33:1365–71
  18. Habib G, Badano L, Tribouilloy C, Vilacosta I, Zamorano JL, Galderisi M, et al. Recommendations for the practice of echocardiography in infective endocarditis. *European Journal of Echocardiography*. 2010;11(2):202-219
  19. Lee MR, Chang SA, Choi SH, et al. Clinical features of right-sided infective endocarditis occurring in non-drug users. *Journal of Korean Medical Science*. 2014; 29(6):776-781.
  20. Haber PS, Demirkol A, Lange K, et al. Management of injecting drug users admitted to hospital. *Lancet*. 2009;374:1284-1293.
  21. Carozza A, De Santo LS, Romano G, et al. Infective endocarditis in intravenous drug abusers: Patterns of presentation and longterm outcomes of surgical treatment. *The Journal of Heart Valve Disease*. 2006;15(1):125-131.
  22. Bonow RO, Carabello BA, Kanu C, et al. ACC/AHA 2006 Guidelines for the management of patients with valvular heart disease. A report of the American college of cardiology/American heart association task force on practice guidelines. *Circulation*. 2006;114(5):e84-e231.
  23. Chrissoheris MP, Libertin C, Ali RG, et al. Endocarditis complicating central venous catheter bloodstream infections: A unique form of health care associated endocarditis. *Clinical Cardiology*. 2009;32:E48-E54.
  24. Kim JH, Kim KH, JB1 C, et al. Commissuroplasty for the anterior commissure defect caused by tricuspid valve endocarditis using patch closure and modified placement of a rigid ring. *Journal of Cardiothoracic Surgery*. 2014;9:36.
  25. Rabkin DG, Mokadam NA, Miller DW et al. Long-term outcome for the surgical treatment of infective endocarditis with a focus on intravenous drug users. *The Annals of Thoracic Surgery*. 2012;93:51-57.
  26. Chen Q, Cao H, Lu H, et al. Bioprosthetic tricuspid valve endocarditis caused by *Acinetobacter baumannii* complex, a case report and brief review of the literature. *Journal of Cardiothoracic Surgery*. 2015;10:149.
  27. Weymann A, Borst T, Popov AF, et al. Surgical treatment of infective endocarditis in active intravenous drug users: A justified procedure? *Journal of Cardiothoracic Surgery*. 2014;9:58.
  28. Slipczuk L, Codolosa JN, Davila CD, et al. Infective endocarditis epidemiology over five decades: a systematic review. 2013; *PLoS One* 8: e82665.
  29. Cami J, Farre M. Drug addiction. *The New England Journal of Medicine*. 2003;349:975-986
  30. O'Toole TP, Pollini R, Gray P, et al. Suboptimal addiction interventions for patients hospitalized with injection drug use-associated infective Endocarditis. *Journal of Substance Abuse Treatment*. 2007. Jul; 33(1):51-59.