



PROTECTIVE EFFECT OF *LANNEA*
COROMADELICA STEM BARK EXTRACT ON
MALONDIALDEHYDE LEVELS AND LUNG
HISTOPATHOLOGICAL FEATURES OF MALE
WISTAR RATS INDUCED BY MONOSODIUM
GLUTAMATE

¹Trinarti Senolangi,² Aryadi Arsyad,³ Aminuddin,⁴ Muhammad
Husni Cangara,⁵ Ika Yustisia,⁶ Yulia Yusrini Djabir

Abstract

This study aims to investigate the effect of *Lannea coromandelica* bark extract on lipid peroxidation activity and the degree of lung damage in male Wistar rats given MSG. This study used 25 rats divided into five treatment groups: healthy control group with standard feed, negative control with monosodium glutamate, treatment group 1 (*Lannea coromandelica* extract 250 mg/KgBW + MSG administration), treatment group 2 (*Lannea coromandelica* extract 500 mg/KgBW + MSG administration) and treatment group 3 (*Lannea coromandelica* extract 500 mg/KgBW + MSG administration). The administration of *Lannea coromandelica* extract and MSG was carried out for 28 days. Subsequently, lung organs of rats were surgically removed, which were then analysed for malondialdehyde (MDA) levels as a biomarker of lipid peroxidation, and the degree of lung damage through histopathological examination. This study showed that the group given *Lannea coromandelica* extract, especially at a low dose (250 mg/kgBB had significantly lower MDA levels than the group given only MSG ($p = 0.045$). However, the administration of *Lannea coromandelica* extract showed no significant effect ($p > 0.05$) on the degree of damage to the rat lungs when compared to the negative group. The use of *Lannea coromandelica* bark extract showed potential in protecting lung damage caused by excessive MSG administration.

Keywords: *Lannea coromandelica* bark extract, lipid peroxidation, histopathology, monosodium glutamate

DOI: 10.53555/ecb/2024.13.02.01

¹Biomedical Sciences, Hasanuddin University Postgraduate, Makassar, Indonesia

² Department of Physiology, Faculty of Medicine, Hasanuddin University, Makassar, Indonesia

³ Department of Nutrition Faculty of Medicine, Hasanuddin University, Makassar, Indonesia

⁴ Department of Anatomical Pathology, Faculty of Medicine, Hasanuddin University, Makassar, Indonesia

⁵ Department of Biochemistry, Faculty of Medicine, Hasanuddin University, Makassar, Indonesia

⁶ Department of Pharmacy, Faculty of Pharmacy, Hasanuddin University, Makassar, Indonesia

Correspondent: aryadi.arsyad@med.unhas.ac.id

1. Introduction

One of the most widely used food additives globally is Monosodium Glutamate (MSG) (Althanoon & Taha, 2022). MSG is an additive that is often used in various types of food as a flavour enhancer. (Yuliana et al., 2019).. The Food and Agriculture Organisation (FAO) and the World Health Organisation (WHO) have set a maximum limit of MSG consumption that is considered safe, which is 120 mg/kg body weight per day. (Kurtanty et al., 2019).. It is reported that excessive MSG consumption may be associated with changes in antioxidant status in various areas of the brain and organs other than the brain. (Putri Laksmi, 2020). If MSG is consumed over a long period of time, it can cause an imbalance between antioxidants and Reactive Oxygen Species (ROS), which can result in oxidative stress. According to research conducted by Hegazy *et al* (2017), it is known that MSG can cause degeneration, necrosis, and inflammation in lung epithelial tissue.

There are antioxidants in the body that can fight free radicals, but when free radicals are in excessive amounts, the body needs antioxidants from outside to fight them. Although many synthetic antioxidants are available and frequently used, the safety and toxicity of these antioxidants have raised concerns. (Alam, Kwon, Lee, et al., 2017).. Treatment using traditional herbs is increasingly popular among people today. One of the main reasons is their easy availability and relatively minimal side effects. One of the plants that has long been used as a traditional medicine is *Lannea coromandelica* stem bark. (Arum et al., 2022).

Java wood has long been used by the Bugis community and is still used today because it is believed to have very effective properties. It is usually used to treat various types of wounds, both internal and external wounds. In addition, java wood is also believed to treat stomach pain, leprosy, ulcer, heart disease, dysentery, and mouth ulcers. The bark of the Java wood plant (*Lannea coromandelica*) contains various antioxidant compounds such as steroids, terpenoids, saponins, tannins, and flavonoids. Based on this, this study aims to investigate the protective effect of *Lannea coromandelica* bark extract on lipid peroxidation activity and the degree of lung damage in male Wistar rats given MSG.

2. Materials and Methods

Preparation of Monosodium Glutamate (MSG)

Monosodium glutamate used was obtained from the free market with the trademark Ajinomoto produced by PT Ajinomoto Indonesia, MSG powder in the form of white crystals containing pure monosodium glutamate. The daily dose given to rats is 3 mg/gBB rat.

Preparation of *Lannea coromandelica* stem bark extraction

Lannea coromandelica bark was obtained from Pinrang Regency, South Sulawesi Province, Indonesia. 100 g samples were weighed and put into a reflux device. Then 96% ethanol was added until the sample was submerged. The reflux process was carried out for 3-4 hours. After that, filtering was carried out, and the filter results were stored to evaporate the solvent. The dregs of the filter were then refluxed again for 3-4 hours.

Preparation of Animal

Twenty-five male Wistar strain rats weighing between 180 to 300 grams and \pm 3 months of age were adapted for 7 days in the animal laboratory before the start of the experiment. During this stage, all rats were given standard feed and water ad libitum, rats were housed individually in their respective cages.

Experimental Protocol

Twenty-five male Wistar rats were divided into five groups, the healthy group was given standard food, the negative group was given MSG 3 mg/grBW, treatment group 1 was given MSG and *Lannea coromandelica* extract at 250 mg/kgBW, treatment group 2 was given MSG and *Lannea coromandelica* extract at 500 mg/kgBW while treatment group 3 was given MSG and *Lannea coromandelica* extract at 750 mg/kgBW for 28 days. *Lannea coromandelica* bark extract was administered 1 hour before MSG administration. In this study, MSG and *Lannea coromandelica* bark extract were given to mice through the gavage method, namely by oral administration using a round. Mouse care was carried out in accordance with laboratory animal care standards, and all procedures involving animals were approved by the Animal Ethics Committee of the Faculty of Medicine, Hasanuddin University.

Malondealdehyde Level Analysis

Rat lung tissue weighing approximately 0.4 grams was added with ± 2000 μ l PBS solution and crushed until smooth. Then, the sample was centrifuged at 3000 rpm for 10 minutes. The supernatant was taken as much as 500 μ l and then mixed with 10% TCA and 1% TBA each added as much as 1000 μ l into a vacutainer tube and homogenised. Next, heated in a water bath at 90°C for 30 minutes. After that, a second centrifugation was performed at 3000 rpm for 10 minutes. The absorbance of the sample was measured using a UV-Vis spectrophotometer at a wavelength of 532 nm.

Histopathological examination

Rat lung organs were washed using saline solution, then fixed with 10% formalin. The fixed tissues were then placed in paraffin blocks and cut into sections with a thickness of 5 μ m. Each section was stained using haematoxylin and eosin (H&E) dye. Histopathological observations were made using a microscope. On microscope observation, lung damage was observed and graded based on the damage degree score, including oedema, inflammatory cell infiltration, necrosis, thickening of septa, and dilation of alveoli.

Statistical Analysis

Statistical analyses were performed using SPSS IBM 25 software. Data distribution was examined using the Saphiro Wilk test to determine whether the data were normally distributed or not. If the data were normally distributed, the analysis continued with ANOVA, while if the data were not normally distributed, the Mann-Whitney test was used. Differences were considered significant if the p value was <0.05 .

3. Results

After treatment for 28 days, on the 29th day the rats were sacrificed to take the lung organs for further examination. The examination that has been carried out obtained the following results:

Results Analysis of malondialdehyde (MDA) levels

Comparison of the value of lung MDA levels in each group can be seen in the figure

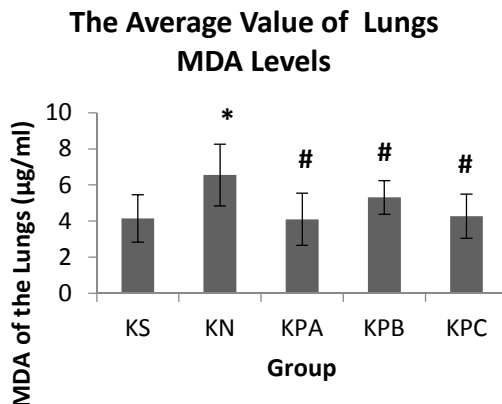


Figure 1. Diagram showing the mean values of lung MDA levels in each group (n=5). Data presented as mean \pm SD and Symbol * indicates significantly different values against healthy control (KS). Symbol # indicates significantly different values against the negative control (KN).

Based on Figure 3, the results show that the highest average MDA level of rat lungs is the Negative Group at $6.55 \pm 1.71 \mu\text{g/ml}$ and for treatment group 2 has an average MDA level of $5.31 \pm 0.93 \mu\text{g/ml}$. In treatment group 3 the average MDA level is $4.26 \pm 1.21 \mu\text{g/ml}$ while in the healthy control group, the average MDA level of rat lungs is $4.15 \pm 1.30 \mu\text{g/ml}$. The lowest average MDA level is treatment group 1 which is $4.10 \pm 1.43 \mu\text{g/ml}$.

Histopathological Analysis Results

The results of histopathological examination of lung tissue based on the degree of damage showed that the negative group (KN) given MSG had a degree of damage 2, with an average histopathological damage of 2.00 ± 0.00 . In the healthy group (KS) and treatment group 1 (KPA) which was given MSG and *Lannea coromandelica* extract at a dose of 250 mg/kgBW, the degree of damage began to decrease significantly with an average value of 1.33 ± 0.57 . In contrast to treatment group 2 (KPB) where rats were given MSG and *Lannea coromandelica* extract at a dose of 500 mg/kgBW and treatment group 3 (KPC) which was given MSG and *Lannea coromandelica* extract at a dose of 750 mg/kgBW had moderate damage with an average value of 1.67 ± 0.57 . Lung histopathological features based on damage parameters, namely Oedema (O), inflammatory cell infiltration (SR), thickening of septa (PS), widening of the alveoli lumen (PL), and necrosis (N) can be seen in the following figure. The results of the comparative analysis between the dose treatment group and the control group showed a value of $p = 0.458$ ($p > 0.05$), which indicates that there is no significant difference in each group after the administration of MSG and *Lannea coromandelica* extract on the histopathological picture of the lungs.

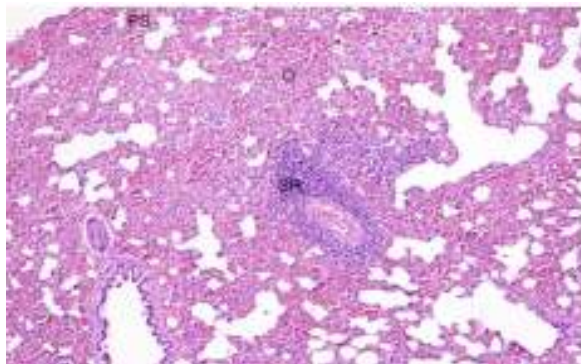


Figure 2. Histopathological features of the lungs of rats in the negative control group after administration of MSG for 28 days . The image shows inflammatory cells and necrosis with a score of 1 (mild damage) and oedema and thickening of the alveolar septum with a score of 3 (severe damage).

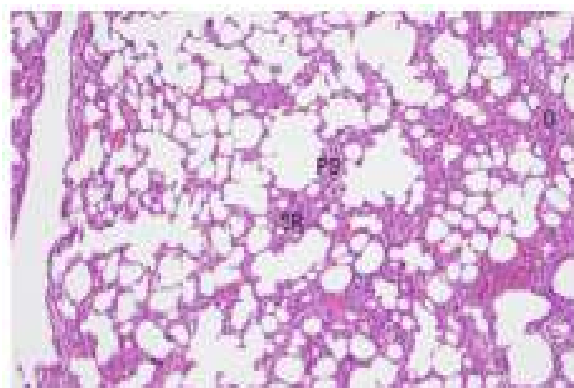


Figure 3. Histopathological picture of rat lungs in the healthy group. The picture shows inflammatory cell infiltration, pulmonary oedema and thickening of the alveolar septum with a score of 1 (mild damage) while the picture does not show dilation of the alveolus lumen and necrosis.

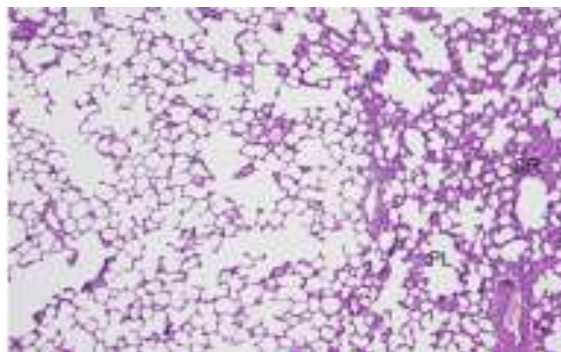


Figure 4. Histopathological features of rat lungs in treatment group 1 which was given MSG and Lannea coromandelica extract at a dose of 250 mg/kg BW for 28 days. showed mild damage (score 1) in inflammatory cell infiltration and dilation of the alveolus lumen.

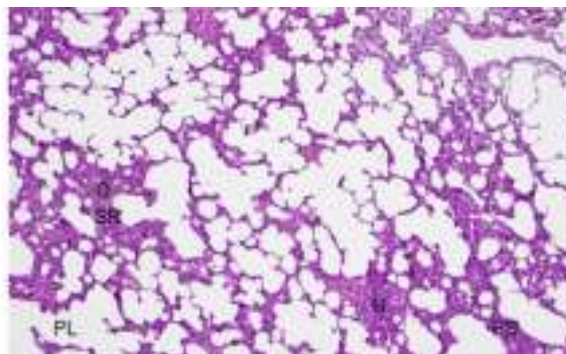


Figure 5. Histopathological picture of rat lungs in treatment group 2 which was given MSG and *Lannea coromandelica* extract at a dose of 500 mg/kg BW for 28 days. The picture shows inflammatory cell infiltration, pulmonary oedema, dilation of the alveolus lumen, thickening of the alveolar septum and necrosis with a score of 1 (mild damage).

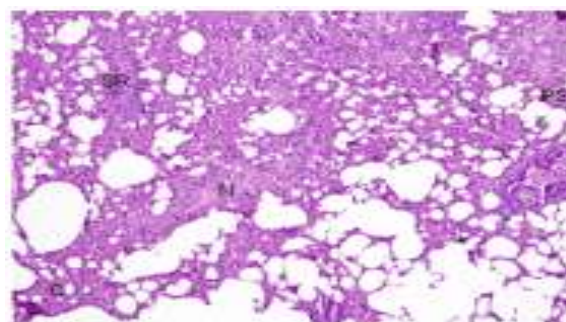


Figure 6. Histopathological picture of rat lungs in treatment group 3 which was given MSG and *Lannea coromandelica* extract at a dose of 750 mg/kg BW for 28 days. seen in inflammatory cell infiltration and necrosis with a score of 1 (mild damage) while in pulmonary oedema and thickening of the alveolar septum with a score of 2 (moderate damage).

4. Discussion

Effect of *Lannea coromandelica* Stem Bark on Malondealdehyde Levels

The increase in MDA levels reflects lipid peroxidation, which indicates an increase in the number of free radicals in the body. (Kumala et al., 2021). The increase in lipid peroxidation observed in this study could be attributed to the direct effect of increased ROS production resulting from the excessive administration of MSG (Onyema & Alisi, 2012). The prevention of oxidative stress in this study will be proven by the use of exogenous antioxidants, namely *Lannea coromandelica* bark extract.

The Anova test results show that $P=0.045$ ($p<0.05$), this means there is a significant difference between groups. So it is necessary to do further statistical tests (Post Hoc Test) to see which treatment is different. The results of further tests showed that the negative control group was significantly different from the treatment group. This is because the negative control group is a group that is conditioned to experience oxidative stress by giving monosodium glutamate, resulting in higher lung MDA levels (6.55 ± 1.71) compared to other groups. In contrast to the negative control group, the MDA level of treatment group 1 was the lowest (4.10 ± 1.43) compared to other groups. These results indicate that the negative control group experienced oxidative stress, which was caused by the administration of MSG and standard feed without antioxidant intake. The absence of antioxidant intake led to an increase in free radicals characterised by an increase in MDA levels. On the other hand, treatment with *Lannea*

coromandelica bark extract, which contains antioxidants, can prevent the increase in MDA levels caused by excessive MSG intake.

The group given *Lannea coromandelica* bark extract was more effective in reducing MDA levels than the group given MSG alone. This is caused by flavonoids contained in *Lannea coromandelica* bark extract. Flavonoids have antioxidant properties because they have the ability as effective acceptors through hydrogen proton donors from their hydroxyl groups. In this case, flavonoids will give one hydrogen atom to oxygen radicals (ROS), making these radicals more stable and reducing their ability to react with other compounds, including lipids in cell membranes (Yulianti Retno, 2019).

Effects of *Lannea coromandelica* Stem Bark on Histopathology of Rat Lungs

In a study conducted by Hegazy et al. (2017), it was found that long-term administration of MSG can cause degeneration, necrosis, and inflammation in lung epithelial tissue. This occurs due to the accumulation of glutamate in the body caused by MSG administration, and this can cause cell damage in the form of degeneration which then continues into necrosis. From the observation results, it was found that the group that only received MSG (KN group) showed the highest amount of cell damage. The cell damage could be caused by the treatment that only involved the administration of MSG and drinking water. The cells were damaged because MSG consumed in excess will increase the amount of free radicals in the body.

In this study, lung damage was measured through several parameters. Inflammatory cell infiltration occurs in response to free radicals, which results in an immune response with an increase in the number of leucocytes, especially neutrophils, in the blood vessels of the lung alveolus wall. The accumulation of inflammatory cells in the alveolus wall leads to thickening of the wall structure. In addition, the degree of damage is also assessed through the parameter of alveolar lumen dilation, which indicates emphysema. Pulmonary edema, characterised by the presence of fluid in the alveolus, is also a parameter of damage, where cells are difficult to find in the fluid, and is accompanied by a loose alveolar septum.

Based on the analysis of the histopathological picture data of Wistar rats, the value of $p = 0.458$ ($p > 0.05$) was obtained where there was no significant effect on the histological picture of the lungs after being given *Lannea coromandelica* extract in MSG-induced rats for 28 days. However, the group treated with MSG and *Lannea coromandelica* bark extract showed better results than the negative group that only received MSG. Among the treatment groups, the most effective was treatment group 1 which was given MSG and *Lannea coromandelica* at a low dose of 250 mg/kgBW. This can be due to the *dose-dependent biphasic effect*, where at low doses a substance can have a beneficial effect, but at higher doses, the effects that occur become contrary or opposite. (Marlina & Armalina, 2016).. *Lannea coromandelica* bark extract can reduce the level of lung damage because it contains many compounds such as flavonoids, saponins, phenols, steroids and tannins. (Puetri et al., 2021).

5. Conclusion

Lannea coromandelica bark extract can reduce MDA levels in the lungs of rats given MSG. In addition, the treatment group given *Lannea coromandelica* extract had lower lung damage than the group that only received MSG, although not significantly different. Thus, *Lannea coromandelica* bark extract has the potential to repair MSG-induced lung damage in male Wistar rats. This is due to the content of antioxidant compounds such as steroids, terpenoids, saponins, tannins, and flavonoids possessed by the *Lannea coromandelica* plant.

Reference

**THE PROTECTIVE EFFECT OF LANNEA COROMANDELICA STEM BARK EXTRACT
ON MALONDIALDEHYDE LEVELS AND LUNG HISTOPATHOLOGICAL FEATURES
OF MALE WISTAR RATS INDUCED BY MONOSODIUM GLUTAMATE**

Section A -Research paper

- Alam, B., Kwon, K., Lee, S., & Lee, S. (2017). *Lannea coromandelica* (Houtt.) Merr. Induces Heme Oxygenase 1 (HO-1) Expression and Reduces Oxidative Stress via the p38/c-Jun N-Terminal Kinase - Nuclear Factor Erythroid 2-Related Factor 2 (p38/JNK - NRF2)-Mediated Antioxidant Pathway. *International Journal of Molecular Sciences*, 1. <https://doi.org/10.3390/ijms18020266>
- Althanoon, S. A., & Taha, A. M. (2022). Histopathological changes on the pregnant rat's lung induced by sodium nitrite and monosodium glutamate. *Iraqi Journal of Veterinary Sciences*, 36(2), 419-424. <https://doi.org/10.33899/ijvs.2021.130464.1824>
- Arum, M., Wahyuningsih, S., & Amin, R. (2022). Effectiveness Test Of Transdermal Patch Of Ethanol Extract Of Javanese Bark (*Lannea Coromandelica* (Houtt.) Merr) Against Cuts In Male White Rats (*Rattus Norvegicus*) Effectiveness Test Of Transdermal Patch Of Ethanol Extract Of Javanese Bark (*Lannea Coromandelica* (Houtt.) Merr). *Madani Multidisciplinary Journal*, 2(2), 1001-1018.
- Kumala, A. R., Dagradi, E. M., Taruna, D., Ngesti, I., Physiology, D., Medicine, F., Hang, U., Surabaya, K., Java, P., & Indonesia, T. (2021). Reduction of MDA Levels in Male White Rats by Giving High Fat Diet and Mahogany Seed Extract. *Surabaya Biomedical Journal*, 1(1), 38-50.
- Kurtanty, D., Faqih, D. M., & Upa, N. P. (2019). Monosodium Glutamate Review How to Understand it Properly? In *Journal of Chemical Information and Modelling* (Vol. 53, Issue 9).
- Marlina, I., & Armalina, D. (2016). Effect of Providing Graded Doses of White Dragon Fruit Peel Extract (*Hylocereus Undatus*) on the Microscopic Picture of Exposed *BabI/C* Mice Lungs. 5(4), 1026-1035.
- Onyema, O. O., & Alisi, C. S. (2012). *Monosodium Glutamate Induces Oxidative Stress and Affects Glucose Metabolism in the Kidney of Rats*. January.
- Puetri, N. R., Marlinda, Bayakmiko Yunsa, S. A., Dian, & Sundari. (2021). *Acute Toxicity Test of Ethanol Extract of Java Wood Leaf (Lannea coromandelica (Houtt.) Merr.) on Wistar Rats*. 357-362.
- Putri Laksmi Desya Putu Sayu Ni. (2020). Changes in Endogenous Enzymatic Antioxidant Activity Resulting from Monosodium Glutamate (MSG) Consumption Based on Dose, Exposure Time, and Region in Brain Tissue. *Journal of Medical and Health Sciences*, 7(3), 547-553.
- Yuliana, E. F., In, M., & Zakiah, M. (2019). Histopathological features and Regeneration Ability of Kidney Cortex of Adult Male White Rats after Discontinuation of Monosodium Glutamate (MSG) Exposure. *Journal of Cerebellum*, 5(1), 1270-1281.
- Yulianti Retno. (2019). *Effectiveness of soursop leaf extract* (. 6(2), 65-71. <https://doi.org/10.22236/farmasains.v6i2.5134>