



THE ROLE OF BEDSIDE THORACIC ULTRASOUND VERSUS THORACIC CT IN THE DIAGNOSIS OF CRITICAL LUNG DISEASES IN ICU

Muhammad Ali Ibrahim Ali ¹, Horia Ahmed Farran Youssif ², Eman M. Moazen³, Manal Foad Abd Elmoniem Ebrahim ^{4*}

Article History: Received: 05.05.2023

Revised: 18.06.2023

Accepted: 29.06.2023

Abstract

Background: LUS is a crucial component of critical care ultrasonography because it enables the intensivist to assess the pleural space and the lung. LUS is the "go-to" modality for quickly, accurately, and safely scanning the lung and pleura due to its simplicity of use, speed, repeatability, and dependability. **Aim of the Study:** To evaluate the detection accuracy of Transthoracic ultrasound (TUS) for the identification of different pathological anomalies in severely ill patients, Utilizing CT as the gold standard. **Patients and Methods:** Al-zahraa university hospital's anesthesia ICU department conducted this prospective cohort study with 60 seriously ill patients who had recently advanced respiratory distress. **Results:** As regarding pulmonary edema it was detected with chest ultrasound and chest CT equally in 15 (25 %) for both. Pulmonary embolism was detected with chest US and chest CT in 1 (1.7%), 6 (10 %) patients respectively. While pneumonia was detected with chest US and chest CT in 13 (21.6%), 12 (20%) patients respectively. COPD and asthma were detected with chest US and chest CT in 22 (36.7 %) and 20 (33.3 %) patients respectively. Finally, pneumothorax, it was detected with chest US, and chest CT in 9 (15%), 7 (11,7%) patients respectively. **Conclusion:** The danger of transporting unstable patients and exposure to radiation is eliminated when using bedside chest ultrasonography, which is a very sensitive and specific technique for the diagnosis

Key Words: Chest Ct; Traditional; Bedside Chest Ultrasound

1.Resident of Anesthesia, Intensive care and Pain Management, Faculty of Medicine for Girls, Al-Azhar University, Cairo, Egypt.

2. Professor of Anesthesia, Intensive care and Pain Management. Faculty of Medicine for Girls, Al-Azhar University, Cairo, Egypt.

3.Lecturer of Chest Diseases, Faculty of Medicine for Girls, Al-Azhar University, Cairo, Egypt.

4. Assistant Professor of Anesthesia, Intensive care and Pain Management, Faculty of Medicine for Girls, Al-Azhar University, Cairo, Egypt.

* **Corresponding Author:** Dr., Manal Foad Abd Elmoniem **Email:** d_taha66@yahoo.com

DOI: 10.48047/ecb/2023.12.8.564

Introduction:

Several pathological conditions, including pneumothorax, consolidations, pleural effusion, ARDS, and pulmonary edema, were found by chest ultrasonography. Among intensivists, the idea of utilizing bedside ultrasound to check the lung is becoming more and more common. The Bedside Lung Ultrasonography in Emergency Department (BLUE-protocol) is a novel diagnostic ultrasonography technique that is intended to be utilized in combination with plain clinical data. It implies a careful investigation that may be finished in ten minutes. [1].

Although thoracic CT is now regarded as the ideal method of diagnosing and directing treatment process in critically ill patients, performing a thoracic CT scan demands transportation to the department of radiology, a risky method requiring the existence of trained physicians and sophisticated cardio-pulmonary monitoring. Fortunately, portable ultrasound now makes patient

assessment possible whenever and wherever. Moreover, helical multi-detector row CT exposes the patient to a high radiation dosage, limiting the procedure's reproducibility. When repeated exams to further study and monitor a pathological condition, the danger of overexposure to ionizing radiation should not be understated [2].

The common forms of pulmonary emergencies: respiratory edema Pneumothorax, pneumonia, acute exacerbations of COPD and asthma, and pulmonary embolism [3]

Patients and Methods:

Aim of the work: Assessing the detection accuracy of Transthoracic ultrasound for the identification of different pathological anomalies in severely ill patients, utilizing CT as the gold standard.

Design and settings of the study: A prospective cohort investigation was conducted in anesthesia ICU department, Al-Zahraa University hospital.

Study population: The study was conducted on 60 severely sick patients, had respiratory difficulty, a

feverish cough, purulent expectoration, or hypoxia. After receiving informed consents from patients or their family, if they were unaware, and ethical study permission from the Al-Zahraa University hospital ethics committee. All the study patients were subjected to lung ultrasound (LUS) and chest CT scan. It was carried out during the period from October 2021 to October 2022.

Inclusion standards: American society of Anesthesia (ASA) physical status II and III, age 21 - 60 years old, both sexes will be included

Exclusion criteria: Refusal to participate in the research, age less than 21 years, Patients with inapplicable lung ultrasound: as pregnant females, subcutaneous emphysema, large thoracic dressings, extremely obese with severe emphysema or hematoma of the chest wall transporting patients at risk for CT.

A written informed permission was obtained from the patient or his family, if they were not aware, after receiving clearance from the hospital ethical committee. Pneumothorax, pleural effusion, lung consolidation, and lung edema were the four pathologic states that each radiological imaging technology was used to assess.

All patients were subjected to the following:

All research participants had complete medical history collection, clinical examinations, and laboratory tests. All patients had lung ultrasound (LUS) and CT chest exams.

Chest CT scan: employing a 160-detector

multidetector scanner (Toshiba, Prime Aquilion Japan)

Lung Ultrasound: was carried out utilizing (Sonosite M-turbo, FUGIFILM, inc., Usturalia) as soon as the patient was admitted for the evaluation of the pleura and lung in this investigation. Two probes were used, mostly a phased array low frequency 5 MHz probe and sometimes a linear high frequency 7-10 MHz probe utilizing time motion (M-mode) and grayscale (B-mode). Subjects were evaluated anteriorly while supine and posteriorly while in a semi-lateral posture. The final diagnosis was made using lung ultrasound performed by the same operator and reviewed by a radiologist with advanced training in the field. The clinical status of the patient served as their guide, and neither the operator nor the expert radiologist were aware of any further chest radiography results. There were three standard points looked at. By placing two hands on the patient's chest, without the thumbs touching, it is possible to determine these spots (the dominant hand contacting the clavicle). The center of the upper hand is where the top point is located, and the middle of the lower palm is where the lower point is located. The bottom BLUE point and a vertical line at the posterior axillary line intersect at the third point, which is known as PLAPS (postero-lateral alveolar or pleural disorder).

Each research participant had a full medical history interview, clinical assessment using the dyspnea index, and laboratory testing:

Table (1): The mMRC (modified Medical Research Council) dyspnea scale [4].

Grade	Symptoms	Description
0	Little	Dyspnea only occurs during vigorous exercise
1	Mild	Dyspnea when rushing or climbing a small incline
2	Moderate	due to dyspnea or the need to halt while walking at one's own speed, moves more slowly than persons their age
3	Many	stops to catch his breath after walking for a short distance (less than 100 yards) or after some time.
4	Very much	Extremely breathless to leave the home or too dyspneic to dress

The following evaluations of ultrasonography examination signals with two possible outcomes (Available or Absence) were made: Lung sliding, artifact analysis (A or B lines), and an unusual ultrasonic shadow (Pleural effusion or alveolar consolidation). It was crucial to do a lateral sub-posterior search for the posterolateral alveolar and/or pleural syndrome (PLAPS). After they were discovered, further ultrasonic symptoms including the lung point and sinusoid signals were described (Table 2). The same probe was used to look for

deep venous thrombosis in individuals who were thought to have pulmonary embolism. Positive results included the visualization of anatomic echoic intraluminal thrombosis or the lack of compressibility. Methodically documenting the symptoms of each condition, the ultrasonography results were compared to the ICU team's diagnosis.

Table (2): chest sonography's importance in identifying acute dyspnea [5]/

Ultrasonic sign	Ultrasonic description
Sliding	dynamic transverse sparkling movement that is coordinated with breathing and evident at the pleural line
A lines	Regularly occurring horizontal lines parallel to the pleural line (normal sign)
B lines	pleural-based vertical lines (fewer than three lines per view, typical indication)
Consolidation	Hypoechoic shadow
Pleural effusion	primarily appears as a homogenous, anechoic gap between the parietal and visceral pleura.
Lung point	Suddenly, a lung pattern was seen on and off.
Sinusoids sign	Pleural effusion-specific sinusoidal waveform on M mode determined by inhalator centrifugal shifting of the visceral pleura with reduction in perceived thickness of the effusion

The BLUE protocol states that the combination of these signals yields eight profiles. These profiles include the A-profile (which links anterior lung sliding to A-lines), the A'-profile (which links anterior lung sliding to lung rockets), the B-profile (which relates lung rockets to anterior lung slipping), the B'-profile (which links anterior lung

sliding to abolished lungsliding), the C-profile (which, independent of quantity and size, signals the consolidation of the anterior lung), the A/B profile (which links anterior lung consolidation to half of an A-profile at one lung and a half of (is an A-profile without PLAPS or DVT).

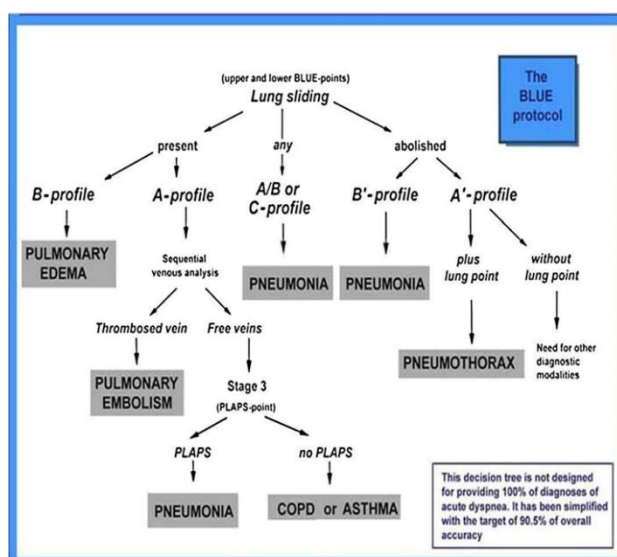


Figure (1): The BLUE protocol (1)

Calculating the sample size:

Convenience sampling is the sampling approach. Patients were sought out all through the investigation. The clinical calculator was used to determine the sample size. Utilizing the sensitivity and specificity from previously published investigations, a minimum sample size of 45 was needed [6].

Statistical Analysis:

A Microsoft Excel 2010 excel sheet is used to gather, code, and statistically evaluate the data. The quantitative data with non-parametric distributions were displayed as median with inter quartile range (IQR), whereas the qualitative data were given as numbers and percentages, means, and standard deviations. In order to compare two sets of quantitative variables, the Unpaired Student

T-test was utilized. The terms mean, standard deviation, frequent, and percentage were used to describe statistical data. Non-parametric data was reported as number and percentage of the total, whereas parametric information was represented as mean ± standard deviation (SD).

For the purpose of identifying any association between two quantitative factors in one group, the linear correlation coefficient (r) was utilized.

Reliability and variability within and between operators: For variance across many readings, paired-samples analysis was used to compute the median and SD for each reading. The variance between readers was calculated using the T-test. To evaluate the repeatability of rates between learners and experts, the intra-class correlation coefficient (ICC) was determined. ICC evaluated intra-operator

dependability. Based on a mean-rating ($k = 2$), absolute-agreement, 2-way mixed-effects model, ICC estimations and associated 95% confidence intervals were computed utilizing SPSS. ICC estimates with values under 0.5 are a sign of low reliability, those with values between 0.5 and 0.75 are a sign of moderate reliability, those with values between 0.75 and 0.9 are a sign of high dependability, and those with values above 0.90 are a sign of outstanding reliability.

A P value of 0.05 or above is deemed significant, and the acceptable margin of error was set at 5%. The confidence interval was also set to 95%. When comparing lung US data to chest CXR results, which were deemed as the standard reference, specificity, sensitivity, PPV, NPV, and accuracy were utilized as metrics of validity.

Considering the test positive (a) and negative (b); and the number of positive (c) and negative (d) instances in the non-diseased group.

- **Sensitivity:** the likelihood that a test will provide a positive result when the illness is established (really positive rate).
= $a / (a+b)$
- **Specificity:** likelihood that a test will come back negative when the illness is absent (really negative rate).
= $d / (c+d)$
- **Positive probability ratio:** ratio between the

likelihood that a test will come back positive given the existence of an illness and the probability that a test will come back positive given the lack of a disease, i.e. = $\text{Sensitivity} / (1 - \text{Specificity}) = \text{True positive rate} / \text{False positive rate}$

- **Negative probability ratio:** ratio between the likelihood that a test will come back negative given the existence of an illness and the probability that a test will come back negative given the lack of a disease, i.e. = $(1 - \text{Sensitivity}) / \text{Specificity} = \text{False Negative Rate} / \text{True Negative Rate}$
- **Positive predictive value (PPV):** if the test is positive, the likelihood that the illness is present. = $a / (a+c)$
- **Negative predictive value (NPV):** when the test is negative, the likelihood that the illness is not existent. = $d / (b+d)$
- Percentages are used to indicate the sensitivity, specificity, PPV and NPV as well as the prevalence of diseases. They use "precise" Clopper-Pearson confidence intervals for their confidence intervals.

$$PPV = \frac{\text{sensitivity} \times \text{prevalence}}{\text{sensitivity} \times \text{prevalence} + (1 - \text{specificity}) \times (1 - \text{prevalence})}$$

$$NPV = \frac{\text{specificity} \times (1 - \text{prevalence})}{(1 - \text{sensitivity}) \times \text{prevalence} + \text{specificity} \times (1 - \text{prevalence})}$$

Results:

Table (3): demographic information for all patients examined

Characteristics		Studied patients No. = 60
Gender	Males	38 (63.3%)
	Females	22 (36.7%)
Age (years)	Mean±SD	37.6 ± 13.5
	Range	21 – 60
Special habits	Smoker	31(51.70%)
	Non-smoker	29 (48.30%)

This table shows that in terms of gender, there were 22 women (36.7%) and 38 men (63.3%) among the investigated patients.

With a minimum age of 21 and a maximum age of 60, the average age of all patients in the study was

37.6 13.5 years. The patient under study included 31 smokers (51.7% of smokers) and 29 non-smokers (48.3% of non-smokers).

Table (4): Clinical characteristics of the studied patients

Character	All studied population No. = 60
Cough	37 (61.67%)
Dyspnea	60 (100.00%)
Fever	22 (36.67%)
Wheeze	13 (21.67%)
Cyanosis	1 (1.67%)
Lower limb edema	10 (16.67%)
Types of co-morbidities	
HTN	38 (63.33%)
DM	27 (45.00%)
IHD	15 (25.00%)
BA	20 (33.33%)

HTN: Hypertension; IHD: ischemic heart disease; DM: diabetes mellitus; BA: bronchialashma. This table shows the symptoms, signs and comorbidities associated with the pathologies. Cough is present in 37 patients (61.67%), dyspnea which is the main complain is present in all patients 60

(100.00%), fever in 22 patients (36.67%), wheeze in 13 patients (21.67%), cyanosis in one patient (1.67%), lower limb edema in 10 patients (16.67%). As regard the comorbidities, HTN was present in 38 patients (63.33%), DM in 27 patients (45.00%), IHD in 15 patients (25.00%) and BA in 20 patients (33.33%).

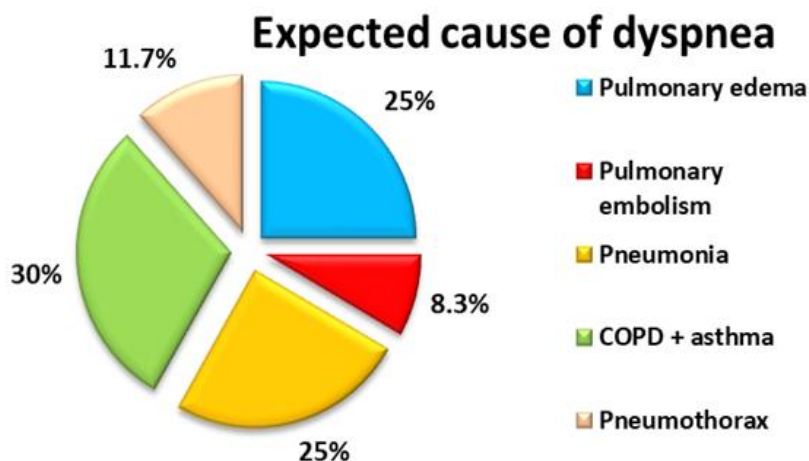


Figure (2): Description of expected cause of dyspnea in all studied patients.

Figure (2) shows that according to expected cause of dyspnea from history and clinical examination there were 15 patients (25%) with pulmonary edema, 5 patients (8.3%) with pulmonary

embolism, 15 patients (25%) with pneumonia, 18 patients (30%) with COPD & asthma exacerbation and 7 patients (11.7%) with pneumothorax.

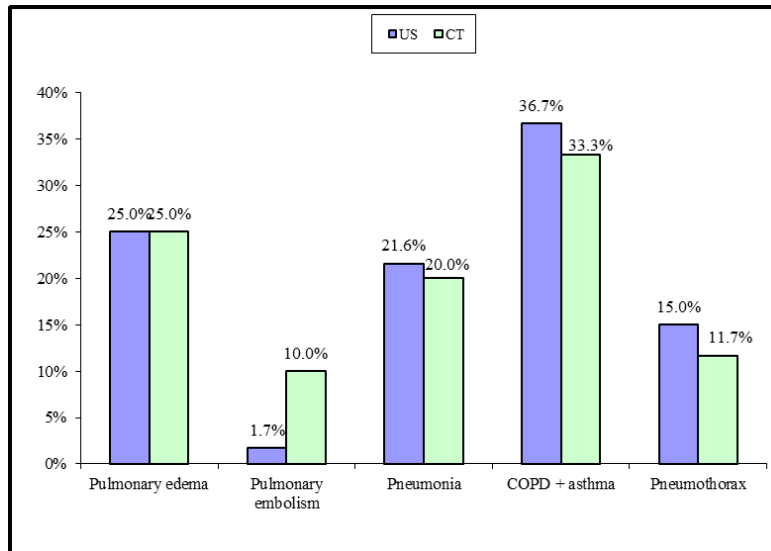


Figure (3): Comparison between CT & LUS in diagnosis of different diseases in all study patients.

As regarding **pulmonary edema**, it was detected with chest US and chest CT equally in 15 (25 %) for both. **Pulmonary embolism** was detected with chest US and chest CT in 1 (1.7%), 6 (10 %) patients respectively. While **pneumonia** was detected with chest US and chest CT in 13 (21.6%),

12 (20%) patients respectively. **COPD and asthma** were detected with chest US and chest CT in 22 (36.7 %) and 20 (33.3 %) patients respectively. Finally, **pneumothorax**, it was detected with chest US, and chest CT in 9 (15%), 7 (11.7%) patients respectively.

Table (4): Diagnostic accuracy, specificity, and sensitivity of US in all trial participants

Pathology	US	CT		P-value	TP	TN	FP	FN	Accuracy	Sensitivity	Specificity	PPV	NPV
		Positive	Negative										
Pulmonary edema	Positive	14	1	<0.001	14	44	1	1	96.7%	93.3%	97.8%	93.3%	97.8%
	Negative	1	44										
Pulmonary embolism	Positive	1	0	0.002	1	54	0	5	91.7%	16.7%	100.0%	100.0%	91.5%
	Negative	5	54										
Pneumonia	Positive	11	2	<0.001	11	46	2	1	95.0%	91.7%	95.8%	84.6%	97.9%
	Negative	1	46										
COPD + Asthma	Positive	19	3	<0.001	19	37	3	1	93.3%	95.0%	92.5%	86.4%	97.4%
	Negative	1	37										
Pneumothorax	Positive	6	3	<0.001	6	50	3	1	93.3%	85.7%	94.3%	66.7%	98.0%
	Negative	1	50										

TP: True positive, FP: False positive, TN: True negative, FN: False negative

As regard **pulmonary edema**, 14 patients were positive in chest ultrasound and chest CT together (true positive “TP”), 1 patient was positive in US only (false positive “FP”) , another 1 patient was positive in chest CT only (false negative “FN”) and 44 patients free from pulmonary edema (true negative “TN”). So, it was diagnosed with chest US and chest CT equally in 15 patients (25%). Chest ultrasonography has a sensitivity and specificity of 93.3% and 97.8% for pulmonary edema diagnosis, respectively.

Regarding **pulmonary embolism**, 1 patient was positive in chest ultrasound and chest CT together (TP), no patients were positive in US only (FP), 5 patients were positive in chest CT only (FN) and 54 patients free from pulmonary embolism (TN). So, it was detected with chest US and chest CT in 1 patient (1.7 %) and 6 patients (10%) respectively. In diagnosing **pulmonary embolism**, sensitivity and specificity of chest US were (16.7 %) and (100%) respectively.

As for **pneumonia**, 11 patients were positive in chest ultrasound and chest CT together (TP), 2 patients were positive in US only (FP), another 1 patient was positive in chest CT only (FN)and 46 patients free from pneumonia (TN). So, it was detected with chest US and chest CT in 13 patients (21.6 %) and 12 patients (20 %) respectively. In **pneumonia** diagnosing, 91.7 % sensitivity and 95.8% specificity of chest US.

Regarding **COPD and Asthma**, 19 patients were positive in chest ultrasound and chest CT together (TP), 3 patients were positive in US only (FP), another 1 patient was positive in chest CT only (FN) and 37 patients free from COPD and asthma (TN). So, it was diagnosed with chest ultrasound and chest CT in 22 patients (36.7 %) and 20 patients (33.3 %) respectively. In diagnosing **COPD and Asthma**, 95 % sensitivity and 92.5% specificity of chest US.

As for **pneumothorax**, 6 patients were positive in chest ultrasound and chest CT together (TP) , 3

patients were positive in US only (FP) , another 1 patient was positive in chest CT only (FN) and 50 patients free from pulmonary edema (TN). So it was detected with chest US and chest CT in 9 patients (15 %) and 7 patients (11.7%) respectively. In identifying **pneumothorax**, sensitivity and specificity of chest US were (85.7 %) and (94.3%) respectively. Chest US shows highly significant values in pulmonary edema, pneumonia, COPD and asthma, and pneumothorax as P value < 0.001 for all. Chest CT shows highly significant value in pulmonary embolism as P value 0. 002.

Discussion:

Effective therapy for critically sick patients hinges on the issue being identified promptly and accurately. The ICU team should swiftly integrate the findings of physical evaluation, laboratory, and radiological studies soon after first resuscitation in order to arrive at an accurate diagnosis, definite course of therapy, and optimal results. (Elmahalawy et al. 2017) [7].

The major conclusion of this research is that lung ultrasonography in the anesthetic ICU accurately diagnoses the most prevalent pathologic anomalies of the respiratory system seen in these patients. We assessed five prevalent anomalies that are crucial for patient treatment and decision-making (pneumonia, COPD, asthma, pulmonary edema, pulmonary embolism, and pneumothorax). (Bouhemad et al., 2014) [8].

According to the medical history and the clinical examination of our studied group we found that the expected Cause of dyspnea the suspected diagnosis were 15 patients (25%) with pulmonary edema, 1 patients (8.3%) with pulmonary embolism, 15 patients (25%) with pneumonia, 18 patients (30%)with COPD & asthma exacerbation and 7 patients (11.7%) with pneumothorax.

The key result from our research is the results with ultrasound were 15 patients (25%) diagnosed as pulmonary edema, 1 patients (1.7 %) diagnosed as pulmonary embolism, 13 patients (21.6%) diagnosed as pneumonia, 22 patients (36.7%) diagnosed as COPD & asthma and 9 patients (15%) diagnosed as

pneumothorax in the studied patients. While in CT, there were 15 patients (25%) diagnosed as pulmonary edema, 6 patients (10%) diagnosed as pulmonary embolism, 12 patients (20%) diagnosed as pneumonia, 20 patients (33.3%) diagnosed as COPD & asthma and 7 patients (11.7%) diagnosed as pneumothorax in the studied patients.

Throughout our study on patients suffering from pulmonary edema specificity and sensitivity of chest US in were (93.3%) and (97.8%) respectively.

Our findings concurred with El Mahalawy et al. 2017 [8] revealed that Both the sensitivity and specificity of the LUS were 93%.

Another study was similar to our results was conducted by Xirouchaki et al. 2011 [9] They found that the sensitivity, specificity, and reliability of chest ultrasonography in identifying pulmonary edema were 94%, 93%, and 94% respectively, which was high. They evaluated 42 mechanically ventilated patients with LUS.

Pulmonary embolism is a critical lung pathology which may be fatal if not diagnosed and managed as early as possible (Bianco et al., 2017) [10].

As regard pulmonary embolism, the current study shows that sensitivity and specificity of LUS in cases of pulmonary embolism were 16.7 % and 100 %, respectively.

This outcome was nearer to Suzan et al., 2014 [11] who revealed that TUS has a sensitivity and specificity for lung embolism of 21.9% and 80.9%, respectively.

Unfortunately, these findings were in conflict with Lichtenstein, 2015 [12] who revealed that LUS had an 86% sensitivity and 67% specificity, for pulmonary embolism. The lack of any gold standard indicators has been the primary issue in many prospective investigations examining the reliability of chest ultrasound in the detection of pulmonary embolism. Hence, a healthy chest imaging scan does not rule out lung embolism.

ICU patients often acquire pneumonia, whether it is brand-new or connected to the reason they were there. LUS is a reliable diagnostic method for pneumonia nowadays. (Elmahalawy et al. 2017) [7].

In our investigation, ultrasonography has a great sensitivity and specificity for the detection of pneumonia (91.7% and 95.8%, respectively).

These outcomes were more similar to the research on Nazerian et al., 2015 [13] on 285 patients with pneumonia and they showed that sensitivity and specificity for diagnosing pneumonia significantly high with LUS (81%) and (94%) respectively.

Also matched with Cortellaro et al. 2012 [14] who studied 120 patients with pneumonia and showed that the sensitivity and specificity was substantially high with LUS (99%) and (95%) respectively. Also, our findings agreed with Agmy et al. 2014

[15] revealed that LUS had an 87 and 100% sensitivity and specificity for pneumonia, respectively.

These findings didn't accord with Chavez et al. 2015 [16] performed an investigation on 62 patients with pneumonia and showed that LUS was diagnostic in 46 (74%) patients which is relatively low.

Also disagreed with nafae et al. 2013 [17] revealed that the lus's sensitivity of 75% and specificity of 97% for pneumoria. Since the LUS method only permits the detection of consolidation areas when such areas are linked to the pleural surface, this may provide an explanation for this variance in accuracy.

The sensitivity of ultrasonography in our investigation was high in diagnosing COPD & asthma (95%) while specificity was (92.5%).

Throughout the course of our research, we found that chest ultrasonography had a sensitivity of 85.7%, a specificity of 94.3%, and an accuracy of 93.3% for identifying pneumothorax.

Our study's findings were consistent with El Gendy et al. 2018 [18] on his study on 192 patients subjected to LUS and he found that LUS considerably high sensitivity (86.1%) and diagnostic accuracy (95.3%). Also, many meta analysis studies like Ding et al. 2011 [19] shows chest ultrasonography has a high sensitivity and specificity (88% and 99%, respectively), Alrajab et al. 2013 [20] shows 78.6% and 98.4%, respectively, for US sensitivity and specificity.

Other studies like Hyacinthe et al. 2012 [21] differ from our study, in his study the sensitivity of LUS to pneumothorax in 119 individuals with chest trauma was only 53%.

Operator alignment brought on by underlying diagnosis of severe COPD, asthma, or chest trauma (diseases linked to a higher risk of pneumothorax) may account for the disparity. Our findings show that LUS is a trustworthy method for bedside identification of these anomalies since it did not miss any clinically relevant pneumothorax, COPD, or asthma patients.

Conclusion: The danger of transporting unstable patients and exposure to radiation is eliminated when using bedside chest ultrasonography, which is a very sensitive and specific technique for the diagnosis and assessment of many chest disorders.

Availability of data and materials:

All the information generated or assessed during this study is included in this article.

Abbreviations

CT: Computed Tomography

TUS: Transthoracic ultrasound

LUS: Lung Ultrasound

ICU: Intensive Care Unit

Ethical Consideration:

This study was approved by the ethical committee, Faculty of Medicine for Girls, Al-Azhar University, Cairo, Egypt with ID No. (IRB00012239).

REFERENCES

1. Lichtenstein, D.A. (2016). The BLUE-Protocol, Venous Part: Deep Venous Thrombosis in the Critically Ill. Technique and Results for the Diagnosis of Acute Pulmonary Embolism. In: Lung Ultrasound in the Critically Ill. Springer, Cham. https://doi.org/10.1007/978-3-319-15371-1_18
2. Chiumello D, Umbrello M, Papa GF et al. (2019) Global and regional diagnostic accuracy of lung ultrasound compared to CT in patients respiratory disorders. *Critical care medicine.*; 47(11):1599-606.
3. Arbelot C, Ferrari F, Bouhemad B et al. (2015) Lung ultrasound in acute respiratory distress syndrome and acute lung injury. *Current Opin Crit Care*; 14:70-4.
4. Agmy GR, Sherif H, Mohamed AS, et al. (2018) Assessment of severe dyspnea in critically ill patients by transthoracic sonography: Fayoum experience of the bedside lung ultrasonography in emergency protocol *Egy Bronchol J.*; 12: 92-97.
5. Daabis R, Banawan L, Rabea a, Elnakedy A, Sadek A. (2014) Relevance of chest sonography in the diagnosis of acute respiratory failure: Comparison with current diagnostic tools in intensive care units *Egyptian Journal of Chest Diseases and Tuberculosis* 63, 979–985.
6. Nermeen Mohammed Ali Hassan M A Maguid Neven M Gamil Mohamed M Tawfeek Sameh Saber Hegab (2019) Evaluation of the role of bed side lung ultrasound versus chest x- ray in critically ill patients. doi: 10.21608/ZUMJ.2019.10704.11150
7. Elmahalawy II, Doha NM, Ebeid OM et al. (2017) Role of thoracic ultrasound in diagnosis of pulmonary and pleural diseases in critically ill patients. *Egyptian Journal of Chest Diseases and Tuberculosis.*; 66(2):261-6.
8. Bouhemad B, Zhang M, Lu Q et al. (2014) Clinical review: bedside lung ultrasound in critical care practice. *Crit Care*; 11:205.
9. Xirouchaki N., Magkanas E., Vaporidi K., et al. (2011) Lung ultrasound in critically ill patients comparison with bedside chest radiography *Intensive Care Med*; 37 (9): 1488-1493.
10. Bianco F, Bucciarelli V, Ricci F et al. (2017) Lung ultrasonography: a practical guide for cardiologists. *Journal of Cardiovascular Medicine.*; 18(7):501-9.
11. Suzan E, Ray P, Birolleau S et al. (2014) Acute respiratory failure in the elderly: etiology, emergency diagnosis and prognosis. *Crit Care*; 5(3): 70-77.
12. Lichtenstein DA. (2015) BLUE-protocol and FALLS-protocol: two applications of lung ultrasound in the critically ill. *Chest*; 147:1659–1670.
13. Nazerian P, Volpicelli G, Vanni S et al. (2015) Accuracy of lung ultrasound for the diagnosis of consolidations when compared to chest computed tomography. *The American journal of emergency medicine.*; 33(5):620-5.
14. Cortellaro F, Colombo S, Coen D et al. (2012) Lung ultrasound is an accurate diagnostic tool for the diagnosis of pneumonia in the emergency department. *Emergency medicine journal.*; 29(1):19-23.
15. Agmy GM, Mohamed S, Gad Y. (2014) Transthoracic chest ultrasound in critically ill patients. *Eur Respir J*; 44: P4968
16. Chavez M.A., Shams N., Ellington L.E. (2015) Lung ultrasound for the diagnosis of pneumonia in adults: a systematic review and meta-analysis. *Respir Res.*; 15:50.
17. Nafae R, Shebl ER, El-Ghamry R et al. (2013) Adjuvant role of lung ultrasound in the diagnosis of pneumonia in intensive care unit patients. *Egypt J Chest Dis Tuberc*; 62:281–285
18. El Gendy M, Abdalla W, Abdelaziz AA et al. (2018) Lung ultrasound versus chest radiography for the diagnosis of pneumothorax in critically ill patients: A prospective, single-blind study. *Saudi Anaes J.*; 265-269.
19. Ding W, Shen Y, Yang J et al. (2011) Diagnosis of pneumothorax by radiography and ultrasonography: a metaanalysis. *Chest.*; 14.
20. Alrajab S, Youssef AM, Akkus NI, et al. (2013) Pleural ultrasonography versus chest radiography for the diagnosis of pneumothorax: review of the literature and meta-analysis, *Crit. Care.*; 17: 208-212.
21. Hyacinthe AC, Broux C, Francony G et al. (2012) Diagnostic accuracy of ultrasonography in the acute assessment of common thoracic lesions after trauma, *Chest.*; 141: 1177-1179.