



Comparative analysis between pedicle screws and hybrid instrumentation in posterior spinal fusion in Adolescent idiopathic scoliosis

Omar Mohamed Darwish, Helmy Abd-ElHalim Al Desouky, Ahmed Abdullah Soliman EL-FIKI, Hussein Abdelrahman Fathalla, Hossam Eldin Mostafa

Neurosurgery Department, Faculty of Medicine, Cairo University, Cairo, Egypt

Email: Omar-darwich@hotmail.com

Abstract

Background: Adolescent idiopathic scoliosis (AIS) is a complex 3D deformity of the spine. Its prevalence is 2% in the general population, with almost 10% requiring surgery. Spinal instrumentation in AIS aims to correct the deformity and maintain long term stability of the spine till the bone healing is ensured, the purpose of this study is to compare between the preoperative and post operative radiographic and results of posterior spinal fusion in AIS using the whole pedicle screw technique and the hybrid technique (hooks= pedicle screws).

Objective: This thesis aims to provide analytical comparison between whole pedicle screws, and the hybrid instrumentation (hooks + pedicle screws) in posterior spinal fusion in AIS.

Methods: This study is conducted on 28 patients fulfilling the inclusion criteria(between 12-20 years old) with AIS admitted at the spine unit in KASR AL AINI hospital. Patients were divided in 2 groups on simple randomized basis, one group will be operated using the whole pedicle screws while the other group will be operated using the hybrid technique (hooks + pedicle screws) for posterior spinal fusion and correction of deformity using neurophysiological monitoring in patients as needed.

Results: our study included 28 patients, seven males(25%), twenty one females (75%), the mean age in our study was 15.5 ± 2.5 , twenty one patients were operated using the pedicle technique, while seven patients were operated using the hybrid technique, the mean of operative time was 3.5 ± 0.9 , the mean of blood loss was 607.1 ± 244 , seventeen patients (60.7%) had levelled shoulders, ten patients (35.7%) had right shoulder up, one patient had left shoulder up, the mean of cobb angle in our cases was 59.4 ± 15.2 , while the mean of cobb angle post 11.8 ± 7.9 , in our study there were (85.7%) improvement rate more than 70% concerning the cobb angle, (75%) improvement rate more than 70% in apical vertebral translation in all cases,

Conclusion: As per our results, the earlier the correction for AIS, the better radiographic curve correction, the earlier the surgery the better height improvement due to increased flexibility, pedicle screws and hybrid system provides great correction of spinal deformities.

Keywords: AIS, scoliosis, adolescent, deformity, hybrid, instrumentation, hooks, pedicle.

Introduction

Adolescent idiopathic scoliosis (AIS) a progressive complex 3D deformity of the spine which leads to cosmetic and body image disturbance and violate the quality of life.

Its prevalence is between 2% and 3% in the general population, with almost 10% of patients requiring some form of treatment and up to 0.1% undergoing surgery.¹⁻⁴

The surgical indication of AIS has been accepted as cob angle greater than 45° .⁵⁻⁷

Spinal instrumentation and fusion is the most common intervention for Adolescent idiopathic scoliosis (AIS) with moderate or severe curve, the goal of which is to correct the deformity and prevent its progression as The cosmetic aspect of the deformity is the biggest concern to the patient and is often accompanied by psychosocial distress In addition, severe curves can cause cardiopulmonary distress¹⁻⁴. With proven benefits from surgery, the aims of treatment are to improve the cosmetic and functional outcomes.

The decision that whether or not undergoing surgery is still difficult to make for AIS patients and families due to concerns in their prospective⁸⁻¹³. Some time AIS patients and families have to delay surgery to avoid conflicts with school and other activities. several other patients include the influence of surgery on the spinal growth, the influence on patients 's psychological stress or the influence on recovery ability. thus delay surgery into adulthood is not uncommon in clinical practice

Obtaining correction in the coronal plane is not the only important endpoint anymore. With better understanding of spinal biomechanics and the long-term effects of multiplanar imbalance, we now know that sagittal balance is equally, if not more, important. Better correction of deformities has also been facilitated by an improvement in the design of implants and a better understanding of metallurgy. Understanding the unique character of each deformity is important. In addition, using the most appropriate implant and applying all the principles of correction in a bespoke manner is important to achieve optimum correction.

Surgical treatment in idiopathic scoliosis aims to restore global coronal and sagittal balance, addresses rotational deformity and minimize complications .

All-screw techniques can lead to a loss of thoracic kyphosis, particularly in high implant density construct¹⁶. the resultant hypokyphosis can cause patient morbidity from adjacent level junctional deformity and accelerated degeneration due to global sagittal imbalance. furthermore, pedicle screw insertion is not a benign procedure, with incidence of misplacement in thoracic screw when assessed with postoperative computed tomography (CT).¹⁷

Additionally, the use of segmental pedicle screws has resulted in a significant increase in the cost of the surgery.¹⁸

To address some of these concerns in scoliosis surgery, it is possible to combine pedicle screw constructs with alternative implants that facilitate rod fixation to vertebrae in hybrid constructs. such technique include the use of pedicle hooks.

The purpose of this study was to assess clinical and radiological results of patients with AIS treated by a hybrid (pedicle screws+ hooks) compared to whole pedicle screw technique.

Subjects and Methods:

This is a Non randomized clinical trial with random sample of 30 patients, which was designed to compare between the whole pedicles screws technique, and the hybrid technique (pedicle screws + hooks) in posterior spinal fusion in Adolescent Idiopathic Scoliosis (AIS). Patients of both sexes between the age of (12-20) years with adolescent idiopathic scoliosis (AIS) with cobb angle > 40.

Inclusion criteria

Patients of both sexes between the age (12-20) years with Adolescent Idiopathic scoliosis (AIS) with cobb angle >40.

Exclusion criteria

- Patients of both sexes above 20 years with Adolescent Idiopathic Scoliosis (AIS).
- Other types of scoliosis (congenital, Neuro-muscular).

Presentation

Patients of both sexes between the age of (12-20) years presented to our Out Patient (OP) Neurosurgery clinic complaining of cosmetic deformity or back pain.

Standard clinical management

- Scoliosis is frequently diagnosed by recognizing truncal asymmetry, trunk may appear to sway toward one side, or may be greater gap between the rib cage and arm. Physical examination of reveals other Musculo skeletal abnormalities associated with scoliotic deformities.
- Full Neurological evaluation is done for all patients including muscle strength, bulk and tone, reflexes and sensation. Careful examination of any cutaneous lesions

Special tests are done during examination of the patient:

- 1- Adams-forward bending test to note any curvature of the spine or rib hump.
 - 2- Scoliometer which can be used in conjunction with the Adams forward bending test to quantify rotation of the trunk
- Limb-length evaluation as it may result in pelvic tilt which can induce (compensatory scoliosis)

Imaging studies

Peri-operative:

- Xray whole spine postero-anterior (PA) position including pelvis: to assess Risser's grading and triradiate cartilage closure to measure expected patient growth and curve progression, then measure Cobb angles detecting the major and minor curves and detecting the lumbar modifier.
- Xray whole spine lateral position: in order to measure main thoracic kyphosis from D5-12 to measure sagittal thoracic modifier.
- Xray whole spine with right and left bending positions to assess the flexibility of the curves for detection which curve is structural or non-structural and to assess proper LENKE classification.
- CT whole spine to measure angle of vertebral rotation, thickness of the pedicles and length of the screws.
- MRI whole spine to exclude presence of intraspinal anomalies (syringomyelia, distomatomyelia and tethered cord), spinal cord tumors and spondylodiscitis.

Post-operative: -Xray whole spine to assess degree of correction and measuring Cobb angle post operative.

Laboratory investigations:

Routine laboratory assessment is done for all patients including CBC, PT, PTT, INR, Liver functions (ALT, AST, BILIRUBIN, Albumin), kidney functions (urea, creatinine), Na and K.

Pulmonary functions are done upon anesthesia request in major deformities Cobb angle >80.

Surgical technique:

- All patients had IV antibiotics at anesthesia induction and two doses postoperatively.
- Multimodal spinal cord monitoring in the form of MEPs, SSEPs and EMG prior to positioning.
- Patient is under general anesthesia during skin incision and muscle dissection then total intravenous anesthesia started in order to enable neurophysiological monitoring afterwards.
- Patients were positioned in prone position on Jackson frame. Upper and lower end of the incision were marked under c-arm fluoroscopy.
- Each segment was operated solely regarding pedicle screws i.e., lumbar levels operated by skin incision and subperiosteal muscle separation, exposure of entry points. Insertion of pedicle screws followed by irrigation using soaked gauze of hydrogen peroxide then augmentation of the skin incision to include adjacent distal thoracic segment and so on. We performed inferior facetectomy in all levels prior to insertion of pedicle screws to increase spinal flexibility and allow deformity correction, other types of osteotomies that were used either Ponte or Smith Peterson osteotomies.

All pedicle screws technique:

Polyaxial screws were used, pedicle screws were placed bilaterally across the two cephalad – and the caudal – instrumented vertebrae to provide proximal and distal construct stability.

Additional pedicle screws were used across the convexity of the thoracic scoliosis to allow segmental correction.

Full density screws were placed along the concave side

Correction was achieved over the concave rod through a cantilever manoeuver with segmental vertebral translation /de-rotation across the apical scoliotic levels. or rod de-rotation technique.

Hybrid hook-screw technique:

This technique included a combination of pedicle hooks proximally and polyaxial pedicle screws distally. Bilateral screws across the two lowest and pedicle hooks in the upper instrumented vertebrae provided proximal and distal construct stability.

The scoliosis was corrected over the concave rod using rod de-rotation which achieved translation of the apical vertebrae toward the midline.

The concave rod was pre -contoured to restore sagittal balance of the spine as some of the kyphosis is lost during engagement of the rod to the pedicle screws and during rod de-rotation.

The convex rod was loosely engaged to the proximal and distal fixation points during the concave correction manoeuvres to prevent exacerbation of rib prominence that can occur during en-bloc rod de-rotation. Proximal and distal distraction / compression was performed to achieve level shoulders and waist.

In both techniques, placement of a free hand technique based on anatomical landmarks. This was followed by decortication of the posterior elements and onlay of bonegrafts.

Locally harvested autologous bone was supplemented by allograft to achieve fusion.

Post operative:

- All patients followed an enhanced recovery pathway in the ward. postoperative trunk support was used in all patients.
- All patients had IV PCA (pain-controlled analgesia): morphine + ketolac + proton pump inhibitor
- Drain was removed 2-3 days post operative.
- Patients were discharged after 4 days post operative, and follow up after 10 days at the outpatient clinic for sutures removal.

Statistical methods:

Data was entered and statistically analyzed on the Statistical Package of Social Science Software program, version 25 (IBM SPSS Statistics for Windows, Version 25.0. Armonk, NY: IBM Corp.). Data was presented using mean and standard deviation for quantitative variables and frequency and percentage for qualitative ones. Improvement rates were calculated as a form of percent change as follow: Percent change = (Post-Pre)/Pre X 100. Comparison between groups for qualitative variables was performed using Chi square or Fisher's exact tests while for quantitative variables the comparison was conducted using Mann Whitney test. Spearman correlation coefficient was calculated to explore the correlation between the improvement rate with different quantitative variables. Change of different measures before and after surgeries was tested using Wilcoxon test. P values less than or equal to 0.05 were considered statistically significant.

Results

This study included 28 patients with Adolescent idiopathic scoliosis (AIS) presented to the Neurosurgical outpatient clinic of Cairo university hospitals during the period between February 2021 and February 2023

Gender:

	Description (n=28)
Sex	
Male	7 (25)
Female	21 (75)

This study included twenty-eight patients, twenty-one (75%) were females and seven (25%) were males.

Age:

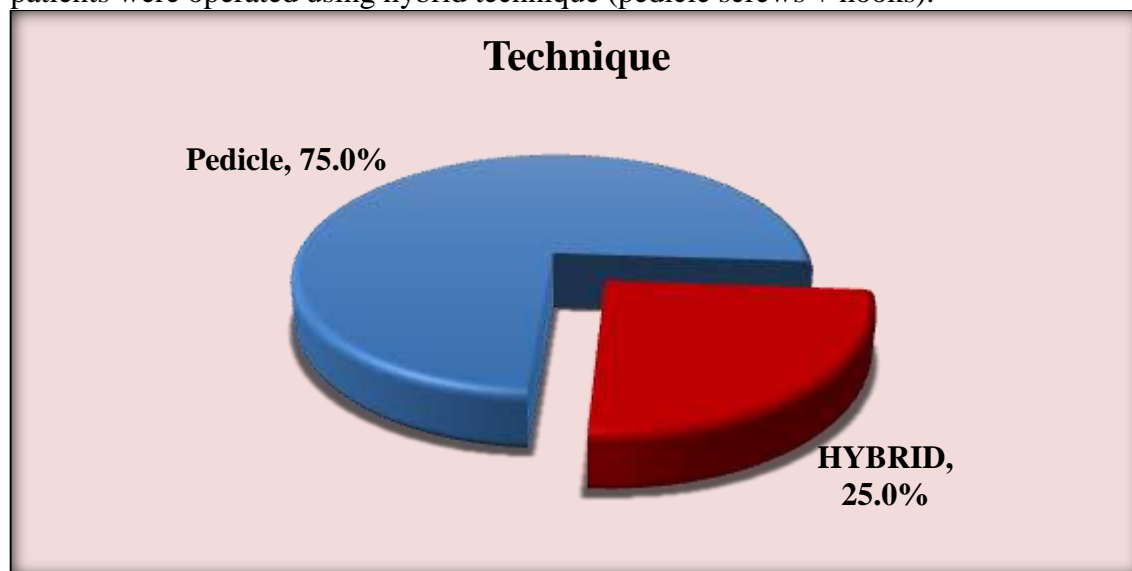
	Description (n=28)
Age	
Range	11 - 22
Mean ± SD	15.5 ± 2.5

All patients who were included this study had a range between 11-22 years with a mean 15.5 ± 2.5.

Technique used:

	Description (n=28)
Technique	
Pedicle	21 (75)
HYBRID	7 (25)

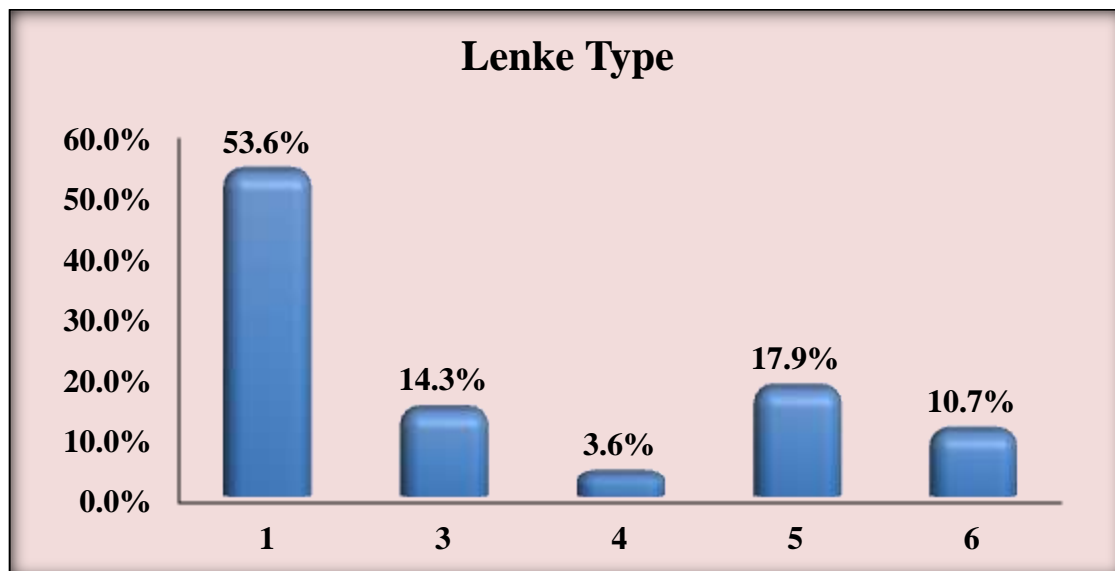
Twenty-one (75%) patients in our study were operated by whole pedicle screws technique, seven (25%) patients were operated using hybrid technique (pedicle screws + hooks).



Lenke classification:

	Description (n=28)
Lenke Type	
1	15 (53.6)
3	4 (14.3)
4	1 (3.6)
5	5 (17.9)
6	3 (10.7)

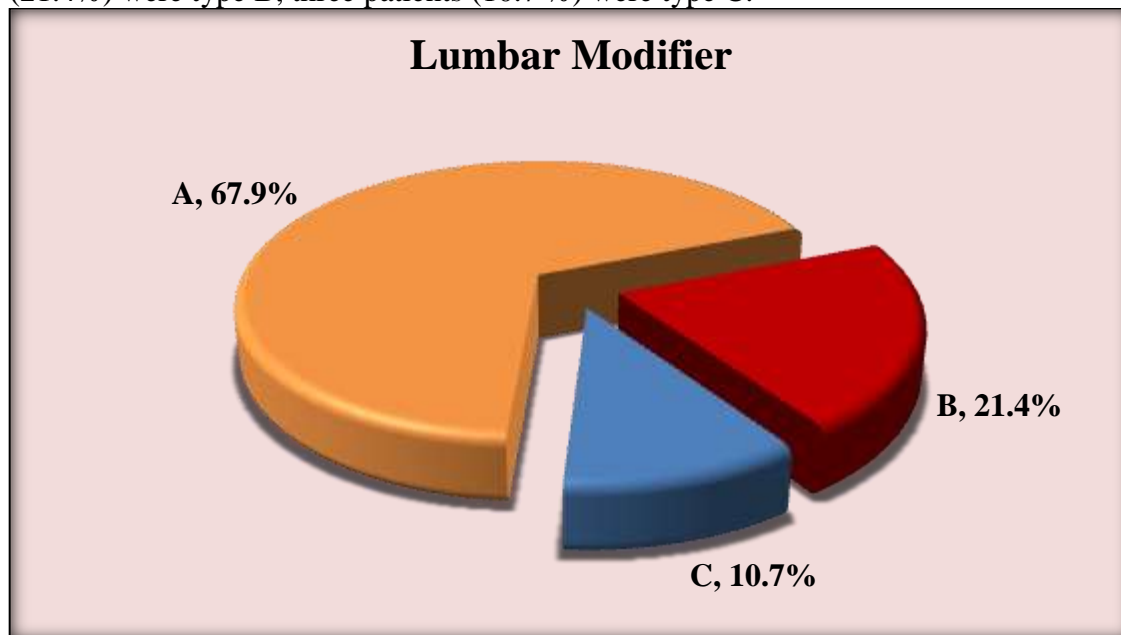
According to Lenke classification , fifteen patients (53.6 %) were type 1 (main thoracic curve(MT)) , four patients (14.3%) were type 3 (double major curve(DM) : main thoracic (major) structural +thoracolumbar/ lumbar Curve structural) , one patient (3.6 %) type 4 (Triple major curve = proximal thoracic+ Main thoracic (major) + thoracolumbar/lumbar) , five patients (17.9%) were type 5 (thoracolumbar / lumbar), three patients (10.7%) were type 6 (triple major with major curve at the thoracolumbar /lumbar curve) .



Lumbar modifier:

	Description (n=28)
Lumbar modifier	
A	19 (67.9)
B	6 (21.4)
C	3 (10.7)

According to Lenke classification lumbar modifiers, sixteen patients (67.9%) were type A, six patients (21.4%) were type B, three patients (10.7 %) were type C.



Operation time (hours):

	Description (n=28)
Operation Time (Hours)	
Range	2.5 - 7
Mean ± SD	3.5 ± 0.9

Duration of the operation ranged from two hours and a half to seven hours with mean 3.5 ± 0.9.

Blood loss (cc):

	Description (n=28)
Blood Loss (cc)	
Range	300 - 1200
Mean ± SD	607.1 ± 244.5

In all our operation the blood loss ranged from three hundred to on thousand and two hundred cc with a mean of 607.1 ± 244.5.

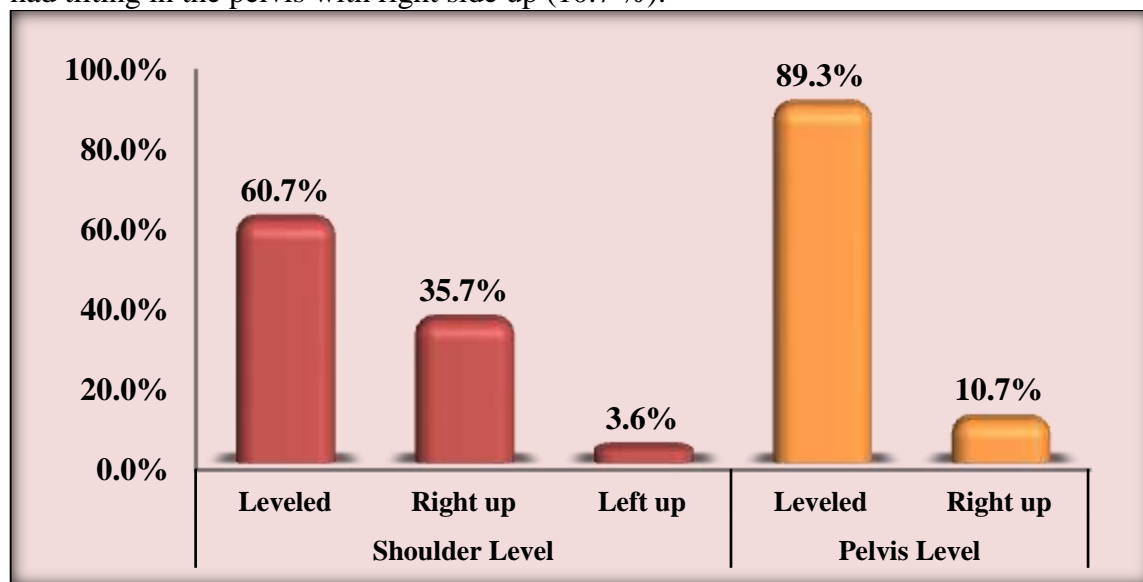
Clinical examination:

	Description (n=28)
Shoulder Level	
Leveled	17 (60.7)
Right up	10 (35.7)
Left up	1 (3.6)
Pelvis Level	
Leveled	25 (89.3)
Right up	3 (10.7)

By clinical examination of our patients, all of them were intact only complaining of cosmetic deformity or mid back pain.

Concerning levelling of shoulders, seventeen patients (60.7%) had levelled shoulders, ten patients (35.7%) had right shoulder up, and only one patient (3.6%) had left shoulder up.

Concerning levelling of the pelvis, twenty-five patients (89.3%) had levelled pelvis and only three patients had tilting in the pelvis with right side up (10.7 %).

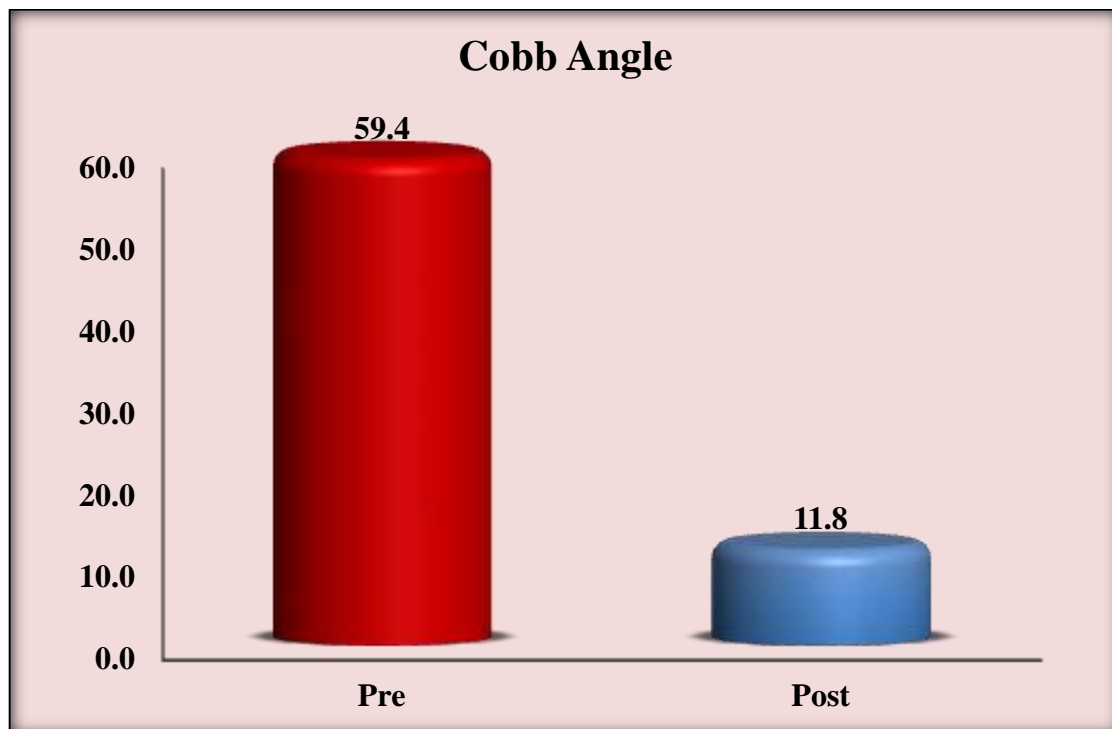


Cobb angle pre-operative and post operative:

	Description (n=28)
Cobb Angle Pre	
Range	40 - 110
Mean ± SD	59.4 ± 15.2
Cobb Angle Post	
Range	4 - 35
Mean ± SD	11.8 ± 7.9

In our study, the cobb angle preoperative ranged between 40° and 110° With a mean 59.4 ± 15.2.

The cobb angle post operative after full correction ranged between 4° and 35° With a mean 11.8 ± 7.9.



	Description (n=28)
Cobb angle Improvement rate	
Range	53.9 – 92.9
Mean ± SD	80.8 ± 9.3

The Cobb angle improvement rate in our cases ranged from 53.9% to 92.9% with a mean 80.8 ± 9.3 .

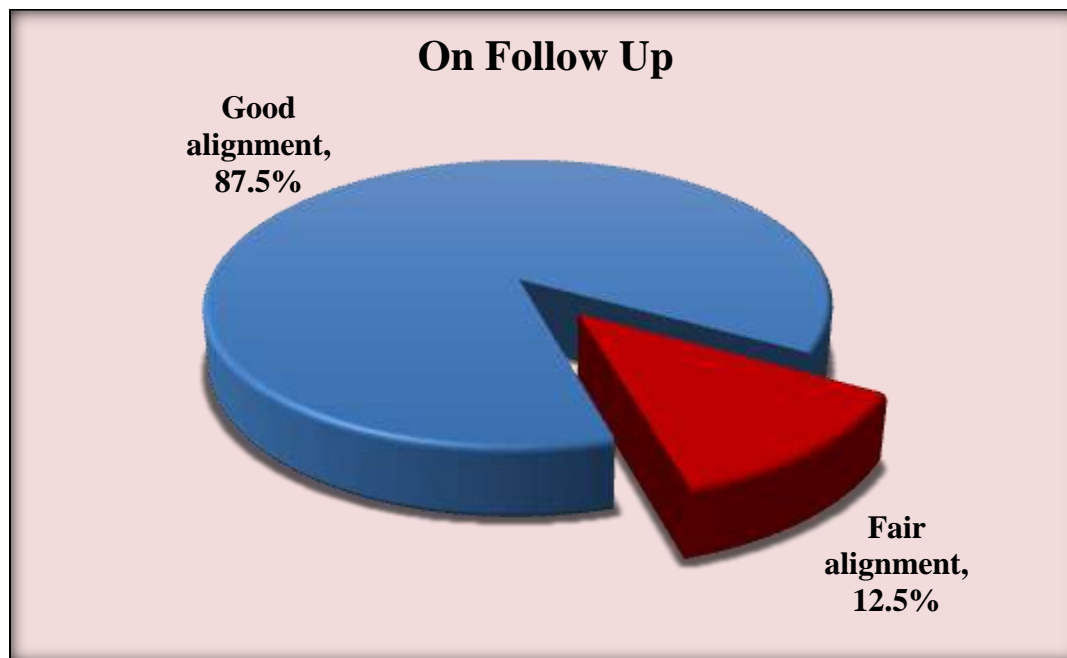
	Description (n=28)
Height Improvement rate	
Range	1.2 - 7
Mean ± SD	3.3 ± 1.4

The height improvement rate in our study ranged between 1.2 cm to 7 cm with a mean of 3.3 ± 1.4

Follow up:

	Description (n=28)
On Follow Up (n=24)	
Good ALIGNMENT	21 (87.5)
Fair ALIGNMENT	3 (12.5)

Only 24 patients came for follow up in our outpatient clinic, twenty-one patient had good alignment (87.5%) while three patients (12.5%) had fair alignment.



Discussion

The surgical treatment in AIS aims to restore the global sagittal balance including the coronal balance, this is done using pedicle screws or pedicle screws combine with hooks named as hybrid instrumentation. This study was done to assess the clinical and radiographic results of patients having AIS treated with whole pedicle screws versus patients treated with hybrid instrumentation.¹⁹

A total of 28 patients with adolescent idiopathic scoliosis (AIS) who underwent posterior spinal fusion operation for correction of deformity were included in this study and were divided into 2 subgroups, whole pedicle screws group (21) patients and hybrid group (screws + hooks) (7) patients, the 28 patients were divided into (7) males and (21) females, the average age at surgery was 15.5 ± 2.5 , our study was a prospective study.

Athanasios I. Tsirikos (A.I.T) et al, included 160 patients in their study, 80 patients in each group, the mean age at their study was 15.6, the all-screws group included 71 female and 9 males, while the hybrid group included 62 females and 18 males.²⁰

In our study, the pedicle screw group included 21 patients with AIS, there were 12 patients with Lenke 1, 2 with Lenke type 3 (double major), 1 with Lenke 4 (triple major), 4 with Lenke type 5 (thoraco-lumbar/lumbar), 2 with Lenke type 6 (major thoracolumbar/lumbar and thoracic structural), 13 patients had lumbar modifier A, 6 patients had lumbar modifier B, 2 patients lumbar modifier type c. While the hybrid group included 7 patients with AIS, 3 had Lenke type 1, 2 with Lenke type 3, 1 patient with Lenke type 5, 1 patient with Lenke type 6, 6 of them had lumbar modifier type A, 1 had lumbar modifier c.

A.I.T et al, included only Lenke type 1 in his study, the pedicle group included 73 patient with lumbar modifier A, 6 patients with lumbar modifier B, 1 patient with lumbar modifier c, while the hybrid group included 67 patients with lumbar modifier A, 10 patients with lumbar modifier B, 3 patients with lumbar modifier type c.²⁰

In our study the groups were not significantly different neither the Cobb angle pre-operative with a P value of $P=0.210$, nor the apical vertebral translation preoperative with a p value of $P=0.066$. However, both groups showed significant differences between the preoperative and post operative Cobb angle, with a P value of <0.01 in pedicle groups and P value of 0.018 in hybrid group. Also, regarding the difference, between the apical vertebral translation preoperative and postoperative, it was significantly different, with P value of <0.01 in the pedicle group and P value of 0.018 in the hybrid group.

According to A.I.T et al, both groups show significant improvement in major Cobb angle and apical vertebral translation with significant P value with a value of $P < 0.001$ but they claimed that apical vertebral translation was better in the pedicle group than the hybrid group.²⁰

However, Ming Luo et al meta-analysis, the Cobb angle of major curve preoperative and post operative showed better coronal correction by pedicle group than hybrid group with a P value < 0.00001 .²¹

In our study, surgery time in hybrid groups was longer but with no P value significance between the 2 groups with p value = 0.182, while in Suken A. Shah and colleagues the surgery time was significantly longer as they claim that these cases were performed in their early experience. However, A.I.T et al, the surgical time was reduced in the hybrid group with a p value < 0.001 .

The difference in our study regarding blood loss and blood transfusion between the 2 groups was not significant with p value of 0.485, this is similar to Suken A. Shah study where the blood loss between the 2 groups was not significant with a P value of $P = 0.27$, while A.I.T et al, intraoperative loss was reduced in the hybrid group with a P value < 0.001 and he insisted that increased surgical time is correlated with increased number of vertebrae fused and greater blood loss.²⁰

Limitations in the other studies were mainly that these studies were retrospective which caused huge loss of evidence and that complications included many aspects as in-hospital complications and long-term complications and radiographic complications.

Conclusion

As per our results, the earlier the correction for AIS, the better radiographic curve correction due to more flexibility. That's why we should communicate with the family and explain the advantage and disadvantage of delaying surgery. The earlier the age of correction, the better height improvement due to increased flexibility. Pedicle screws and hybrid system provide great correction for spinal deformities.

Conflicts of Interest: The authors declare no conflict of interest.

References

1. Freidel K ,Petermann F,Reichel D ,et al. quality of life in women with idiopathic scoliosis. Spine (Phila Pa 1976)2002;27:E87-E91.
2. Andersen M,Christensen SB,Thomsen K.Outcome at 10 years after treatment for adolescent idiopathic scoliosis .Spine (Phila Pa 1976)2006;31:350-354.
3. Weinstein SL,Dolan LA, Spratt KF,et al. Health and function of patients with untreated idiopathic scoliosis :a 50 - year natural history study .JAMA 2003;289:559-567
4. Asher MA,Burton DC.Adolescent idiopathic scoliosis :natural history and long term treatment effects .scoliosis 2006;1:2
5. Rushon PR,Grevitt MP.What is the effect of surgery on the quality of life of the adolescent idiopathic scoliosis ? A review and statistical analysis of the literature .Spine (Phila Pa 1976)2013;38;786-794
6. Landman Z,Oswald T , Sanders J, Diab M,Spinal Deformity study Group.Prevalance and predictors of pain in surgical treatment of adolescent idiopathic scoliosis .spine (Phila Pa 1976)2011;36:825-829.
7. Weinstein SL,Zvala DC, Ponseti IV .Idiopathic scoliosis :long-term follow-up and prognosis in untreated patients .J Bone joint surg[Am]1981;63-A:702-712.
8. Weinstein SL, Zavala DC, Ponseti IV. Idiopathic scoliosis. Long term follow up and prognosis in untreated patients. J Bone Joint Surg Am 1981;63:702-12.
9. Weinstein SL. Idiopathic scoliosis. Natural history. Spine (Phila Pa 1976) 1986;11:780-3.
10. Weinstein SL, Ponseti IV. Curve progression in idiopathic scoliosis. J Bone Joint Surg Am 1983;65:447-55.
11. Weinstein SL, Dolan LA, Spratt KF, et al. Health and function of patients with untreated idiopathic scoliosis: a 50-year natural history study. JAMA 2003;289:559-67.

12. Mayo NE, Goldberg MS, Poitras B, et al. The Ste-Justine Idiopathic Scoliosis Cohort Study. Part III: back pain. *Spine (Phila Pa 1976)* 1994;19:1573-81.
13. Ascani E, Bartolozzi P, Logroscino A, et al. Natural history of untreated idiopathic scoliosis after skeletal maturity. *Spine (Phila Pa 1976)* 1986;11:784-9.
14. Mankin H, Graham J, Schauk J. Cardiopulmonary function in mild and moderate scoliosis. *J Bone Joint Surg Am* 1964;46:53-62.
15. Goldberg MS, Mayo NE, Poitras B, et al. The Ste-Justine Adolescent Idiopathic Scoliosis Cohort Study: Part II: perception of health, self and body image, and participation in physical activities. *Spine (Phila Pa 1976)* 1994;19:1562-72.
16. Le Navéaux F., Aubin C.-É., Larson A.N., Polly D.W.J., Baghdadi Y.M.K., Labelle H. Implant Distribution in Surgically Instrumented Lenke 1 Adolescent Idiopathic Scoliosis: Does It Affect Curve Correction? *Spine*. 2015;40:462–468. doi: 10.1097/BRS.0000000000000793.
17. Hicks J.M., Singla A., Shen F.H., Arlet V. Complications of pedicle screw fixation in scoliosis surgery: A systematic review. *Spine*. 2010;35:E465–E470. doi: 10.1097/BRS.0b013e3181d1021a.
18. Roach J.W., Mehlman C.T., Sanders J.O. Does the outcome of adolescent idiopathic scoliosis surgery justify the rising cost of the procedures? *J. Pediatr. Orthop.* 2011;31((Suppl. 1)):S77–S80. doi: 10.1097/BPO.0b013e3181f73bfd.
19. Weinstein SL, Dolan LA, Cheng JC, et al. Adolescent idiopathic scoliosis *Lancet* 2008;371:1527-37
20. Tsirikos, A. I., & McMillan, T. E. (2022). All Pedicle Screw versus Hybrid Hook-Screw Instrumentation in the Treatment of Thoracic Adolescent Idiopathic Scoliosis (AIS): A Prospective Comparative Cohort Study. *Healthcare (Basel, Switzerland)*, 10(8), 1455.
21. Luo, Ming et al. "Pedicle screw versus hybrid instrumentation in adolescent idiopathic scoliosis." *Medicine* 96 (2017): n. pag.