



Role of oral mucosal graft in Management of Male Anterior Urethral Stricture Disease: Review Article

Aref Mohamed Maarouf¹, Hazem Mohamed Algalaly¹, Ahmed Ali Mashat Deeb², Hamdy Mohamed De souki¹, Mohamed Gomaa Abdeen¹, Ahmed Eliwa¹.

¹Department of Urology, Faculty of Medicine, Zagazig University, Egypt

²Department of Urology, Faculty of Medicine, Al-Tripole University, Libya

*Corresponding author: Ahmed Ali Mashat Deeb,

E-mail: ahmedali80dr@gmail.com

Article History: Received: 26.05.2023

Revised: 18.06.2023

Accepted: 12.07.2023

Abstract:

Background: Broadly defined, urethral strictures are narrowing of the urethral lumen that is surrounded by corpus spongiosum, i.e., urethral meatus through the bulbar urethra. Urethral stenosis is narrowing of the posterior urethra, i.e., membranous urethra through bladder neck/prostate junction, which is not enveloped by corpus spongiosum. The disease has significant quality of life ramifications because many times younger patients are affected by this compared to many other urological diseases.

Keywords: buccal mucosa, Urethra, Urethroplasty.

DOI: 10.53555/ecb/2023.12.1127

Introduction:

Treatment of urethral stricture depends upon many factors: site: anterior / posterior urethral stricture, length : short < 2 cm / long 2 cm or above, denovou / recurrent stricture and number of strictures (1). There is no medical therapy to treat urethral stricture disease, however, urinary tract infections (UTIs) should be adequately treated prior to surgical intervention. Surgical treatment of urethral stricture disease is indicated when the patient has severe voiding symptoms, bladder calculi, increased postvoid residual, and recurrent urinary tract infection or when conservative management fails (2).

Treatment of Urethral Stricture:

A-Observation: Stricture will usually result in diminution in flow once the caliber of the urethral lumen is < 10 Fr. In other strictures (> 10 Fr), the diagnosis is often made by coincidence in asymptomatic patients because of a urologic examination for other reasons (e.g., cystoscopy, need for urethral catheterisation) asymptomatic strictures do not always need active treatment. Endoluminal treatments can be used for short, nonobliterative strictures at the bulbar and posterior urethra as first-line treatment. Repetitive endoluminal treatments are not curative. Urethroplasty encompasses a multitude of techniques, and adaptation of the technique to the local conditions of the

stricture is crucial to obtain durable patency rates (3). Patients who needed intervention had poorer PROMs suggesting clinical symptoms and bother. There is no information on long-term complications in patients with recurrences who did not undergo intervention. In cases of an asymptomatic stricture recurrence, it might be an option not to intervene but to perform regular follow-up (3).

B- Optical internal urethrotomy (OIU):

OIU represents the basis of endoscopically treating urethral strictures and is inspired by a French idea, born in the 19th century by Civiale and Maisonneuve. This treatment principally differs from urethral dilation as it involves an intervention which is guided by the direct vision of the surgeon. During this procedure, a longitudinal incision is made over the entire stricture length into healthy urethral tissue, after which the gap between the wound edges is expected to be re-epithelialized (4). *OIU is indicated in cases with* primary, single, short (< 2 cm), anterior urethral stricture (5). There are several prognostic factors impeding success rates of OIU including number of previous urethrotomies (and stricture-free interval thereafter), stricture length, number of strictures, stricture location, and the amount of surrounding spongiofibrosis (6). A knife blade or Ho YAG Laser is used to cut the stricture and create a gap and allowing 16/18 Fr urethral catheter to be inserted (7); (8).

C-Open Urethroplasty: Urethral dilatation and internal urethrotomy as modalities of treatment have limited usage in current day practice because when there is associated spongiofibrosis, they are not curative. Urethral reconstruction has therefore become the mainstay treatment of urethral stricture disease when the aim is to cure the patient of such a crippling ailment (9). Many reconstructive procedures have been used to treat strictures. In all cases, the choice of repair is based on the location, length and recurrence of the stricture. No single repair is right for all cases. The 2 main types are Excision primary anastomotic and substitution urethroplasty (4).

Anastomotic Urethroplasty This method is usually reserved for short bulbar or membranous urethral strictures. In this situation, a perineal incision is made and the urethra can then be reconnected after removing the stricture. A 16/18 Fr, soft catheter is left in the urethra for 7 to 14 days. It is then removed, an ascending cystourethrogram is done to make sure the repair has healed (10); Figure(1)Some surgeons prefer the use of a suprapubic catheter, as they believe insertion of an in-dwelling urethral catheter may damage the anastomosed area (4). *The Expected average success rate of EPA is above 95%*, anastomotic urethroplasty is considered the "gold standard" of surgical repair options. It is generally used when strictures are less than 2 cm in length (8).

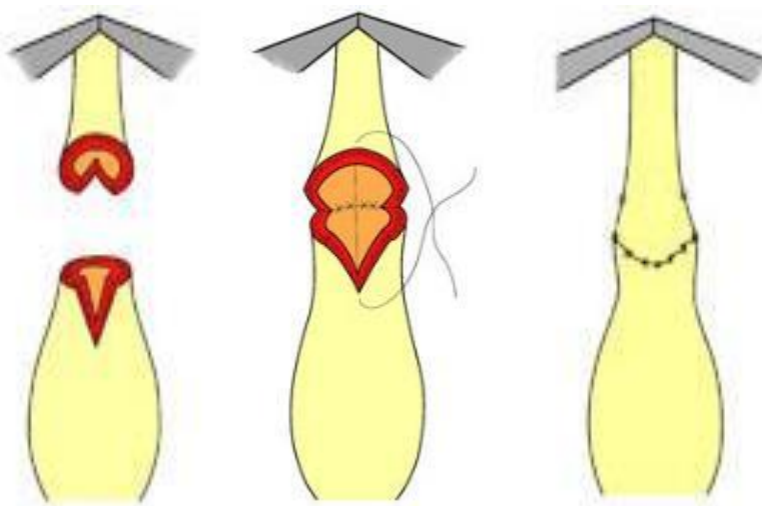


Figure (1): Anastomotic Urethroplasty (8).

Substitution Urethroplasty when the stricture is long, tissue can be transferred to replace the section that had the stricture. A number of different tissue types—including penile skin, scrotal skin, extragenital skin, bladder mucosa, intestinal mucosa, and oral mucosa—have been used as urethral substitutes. Traditionally, penile skin as a pedicled flap or as a free graft had been considered the most reliable material for reconstruction of urethral strictures and until several decades ago had been the most

popular material for anterior urethroplasty. However, penile skin has gradually been replaced by buccal mucosa grafts (BMGs) because of their advantageous histological properties and superior handling characteristics. It has been shown that there was a much higher morbidity with penile skin flaps than with BMGs. The types of urethroplasty for bulbar urethral strictures are mainly categorized into two groups (11) Figure (2).

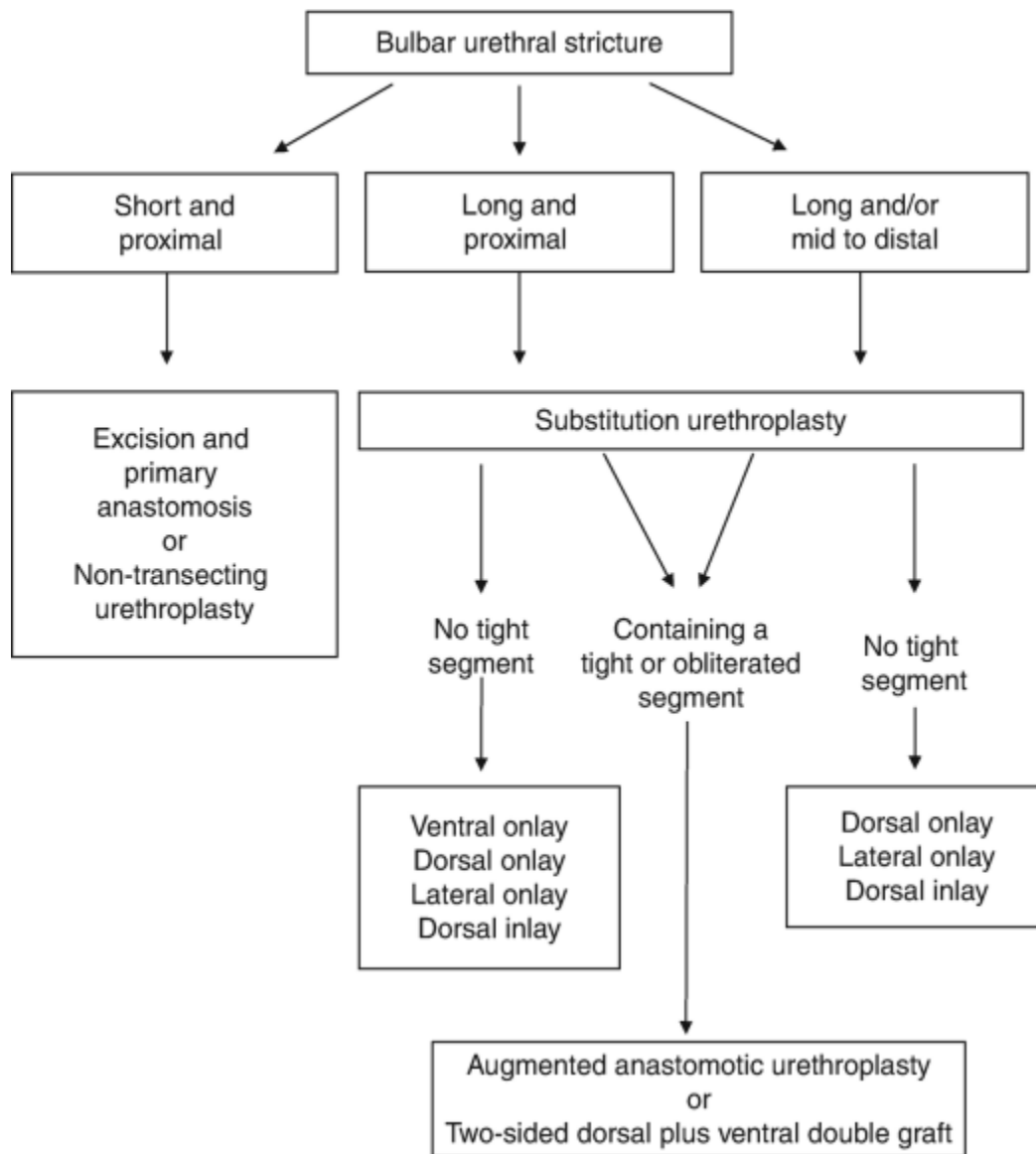


Figure (2): A flowchart of selecting the type of urethroplasty for bulbar urethral stricture (12).

Surgical Anatomy of Oral Mucosa

Buccal and labial mucosae are covered by lining mucosa and have a stratified squamous nonkeratinized epithelium that lines a thin elastic lamina propria and submucosa (13); Figure (3).

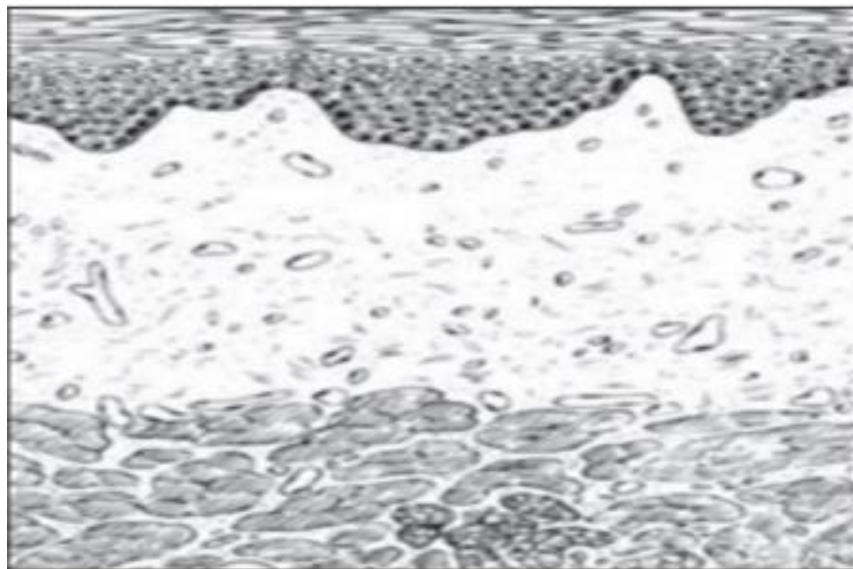


Figure (3): Histology of buccal mucosa (13).

The lamina propria consists of a rich vascular supply and dense connective tissue with short, irregular dermal papillae; while the submucosa is firmly attached to the

underlying buccinator and orbicularis oris muscles and contains minor salivary glands (14) Figure (4).

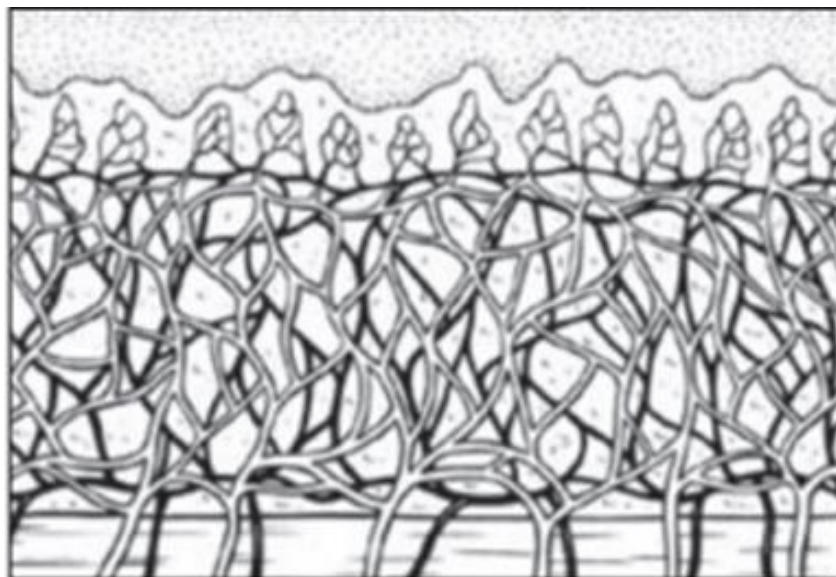


Figure (4): Microvasculature of buccal mucosa (13).

After the removal of its subcutaneous tissue, buccal mucosa is relatively thick, mechanically stiff and elastic and so easy to handle. It is also suggested to have an

infection defense layer denoted by a high concentration of IgA antibodies as a result of evolution-related qualities (15). Furthermore, the natural moist location of the buccal

mucosa in the oral environment favors its easy adaptability in the urethral passage when used as a free graft (16).

The mucous membranes of the cheek and lower lip receive their nerve supply from the buccal and mental branches of the mandibular nerve, respectively. The lip mucosa is thinner and less resistant than the

buccal mucosa. In addition, the width of the lip (maximal dimension, 1.0 to 4.0 cm), unlike the buccal mucosa (maximal dimension, 3 to 5.5 cm), limits the size of the graft (17); Figures (5).

Advantage of oral mucosal graft: Hairless, Accustomed to a wet environment, Easy to harvest and High stability of the grafts.

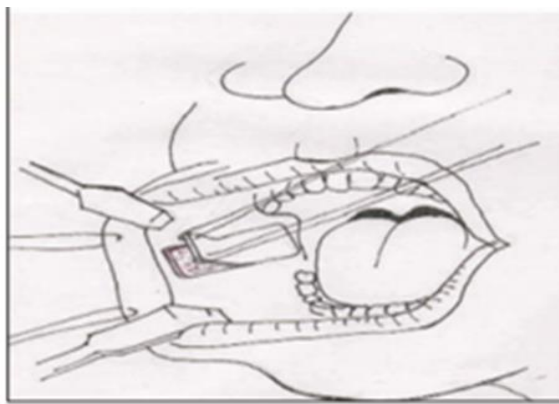
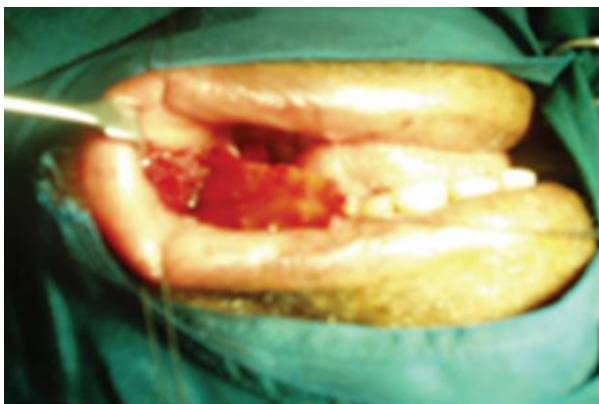


Figure (5): Buccal mucosa harvest from the right inner cheek (14).

Conclusion: The use of the buccal mucosa graft for urethral reconstruction is a successful method with a low incidence of complications.

References:

1. Lucas, J. W., Ghiraldi, E., Ellis, J., & Friedlander, J. I. (2018). Endoscopic management of ureteral strictures: an update. *Current urology reports*, 19(4), 1-7.
2. Sarin, I., Narain, T. A., Panwar, V. K., Bhadoria, A. S., Goldman, H. B., & Mittal, A. (2021). Deciphering the enigma of female urethral strictures: A systematic review and meta-analysis of management modalities. *Neurourology and Urodynamics*, 40(1), 65-79.
3. Lumen, N., Verla, W., Waterloos, M., & Waterschoot, M. (2021). Update on the management of complex strictures of the bulbar urethra. *Current Opinion in Urology*, 31(5), 516-520.
4. Policastro, C. G., Simhan, J., Martins, F. E., Lumen, N., Venkatesan, K., Angulo, J. C., ... & Nikolavsky, D. (2021). A multi-institutional critical assessment of dorsal onlay urethroplasty for post-radiation urethral stenosis. *World Journal of Urology*, 39(7), 2669-2675.
5. Favre, G. A., Alfieri, A. G., Villa, S. A. G., Tobia, I., & Giudice, C. R. (2021). Bulbomembranous urethral strictures repair after surgical treatment of benign prostatic hyperplasia. Experience from a Latin American Referral Centre. *Urology*, 147, 281-286.
6. Jasionowska, S., Brunckhorst, O., Rees, R. W., Muneer, A., & Ahmed, K. (2019). Redo-urethroplasty for the management of recurrent urethral strictures in males:

- a systematic review. *World Journal of Urology*, 37(9), 1801-1815.
7. Daneshvar, M., Pinkhasov, A. M., & Nikolavsky, D. (2020). Surgical management of fossa navicularis and distal urethral strictures. *Textbook of Male Genitourethral Reconstruction*, 93-102.
 8. Verla, W., Oosterlinck, W., Spinoit, A. F., & Waterloos, M. (2019). A comprehensive review emphasizing anatomy, etiology, diagnosis, and treatment of male urethral stricture disease. *BioMed research international*, 2019.
 9. Rosen M et al. The actuarial success rate of surgical treatment of urethral strictures. *J Urol*, 1994. 151(Suppl 360): p. A529.
 10. Awad, M. A., Gaither, T. W., Osterberg, E. C., Murphy, G. P., Baradaran, N., & Breyer, B. N. (2018). Prostate cancer radiation and urethral strictures: a systematic review and meta-analysis. *Prostate cancer and prostatic diseases*, 21(2), 168-174.
 11. Granieri MA, Webster GD, Peterson AC (2014). The evolution of urethroplasty for bulbar urethral stricture disease: lessons learned from a single center experience. *J Urol.*; 192:1468.
 12. Horiguchi, A., Shinchu, M. (2020). Substitution Urethroplasty for Bulbar Urethral Strictures. In: Martins, F.E., Kulkarni, S.B., Köhler, T.S. (eds) *Textbook of Male Genitourethral Reconstruction*. Springer, Cham
 13. Jordan, G., Schlossberg, S., (1993). Using tissue transfer for urethral reconstruction. *Contemp Urol* 5, 13-23.
 14. Mungadi, I., Mungadi, V., (2009). Oral mucosa grafts for urethral reconstruction. *Annals of African medicine* 8.
 15. Filipas, D., Wahlmann, U., Hohenfellner, R., (1998). History of oral mucosa. *European urology* 34, 165-168.
 16. Kane, C.J., Tarman, G.J., Summerton, D.J., Buchmann, C.E., Ward, J.F., O'Reilly, K.J., Ruiz, H., Thrasher, J.B., Zorn, B., Smith, C., (2002). Multi-institutional experience with buccal mucosa onlay urethroplasty for bulbar urethral reconstruction. *The Journal of urology* 167, 1314-1317.
 17. Barbagli, G., Palminteri, E., Guazzoni, G., Cavalcanti, A., (2003). Bulbar urethroplasty using the dorsal approach: current techniques. *International braz j urol* 29, 155-161.