

Role of Fluorine-18 Fluorodeoxyglucose Positron Emission Tomography/Computed Tomography in Diagnosis of Breast Cancer

Hanan A. Hassan, Enass M. Khattab, Ruqayah Abdulqadir Abdulsalam, Rania Mostafa Hassan



Radiodiagnosis Department, Faculty of Medicine, Zagazig University

Corresponding author: Ruqayah Abdulqadir Abdulsalam

Email: dr.rogeiaabd@gmail.com, **Mobile:** 01121549635

Article History: Received: 26.06.2023 Revised:14.07.2023 Accepted: 29.07.2023

Abstract:

Breast cancer (BC) affects 1 in 13 women in their lifetime. Treatment options have developed significantly over the past decade and have had an impact on survival. The diagnosis of BC recurrence is important to allow appropriate treatment. Positron emission tomography (PET) and positron emission tomography/computed tomography (PET/CT) are technologies that have application in the detection and management of cancer. The adoption of PET or PET/CT depends not only on their diagnostic accuracy but also on their comparative advantage over existing diagnostic approaches.

Key words: Breast Cancer, PET, CT.

DOI: 10.31838/ecb/2023.12.9.163

Introduction:

The series of tests needed to evaluate a possible breast cancer usually begins when a woman or their doctor discover a mass or abnormal calcifications on a screening mammogram, or a lump or nodule in the breast during a clinical or self-examination. Less commonly, a woman might notice a red or swollen breast or a mass or nodule under the arm. (1)

The following tests may be used to diagnose breast cancer or for follow-up testing after a breast cancer diagnosis. (2)

1. IMAGING TESTS:

Imaging tests show pictures of the inside of the body. The following imaging tests of the breast may be done to learn more about a suspicious area found in the breast during screening. In addition to these, there are other new types of tests that are being studied. (3)

- **Diagnostic mammography.** Diagnostic mammography is similar to screening mammography except that more pictures of the breast are taken. It is often used when a woman is experiencing signs, such as a new lump or nipple discharge. Diagnostic mammography may also be used if something suspicious is found on a screening mammogram. (4)

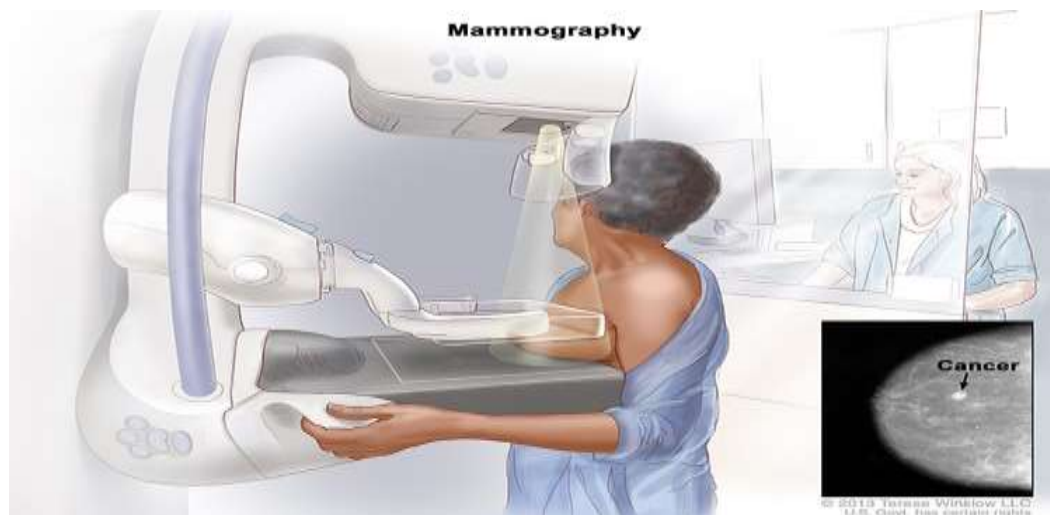


Figure (1): Diagnostic mammography (4)

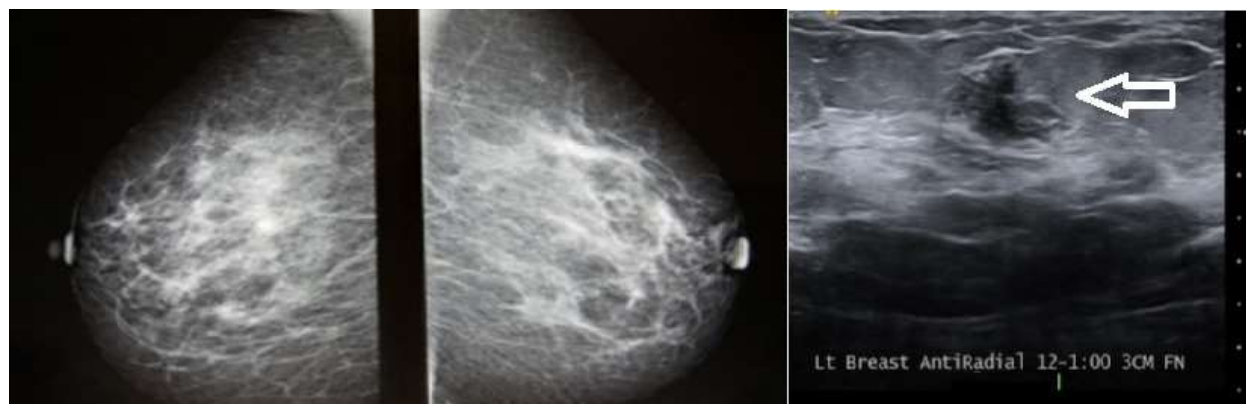


Figure (2): Breast mammography (5)

- **Ultrasound.** An ultrasound uses sound waves to create a picture of the breast tissue. An ultrasound can distinguish between a solid mass, which may be cancer, and a fluid-filled cyst, which is usually not cancer. (5)
- **MRI.** An MRI uses magnetic fields, not x-rays, to produce detailed images of the body. A special dye called a contrast medium is given before the scan to help create a clear picture of the possible cancer. This dye is injected into the patient's vein. A breast MRI may be used after a woman has been diagnosed with cancer to find out how much the disease has grown throughout the breast or to check the other breast for cancer. Breast MRI is also a screening option, along with mammography, for some women with a very high risk of developing breast cancer and for some women who have a history of breast cancer. MRI may also be used if locally advanced breast cancer is diagnosed or if chemotherapy or endocrine therapy is being given first, followed by a repeated MRI for surgical planning. Finally, MRI may be used as a surveillance method following a breast cancer diagnosis and treatment. (6)

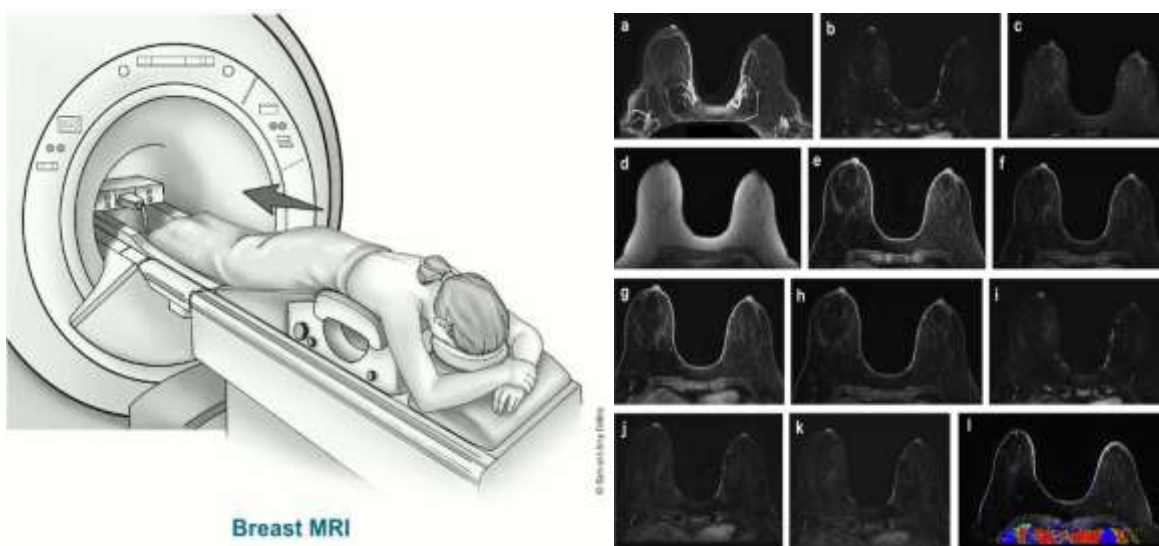


Figure (3): Breast MRI (6)

2. BIOPSY:

A biopsy is the removal of a small amount of tissue for examination under a microscope. Other tests can suggest that cancer is present, but only a biopsy can make a definite diagnosis. A pathologist then analyzes the sample(s). A pathologist is a doctor who specializes in interpreting laboratory tests and evaluating cells, tissues, and organs to diagnose disease. There are different types of biopsies, classified by the technique and/or size of needle used to collect the tissue sample. (7)

- **Fine needle aspiration biopsy.** This type of biopsy uses a thin needle to remove a small sample of cells. (8)

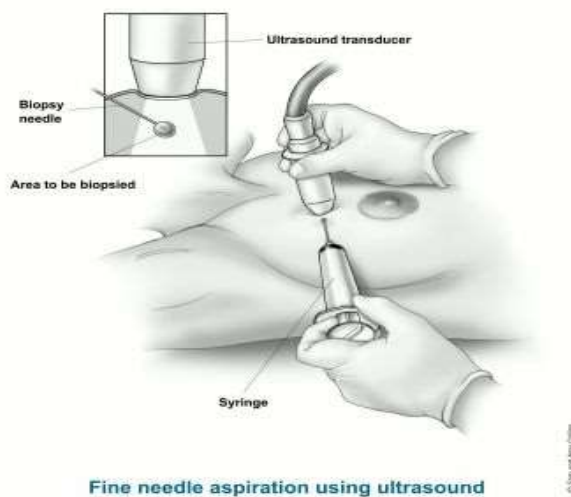


Figure (4): Fine needle aspiration biopsy (8)

- **Core needle biopsy.** This type of biopsy uses a wider needle to remove a larger sample of tissue. This is usually the preferred biopsy technique for finding out whether an abnormality on a physical examination or an imaging test is invasive cancer and, if so, what the cancer biomarkers are, such as hormone receptor status (ER, PR) and HER2 status. Biomarkers, sometimes called tumor markers, are substances in a person's blood, urine, or other body fluids that can also be found in or on the tumor. They are made by the tumor or by the body in response to the cancer. This information will help develop a treatment plan. Local anesthesia, which is medication to block pain, is used to lessen the patient's discomfort during the procedure. (9)

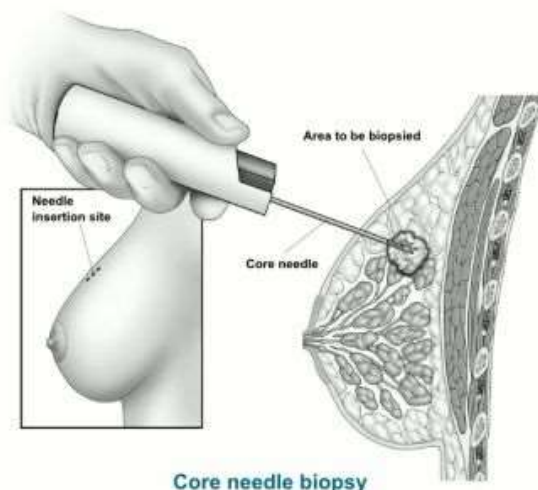


Figure (5): Core needle biopsy (9)

- **Surgical biopsy.** This type of biopsy removes the largest amount of tissue. Because surgery is best done after a cancer diagnosis has been made, a surgical biopsy is usually not the recommended way to diagnose breast cancer. Most often, non-surgical core needle biopsies are recommended to diagnose breast cancer in order to limit the amount of tissue removed. Since many people who are recommended to undergo breast biopsy are not diagnosed with cancer, using a needle biopsy for diagnosis reduces the number of people who have surgery unnecessarily. (10)

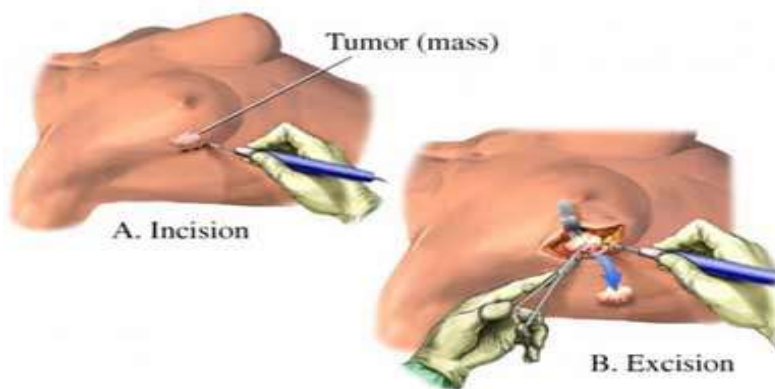


Figure (6): Surgical biopsy (10)

- **Image-guided biopsy.** During this procedure, a needle is guided to the location of the mass or calcifications with the help of an imaging technique, such as mammography, ultrasound, or MRI. A stereotactic biopsy is a type of image-guided biopsy that is done using mammography to help guide the needle. Your doctor will let you know what type of biopsy is best for your situation. A small metal clip is usually put into the breast at the time of biopsy to mark where the biopsy sample was taken, in case the tissue is cancerous and more

surgery is needed. This clip is usually titanium so it will not cause problems with future imaging tests, but check with your doctor before you have any imaging tests done. (11)

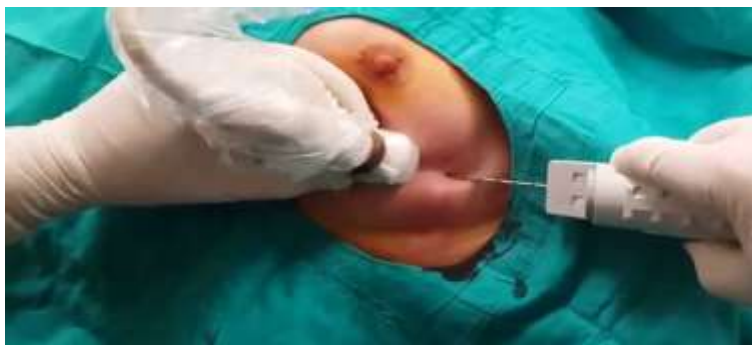

Figure (7): Image-guided biopsy (11)

- **Sentinel lymph node biopsy.** When cancer spreads through the lymphatic system, the lymph node or group of lymph nodes the cancer reaches first is called the “sentinel” lymph node. In breast cancer, these are usually the lymph nodes under the arms called the axillary lymph nodes. The sentinel lymph node biopsy procedure is a way to find out if there is cancer in the lymph nodes near the breast. (12)

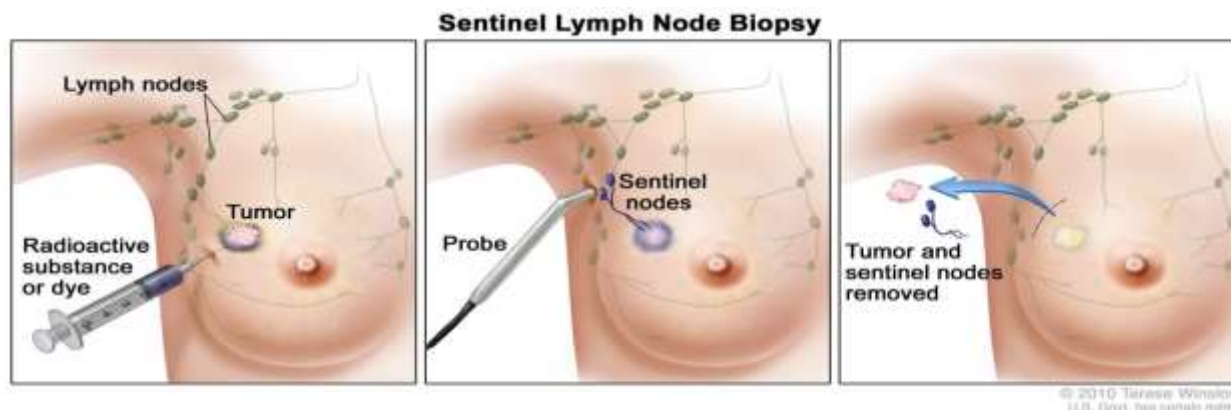


Figure (8): Sentinel lymph node biopsy (12)

BREAST POSITRON EMISSION TOMOGRAPHY

Breast positron emission tomography (PET) is an organ-specific high-resolution technology that is used to visualize the metabolism of the breast. PET scanning is a nuclear medicine technique that images the flow of molecules in the body. This is made possible by attaching a radionuclide to a molecule that enters into metabolic pathways; the photons emitted when the radionuclide decays are then imaged. While anatomic imaging allows visualization of body structures, PET molecular imaging allows visualization of molecular flow and metabolic processes within the body (13)

The primary benefit of PET imaging is that diseases such as cancer often first manifest as disordered metabolism before anatomic changes can be seen. In addition, dense breast tissue or scarring may cause anatomic techniques (mammography, MRI, ultrasonography) to be indeterminate. In such cases, knowing whether an anatomic structure is glucose hypermetabolic can be critical in the determination of proper medical management (**14**)

Breast PET typically utilizes the radiotracer F-18 fluorodeoxyglucose (F-18 FDG) to image glucose metabolism; however, other radiotracers are under development. L-methyl-[11C]-methionine ([11C]C-MET) is one of the first radiolabeled amino acids used to assess amino acid metabolism in PET imaging. Uptake of [18F]F-FACBC ([18F]-fluciclovine) has been shown to be higher in breast cancer lesions than in benign lesions and healthy breast tissue, with a higher uptake in patients with a higher tumor grade. In some studies, [11C]C-labeled tyrosine (L-[1-11C]C-tyrosine), has been shown to be more accurate than F-18 FDG in differentiating malignant lesions from benign lesions, and [18F]-(2S, 4R)4-fluoroglutamine ([18F]F-FGln), has been used in the assessment of glutamine pool changes in patients with triple-negative breast cancer (TNBC) (**15**)

A tracer with great promise is [18F]fluoroestradiol (FES), which can be used for whole-body assessment of estrogen-receptor status. The FDA approval of FES-PET was based on the excellent ability to predict estrogen-receptor expression status on pathology; patients with a positive FES-PET have estrogen receptors on immunohistochemistry. The presence of estrogen receptors is the only factor that can predict the effectiveness of endocrine therapy (**16**)

Whole-body PET cameras are typically combined with a CT scanner to allow acquisition of anatomic and molecular information from a single procedure. These hybrid PET/CT cameras are donut-shaped. During the procedure, the patient is passed through the central hole of the camera. PET/CT cameras have the detector several centimeters away from the body surface, which limits scan resolution. While PET/CT cameras are useful for whole-body imaging, breast-specific PET imaging, known as positron emission mammography (PEM), requires the PET camera to be configured like a mammography machine. PEM cameras utilize 2 small movable flat detectors that are pressed directly against the breast. The camera technology utilized by PEM has been shown to be more sensitive than whole-body PET/CT imaging in the detection of breast tumors (**17**)

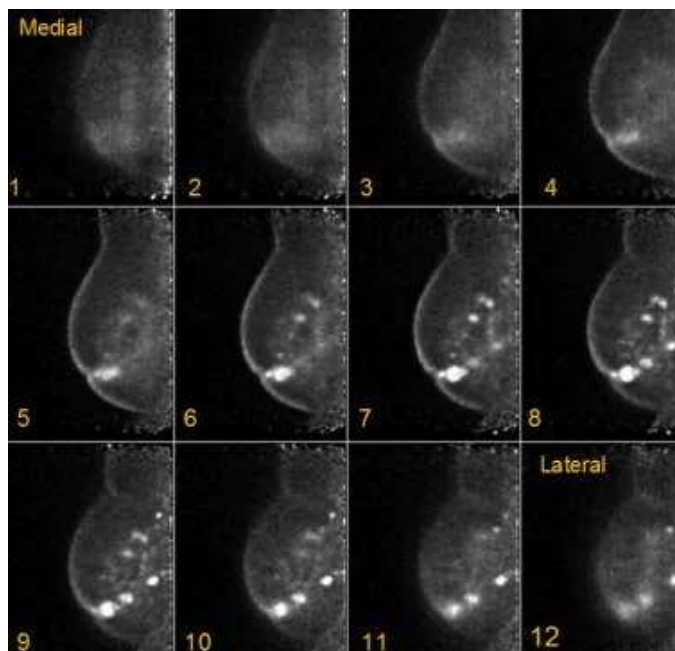


Figure (9): Grade III multifocal infiltrating ductal carcinoma as seen on F-18 fluorodeoxyglucose positron emission tomography . This organ specific positron imaging technique results in a much higher resolution (down to 1 to 2 mm) compared to whole body PET/CT imaging (17)

- **Indications:**

Positron emission mammography (PEM) is particularly useful when other imaging scan results are indeterminate. It has a useful complementary role to mammography, ultrasonography, and MRI. PEM can assist in presurgical planning in breast cancer, monitoring response to therapy, and evaluating for tumor recurrence. In some cases, it may be useful in breast cancer staging and in helping guide breast biopsies. PEM has a sensitivity and specificity of over 90% in the detection of primary breast cancer (18)

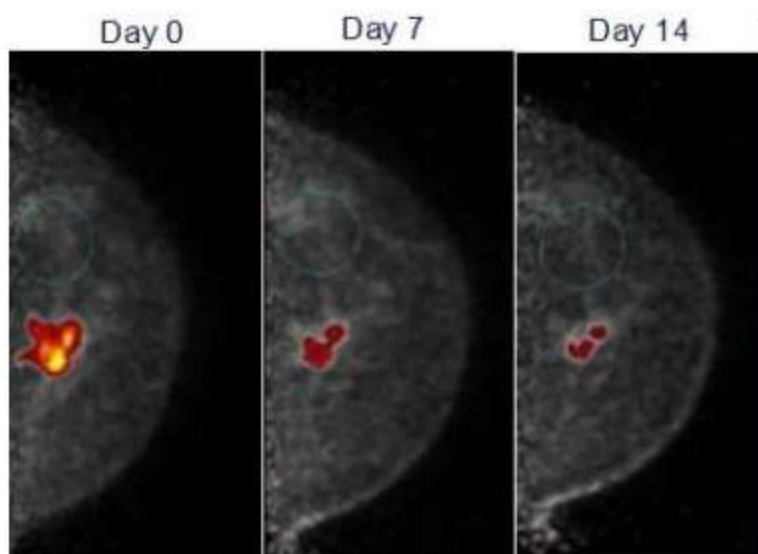


Figure (10): This image demonstrates the ability of positron emission tomography to quickly assess response to chemotherapy, as early as 1 week after the first cycle (18)

- **Outcomes:**

When required, a PET-guided breast biopsy has been found to be safe, effective, and associated with only minimal to mild discomfort. The camera technology utilized by PEM has been shown to be more sensitive than whole-body PET/CT imaging in the detection of breast tumors. PEM has a sensitivity and specificity of over 90% in the detection of primary breast cancer. In a retrospective study, Satoh et al determined that whole-body total lesion glycolysis (WTLG) on FDG PET/CT images is an independent prognostic factor for survival in breast cancer patients who have metastases on initial presentation. Although very rare, hypersensitivity allergic reactions to the radiotracer can occur (19).

PET SCANNING

Positron emission tomography (PET) scanning is an imaging modality with primary use in the field of oncology. It utilizes radiotracers for measuring various metabolic processes in the body. Various changes in metabolism, blood flow, and regional chemical composition can be analyzed by it (20)

Radio-tracers can be injected, swallowed, or inhaled depending upon the site of the body being examined, and the tracer gets trapped in various tissues of the body depending upon the affinity. Areas of higher activity show higher uptake and brighter spots on images (21)

Unstable nuclei of radioactive-tracer emit positrons that produce gamma rays upon the combination with the neighboring electrons. The gamma rays are detected by a ring of detectors

in the scanner. A computer then uses this data to create a 3D-image of the tracer in the body. Various tracers are utilized depending on the targets (22)

Procedures

The tracer may be administered via an intravenous route, orally or via inhalation. The tracer takes some time to distribute throughout the body. A contrast may be administered intravenously or orally if a PET-CT is to be done. Positioning depends upon the site to be scanned. The PET machine has a central hole through which the patient slides through. First images are generally scout images to assess whether the positioning is correct. Sometimes breath-holding maybe required. The scan takes anything from 30 minutes to 1 hour (23)

Oncology

Tracers used commonly include fluorine-18 (18F) fluoro-deoxyglucose (FDG), called [18F] FDG PET. 18F-FDG being a glucose analog, gets picked up by the cells instead of regular glucose for metabolism. Glucose gets phosphorylated by hexokinases. The values of the mitochondrial form of this enzyme are raised in cancers that are rapidly growing (24)

In locations of cancer, the metabolic activity is quite high; hence the glucose uptake is quite high. So this 18F-FDG also gets taken up quite significantly in these locations, and then this shows up as a bright spot on the PET scan. This helps in the detection of metastasis also. Typical doses amount to 7.5 mSv. In the generation of 18-F FDG, the hydroxyl group is replaced by radioactive Fluorine. This hydroxyl group is essential in glucose metabolism steps & its absence causes the stoppage of further reactions in the cells. Most tissues (except liver & kidney) can't remove the phosphate which hexokinase has added. So, the 18F-FDG gets trapped inside the cell till its decay. This is because phosphorylation of sugar leads to the development of ionic charge, which prevents the exit of the sugar from the cell till its decay. Hence tissues with higher glucose uptake & utilization like brain, liver, kidneys, and most of the cancers (due to Warburg effect) show intensive radio-labeling (25)

FDG-PET is used for diagnosis, staging, and monitoring cancers, particularly in Hodgkin's lymphoma, non-Hodgkin lymphoma, and lung cancer. In a study, the likelihood ratio for malignancy in a solitary pulmonary nodule with an abnormal FDG-PET scan was 7.11. This study suggested that the FDG-PET scan is more accurate than the standard criteria for diagnosis. FDG-PET can be used as an adjunct test in solitary pulmonary nodule evaluation (26)

In assessing FDG-PET in staging patients with non-small cell carcinoma, FDG-PET had a higher sensitivity (71% vs 43%), positive predictive value (44% vs 31%), negative predictive value (91% vs 84%) & accuracy (76% vs 68%) than computed tomography (CT) scan for N2 lymph nodes. Whereas, FDG-PET had a higher sensitivity (67% vs. 41%) but lower specificity (78% vs. 88%) than CT scan for N1 lymph nodes. It accurately upstaged 28 patients (7%) with unsuspected

metastasis & down-staged 23 patients (6%). Hence it can be concluded that the FDG-PET scan allows for improved patient selection & accurately stages the mediastinum. However, there were many false positives lymph nodes, and it may miss N2 disease in the #5, #6, and #7 stations (27)

A positive FDG-PET scan means a tissue biopsy is indicated in that location. In FDG-PET evaluation of cancers of the esophagus and gastroesophageal junction, FDG-PET had lower accuracy in the diagnosis of locoregional nodes (N1–2) than combined CT (computed tomography) and EUS (endoscopic ultrasound) (48% vs. 69%) because of a lack of sensitivity (22% vs. 83%) (28)

The accuracy for distant nodal metastasis was significantly higher for FDG-PET than the combined use of CT & EUS. Sensitivity was no different, however, specificity was higher. FDG-PET correctly upstaged five patients (12%) from N1–2 stage to the M+Ly stage, while one was falsely downstaged by FDG-PET scanning. In a study on the role of FDG PET scan in colorectal cancer screening in asymptomatic adults, it was found that sensitivity of FDG-PET to detect primary colorectal cancer is high, primary colorectal cancer being detected with FDG PET in a resectable stage. FDG-PET could detect large size (> 0.7 cm) and pre-malignant change of colonic adenomas. It's possible to differentiate adenoma from carcinoma of the colon by assessing the increase in the rate of glycolysis in carcinoma (29)

FDG-PET has a role in the detection of recurrent cervical cancer in symptomatic and asymptomatic women. Thirty percent of asymptomatic women had recurrent disease detected by PET scan compared to 66.7% of symptomatic women. The sensitivity of PET for recurrent disease in asymptomatic women was 80.0%, specificity 100%, the positive predictive value of 100% and a negative predictive value of 88.9%.

For symptomatic women, the sensitivity of PET was 100%, specificity 85.7%, the positive predictive value of 93.3%, and negative predictive value of 100%. Hence, whole-body PET can be a sensitive imaging modality for the detection of recurrent cervical carcinoma in both symptomatic and asymptomatic women also (30)

The 68-gallium DOTA peptide is used to detect primary and metastatic neuroendocrine tumors (NETs). NETs express somatostatin receptors (SSTRs), with SSTR2 (51%) of cases, followed by SSTR1 (47%) and SSTR5 (43%). The remaining SSTR4 (36%) and SSTR3 (23%) have low expression levels. The 68-gallium DOTA PET-CT was able to detect significantly more lesions in patients with negative anatomical imaging compared with 111-In-octreoscan (30 vs. 2; $p = 0.028$). Pfeifer *et al.* reported a sensitivity of 88% for In-octreoscan in comparison to 97% for the 64-Cu DOTA PET-CT (31).

References:

1. **Sauter, E. R. (2019).** Benign Diseases of the Breast. In *Breast Disease* (pp. 11-15). Springer, Cham.
2. **Cardoso, F., Kyriakides, S., Ohno, S., Penault-Llorca, F., Poortmans, P., Rubio, I. T., ... & Senkus, E. (2019).** Early breast cancer: ESMO Clinical Practice Guidelines for diagnosis, treatment and follow-up. *Annals of Oncology*, 30(8), 1194-1220.
3. **Akselrod-Ballin, A., Chorev, M., Shoshan, Y., Spiro, A., Hazan, A., Melamed, R., ... & Guindy, M. (2019).** Predicting breast cancer by applying deep learning to linked health records and mammograms. *Radiology*, 292(2), 331-342.
4. **Gupta, D., Mendelson, E. B., & Karst, I. (2021).** Nipple discharge: current clinical and imaging evaluation. *American Journal of Roentgenology*, 216(2), 330-339.
5. **Wiacek, A., Oluyemi, E., Myers, K., Mullen, L., & Bell, M. A. L. (2020).** Coherence-based beamforming increases the diagnostic certainty of distinguishing fluid from solid masses in breast ultrasound exams. *Ultrasound in medicine & biology*, 46(6), 1380-1394.
6. **Siu, A. L. (2016).** Screening for breast cancer: US Preventive Services Task Force recommendation statement. *Annals of internal medicine*, 164(4), 279-296.
7. **Pritzker, K. P., & Nieminen, H. J. (2019).** Needle biopsy adequacy in the era of precision medicine and value-based health care. *Archives of pathology & laboratory medicine*, 143(11), 1399-1415.
8. **Son, D., Dogan, M. D., & Sitti, M. (2017, May).** Magnetically actuated soft capsule endoscope for fine-needle aspiration biopsy. In *2017 IEEE International Conference on Robotics and Automation (ICRA)* (pp. 1132-1139). IEEE.
9. **Pinder, S. E., Shaaban, A., Deb, R., Desai, A., Gandhi, A., Lee, A. H. S., ... & Sharma, N. (2018).** NHS Breast Screening multidisciplinary working group guidelines for the diagnosis and management of breast lesions of uncertain malignant potential on core biopsy (B3 lesions). *Clinical radiology*, 73(8), 682-692.
10. **Sanderink, W. B. G., & Mann, R. M. (2018).** Advances in breast intervention: where are we now and where should we be?. *Clinical radiology*, 73(8), 724-734.

11. **Bick, U., Trimboli, R. M., Athanasiou, A., Balleyguier, C., Baltzer, P. A., Bernathova, M., ... & Sardanelli, F. (2020).** Image-guided breast biopsy and localisation: recommendations for information to women and referring physicians by the European Society of Breast Imaging. *Insights into imaging, 11*(1), 1-18.
12. **Ye, J. M., Guo, B. L., Liu, Q., Ma, F., Liu, H. J., Wu, Q., ... & Liu, Y. H. (2021).** Clinical practice guidelines for sentinel lymph node biopsy in patients with early-stage breast cancer: Chinese Society of Breast Surgery (CSBrS) practice guidelines 2021. *Chinese Medical Journal, 134*(8), 886.
13. **Paydary K, Seraj SM, Zadeh MZ, Emamzadehfard S, Shamchi SP, Gholami S, Werner TJ, Alavi A (2019).** The evolving role of FDG-PET/CT in the diagnosis, staging, and treatment of breast cancer. *Molecular imaging and biology.* 2019 Feb 15;21:1-0.
14. **Ogino K, Nakajima M, Kakuta M, Hayashi M, Yamaguchi S, Tsuchioka T, et al. (2014).** Utility of FDG-PET/CT in the Evaluation of the Response of Locally Advanced Breast Cancer to Neoadjuvant Chemotherapy. *Int Surg.* 2014 Jul-Aug. 99(4):309-18.
15. **Balma M, Liberini V, Racca M, Laudicella R, Bauckneht M, Buschiazzo A, Nicolotti DG, Peano S, Bianchi A, Albano G, Quartuccio N (2022).** Non-conventional and Investigational PET Radiotracers for Breast Cancer: A Systematic Review. *Frontiers in Medicine.*;9.
16. **Fiz F, Bottoni G, Treglia G, Trimboli P, Piccardo A (2022).** Diagnostic and Prognostic Role of 18F-Fluoroestradiol PET in Metastatic Breast Cancer: The Second Youth of an Older Theranostic Concept. *Journal of Clinical Medicine.* Jun 22;11(13):3589.
17. **Satoh Y, Kawamoto M, Kubota K, et al. (2021).** Clinical practice guidelines for high-resolution breast PET, 2019 edition. *Ann Nucl Med.* 2021 Mar. 35 (3):406-414.
18. **Berg WA, Weinberg IN, Narayanan D, Lobrano ME, Ross E, Amodei L, et al. (2006).** High-resolution fluorodeoxyglucose positron emission tomography with compression ("positron emission mammography") is highly accurate in depicting primary breast cancer. *Breast J.* 2006 Jul-Aug. 12(4):309-23.
19. **Kitajima K, Miyoshi Y, Yamano T, Odawara S, Higuchi T, Yamakado K (2018).** Prognostic value of FDG-PET and DWI in breast cancer. *Ann Nucl Med.* 2018 Jan. 32 (1):44-53.

20. **Kuntner-Hannes, C., Wanek, T., & Wadsak, W. (2021).** Positron emission tomography. In *Imaging Modalities for Biological and Preclinical Research: A Compendium, Volume 2: Parts II–IV: In vivo preclinical imaging, multimodality imaging and outlook* (pp. II-10). Bristol, UK: IOP Publishing.
21. **Shubeska Stratrova, S., Jovanovska Mishevskaja, S., & Spasovski, D. (2021).** Dual-energy X-ray absorptiometric assessment of android to legs ratio index of abdominal obesity in women.
22. **Pellico J, Gawne PJ, de Rosales RT (2021).** Radiolabelling of nanomaterials for medical imaging and therapy. *Chemical Society Reviews*. 2021;50(5):3355-423.
23. **Subramaniam, R. M., Bradshaw, M. L., Lewis, K., Pinho, D., Shah, C., & Walker, R. C. (2018).** ACR practice parameter for the performance of gallium-68 DOTATATE PET/CT for neuroendocrine tumors. *Clinical nuclear medicine*, 43(12), 899-908.
24. **Sachpekidis C, Goldschmidt H, Dimitrakopoulou-Strauss A (2019).** Positron emission tomography (PET) radiopharmaceuticals in multiple myeloma. *Molecules*. 2019 Dec 29;25(1):134.
25. **Christensen-Jeffries, K., Couture, O., Dayton, P. A., Eldar, Y. C., Hynynen, K., Kiessling, F., ... & Van Sloun, R. J. (2020).** Super-resolution ultrasound imaging. *Ultrasound in medicine & biology*, 46(4), 865-891.
26. **Zaucha, J. M., Chauvie, S., Zaucha, R., Biggii, A., & Gallamini, A. (2019).** The role of PET/CT in the modern treatment of Hodgkin lymphoma. *Cancer treatment reviews*, 77, 44-56.
27. **McCarten KM, Nadel HR, Shulkin BL, Cho SY (2019).** Imaging for diagnosis, staging and response assessment of Hodgkin lymphoma and non-Hodgkin lymphoma. *Pediatr Radiol*. Oct;49(11):1545-1564.
28. **Lan, L., Zhang, S., Xu, T., Liu, H., Wang, W., Feng, Y., ... & Qiu, L. (2022).** Prospective comparison of 68Ga-FAPI versus 18F-FDG PET/CT for tumor staging in biliary tract cancers. *Radiology*, 304(3), 648-657.
29. **Akin, E. A., Qazi, Z. N., Osman, M., & Zeman, R. K. (2020).** Clinical impact of FDG PET/CT in alimentary tract malignancies: an updated review. *Abdominal Radiology*, 45, 1018-1035.

- 30. Becker J, Schwarzenböck SM, Krause BJ (2020).** FDG PET hybrid imaging. *Molecular Imaging in Oncology*.:625-67.
- 31. Shell J, Keutgen XM, Millo C, Nilubol N, Patel D, Sadowski S, Boufraquech M, Yang L, Merkel R, Atallah C, Herscovitch P, Kebebew E (2018).** 68-Gallium DOTATATE scanning in symptomatic patients with negative anatomic imaging but suspected neuroendocrine tumor. *Int J Endocr Oncol*. Feb;5(1):IJE04.