



**Functional outcome of isolated PCL avulsion fractures treated with cancellous screws through Burks and Schaffer approach: A case series**

**<sup>1</sup>Dr. Anirudh C K, <sup>2</sup>Dr. Arun KN, <sup>3</sup>Dr. Naveen S, <sup>4</sup>Dr. Sanjeev Chincholi, <sup>5</sup>Dr. Veerabhadra Javali, <sup>6</sup>Dr. Madhusudhan C N**

<sup>1,3</sup>Associate Professor, Department of Orthopaedics, Navodaya Medical College Hospital and Research Centre Raichur, Karnataka, India

<sup>2</sup>Professor and HOD, Department of Orthopaedics, Navodaya Medical College Hospital and Research Centre Raichur, Karnataka, India

<sup>4</sup>Professor, Department of Orthopaedics, Mamta General Hospital, Giriprasad Nagar Khammam, Telangana, India

<sup>5</sup>Associate Professor, Department of Orthopaedics, Karwar Institute of Medical Sciences, Karwar, Karnataka, India

<sup>6</sup>Post-Graduate, Department of Orthopaedics, Navodaya Medical College Hospital and Research Centre, Raichur, Karnataka, India

**Corresponding Author:** Dr. Madhusudhan C N

**Email:** madhu.cn94@gmail.com

---

**Abstract**

**Introduction:** Posterior cruciate avulsion fractures are not very common but among the avulsion fractures around the knee, PCL avulsions are very common followed by anterior cruciate ligament avulsion, various treatment modalities have been described in the literature right from non-operative treatment to operative treatment.

**Objective:** To report the functional outcome of posterior cruciate ligament (PCL) tibial avulsion fracture treated with open reduction and internal fixation using CC screws through BURKS AND SCAHFFER approach.

**Material and Methods:** A series of 20 patients having isolated PCL avulsion fractures at tibial attachment were selected for this study, 3 patients refused treatment by any means. 17 patients (12 male and 5 female) were included in the study with median age group of 28 years (19-45 years). All the patients were treated with ORIF with CC screws through burks and Schaffer approach all of them were followed up for the period of two years. And functional outcome was assessed using Lysholm knee scoring system.

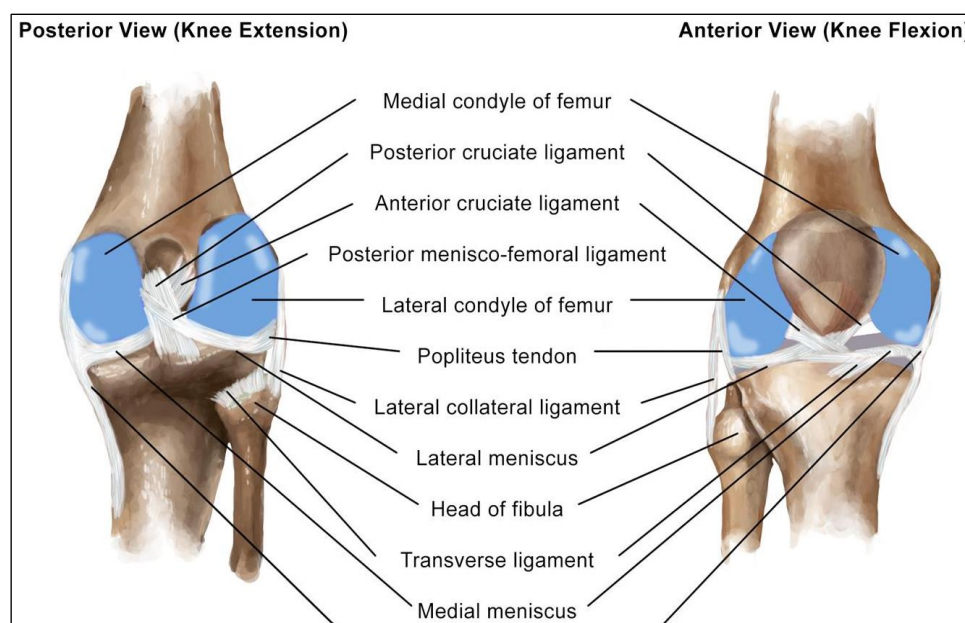
**Results:** Union was achieved in all the cases at the end of the study all patients were able to squat easily and extend the knee fully. Lysholm score was excellent in 13 patients and good in 3 patients.

**Conclusion:** It was concluded that ORIF using CC screw is a good mode of fixation with a good functional recovery with stable knee.

**Keywords:** PCL avulsion, CC SCREW, Lysholm knee score

## Introduction

The posterior cruciate ligament (PCL) is an intra-articular but extra synovial structure. It prevents posterior translation of the tibia as well as provides rotational stability. Injury to PCL usually causes an intrasubstance tear, but incidences of femoral or tibial avulsion fractures have also been described<sup>1</sup>. The reported incidence of general PCL injuries varies between 3% and 38% of acute knee

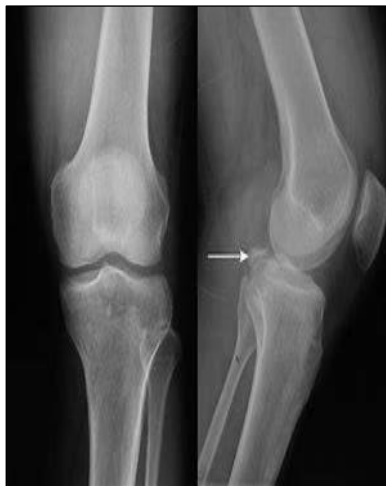

**Fig 1:** Anatomy of Knee Joint

Although the incidences of PCL injuries are low, the complications in the neglected patients in the form of instability and early degenerative changes can be very troublesome to patients, who are mostly young males<sup>5</sup>. Isolated PCL avulsion fractures are uncommon injuries and can be missed many times<sup>6</sup>. Among the avulsion fractures around the knee, PCL avulsion is very common followed by anterior cruciate ligament avulsion. As PCL is a strong ligament, avulsion fracture of its tibial attachment<sup>7</sup> is more common. Avulsion fractures can be easily made out by X-rays (Fig. 2)

Due to the difficulty and apprehension of the posterior approach, many times, fixations of these fractures were avoided. According to literature, nonoperative treatment can be undertaken when the displacement is  $<5$  mm<sup>8</sup>. Regardless of the displacement, nonoperative treatment can still be done if posterior translation of the tibia in  $90^\circ$  of flexion with posterior drawer is  $<10$  mm<sup>9</sup>. Nonoperative treatment is dependent on restoration of the tibiofemoral relationship achieved with immobilization followed by physical rehabilitation.

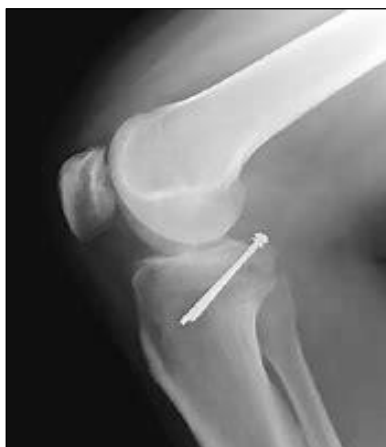To restore the function of the PCL, it is best to fix the avulsed fragment when the displacement is more than 5 mm or posterior translation is more than 10 mm. If these fractures are not fixed, it can lead to many complications such as nonunion, functional instability, and secondary osteoarthritis<sup>10</sup>.



**Fig 2**

It is always a good option to fix these fractures. Multiple types of fixation devices have been used such as lag screws, CC screws, steel wires, spiked washer with lag screws, absorbable screws, suture anchors, and straddle nails<sup>11, 12</sup>.

The study was undertaken at our Navodaya medical college hospital and research center, Raichur, Karnataka to evaluate the clinical and functional outcome of open reduction and internal fixation (ORIF) of tibial avulsion of PCL using CC screws (fig. 3).



**Fig 3**

Fixation can be done by an open or arthroscopic technique. Studies have shown almost similar results of screw fixation, done either by open or arthroscopic means<sup>13</sup>. As arthroscopic repair is technically more demanding, and at present, we were not versed with the arthroscopic techniques of PCL avulsion fixations, we treated all the

cases by ORIF using CC screws. Implants such as CC screw are very cheap and easily available, which helped us present our experience in a small number of isolated PCL avulsion fractures.

Literatures have always suggested satisfactory results<sup>14-18</sup> with ORIF using screws. A simple posteromedial approach described by Burks and Schaffer<sup>19</sup> can be very useful in approaching this fracture.

### **Aim**

The purpose of our study was to evaluate the clinical and functional outcome after ORIF of tibial avulsion injuries of the PCL using cannulated cancellous screws.

### **Etiology and mechanism of injury**

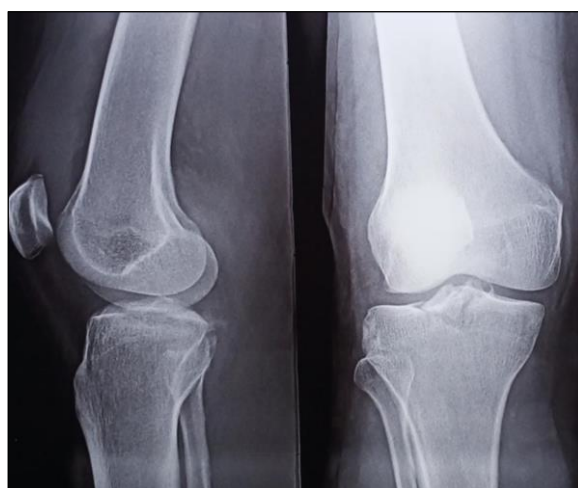The foremost common mode are road traffic accidents and among them, motorcycle injuries. When the dashboard strikes against the proximal tibia in a flexed knee, it can cause PCL avulsion fracture. The next common mode of injury is trauma associated with sports. Here, knee hyperextension is the reason for PCL avulsion. The third common mode of damage are injuries associated with falls.

Associated injuries are commonly encountered (ligament injuries, menisci, intra articular pathologies) Tibial-sided avulsion is the most common in cases of isolated PCL avulsion fractures.

### **Imaging**

#### **X-Ray**

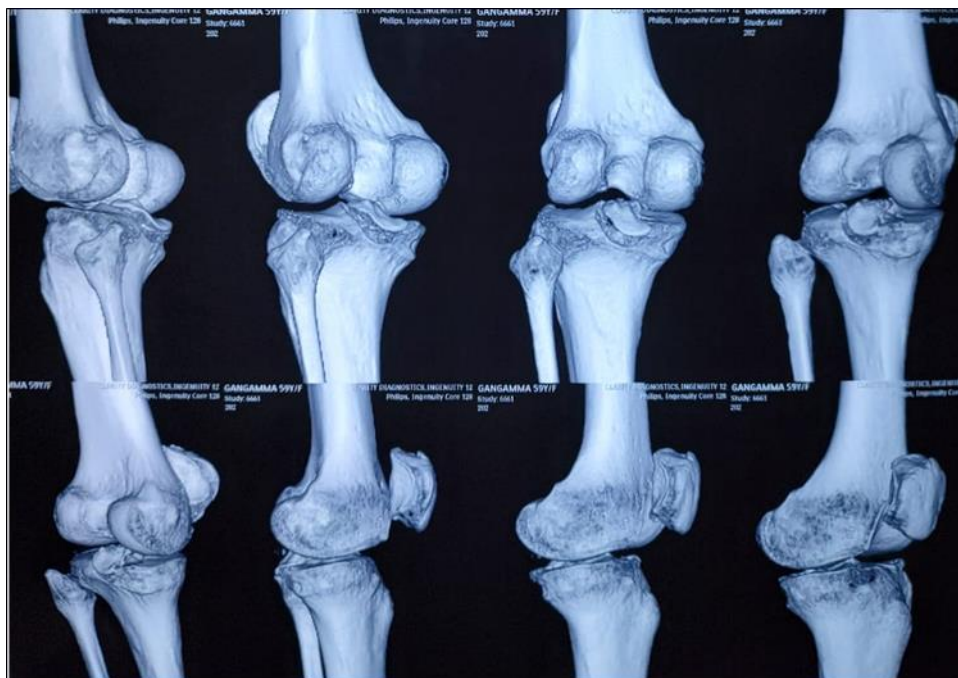
It is important to spot PCL avulsion fractures as early as possible because early reduction and fixation leads to good union, stability, and functional outcome. The lateral view is most vital. A focal discontinuity of the PCL facet at the posterior aspect of the tibia suggests PCL avulsion fractures. (Fig. 4)



**Fig 4:** X-Ray showing AP and Lateral View of avulsion fracture

The insertion of PCL is about 10 mm distal to the joint line. Due to this reason, avulsions with < 10 mm displacement may not be appreciated on radiographs.

Therefore, a rough assumption is often made that if the fragment is well visualized on standard radiographs, the displacement is more than 10 mm<sup>12</sup>. CT SCAN (Dimension, comminution of fracture, preoperative planning) (Fig 6) MRI (associated soft tissue injuries)<sup>[12, 13]</sup>.



**Fig 6:** CT scan with 3D reconstruction

### **Materials and Methods**

During the time frame from FEB 2021 to FEB 2022, the patients coming to the Department of Orthopedics at NMCH and RC were selected for the study.

#### **Inclusion criteria: -**

1. Patients Between age Group of 19-45 Years.
2. Injuries Less Than 3 Months Old.

#### **Exclusion criteria**

1. Injuries Greater Than 3 Months.
2. Other Associated Ligamentous Injuries.
3. Small Avulsed Fragment.

All the cases were clinically assessed.

Posterior sag sign.

Dial test at 90° knee flexion.

Posterior drawer test.

Anteroposterior and lateral radiographs and MRI were taken for all the patients.



A total of 20 patients were enrolled. Among them, three patients refused treatment of any kind. They were opted out from any active mode of treatment but were asked to come for follow-ups at regular intervals.

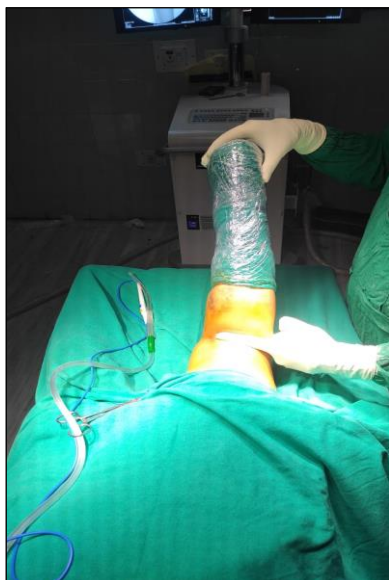Finally, seventeen patients were selected for fixation of the fracture by ORIF using cannulated cancellous screw via the posterior approach.

### **Procedure**

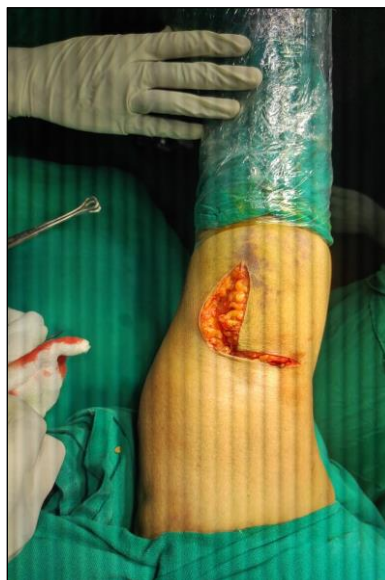An inverted “L” incision was given, beginning on the medial border of the gastrocnemius and curving along the flexor crease of the joint toward the lateral side. The fascia is incised in the line of skin incision. Through the interval between the semimembranosus and gastrocnemius, the capsule is approached. A longitudinal incision is given and the joint is exposed at the site of the avulsed fragment. The avulsed fragment was thoroughly freshened if needed and reduced. Slight flexion of the knee joint helps in reduction. A small bump or pad on the anterior aspect of the distal femur also helps in reduction of the fracture. (Fig 7-9) The reduction was maintained by temporary fixation with a K-wire.

The point of insertion of CC screw was finalized. Depending on the size of the fragment, one or two guide wires were inserted. It was over drilled with a cannulated drill bit. Finally, the avulsed fragment was fixed using one or two 4 mm cannulated cancellous screws by screwing over the guide wires according to the size of the fragment a washer was also used in all cases. K-wire which was holding the temporary fixation was removed. (Fig 10)

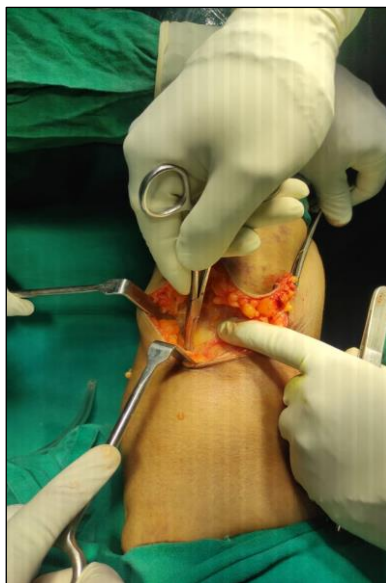
After closure of the incision, antiseptic dressing and proper padding, the limb was kept immobilized using a long knee brace for 6 weeks.



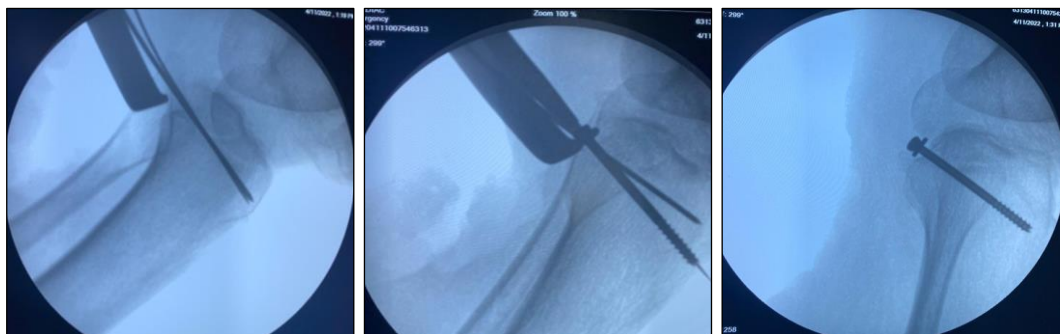**Fig 7:** (Positioning)



**Fig 8:** (Skin Incision)



**Fig 9:** (Deep Dissection)



**Fig 10:** Intra op Images

From the 2nd postoperative day, quadriceps strengthening program was started. Suture removal was done after 10–12 days of surgery. Passive knee bending in the prone position was started after 2 weeks. About 3 weeks after surgery, active mobilization of the knee was started. All the patient were able to gain full extension. Gradually all the patient were able to sit cross-legged and squat. Over a few weeks of time, all the patients were able to regain their ROM.

### **Post Op Follow-Up**

Partial weight bearing was allowed after 6 weeks of surgery, whereas full weight bearing was allowed after 12 weeks. At this time, the brace was also discarded. Return to heavy activities, such as running and sports, was allowed only after 6-9 months. Patients were followed up every month for the first 3 months and every 3 months thereafter for a minimum of 12 months. The patients were followed up for a period of 1 year. At the end, the final functional outcome was calculated using the Lysholm knee scoring system.



**Fig 11:** Post op follow up Images

## Results

6 weeks after surgery, the ROM was more than 90° in all seventeen patients. All the seventeen patients were followed up for at least 1 year at the final follow-up, the fracture had united in all the seventeen patients. 8-12 weeks was the average time taken for the fracture to heal. The average flexion of 121.9°±10.4° with full extension was achieved in all patients. Mild instability was noted in one patient who was, while the rest of the patients had no residual instability. No other complications were observed. The average Lysholm score was 97 ± 7.6.

The statistical analysis showed a highly significant improvement (P < 0.001) in functional outcome assessed by the Lysholm score and joint stability (P < 0.001) (Table 1)

The postoperative Lysholm knee scores improved compared with the pre surgery scores (Table 2).

**Table 1:** Statistical analysis

Parameter	Preoperative	Post-Operative	P Value	Inference
Lysholm Score	3+/-6.7	97+/-7.6	<0.001	Significant
Instability	2.5+/-0.5	0.3+/-0.5	<0.001	Significant

**Table 2:** Lysholm Score before and after surgery

Time	No. of Patients	Lysholm Score
Before surgery	17	25.3+/-14.7
After surgery	17	93.6+/-5.9
P Value	-	<0.001

## Conclusion

Although PCL avulsion fractures are rare, they should undergo fixation when displacement is present. Supervised rehabilitation and mobilization after early and stable fixation gave excellent to good results. The method used in this study resulted in significant improvement in functional and clinical outcome, but it cannot be specified to conclude that it is the treatment of choice for PCL avulsion fractures due to a very small sample size.

As long as studies with a much larger group of patients along with case-control studies comparing different techniques of fixation are not done, it is not wise to



confirm our results. At the end, it can be said that we utilized a good and simple technique for the management of PCL avulsion fractures and added a bit to the already present, vast literature on this topic.

## **References**

1. Hooper PO 3rd, Silko C, Malcolm TL, Farrow LD. Management of posterior cruciate ligament tibial avulsion injuries: A systematic review. *Am J Sports Med.* 2018;46:734-42.
2. Barros MA, Cervone GL, Costa AL. Surgical treatment of avulsion fractures at the tibial insertion of the posterior cruciate ligament: Functional result. *Rev Bras Ortop.* 2015;50:631-7.
3. Fanelli GC, Edson CJ. Posterior cruciate ligament injuries in trauma patients: Part II. *Arthroscopy.* 1995;11:526-9.
4. Janousek AT, Jones DG, Clatworthy M, Higgins LD, Fu FH. Posterior cruciate ligament injuries of the knee joint. *Sports Med.* 1999;28:429-41.
5. Joshi S, Bhatia C, Gondane A, Rai A, Singh S, Gupta S. Open reduction and internal fixation of isolated posterior cruciate ligament avulsion fractures: Clinical and functional outcome. *Knee Surg Relat Res.* 2017;29:210-6.
6. Allen CR, Kaplan LD, Fluhme DJ, Harner CD. Posterior cruciate ligament injuries. *Curr Opin Rheumatol.* 2002;14:142-9.
7. Sonin AH, Fitzgerald SW, Hoff FL, Friedman H, Bresler ME. MR imaging of the posterior cruciate ligament: Normal, abnormal, and associated injury patterns. *Radiographics.* 1995;15:551-61.
8. Zhao J, He Y, Wang J. Arthroscopic treatment of acute tibial avulsion fracture of the posterior cruciate ligament with suture fixation technique through Y- shaped bone tunnels. *Arthroscopy.* 2006;22:172-81.
9. Jazayeri SM, Esmaili Jah AA, Karami M. A safe postero-medial approach to posterior cruciate ligament avulsion fracture. *Knee Surg Sports Traumatol Arthrosc.* 2009;17:244-7.
10. Griffith JF, Antonio GE, Tong CW, Ming CK. Cruciate ligament avulsion fractures. *Arthroscopy.* 2004;20:803-12.
11. Sun HQ, Ren YJ, Zhang YQ. Treatment of posterior cruciate ligament avulsion fracture with pressurized staples. *Chi J Orthop Trauma.* 2011;13:1189-90.
12. Fu YP, Hang CM, Fam HQ. Treatment of posterior cruciate ligament avulsion fracture using anchor system combined with cannulated screw. *J Pract Orthop.* 2011;17:73-4
13. Sasaki SU, Da Mota E Albuquerque RF, Amatuzzi MM, Pereira CA. Open screw fixation versus arthroscopic suture fixation of tibial posterior cruciate ligament avulsion injuries: A mechanical comparison. *Arthroscopy.* 2007;23:1226-30.
14. Chen CH, Chen WJ, Shih CH. Fixation of small tibial avulsion fracture of the posterior cruciate ligament using the double bundles pull-through suture method. *J Trauma.* 1999;46:1036-8.
15. Chiu FY, Wu JJ, Hsu HC, Lin L, Lo WH. Management of avulsion injury of the PCL with reattachment. *Injury.* 1994;25:293-5.

16. Parkkari J, Pasanen K, Mattila VM, Kannus P, Rimpelä A. The risk for a cruciate ligament injury of the knee in adolescents and young adults: A population-based cohort study of 46 500 people with a 9 year follow-up. *Br J Sports Med.* 2008;42:422-6.
17. Nicandri GT, Klineberg EO, Wahl CJ, Mills WJ. Treatment of posterior cruciate ligament tibial avulsion fractures through a modified open posterior approach: Operative technique and 12-to 48-month outcomes. *J Orthop Trauma.* 2008;22:317-24.
18. Bali K, Prabhakar S, Saini U, Dhillon MS. Open reduction and internal fixation of isolated PCL fossa avulsion fractures. *Knee Surg Sports Traumatol Arthrosc.* 2012;20:315-21.
19. Burks RT, Schaffer JJ. A simplified approach to the tibial attachment of the posterior cruciate ligament. *Clin Orthop Relat Res.* 1990;254:216-9.