



ANTIOXIDANT ACTIVITY OF RED DRAGON FRUIT EXTRACT (HYLOCEREUS POLYRHIZUS) ON CYSTATIN C AND KIDNEY INJURY MOLECULE 1 (KIM-1) ON INDUCED WISTAR WHITE RATS GENTAMICIN

Debby Siltami¹, Nazran Nailufar¹, Ermi Girsang², Fiska Maya Wardhani², Gibert Lister², Adek Amansyah¹

Article History: Received: 12.02.2023

Revised: 20.03.2023

Accepted: 29.05.2023

Abstract

The main trigger of kidney failure is free radicals. Our bodies need a compound that can help counteract free radicals or often called antioxidants. Research shows that dragon fruit is rich in antioxidants. This study aims to determine the antioxidant activity of red dragon fruit peel extract (*Hylocereus polyrhizus*) against cystatin C and Kidney Injury Molecule 1 (KIM-1) in gentamicin-induced wistar rats. This study was an experimental study conducted at the USU Pharmacology Laboratory during October 2022. The experimental animals were divided into 5 treatment groups and each treatment consisted of 5 rats. The test animals were given red dragon fruit peel extract (*Hylocereus polyrhizus*) at a dose of 100, 200 and 300 mg/kg BW which is an effective dose because it can reduce free radicals. Data were analyzed using the one way Anova test at the 95% level of confidence and for data that were not normally distributed and not homogeneous, the Kruskal Wallis test was used. Dragon fruit ethanol extract at a dose of 300 mg/kgbw can significantly reduce urea and creatinine levels ($p < 0.05$), KIM-1 levels ($p < 0.05$), and cystatin levels significantly ($p < 0.05$) when compared to the group that was given only gentamicin. Dragon fruit extract antioxidants have a good effect on preventing gentamicin-induced kidney deterioration.

Keywords: Antioxidant, Cystatin, Dragon fruit extract; Kidney; Kidney Injury Molecule-1

¹Biomedical Masters Study Program Students

²Lecturer in the Faculty of Medicine, Dentistry and Health Sciences

Corresponding Email: ermigirsang@unprimdn.ac.id

1. Introduction

Based on data from the World Health Organization (WHO) in 2015, there were 1.2 million people with chronic kidney failure. In 2017 an estimated 30 million people suffer from chronic kidney failure. In 2018 an estimated 37 million people suffer from chronic kidney failure, whereas acute kidney failure shows an incidence that varies between 0.5-0.9% in the community, 0.7-18% in hospitalized patients, up to 20% in patients admitted to the intensive care unit (ICU), with reported mortality rates worldwide ranging from 25% to 80% (WHO 2018).

In Indonesia the incidence of chronic kidney failure from Basic Health Research (Riskesdas) the prevalence of chronic kidney failure in 2013

was 0.2% and in 2018 the prevalence of chronic kidney failure increased by 0.38%. The number of patients with chronic kidney failure in 2018 was 355,726 in men and 358,057 in women (RI Ministry of Health, 2018).

One way to diagnose kidney disease is to measure urea and creatinine levels, because these compounds can only be secreted by the kidneys (Putriana et al., 2017). Urea and creatinine are chemical compounds that indicate normal kidney function, while creatinine is an endogenous metabolism that is useful for assessing glomerular function (Putriana et al., 2017).

Creatinine is produced in equal amounts and excreted in the urine each day, with normal values for creatinine < 1.5 mg/dl and urea 10-50

mg/dl. Urea is a nitrogen product excreted by the kidneys from a protein diet. In patients with kidney failure, serum urea levels provide the best sign for the emergence of toxic urea and are a symptom that can be detected compared to creatinine (Suryawan et al., 2016).

Currently there are several new biomarkers that are superior for early detection of acute kidney injury through urine or plasma samples compared to using conventional measurements and subclinical detection. These biomarkers include Synthacin C and Kidney Injury

Molecule-1. KIM-1 is a protein that is regulated in response to cell or tissue injury and has increased levels in the apical membrane of proximal tubular epithelial cells in the injured kidney. KIM-1 can be detected in injured kidneys within 4 hours, faster than serum creatinine within 24 hours. Fast and sensitive parameters are needed in the detection of AKI to prevent kidney damage from getting worse which leads to chronic kidney disease (Indriani et al., 2021).

The main trigger of kidney failure is free radicals. Our bodies need a compound that can help counteract free radicals or often called antioxidants. Antioxidants are compounds or molecules that can prevent the rate of oxidation and neutralize free radicals from other molecules. Various kinds of antioxidants can be obtained in synthetic or natural form (Prasetya et al., 2020).

However, natural antioxidants are the alternative chosen at this time, considering the side effects found in synthetic antioxidants. Natural antioxidants have many advantages such as being able to protect the body from damage caused by reactive oxygen species, besides being able to prevent lipid peroxidation in food, and can also prevent degenerative diseases (Prasetya et al., 2020).

Antioxidants can be produced by our own bodies and can also be obtained from food ingredients in the form of vegetables and fruits. By consuming food sources of antioxidants, we actually no longer need to consume antioxidant supplements. Therefore, we can consume various vegetables and fruits that contain vitamins A, C, E and other minerals as sources of antioxidants to stay healthy (Yusriyani & Syarifuddin, 2021).

Natural antioxidant compounds can be found in fruits. One example of a plant that is a source of natural antioxidants is the red dragon fruit plant (*Hylocereus polyrhizus*). Dragon fruit is a plant that has the potential to be developed, one of which is as a source of natural antioxidants. The level of utilization and consumption of dragon fruit is increasing, but generally it is still limited to the processing of the fruit flesh, even though in fact there is still a lot of great potential that other parts have, one of which is the skin of the fruit. (Nizori & Nola, 2020).

Red dragon fruit skin (*Hylocereus polyrhizus*) contains vitamin C, vitamin E, vitamin A, alkaloids, terpenoids, flavonoids, thiamine, niacin, pyridoxine, cobalamin, phenolic, carotene and phytoalbumin. In addition, the superiority of dragon fruit skin is rich in polyphenols and is a source of antioxidants. In addition, the antioxidant activity in dragon fruit skin is greater than the antioxidant activity in the fruit flesh, so it has the potential to be developed as a natural source of antioxidants (Viany et al., 2019).

In this study, the antibiotic gentamicin was used, which is an aminoglycoside class of antibiotics which has nephrotoxic side effects because it can cause necrosis of tubular epithelial cells. After being filtered through the glomerulus, a small portion of gentamicin will be retained in the proximal tubule mainly in lysosomes, golgi apparatus, and endoplasmic reticulum. This accumulation leads to impaired kidney function. The production of reactive oxygen species (ROS) also plays an important role in the reversible process of gentamicin nephrotoxicity (Viany et al., 2019).

Reactive oxygen species directly cause damage to cellular molecules including nucleic acids, proteins, and lipids which can trigger cell death, causing inflammation and contraction of mesangial and blood vessels. Therefore the use of antioxidants to prevent increased ROS in the cytosol is effective in kidney damage induced by gentamicin. Doses of 50, 120, and 300 mg/kg BW can prevent decreased kidney function in rats due to gentamicin-induced parameters of serum creatinine (sCr) and blood urea nitrogen (Sujono & Rizki, 2020).

Administration of gentamicin as an aminoglycoside class of antibiotics which is widely used for the treatment of severe infections, especially for infections caused by

gram-negative bacteria and some gram-positive bacteria. Gentamicin can cause nephrotoxicity by inhibiting protein synthesis in kidney-building cells (Lukiswanto & Wiwik, 2017).

The mechanism is specifically by causing cell necrosis which will eventually lead to acute kidney failure. This depends on the dose of gentamicin used and the condition of the kidneys before therapy. Gentamicin is thought to be able to cause temporary or permanent changes in blood picture examination results related to impaired kidney function (Lukiswanto & Wiwik, 2017).

The results showed that the description of urea and creatinine levels in the male white rat group after administration of the ethanol extract of red dragon fruit skin (*Hylocereus polyrhizus*) showed that the ethanol extract of red dragon fruit skin (*Hylocereus polyrhizus*) dose of 100 mg/kg BW, dose of 200 mg/kg BW and a dose of 300 mg/kg BW has a nephrotherapy effect in reducing urea and creatinine levels. In addition, the ethanol extract of red dragon fruit peel contains alkaloids, flavonoids, tannins, saponins and phenolic compounds (Tuldjanah et al, 2021).

2. Methods

This research is an experimental research (experimental). This pre test and post test control study was to analyze the antioxidant activity of red dragon fruit peel extract (*Hylocereus polyrhizus*) against Cystatin C and Kidney Injury Molecule 1 (KIM-1) in gentamicin-induced wistar rats. (Rahmawati, 2016). This research has passed the research ethics committee through ethical clearance with number 024/KEPK/UNPRI/X/2022.

Place of Research This research was conducted at the Pharmacology Laboratory of the USU Faculty of Pharmacy to examine levels of urea, creatinine, cystatin, Kidney Injury Molecule 1 (KIM-1), microalbumin and histopathology. Time of Research.

3. Results and Discussion

Phytochemical Screening

Phytochemical screening of dragon fruit ethanol extract was carried out including examination of alkaloids, flavonoids, glycosides, saponins, tannins, and steroid/triterpenoid compounds. (Rahmawati, 2016).

The results of the phytochemical screening examination of dragon fruit ethanol extract can be seen in Table 1.

Table 1. Phytochemical screening of red dragon fruit ethanol extract

No.	Compound Class	Result
1.	Flavonoid	+
2.	Tanin	+
3.	Alkaloid	+
4.	Glikosida	+
5.	Saponin	+
6.	Steroid/triterpenoid	+

The results of the phytochemical screening showed that the ethanol extract of red dragon fruit contained flavonoids, alkaloid tannins, glycosides, saponins, steroids/triterpenoids (Rahmawati, 2016).

Dragon fruit skin has a higher total phenol content compared to red dragon fruit flesh. The total phenol in the red dragon fruit skin was 28.16 mg/100 kg while the red dragon fruit flesh was 19.72. Flavonoid compounds are polyphenolic compounds that contain 15 carbon atoms in their basic core. Betacyanin can also be found in dragon fruit at 10.3+0.22/100g red dragon fruit flesh and at 13.8 and

0.85 mg/100g in red dragon fruit skin, betacyanin which has a phenolic molecular structure (Rahmawati, 2016).

Phenolic compounds are a major group of phytochemical secondary metabolites (Hoda et al., 2019) which exhibit strong antioxidant capabilities due to the presence of phenolic groups that donate electrons or conjugate with metal ions (Hoyweghen et al., 2012). Phenolic compounds can be categorized into different groups such as flavonoids, phenolic acids, stilbenes and lignans based on the number of carbon molecules and the complexity of their structure (Hoda et al., 2019).

Each phenolic group has unique attributes due to its specific mole. Dragon fruit skin and flesh are potential sources of phenolic compounds, with the skin in particular being a source of phenolic antioxidants that have the potential to be used as ingredients for the food and pharmaceutical industries. (Hoda et al., 2019).

The ethanol extract of red dragon fruit peel is indicated to have alkaloid, phenolic, flavonoid, terpenoid, steroid, saponin and tannin compounds. The hydroxyl groups in red dragon fruit peel flavonoids can also affect antioxidant activity, the more free hydroxyl groups of ring B of a flavonoid, the greater its antioxidant activity (Amic, 2003). Betalain pigment, a derivative of phenolic compounds consisting of betacyanin and betaxanthin, in red dragon fruit skin acts as a natural dye.

Flavanoids were previously identified as the main group of phenolic compounds in dragon fruit. The largest number of compounds detected in dragon fruit samples came from this phenolic class. Eight subgroups of flavonoids were identified, including anthocyanins, dihydrochalcones, dihydroflavonols, flavanols, Flavanones, flavones, flavonols and Isoflavonoids. Flavonoids are a group of secondary metabolites produced by plants that are belongs to the large group of polyphenols. These compounds are present in all parts of the plant including leaves, roots, wood, bark, pollen, nectar, flowers, fruits, and seeds. Flavonoids have the ability to scavenge free radicals and inhibit lipid oxidation (Banjarnahor & Artanti, 2014; Treml & Smejkal, 2016). Lipid oxidation is caused by oxygen in the initiator, for example as found in free radicals, it is known that lipids have 3 reaction pathways, namely nonezymatic chain free radical auto-oxidation, nonezymatic and non-radical photo-oxidation, the latter, enzymatic oxidation by lipoginase (Nathalie, 2021)

Flavanoids together with polyphenols are strong antioxidants which can reduce cell necrosis and increase cell proliferation thereby helping to reduce tissue damage or cell death in the glomerular epithelium and kidney tubules, so that the kidney tubular epithelial cells experience necrosis. The antioxidant activity of phenolic and flavonoid components by reducing free radicals depends on the number of hydroxy groups in their molecular structure.

There is a relationship between the structure of flavonoids and phenolic compounds with their activity as antioxidants. Determination of phenol content using the Folin-Ciocalteu reagent based on the reducing power of the phenolic hydroxy groups. Phenol compounds reduce phosphomolybdate to form blue molybdenum (Huang, Ou, & Prior, 2005).

The colorimetric method used for the measurement of total flavonoids is based on the formation of a complex reaction between the flavonoid and aluminum chloride (AlCl₃). AlCl₃ solution will form a stable complex with the C4 keto group and the hydroxyl group of C3 or C5 in flavones and flavonols (Umar, 2008).

The phenolic and flavonoid compounds contained in the 82% ethanol extract have antioxidant activity and high SPF values and include broad spectrum UVA and UVB photoprotection. Routine compounds which are compounds derived from flavonoids have good photoprotective properties. Rutin occupies an important position in the list of natural sunscreen agents, thanks to its structural arrangement that shares similarities with organic UV filters as well as its extraordinary antioxidant potential to scavenge free radicals.

Red dragon fruit skin (*Hylocereus polyrhizus*) contains anthocyanin. Anthocyanins are phenolic compounds belonging to the flavonoid group. Anthocyanins also inhibit Interlukin-6 (IL-6) which works to repair kidney injury by reducing oxidative stress and inflammation (Widyasanti et al. 2015). Ethylene glycol causes poisoning in the kidneys. Ethylene glycol in the body is metabolized to glycoaldehyde by the alcohol dehydrogenase catalyst. Glycoaldehyde is converted to glycolic acid, then glycolic acid is metabolized to glyoxalic acid and finally to oxalic acid. Oxalic acid binds with calcium to form calcium oxalate crystals and deposits in organs which can cause damage to various organs of the body including the brain, heart, kidneys and lungs. Accumulation of calcium oxalate in the kidneys causes kidney damage and acute kidney failure (Brent, 2001).

In previous research, the ethanol extract of red dragon fruit peel contains chemical compounds that are useful as antioxidants, one of which is anthocyanin (Meidayanti Putri et al, 2015). At concentrations of 0.0625 g, 0.125 g and 0.25 g, the percentages of antioxidant activity were

6.468%, 9.738% and 12.286% respectively with an IC50 value of 3.14 gram/100ml. These results indicated that the ethanol extract of dragon fruit peel The red color can reduce free radicals (Niah, 2016).

Dragon fruit skin has a higher total phenol content compared to red dragon fruit flesh. The total phenol in the red dragon fruit skin was 28.16 mg/100 kg while the red dragon fruit flesh was 19.72. Flavonoid compounds are polyphenolic compounds that contain 15 carbon atoms in their basic core. Betacyanin can also be found in dragon fruit at 10.3+ 0.22/100g red dragon fruit flesh and at 13.8 and 0.85 mg/100g in red dragon fruit skin, betacyanin which has a phenolic molecular structure. (Niah, 2016).

Examination Results of Urea and Creatinine Levels

Urea and creatinine are the result of the formation of metabolites that are not needed by the body so they must be excreted through the kidneys. Detection of kidney damage using urea and creatinine levels is important because it can analyze kidney damage, especially in the glomerulus. In this study, the results showed that gentamicin damaged the kidneys so that the

levels of urea and creatinine in the group given only gentamicin increased, whereas in the group given ethanol extract of dragon fruit it provided a protective effect because it contains flavonoids and other secondary metabolites which provide a synergistic effect in preventing kidney damage (Rahmawati, 2016).

Ureum and Creatinine Levels

Urea and creatinine are the result of the formation of metabolites that are not needed by the body so they must be excreted through the kidneys. Detection of kidney damage using urea and creatinine levels is important because it can analyze kidney damage, especially in the glomerulus. In this study, the results showed that gentamicin damaged the kidneys so that the levels of urea and creatinine in the group given only gentamicin increased, whereas in the group given dragon fruit ethanol extract it provided a protective effect because it contains flavonoids and other secondary metabolites which provide a synergistic effect in preventing kidney damage, the data can be seen in the table below:

Table 2. Ureum and Creatinine Levels

No.	Group	Urea (mg/dL) Mean ± SD	Creatinine (mg/dL) Mean ± SD
1.	Group 1 Positive Control	12,467 ± 0,577	0,6018 ± 0,1417
2.	Group 2 Negative Control	51,702 ± 2,517	6,007 ± 1,033
3.	Group 3	43,167 ± 1,615	3,418 ± 0,33
4.	Group 4	30,97 ± 3,33	1,539 ± 0,317
5.	Group 5	15,313 ± 2,445	0,573 ± 0,199

Description: The results showed that the highest ureal and creatinine levels were found in the gentamis-induced group with ureal values of 51.702 ± 2.517 mg / dL and creatinine values of 6.007 ± 1.033 mg / dL

The drug discovery and development process is challenging, rewarding, time-consuming, and complex. Delays in drug development are not uncommon due to unexpected toxicity and side effects in clinical studies. Therefore, there is a need to identify, validate and evaluate various biomarkers that aid decision-making for the advancement of compounds to the next

nonclinical or clinical developmental stage (Rahmawati, 2016).

An emerging approach to achieving this goal is the use of biomarkers early in the lead optimization phase or Phase 1 clinical trials. Renal safety assessment is a mandatory component of preclinical trials and clinical trials of new test materials. Drug-induced kidney injury is one of the reasons for reducing compounds in drug development. Kidney damage may be acute (sudden decrease in kidney function or urine output) or chronic (continuous structural and functional changes) and is traditionally diagnosed using serum

markers such as elevated urea and creatinine levels only after significant kidney damage (approx. 30%) (Rahmawati, 2016).

Because this marker is neither sensitive nor specific, a novel kidney biomarker has been used recently as a tool to evaluate early kidney damage in both preclinical species and humans. Gentamicin is an effective aminoglycoside antibiotic that is widely prescribed to treat patients with infections, but the associated side effects of oxidative stress and kidney injury limit its long-term clinical use. The onset of renal failure is usually slower and the daily increase in serum creatinine tends to be lower than for other causes of acute renal failure (Rahmawati, 2016).

Serum creatinine and blood urea nitrogen typically increase 7-10 days after starting aminoglycoside therapy. In more than half of cases with nephrotoxicity, decreased renal function occurs only after completion of therapy. A long duration is required to recover from gentamicin-induced nephrotoxicity,

especially in the elderly. Although the majority of patients recover, the presence of several risk factors can alter the clinical picture or course of the disease, resulting in the development of acute renal failure and a prolonged course of the disease (Rahmawati, 2016).

KIM-1 Level Test Results

KIM-1 is a type I membrane protein, consisting of an extracellular portion and a cytoplasmic portion, which is expressed at very low levels in normal kidneys. The extracellular portion can divide and rapidly enter the tubular lumen after kidney injury, and can then be detected in the urine. It has been confirmed that urinary KIM-1 levels are closely related to tissue KIM-1 levels and correlate with kidney tissue damage. KIM-1 has not only been shown to be an early biomarker of acute kidney injury but also has a potential role in predicting long-term renal outcome. The group that was given gentamicin experienced an increase in KIM-1 levels. Data can be seen in table 11 below;

Table 3. KIM-1 Levels

No.	Group	KIM-1 (pg/mL) Mean ± SD
1.	Group 1 Positive Control	30,88 ± 1,22
2.	Group 2 Negative Control	115,387 ± 3,601
3.	Group 3	78,90 ± 3,47
4.	Group 4	51,60 ± 2,77
5.	Group 5	33,52 ± 2,583

Description: The results showed that the highest levels of KIM-1 were found in the gentamicin-induced group with values of 115.387 ± 3.601 pg/mL

Our data clearly reveal that Gentamicin induced kidney injury in all study animals, as seen by the increase in KIM-1 tissue. Many protein products that can serve as new biomarkers for the initiation phase of AKI have been studied, including kidney injury molecule-1 (KIM-1), neutrophil-associated lipocalin gelatinase (NGAL) and others.

KIM-1 is a type I transmembrane glycoprotein that is not detected in healthy kidneys. Increased expression of this protein was found at very high levels in the apical membranes of proximal tubular cells after ischemic and nephrotoxic injury. Urinary KIM-1 outperforms urinary SCr, BUN, and NAG in

several rat kidney injury models and may facilitate sensitive, specific, and accurate prediction of human nephrotoxicity in preclinical drug screening (Rahmawati, 2016).

Kadar Cystatin

Cystatin C (CysC) is a small molecule 13.3 kDa, 122 amino acids inhibitor of basic non-glycosylated cysteine proteases (lysosomal proteinases), prevents the breakdown of certain intracellular and extracellular proteins in the body, is constitutively expressed by all nuclear cells, and is synthesized and is secreted into plasma at a steady rate. Under healthy conditions, negligible amounts of CysC are found in the urine. CysC is a validated and quality biomarker of acute tubular and glomerular injury in mice and is elevated during impaired gentamicin reabsorption capacity. Cystatin C levels in the blood do not change

with muscle mass, exercise, gender, age of the individual, etc (Rahmawati, 2016).

Therefore, it is considered a more realistic marker for the assessment of glomerular function even in cachexia or early AKI, where serum creatinine may underestimate true kidney function. CysC is considered a specific marker for the assessment of glomerular filtration rate (GFR) rather than a primary marker for AKI although it can be used to detect AKI (Rahmawati, 2016).

Many independent studies have demonstrated the superiority of serum cystatin C compared to serum creatinine, especially for detecting minor changes in decreased GFR. Investigators started using serum CysC as a marker of GFR recently in toxicology studies although it has been widely used in the clinic. It has been demonstrated that serum CysC is superior to other traditional markers in detecting site-specific nephrotoxicity in mice. In this study, gentamicin administration increased cystatin c levels. Data can be seen in the table below:

Table 4. Cystatin Levels

No.	Group	Cystatin (pg/mL) Mean \pm SD
1.	Group 1 Normal Control	0,732 \pm 0,12
2.	Group 2 Negative Control	24,700 \pm 2,06
3.	Group 3	12,617 \pm 1,723
4.	Group 4	3,937 \pm 1,88
5.	Group 5	1.12 \pm 0.28Good

Description: The results showed that cystatin levels in the normal group were 0.732 ± 0.12 , the control group was negative 24.700 ± 2.06 , group 3 12.617 ± 1.723 , group 4 3.937 ± 1.88 and group 5 1.12 ± 0.28 good, the highest cystatin levels were found in the gentamicin-induced group with values of 24.700 ± 2.06 pg/mL

Statistically, the group that was given red dragon fruit ethanol extract at doses of 200 and 300 was not significantly different $p > 0.05$ from the normal group, while the negative group that was only given gentamicin had a significant difference. $P < 0.05$ in the normal group, because the dose of 300 has a higher antioxidant so there is an effect on filtration in the nephrons.

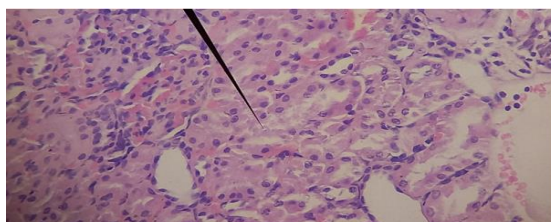
The choice of dose of 300 mg/kg BW is because according to previous research conducted by Niah 2019, the concentration values used for the antioxidant activity of red dragon fruit peels

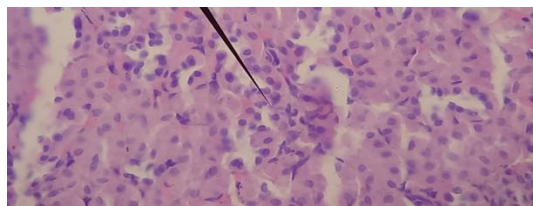
of 62.5 mg, 125 mg and 250 mg can reduce free radicals.

Renal Histopathological Examination Results

The results of histopathological examination of the kidneys with exposure to the antioxidant activity of red dragon fruit peel extract (*hylocereus polyrhizus*) against cystatin c and kidney injury molecule 1 (kim-1) in gentamicin-induced white wistar rats in this case can result in changes in the kidney organs in rats. In normal preparations, the rat kidney is red and the glomerulus is perfectly shaped. After the induction of gentamicin in the kidneys began to appear. The results of histopathological observations of the rat kidneys that had been treated at each concentration are presented in Figure 5 as follows:

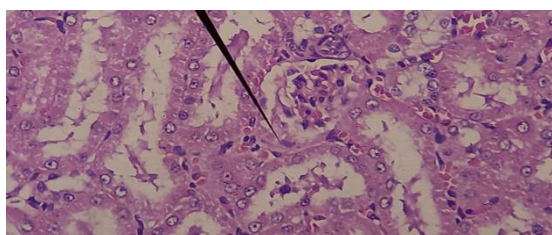
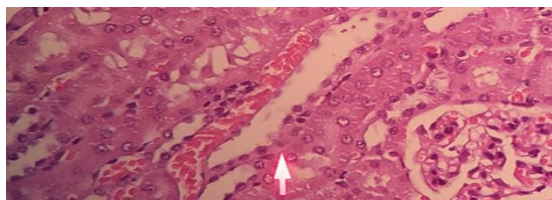
Positive Control





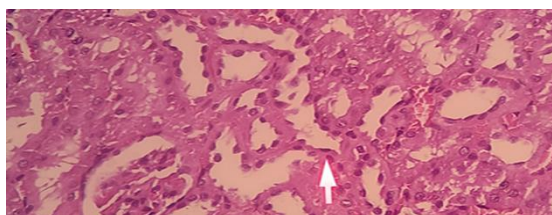
Positive Control: (without Damage)

Negative Treatment

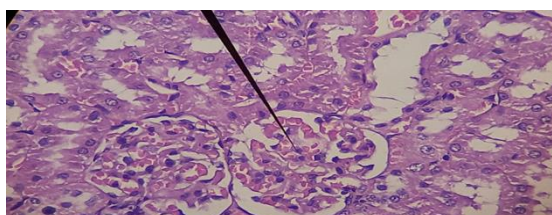


Negative Control : Pigment Deposits, Degeneration Swelling, Lumen Tubule Damage, Glomerular Damage, Cleft Bomen Narrowing

Treatment 3

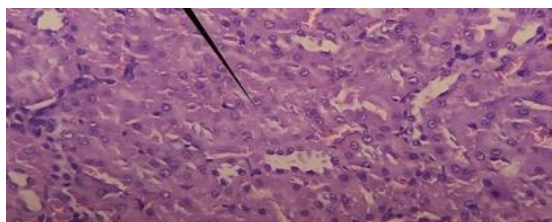


Treatment 3. Pigment deposit, Damage to the lumen of the tubules



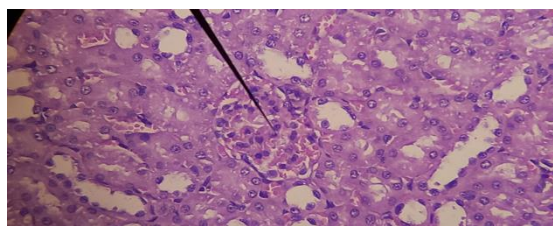
Treatment 3. Glomerular Congestion, Degeneration Swelling)

Treatment 4



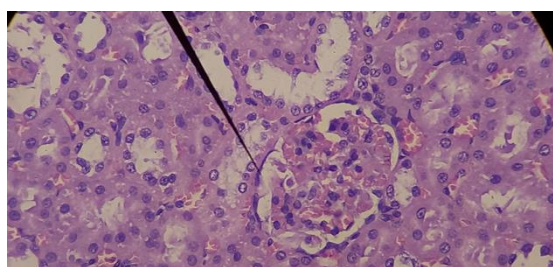
Treatment 4: (Pigment Deposit, Proximal Tubule Necrosis)

Treatment 4: (Pigment Deposits, epithelial necrosis (Proximal Tubule)

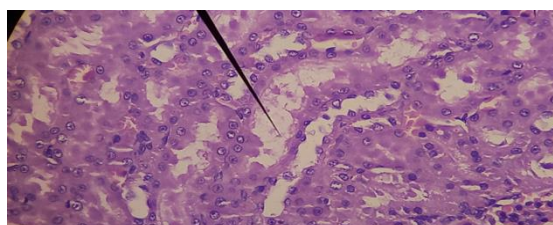


Treatment 4: (Cells degenerate)

Treatment 5



Treatment 5: (Pigment deposits, epithelial necrosis, proximal tubules



Treatment 5: (Degeneration Swelling)

Table 5. Results of Observations on Tissues that Occur in the Kidneys

Treatment	Concentration	Forms of tissue damage to the kidneys
Group 1	Control	No damage occurred
Group 2	The group of white rats were given aquades orally (p.o) and gentamicin 100 mg/kgBB intraperitoneal (i.p)	Pigment deposits, degeneration swelling, damage to the lumen of the tubules, damage to the glomerulus, narrowed bomen cleft
Group 3	The white rat group was given Red Dragon Fruit Skin Extract Antioxidants (<i>Hylocereus polyrhizus</i>) 100 mg/kgBB orally (p.o) and gentamicin 100 mg/kgBB intraperitoneal (i.p)	Pigment deposits, glomerular damage, lumen damage, tubules;
Group 4	The white rat group was given Red Dragon Fruit Skin Extract (<i>Hylocereus polyrhizus</i>) 200 mg/kgBB orally (p.o) and gentamicin 100 mg/kgBB intraperitoneal (i.p)	Pigment deposits, epithelial necrosis of the proximal tubules, degenerated cells
Group 5	Antioxidants Red Dragon Fruit Skin Extract (<i>Hylocereus polyrhizus</i>) 300 mg/kgBB orally (p.o) and gentamicin 100 mg/kgBB intraperitoneal (i.p)	Pigment deposits, proximal tubular epithelial necrosis, swelling degeneration

From the results of the study, the Wistar rats group which was given gentamicin 100 mg/kgBB with antioxidant red dragon fruit peel extract (*Hylocereus*

polyrhizus) 300 mg/kgBB orally showed less proximal tubular damage than the treatment group which was given gentamicin without the antioxidant

fruit peel extract. red dragon (*Hylocereus polyrhizus*). Based on microscopic observations, it was found that there was closure of the proximal tubule lumen and necrosis of the proximal tubular epithelium in rats given gentamicin 100 mg/kgBW intraperitoneally. Antioxidant administration of red dragon fruit skin extract (*Hylocereus polyrhizus*) showed improvement of kidney histology damaged due to the negative effect of gentamicin. Of the three antioxidant doses of red dragon fruit peel extract (*Hylocereus polyrhizus*) given orally (100 mg/kg BW, 200 mg/kg BW, 300 mg/kg BW) to rats given gentamicin, the higher the antioxidant dose of red dragon fruit peel extract (*Hylocereus polyrhizus*) given showed a decrease in the mean amount of damage to the proximal tubule lumen. In proximal

tubule damage in treatment 5, which was given antioxidant red dragon fruit skin extract (*Hylocereus polyrhizus*) dose of 300 mg/kg BW showed improvement in kidney histology. This is in accordance with the theory that antioxidants can reduce cell degeneration due to free radicals. High antioxidants can be found in red dragon fruit skin extract (*Hylocereus polyrhizus*) which has been known as an antioxidant capable of maintaining the integrity of cell membranes. Giving high doses of antioxidants from red dragon fruit skin extract (*Hylocereus polyrhizus*) can provide protection against cell damage in the kidneys. According to Mayori (2015) states that the level of kidney damage increases with the dose and duration of administration of chemicals that can be toxic.

Table 6. Average Total Renal Histopathology

Sample No	Tubule damage		
	Tubule dilation	The boundary between the tubules is lost	Glomerular damage
1	1	0	1
2	0	0	1
3	1	0	1
4	1	0	0
5	0	0	0
6	2	3	3
7	1	2	3
8	2	2	2
9	1	3	2
10	2	2	3
11	3	2	2
12	2	2	2
13	2	2	1
14	1	1	2
15	2	1	3
16	2	1	2
17	2	1	2
18	1	1	3
19	1	2	1
20	1	1	2
21	0	1	1
22	0	1	2
23	1	1	1
24	1	0	1
25	1	1	2

Tubule damage

1. : Normal
2. : light (Focal)
3. : medium (Multifocal)

4. : weight (Diffuse)

Glomerular damage

1. : normal
2. : inflammatory cell infiltration
3. : edema spatium bowman
- 0 : necrosis

Based on the average histopathological total score table, tubular damage occurs with tubular dilatation and glomerular damage. Kidney damage due to toxic substances can be identified based on changes in histological structure, namely acute tubular necrosis (ANT) which is morphologically characterized by destruction of the proximal tubular epithelium. In nephrotoxic ATN, there is a pale, enlarged and edematous renal cortex, pyramidal congestion, cytoplasmic vacuolization of tubular epithelial cells and most of it in the proximal tubule (Suhita, 2013).

Based on observations on the histopathology of rat kidney toxicity after administration of antioxidants from red dragon fruit skin extract (*Hylocereus polyrhizus*), it showed that there were changes in the histological structure of the kidneys including the discovery of cell degeneration and also cell necrosis in each treatment group. Damage that occurs to the kidneys can be caused by several factors, including due to toxic substances that enter the body, where the main function of the kidneys is to excrete metabolic wastes. Damage to the kidneys caused by toxic substances can be identified through changes in histological structure including the occurrence of necrosis of cells which is morphologically characterized by the destruction of proximal tubular epithelial cells where proximal tubular epithelial cells have sensitivity to anoxia and are easily destroyed in case of poisoning due to residual - metabolic waste excreted by the kidneys So that changes.

Histology in the kidney can be ascertained due to the number of compounds that enter the body (Suhita, 2013). Red dragon fruit skin extract has antioxidant substances to help the body fight excess free radicals resulting in a decrease in the number of damaged cells according to the additional dose of red dragon fruit skin extract (Cristovao, 2019).

From the results of statistical analysis of kidney histopathology, there are two things that can be concluded that:

1. The ethanol extract of dragon fruit contains flavonoids which can play an important role in preventing apoptosis in tissues so that histopathologically it shows improvement in the kidney while the group that was given gentamicin alone suffered damage, especially in the glomerulus

2. Dragon fruit ethanol extract indirectly has anti-inflammatory activity so it can reduce markers of heart damage such as cystatin and KIM-1.

Giving gentamicin for 10 days at a dose of 60 mg/kgBW/day in addition to the description above also shows the presence of tubular epithelial cells with fat, enlarged cells with large vacuoles in the cytoplasm and the nucleus is pushed to the side, this is called macrovesicular fat (Rahmawati, 2016).

Glomerulonephritis is inflammation that occurs in the glomerulus, which is the part of the kidney that functions to filter waste products and remove excess fluids and electrolytes from the body. If not treated immediately, severe or prolonged glomerulonephritis can lead to kidney failure. Glomerulonephritis can occur suddenly (acute) or last a long time (chronic). This condition can also develop quickly and cause kidney damage (rapidly progressive glomerulonephritis) (Rohmatika Nabhani, 2021)

Gentamicin (GM) is an aminoglycoside antibiotic commonly used to treat bacterial infections, especially those caused by aerobic gram-negative bacilli. Its nephrotoxicity is a major concern from a clinical perspective. It is estimated that more than one third of patients on long-term (more than 7 days) administration of gentamicin show signs of kidney damage. The renal toxicity of gentamicin contributes to its ability to activate apoptosis in kidney tissue (Amalia, 2018).

Gentamicin is classified as an aminoglycoside antibiotic which is known to be toxic to the kidneys. One of the consequences that can be caused by this nephrotoxic agent is damage to the kidney tubules (Siahaan et al., 2016).

The formation of free radicals by nephrotoxic substances is thought to play a role in causing cell injury. The body's response to counteract free radicals is to produce endogenous antioxidants. Free radicals that are formed exceed the amount of endogenous antioxidants, so they need exogenous antioxidants to compensate. In general, the side effects of gentamicin are divided into three groups, namely allergies, irritation and toxicity reactions, and biological changes (Rohmatika Nabhani, 2021)

The kidney is one of the vital organs of the body, because it functions to filter and excrete the remains of the body's metabolism. Increased excretion of metabolic remnants can cause kidney damage, due

to poisoning resulting from contact with these materials. Kidneys are organs where the process of filtering blood occurs. Contaminants carried by the blood which are metabolic wastes accumulate in the kidneys. Contaminants are very harmful to the kidneys, which can cause inflammation and accumulation of extra cellular matrix (Hu et al., 2008).

Failure of the kidney tissue healing system due to chronic trauma is known as renal fibrosis. Renal fibrosis is a type of damage that is difficult to restore because it is irreversible. Renal fibrosis includes chronic kidney symptoms that indicate a long-lasting damage process has occurred (Rohmatika Nabhani, 2021)

The main sites of gentamicin-induced nephrotoxicity are mesangial cells and renal proximal tubular cells. Gentamicin can act on mitochondria and cause oxidative stress which causes necrosis and apoptosis. Gentamicin causes tubular injury featuring loss of the brush-like margins of the epithelial cells. Without intervention, the tubular injury progresses to acute tubular necrosis. Gentamicin-induced renal toxicity can be evaluated by histopathological and morphometric examinations, as well as serum creatinine and blood urea nitrogen levels (Amalia, 2018)

A central aspect of the nephrotoxicity of aminoglycosides is their tubular cytotoxicity. Treatment of experimental animals with gentamicin resulted in apoptosis and tubular epithelial cell necrosis. In culture, gentamicin also causes apoptosis and necrosis of these cells. The lethal phenotype may depend on the concentration of the drug, as can other cytotoxic compounds such as cisplatin. It may also depend on the approval of other triggering or predisposing factors, such as the degree of ischemia, at specific points of the renal parenchyma. Apoptosis is a process that requires ATP (Amalia, 2018)

When the cell's ATP reserves fall, the death mode loses the typical characteristics of apoptosis and acquires those of necrosis. Hypoxia inhibits respiration, ATP production, and sensitizes cells to Fas32 ligands and induces cell death. However, the most commonly observed *in vitro* phenotype is apoptosis, possibly because cultured cells need to be exposed to high drug concentrations (>1 to 2 mg/ml) to observe modest cytotoxic effects (Amalia, 2018)

Dragon fruit is believed to have originated in Mexico and Central and South America. Currently, this fruit is widely cultivated and gained popularity in Thailand, Malaysia, Indonesia, China, Vietnam, Taiwan, Bangladesh and Australia. Typical of cacti, pitaya is an evergreen perennial with a cladode (as stem). Fruits are categorized by the presence of unique bracts on the bright red (pink to purple) thin skin of the fruit (Pardede, 2016)

The flowers and fruit of the plant are edible. Depending on the cultivar, the edible pulp can be red (pink) (*H. polyrhizus*), white (*H. undatus*), or yellow (*H. megalanthus*) with small black edible seeds. Overall, the average fruit weight is about 300–350 g, and one plant is estimated to produce up to six fruit cycles annually (Pardede, 2016)

Dragon fruit is loved by consumers because of its unique taste, shape and flesh color. Although pitaya is preferred to be eaten fresh, its intake as a fresh juice is more popular in growing areas. Pitaya-based products such as jams and candies are commercially available in Malaysia and Indonesia. The preparation of wine from red pitaya is also reported in the Guangxi province of China. Pitaya fruit (skin and flesh) is reported to contain water-soluble betacyanin, which is responsible for its intense red (dark pink/purple) color and antioxidant activity. In addition, lycopene, vitamin E, and beta-carotene were reported in the pulp (Pardede, 2016)

Fruits are high in total polyphenols, tannins, betalains, nonbetalainic compounds, and antioxidant compounds. Oligosaccharides from pitaya fruit are associated with prebiotic properties. Pitaya skin contains high amounts of pectin and insoluble fiber to dissolve. In addition, processed powder from the fruit has the potential to be used as a natural food coloring. Significant amounts of betacyanin pigment were reported from the peel. Inhibition of melanoma cell growth was also reported from red dragon fruit peel extract. Pitaya fruit intake was also associated with reduced dyslipidemia and increased wound healing capacity in diabetic rats. Seeds contain essential fatty acids which are dominated by linoleic and linolenic acids (Anggraini, 2013)

The mechanism of dragon fruit ethanol extract to prevent kidney damage due to gentamicin can be seen in figure 5 below:

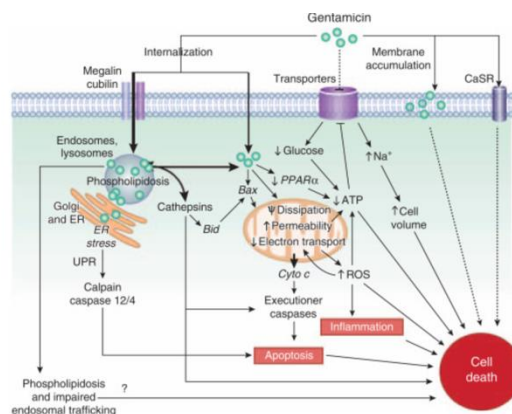


Figure 5. Dragon Fruit Ethanol Extract Prevents Kidney Damage Due to Gentamicin (Anggraini, 2013)

The kidney is an important organ in the rat's body which functions to filter waste from the blood and send it to the bladder to become urine. In addition, the kidneys also regulate blood pressure, regulate water absorption, control acidity in the body, and balance electrolyte levels. Therefore, if there is even a little damage to the kidneys, it will be fatal. The treatment also takes a long time. Eating foods that are good for the kidneys can also lighten and facilitate the work of the kidneys (Latifah, 2010).

Dragon fruit is good for preventing various kinds of degenerative diseases and neutralizing toxins in the body. The fiber content in dragon fruit reaches 0.7-0.9 grams per 100 grams. In the digestive tract, fiber will bind bile acids (the end product of cholesterol) and then excreted simultaneously with the feces. The higher the consumption of fiber, the more bile acids and fat excreted by the body. Dragon fruit is also known as a source of beta-carotene, which is pro-vitamin A which is converted into vitamin A in the body which is beneficial for vision, reproduction and other metabolic processes (Latifah, 2010).

Data Analysis Results

From the results of the data normality test with Kruskal Wallius, it was found that $p > 0.05$ for each treatment group, it was found that the data were normally distributed (Ahad, 2011). Because the data is normally distributed, it can be continued with the ANOVA parametric statistical test (Wahyuni, 2007).

Based on the data from the ANOVA test results, the p value of serum urea, creatinine, and histopathological score for each treatment was 0.000 (< 0.05). Thus, it can be concluded that there are significant differences from each group. The analysis was continued with Post-Hoc LSD to find out the relationship between each of the further treatments (Rohmatika Nabhani, 2021)

In the LSD Post-Hoc test, the serum urea and creatinine levels of the group that were given red dragon fruit ethanol extract at doses of 200 and 300

were not significantly different $p > 0.05$ from the normal group, while the negative group that was only given gentamicin had a significant difference. $P < 0.05$ in the normal group. The highest urea and creatinine levels were in the gentamicin-induced group with urea values of 51.702 ± 2.517 mg/dL and creatinine values of 6.007 ± 1.033 mg/dL. Group 1 had a significant difference with groups 3 and 5 ($p < 0.05$), group 2 had a significant difference which is significant with Groups 3 and 5 ($p < 0.05$), Group 3 has a significant difference with Group 2, 5 ($p < 0.05$), Group 4 has a significant difference with Group 5 ($p < 0.05$), Group 5 has a significant difference significant with all treatment groups ($p < 0.05$) (Rohmatika Nabhani, 2021)

Post-Hoc LSD test KIM-1 levels in the group that was given red dragon fruit ethanol extract at doses of 200 and 300 were not significantly different $p > 0.05$ from the normal group, while the negative group that was only given gentamicin had a significant difference. $P < 0.05$ in the normal group. The highest KIM-1 levels were found in the gentamicin-induced group with a value of 115.387 ± 3.601 pg/mL. Group 1 and Group 2 had significant differences with Groups 3, 4 and 5, ($p < 0.05$), Groups 3, 4 and 5 had significant difference with all treatment groups ($p < 0.05$) (Rohmatika Nabhani, 2021)

The highest levels of Post-Hoc cystatin LSD were found in the gentamicin-induced group with a value of $24,700 \pm 2.06$ pg/mL Group 1 and Group 2 had significant differences with Groups 3, 4, and 5, ($p < 0.05$), Group 3, 4 and 5 had significant differences with all treatment groups ($p < 0.05$) (Rohmatika Nabhani, 2021)

For the LSD Post-Hoc test the renal histopathological scores of Group 1 and Group 2 had a significant difference with Groups 3, 4 and 5 ($p < 0.05$), Group 3 had a significant difference with Groups 1, 2 and 4 ($p < 0.05$), Group 4 had a significant difference with all treatment groups ($p < 0.05$), Group 5 had a significant difference with

Groups 1, 2 and 4 (p <0.05) (Rohmatika Nabhani, 2021).

Calculation of percent Damping and IC50 value
Percent Damping Calculation

Antioxidant Value

Table 7. Absorbance Data

No.	Concentration	Absorbance			Average
		Repetition 1	Repetition 2	Repetition 3	
1.	0	0,850(Akontrol)			0,850(Akontrol)
2.	20	0,742	0,76	0,71	0,737
3.	40	0,678	0,654	0,594	0,642
4.	60	0,639	0,488	0,54	0,556
5.	80	0,551	0,47	0,386	0,469
6.	100	0,471	0,389	0,317	0,392

Calculation of IC50 value

Table 8. IC50

No.	X	And	XY	X2	(ΣX) ²
1	0	0	0	0	90000
2	20	13,2941	265,8824	400	
3	40	24,4706	978,8235	1600	
4	60	34,5882	2075,2941	3600	
5	80	44,8235	3585,8824	6400	
6	100	53,8824	5388,2353	10000	
Σ	300	171,0588	12294,1176	22000	
Mean	50	28,5098	2049,0196	3666,66667	

Description: X = Concentration (ppm)
Y = % Peredaman

IC50 Value Calculation

The calculation of the result of the DPPH ranking method is to calculate IC50. this value indicates that plant extracts can cause a reduction of as much as 50% of DPPH activity. This can also be seen from the color change of the test sample which is deep purple when

added DPPH will turn yellowish if the extract has damping. The calculation results are entered into the regression equation with the sample concentration (ppm) as the abscissa (X axis) and the percent value of damping activity as the ordinate (Y axis)

Wavelength

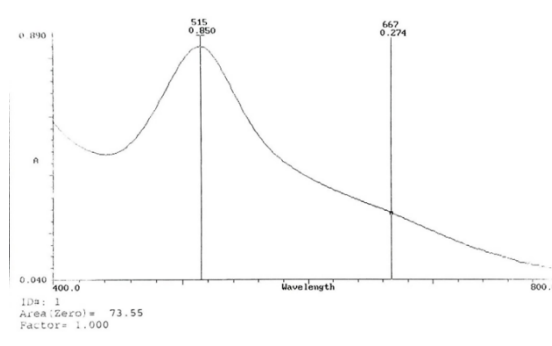


Figure 6. Antioxidant Wavelengths

Antioxidant Curve

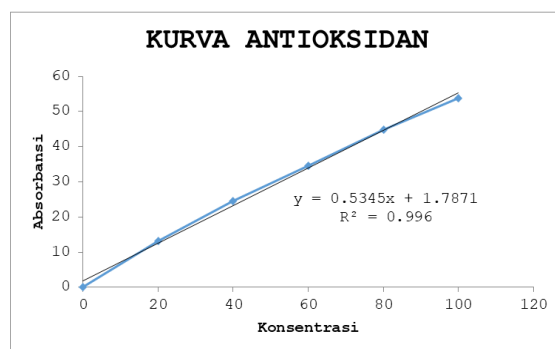


Figure 7. Antioxidant Curve

4. Conclusion

Dragon fruit ethanol extract dose of 300 mg / kgbw can reduce ureal and creatinine levels significantly ($p < 0.05$) when compared to the group given only gentamicin.

Dragon fruit ethanol extract dose of 300 mg / kgbw can reduce KIM-1 levels significantly ($p < 0.05$) when compared to the group given gentamicin only.

Dragon fruit ethanol extract dose of 300 mg / kgbw can reduce cystatin levels significantly ($p < 0.05$) when compared to the group given only gentamicin.

Dragon fruit ethanol extract exerts a histopathological protective effect on the kidneys.

Suggestion

Dragon fruit ethanol extract can be tested in the next in vitro experimental model.

References

- Adawiah, A., & Muawanah, A. (2015). Aktivitas antioksidan dan kandungan komponen bioaktif sari buah namnam. *Jurnal Kimia VALENSI*, 1(2), 130–136.
- Agustin, A., Dian, H., & Arif, P. (2020). Pengaruh aromaterapi inhalasi terhadap kecemasan pasien hemodialisa. *Prosiding Seminar Nasional Keperawatan Universitas Muhammadiyah Surakarta*, 16–24.
- Amalia, M. N. (2018). Aktivitas antioksidan emulgel gamma oryzanol sebagai anti aging terhadap mencit yang dipapar sinar ultraviolet b. *Fakultas Kedokteran dan Ilmu Kesehatan Universitas Islam*

Negeri Syarif

- Andarina, R., & Djauhari, T. (2017). Antioksidan Dalam Dermatologi. *Jurnal Kedokteran Dan Kesehatan*, 4(1), 39–48.
- Andriani, Y. (2007). Uji aktivitas antioksidan ekstrak betaglukan dari *Saccharomyces Cerevisiae*. *Gradien*, 3(1), 226–230.
- Anggraini, A. (2013). Pengaruh Pemberian Ekstrak Kulit Manggis (*Garcinia Mangostana L.*) Dalam Mencegah Peningkatan Kadar Proteinuria Tikus Putih (*Rattus Norvegicus*) Yang Diinduksi Gentamisin.
- Ansel, H. (2014). *Pengantar Bentuk Sediaan Farmasi Edisi Keempat Penerjemah, Farida Ibrahim*. Jakarta, UI-Pres.
- Dungir, S. G., Katja, D. G., & Kamu, V. S. (2012). Aktivitas antioksidan ekstrak fenolik dari kulit buah manggis (*Garcinia mangostana L.*). *Jurnal Mipa*, 1(1), 11–15.
- Ervina, L., Bahrin, D., & Lestari, H. I. (2015). Tatalaksana Penyakit Ginjal Kronik pada Anak. *Majalah Kedokteran Sriwijaya*, 47(2), 144–149.
- Haerani, A., Chaerunisa, A., & Subarnas, A. (2018). Antioksidan Untuk Kulit. *Jurnal Farmaka*, 16(2), 135–151.
- Handi, R., Hengky, T., & Tinalia, P. (2018). Faktor - Faktor yang Mempengaruhi Kualitas Hidup Pasien Chronic Kidney Disease (CKD) yang Menjalani Hemodialisa di Ruang Hemodialisa. *Jurnal Keperawatan Silampari*, 1(2), 32–46.

- Husna, C. (2014). Gagal Ginjal Kronis dan Penanganannya. *Jurnal Keperawatan Unimus*, 3(1), 66–73.
- Hutagaol, E. V. (2017). Peningkatan Kualitas Hidup Pada Penderita Gagal Ginjal Kronik yang Menjalani Terapi Hemodialisis melalui Psychological Intervention di Unit Hemodialisa RS. Royal Prima. *Jurnal Jumantik*, 2(1), 43–59.
- Indriani, E., Amalia, R., & Levita, J. (2021). Peran dan Metode Pengukuran Protein Kidney Injury Molecule-1 (Kim-1) sebagai Biomarker pada Cedera Ginjal Akut. *Jurnal Sains Farmasi & Klinis*, 8(2), 93. <https://doi.org/10.25077/jsfk.8.2.93-106.2021>
- Irianti, T., Sugiyanto, Sindu, N., & Kuswandi. (2017). Antioksidan. Yogyakarta, Universitas Gadjah Mada.
- Julianto, T. S. (2019). Fitokimia Tinjauan Metabolit Sekunder dan Skrining Fitokimia. Universitas Islam Indonesia.
- Kardila, A., Zantrie, R., & Teresia Marbun, R. A. (2019). Identifikasi Kadar Vitamin C Pada Daging dan Kulit Buah Naga Merah (*Hylocereus polyrhizus*) dengan Metode Spektrofotometri Uv Visible. *Jurnal Farmasi*, 2(1), 40–46. <https://doi.org/10.35451/jfm.v2i1.285>
- Kemendes RI. (2018). Laporan Nasional Riset Kesehatan Dasar (Riskesdas) Tahun 2018. In Badan Penelitian dan Pengembangan Kesehatan, Kementerian Kesehatan RI.
- Latifah, I. N. (2010). Pengaruh pemberian ekstrak jahe merah (*Zingiber officinale rosc.*) terhadap sel nekrosis pada jaringan glomerulus dan tubulus ginjal tikus putih (*Rattus norvegicus*) yang terpapar allethrin. Universitas Islam Negeri Maulana Malik Ibrahim.
- Lukiswanto, B., & Wiwik, M. Y. (2017). Pengaruh Ekstrak Buah Delima Terstandar 40 % Ellagic Acid Terhadap Profil Darah Tikus Putih yang Mengalami Nefrotoksitas Akibat Induksi Gentamicin. In *Jurnal Sain Veteriner*.
- Lung, J. K. S., & Destiani, D. P. (2017). Uji aktivitas antioksidan vitamin A, C, E dengan metode DPPH. *Farmaka*, 15(1), 53–62.
- Malangngi, L., Sangi, M., & Paendong, J. (2012). Penentuan kandungan tanin dan uji aktivitas antioksidan ekstrak biji buah alpukat (*Persea americana* Mill.). *Jurnal Mipa*, 1(1), 5–10.
- Mescher, A. (2017). Histologi Dasar Qunqueira. Jakarta, EGC.
- Niah, R., & Baharsyah, R. N. (2018). Uji Aktivitas Antioksidan Ekstrak Etanol Kulit Buah Naga Merah Super (*Hylocereus costaricensis*). *Jurnal Pharmascience*, 5(1), 14–21. <https://doi.org/10.20527/jps.v5i1.5781>
- Nizori, A., & Nola, S. (2020). Karakteristik Ekstrak Kulit Buah Naga Merah (*Hylocereus Polyrhizus*) Dengan Penambahan Berbagai Kosentrasi Asam Sitrat Sebagai Pewarna Alami Makanan. *Jurnal Teknologi Industri Pertanian*, 30(2), 228–233. <https://doi.org/10.24961/j.tek.ind.pert.2020.30.2.228>
- Notoatmodjo, S. (2012). *Metodologi Penelitian Kesehatan*. Rikena Cipta, Jakarta.
- Pardede, S. O. (2016). Struktur sel streptokokus dan patogenesis glomerulonefritis akut pascastreptokokus. *Sari Pediatri*, 11(1), 56–65.
- Prasetya, I. P. D., Arijana, I. G. K. N., Linawati, N. M., Wayan, & Sudarmaja, M. (2020). Krim Ekstrak Kulit Buah Naga Super Merah (*Hylocereus costaricensis*) Meningkatkan Kelembapan Kulit Tikus Wistar (*rattus norvegicus*) Yang Dipapar Sinar ultraviolet. *Jurnal Medika Udayana*, 9(1), 76–82.
- Putriana, D., Virhan, N., Andriani, & Willy, H. (2017). Pengaruh Pemberian Astaxanthin terhadap Kadar Ureum dan Kreatinin Serum Tikus Putih (*Rattus norvegicus*) Galur Wistar yang diinduksi Formaldehid secara Oral. *Jurnal Kesehatan Khatulistiwa*, 3(1), 445–460.
- Rahmawati, M. (2016). Aktivitas Antioksidan Ekstrak Kulit Buah Naga Merah

- (*Hylocereus polyrhizus*) Secara In Vitro. *Laboratory*, 4(2), 145–153. <https://doi.org/10.33992/m.v4i2.64>
- Rahmi, H. (2017). Aktivitas Antioksidan dari Berbagai Sumber Buah-buahan di Indonesia. *Jurnal Agrotek Indonesia*, 2(1), 34–38. <https://doi.org/10.33661/jai.v2i1.721>
- Risnayanti, Sri, M., & Ratman. (2015). Analysis of Differences In Vitamin C Levels of Red Dragon (*Hylocereus polyrhizus*) and White Dragon (*Hylocereus undatus*) Fruits Growth In Kolono Village Morowali Central Sulawesi. *Jurnal Akad Kimia*, 4(2), 91–96.
- Rohmatika Nabhani, S. (2021). Uji Aktivitas Antioksidan dan Antibakteri Ekstrak Bandotan (*Ageratum conyzoides* L.) Terhadap Bakteri *Streptococcus pyogenes*.
- Sujono, T. A., & Rizki, F. A. (2020). Efek Nefroprotektif Ekstrak Etanol Bawang Putih (*Allium sativum* L.) pada Tikus yang Diinduksi Gentamisin. *Jurnal Farmasi Indonesia. Edisi Khusus (Rakerda-Seminar IAI Jateng)*, 1(1), 1–9.
- Suryawan, Arjani, & Sudarmanto. (2016). Gambaran Kadar Ureum Dan Kreatinin Serum Pada Pasien Gagal Ginjal Kronis (Ggk) Yang Menjalani Terapi Hemodialisis Di Rsud Sanjiwani Gianyar. *Journal of Medical*
- Tuldjanah, M., Hosana, L., & Tandi, J. (2021). Uji Efek Nefroterapi Kulit Buah Naga Merah Terhadap Kreatinin dan Ureum Tikus Putih Jantan. *Jurnal Farmakologika*, 18(1), 23–33.
- Verdiansah. (2016). Pemeriksaan Fungsi Ginjal. *Jurnal CDK*, 43(2), 148–154.
- Viany, L., Rizal, R., Widowati, W., Samin, B., Kusuma, R., Fachrial, E., & Nyoman, L. E. I. (2019). Comparison of Antioxidant and Antiaging Activities Between Dragon Fruit (*Hyloceureus polyrhizus* (F.A.C. Weber) Britton & Rose) Rind Extract and Kaempferol. *Majalah Kedokteran Bandung*, 51(3), 147–153. <https://doi.org/10.15395/mkb.v51n3.1715>
- Wahyuni, P., Miro, S., & Eka, K. (2018). Hubungan Lama Menjalani Hemodialisis dengan Kualitas Hidup Pasien Penyakit Ginjal Kronik dengan Diabetes Melitus di RSUP Dr. Djamil Padang. *Jurnal Kesehatan Andalas*, 7(4), 480–485.
- Yusriyani, & Syarifuddin. (2021). Uji Aktivitas Antioksidan Fraksi Polar Ekstrak Kulit Buah Naga Merah Menggunakan Metode DPPH (1,1 Diphényl-2-Picryl Hidrazil). *Jurnal Kesehatan Yamasi Makasar*, 5(2), 59–67.