



SURGICAL MANAGEMENT OF RADICULAR CYST ASSOCIATED WITH OPEN APEX AND APICECTOMY WITH MAXILLARY ANTERIOR TEETH- A CASE REPORT.

Dr. Manali Kadam¹, Dr. Anupam Sharma², Dr. Hrishita Majumder³, Dr. S. Vijay Ganesh⁴

Article History: Received: 10.04.2023 Revised: 06.06.2023 Accepted: 01.07.2023 Published: 10.07.2023

Abstract

Traumatic dental injuries frequently affect soft and hard tissues around the anterior teeth. Pulpal necrosis and cystic alterations are common consequences of dental traumas. The most prevalent inflammatory odontogenic cyst in the oral cavity is radicular cysts, developing from the epithelial cell rests of Malassez. The management of these cysts typically involves cyst enucleation, decompression or marsupialization depending upon the size and extent of invasion of the lesion. Moreover, the open apex corresponding to the non-vital teeth should also undergo apicoectomy and root-end filling. The present case report emphasizes on the enucleation of a large radicular cyst, followed by apicoectomy of the involved teeth and retrograde filling of the open apex.

Keywords: Cystic enucleation, apicectomy, retrograde filling.

¹Post Graduate Student Department of conservative Dentistry and Endodontics Bharati Vidyapeeth (Deemed to be University) Dental College and Hospital, Pune, Maharashtra, India

²Professor and Head of the Department Department of conservative Dentistry and Endodontics Bharati Vidyapeeth (Deemed to be University) Dental College and Hospital, Pune, Maharashtra, India

³Post Graduate Student Department of conservative Dentistry and Endodontics Bharati Vidyapeeth (Deemed to be University) Dental College and Hospital, Pune, Maharashtra, India

⁴Post Graduate Student Department of conservative Dentistry and Endodontics Bharati Vidyapeeth (Deemed to be University) Dental College and Hospital, Pune, Maharashtra, India

DOI: 10.31838/ecb/2023.12.s2.383

Case Report

A 22 years old male patient reported to the Department of Conservative Dentistry and Endodontics, Bharati Vidyapeeth Dental College and Hospital, Pune, with a chief complaint of swelling in palatal region in the past 2 months. Patient reported history of trauma in upper front region of jaw about 10 years ago. Clinical examination revealed a fractured maxillary left central and lateral incisor and right central incisor which were asymptomatic in nature (Figure 1a). On intra oral examination a swelling extended from 21 to 23 regions measuring 3 x 3.5cms in the palatal

region. Swelling was soft and fluctuant in nature (Figure 1b). Pulp sensibility test revealed negative response in 21 and 22 while adjacent teeth showed normal response. A large periapical radiolucency involving 21 and 22 was detected on radiographic examination (Figure 1c), and cone beam computed tomography revealed well defined unilocular hypodensity extending from 11 to 23 along with palatal plate perforation (Figure 1d). Patient was explained about the procedure and informed consent was obtained to commence the treatment

Figure 1: PRE-OPERATIVE EXAMINATION

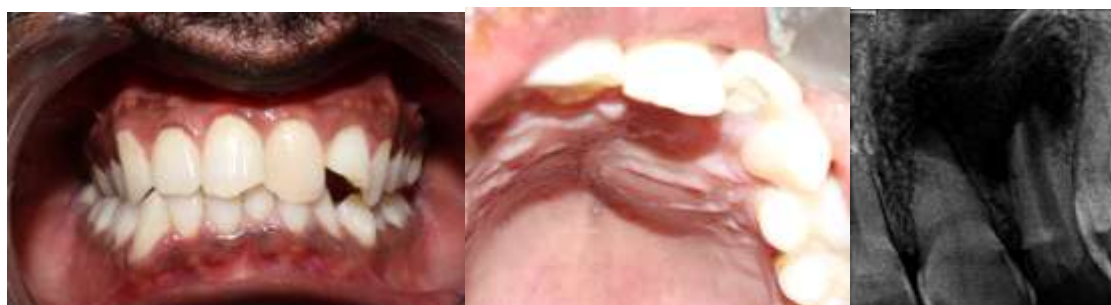

Figure 1a: Pre-operative picture

Figure 1b: Palatal swelling

Figure 1c: Periapical lesion

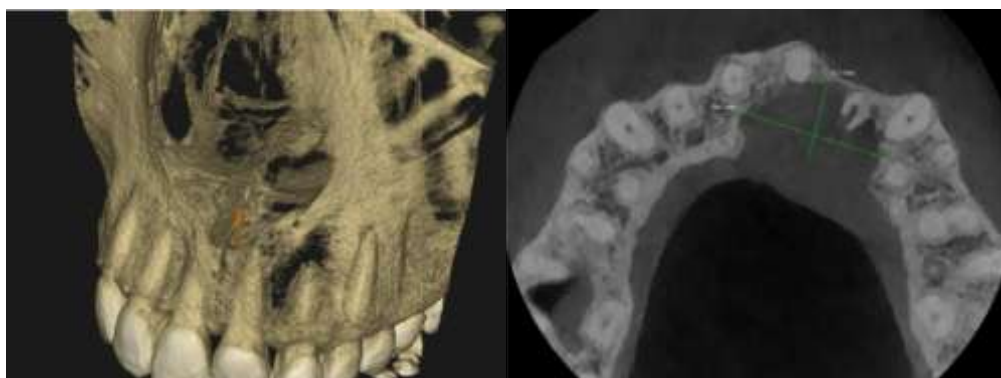


Figure 1d:CBCT examination showing well defined unilocular hypodensity extending from 11 to 23 along with palatal plate perforation

Endodontic treatment protocol

Access opening was done in relation to 21 and 22 and the working length was measured using radiographic method. Biomechanical preparation was done using step back technique for 21. The master apical file was #50K and coronal preparation up to #80K-file (Figure 2a). Irrigation was done using 5.25% sodium hypochlorite followed by 17% EDTA gel (RC prep) during biomechanical preparation, and saline was used as a final irrigant. Minimal instrumentation was done

with 22 to preserve the remaining dentin. Similar irrigation protocol was followed. The prepared canals received calcium hydroxide (RC Cal) as an intracanal medicament, with an interval of 2 weeks, but the patient was still symptomatic. Periapical surgery was planned with 21 and 22 and the obturation was completed using gutta-percha points by lateral condensation technique using AH Plus® sealer for 21 (Figure 2b). Also, retrograde filling of 22 followed by orthograde obturation using thermoplasticized gutta percha was planned.

Figure 2: ENDODONTIC TREATMENT PROTOCOL

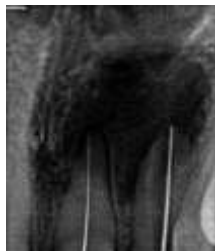

figure 2a: Working length determination

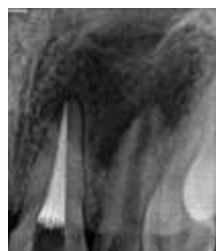

Figure 2b: Obturation with 21

Surgical treatment protocol

The surgical procedure was performed under local anesthesia and labial approach was planned for the enucleation of the cyst. On the scheduled appointment, local anaesthesia was achieved using 2% lignocaine HCl with 1: 200000 adrenaline. A full-thickness trapezoidal mucoperiosteal flap extending from 12 to 24 was raised (Figure 3a). Once the access to the cyst was attained by creating a bony window using micromotor under continuous saline irrigation (Figure 3b), tunnelling knives and excavators were used for careful separation of the cystic lining from the adjacent. The cyst along with the lining was then enucleated completely without any breach of the cystic contents (Figure 3c). The

bone was thoroughly curetted to remove residual granulation tissue. Root end of 21 was resected and cold burnishing was done to seal dentinal tubules and reduction of marginal leakage. Retrograde filling of 22 was done with biodentin and an apical plug of about 4mm was obtained (Figure 3d). The flap closure was done with 3-0 silk following hemostasis (Figure 3e). A radiograph was taken immediately post-surgery to confirm the biodentin apical plug. The histopathology report confirmed the diagnosis of an infected radicular cyst. Post-operative instruction given to the patient and patient was kept under antibiotics and analgesics. Patient was recalled at intervals of 1, 7 days 3 and 6 months.

Figure 3: SURGICAL PROTOCOL

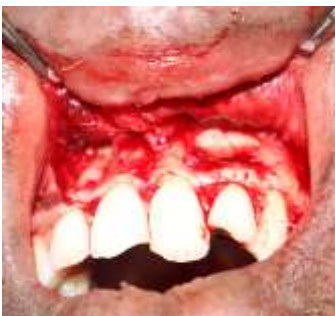

Figure 3a: Flap reflection

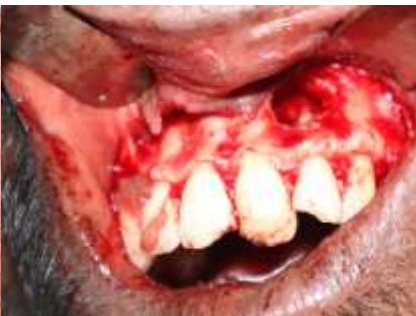

Figure 3b: Osseous window was created to access the cyst



Figure 3c: Enucleation of cyst

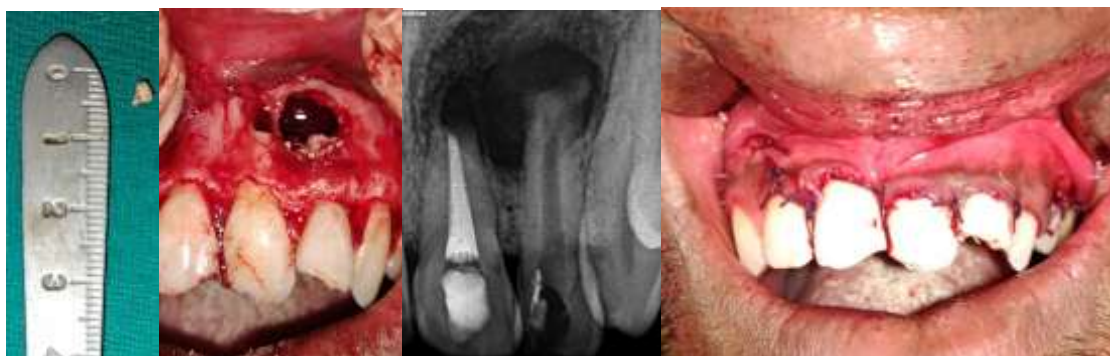

Figure 3d: Apicectomy of 21 and retrograde filling with biodentin

Figure 3e: Reapproximation of soft tissues

Figure 4: FOLLOW UP RADIOGRAPHS

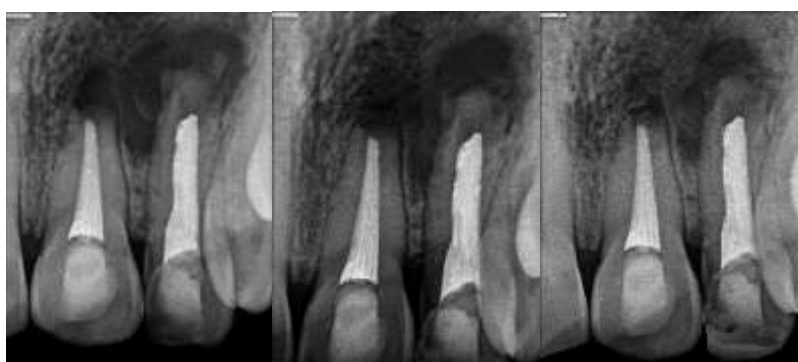

Figure 4a: Immediate post operative

Figure 4b: 3 months follow up

Figure 4c: 6 months follow up

1. Discussion

Anterior maxillary teeth exhibit higher rate of such cysts as they are more prone for trauma and the resultant tooth non-vitality.^[1] The development of a periapical cyst is a gradual and continuous process. Epithelial cell rests of Malassez are stimulated by an inflammatory process and cystic expansion occurs from cystic fluid.^[2] Cysts constitute about 15% of all periapical lesions, and radicular cysts are the most common among them with an incidence rate of 52.3-70.7%.^[3] The treatment option is based on the consideration of several factors such as the origin and extent of the lesion, its relationship to vital structures, clinical features, systemic conditions, and patient cooperation.^[4] The treatment of these cysts is still a matter of dispute and controversy. Endodontic therapy is used as a conservatory approach by many professionals for smaller lesions. In this case, endodontic treatment was performed over multiple visits with intracanal medicament of calcium hydroxide. The intracanal dressings have shown have high clinical efficacy, due to its hygroscopic properties, in reducing the exudate over multiple visits, also reducing microbial loads.^[5] However, in the present case,

though the cystic lesion involved four teeth, the size and extent of the lesion was large for conservative treatment and decompression; small for marsupialization. Therefore, cyst enucleation was decided as the treatment plan. AH Plus®, an epoxy resin-based sealer, was used as it has more antimicrobial activity than other sealers against endodontic pathogens.^[6] Apical surgery is considered a standard oral surgical procedure. The main goal of apical surgery is to prevent bacterial leakage from the root-canal system into the periradicular tissues by placing a tight root-end filling following root-end resection. In this case apicectomy was done with 21 in order to eliminate any residual bacterial following cyst enucleation.^[7] The endodontic treatment of wide-open apex teeth is challenging as teeth are more fragile due to thin dentinal walls, they are more prone to fracture. Biodentine represents a great improvement compared to the other calcium silicate dental materials. In contrast with MTA, the mechanical properties of Biodentine are like those of natural dentin. The material is stable, less soluble, non-resorbable, hydrophilic, easy to prepare and place, needs much less time for setting, produces a tighter seal and has greater radiopacity.^[8] The importance

of the thickness of the apical plug material on the sealing ability was evaluated by Baniet *al.*^[9] The 3-mm and 4-mm thickness were found more effective in preventing apical leakage than 1 mm and 2 mm thickness. These researchers suggested thickness of at least 3 mm Biodentine when used as apical filling material. Post-surgical period was uneventful. The cystic lesion was submitted for histopathological examination. Histopathological features were consistent with the clinical diagnosis of infected radicular cyst. The cystic cavity was lined by non-keratinized stratified squamous epithelium with mixed inflammatory infiltration present. A significantly healing (about 92%) was observed after six months post operatively.^[10]

2. Conclusion

Early and prompt intervention is mandated for the treatment of radicular cysts to avoid extensive invasion of the lesion, loss of teeth and any other potential complications. The present case report focuses on the swift diagnosis and treatment plan, the successful management by enucleation and reduction of the postoperative morbidity of the treated site. The 6-month follow-up of the region showed that such lesions heal after adequate treatment and bone formation will take place once the periapical environment favour is favourable.

3. References

- Shear M, Speight P. Cysts of the Oral and Maxillofacial Regions. 4th ed. Oxford: Wiley-Blackwell; 2007. p. 123-42
- Natkin E, Oswald RJ, Carnes LI: The relationship of lesion size to diagnosis, incidence, and treatment of periapical cysts and granulomas. *Oral Surg Oral Med Oral Pathol.* 1984, 57:82-94. 10.1016/0030-4220(84)90267-6
- Ali M, Baughman RA: Maxillary odontogenic keratocyst: a common and serious clinical misdiagnosis. *J Am Dent Assoc.* 2003, 134:877-83. 10.14219/jada.archive.2003.0286
- Ribeiro PD Jr, Gonçalves ES, Neto ES, Pacenka MR: surgical approaches of extensive periapical cyst. Considerations about surgical technique. (2004). Accessed: January 19, 2023:
- Mohammadi Z, Dummer PMH. Properties and applications of calcium hydroxide in endodontics and dental traumatology. *International Endodontic Journal*, 44, 697–730, 2011.
- Huang, Y., Li, X., Mandal, P. *et al.* The in vitro antimicrobial activities of four endodontic sealers. *BMC Oral Health* **19**, 118 (2019). <https://doi.org/10.1186/s12903-019-0817-2>
- von Arx T. Apical surgery: A review of current techniques and outcome. *Saudi Dent J.* 2011 Jan;23(1):9-15. doi: 10.1016/j.sdentj.2010.10.004. Epub 2010 Nov 11. PMID: 24151412; PMCID: PMC3770245.
- Malkondou O, Kazandag MK, Kazazoglu E. A review on biodentine, a contemporary dentine replacement and repair material. *Biomed Res Int* 2014;2014:160951. †
- Bani M, SungurtekinEkçi E, Odabaş ME. Efficacy of biodentine as an apical plug in nonvital permanent teeth with open apices: An *in vitro* study. *Biomed Res Int* 2015;2015:1-4. †
- Carmina Barone, Thuan T. Dao, Bettina B. Basrani, Nancy Wang, Shimon Friedman, Treatment Outcome in Endodontics: The Toronto Study—Phases 3, 4, and 5: Apical Surgery, *Journal of Endodontics*, Volume 36, Issue 1, 2010, Pages 28-35, ISSN 0099-2399, <https://doi.org/10.1016/j.joen.2009.09.001>.