



Effect of Rutin _C on osseointegration and soft tissue healing of dental implants: a randomized clinical trial

Noha M. Al Adl*¹, Aalaa Shokry Emara², Wessam Mohamed Youssef³,
Nesma Mohamed Awaad⁴

1 Researcher *- Surgery and Oral medicine department, Oral and Dental research institute, National Research Center, Egypt [Corresponding author]

e-mail: dr.nohaeladl@yahoo.com

2 Associate Professor – Oral & Maxillofacial Surgery Department, Faculty of Dentistry- Cairo University, Egypt

e-mail: masa2502@gmail.com

3 Researcher - Surgery and Oral medicine department, Oral and Dental research institute, National Research Center, Egypt

e-mail: wessam2004@gmail.com

4 Lecturer - Prosthodontics Department, Faculty of Dentistry- Cairo University, Egypt

e-mail: nesmaawaad@dentistry.cu.edu.eg

Corresponding author:

Noha M. Al Adl*

Email address: dr.nohatona@gmail.com

Background: Wound healing after dental implant surgery is critical to the procedure's success. This study aims to assess Rutin+Vitamin C supplements on wound healing with dental implant placement.

Methods: 20 male patients requiring implant placement for restoration of maxillary posterior teeth were included. Patients were divided into two groups, group A receiving dental implants while group B receiving dental implants with Rutin+Vitamin C administration. Follow-up appointments were scheduled at days 3,7 and 14 post-surgery during which soft tissue healing was evaluated by Landry index. Postoperative digital panoramas were taken immediately after surgery, 3 months and 6 months postoperatively. Changes in bone density along the bone-implant interface at the mesial, distal and apical sides were assessed using Digora software.

Results: Statistical analysis showed a significant increase in bone densities at the mesial, distal and apical sides of both groups while being statistically significantly higher in Group B. The mean increase in bone density after 6 months was 101.72 ± 12.04 in group A, while it was 131.74 ± 7.96 in group B. Moreover, the rate of increase was statistically significantly higher in group B. Significance was recorded at $P = 0.004$, $P = 0.0001$, and 0.001 at the mesial, distal and apical sides respectively. The wound healing was also significantly higher in group B.

Conclusions: The application of Rutin + Vitamin C significantly enhanced bone healing and improved bone density. It also promoted soft tissue healing which was visible with clinical assessment.

Keywords: dental implant, soft tissue healing, osseointegration, Rutin, Vitamin C

Background: One of the methods to restore missing teeth is a dental implant. They are now a crucial component of dentistry's treatment options for both total and partial edentulism. Comparing dental implants to traditional fixed partial dentures, there are several benefits. A high success rate (over 97% for 10 years), reduced risk of caries and endodontic issues with neighbouring teeth, enhanced bone maintenance in the edentulous location, and reduced sensitivity of nearby teeth are all benefits of this procedure. [1]

It improves occlusal function, lowers anxiety, and boosts patient self-esteem. However, given that dental implants have a high rate of success, it makes sense to use them when necessary. [2]

[3] There are numerous prosthetic options for restoring lost teeth, including dental implants, fixed partial dentures, and removable partial dentures (RPD). [4]

Because it is a potent reducing agent and is necessary for good wound healing because it promotes fibroblast differentiation and collagen formation, vitamin C is a necessary water-soluble vitamin for humans. In addition, vitamin C has immune-modulating properties that affect a host's susceptibility to infection, aid in bone production by hydroxylating proline and lysine, and shield tissue from damaging free radicals. [5]

One of the most crucial nutrients for healthy bones is calcium (Ca). Dietary calcium had an impact on the amount of the calcium reserve since it had to be mobilised in order to keep the blood calcium levels normal. It never interferes with those biological processes, though. For adults, 1200 mg of calcium per day is now advised. It is known that the local supply of calcium in the form of hydroxyapatite enhanced the osseointegration of dental implants. [6]

In apples, onions, and tea, rutin (RT), a flavonoid glycoside, is present. Many pharmacological effects, including antibacterial, anticancer, anti-inflammatory, anti-diarrheal, anti-ulcer, anti-mutagenic, vasodilator, and immunomodulator, are well recognised. [7] Several studies have shown it to have anti-oxidant, anti-inflammatory, neuroprotective, nephroprotective, and hepatoprotective characteristics. Moreover, vitamin (C) ascorbic acid is crucial for the production of collagen and the healing of soft tissues. A water-soluble micronutrient called vitamin C is crucial for maintaining human health. Because the body is unable to create it on its own, it must be obtained from outside sources through dietary consumption and supplementation. When plasma vitamin C concentrations fall below [7]

This study therefore aims to evaluate the effect of Rutin and vit C supplementation on dental implant osseointegration and soft tissue healing.

Methods :Patients were recruited in this study according to the eligibility criteria, where patients were selected from age range 30-45 male patients to exclude hormonal disturbance in females which may affect wound healing and osseointegration. Patients with missing teeth in maxillary premolar molar region were included passing through a thorough diagnosis and blood profile to

exclude uncontrolled diabetes ,bruxism , smoking habits and other absolute contraindications for implant installation. This study was a randomized clinical trial parallel groups where patients were randomly assigned either to receive Rutin+Vit c as an intervention group or not receiving any medication as the a control group using Computer generated randomization list (www.RANDO.Org) with 1:1 allocation ratio to ensure balanced allocation of the treatment... the sample size was calculated to be 20 patients ; ten patients in each group. Patients were informed about the surgical procedures and written consents were signed before any intervention. Ethical approval of this study was acquired,. The study was double blinded, blinding included the statistician and the operator where administration of Rutin and Vit c where given by another subject with the allocation concealment.

Periodontal treatment was performed to remove any plaque, gingival irritation, and clean periodontal pockets. Preoperatively, cone beam computed tomography were made to examine bone quality and quantity at the implant locations. Implant used NEO BIOTECH system(Neo Biotech Co. Ltd, Seoul, Korea). With 4mm width/ 10 mm height. For the participants in all groups, the surgical placement of dental implants was performed using local anesthesia (INIBSA ARTINIBSA 4% 1:100.000, Spain) with a horizontal releasing incision for pain and bleeding control.

Surgical procedure:

Implant placement was performed on a disinfected region by scrubbing with Betadine solution. A crestal and releasing incision were made using a 10 Bard Parker blade. Reflection of the mucoperiosteal full thickness flap was done as routinely to expose the underling bone and locate site of implant placement. The implant drills were used sequentially to reach the required depth and width for implant placement under copious irrigation. The implant shoulder was kept subcrestal as per the manufacturers recommendations. Once the implant was secured in position and 1ry stability confirmed, the flap was returned in position and secured in place with interrupted 3-0 silk sutures.(3/0 silk braided Shandong Weigao Co.LTD) (figures 1-3).

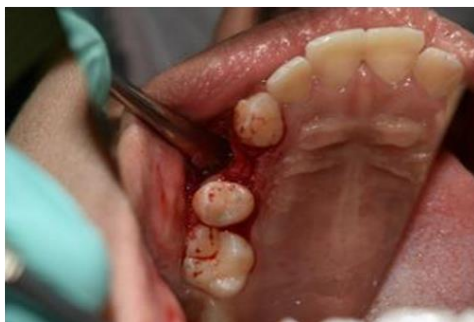

Figure 1: surgical incision for bony exposure to allow implant placement

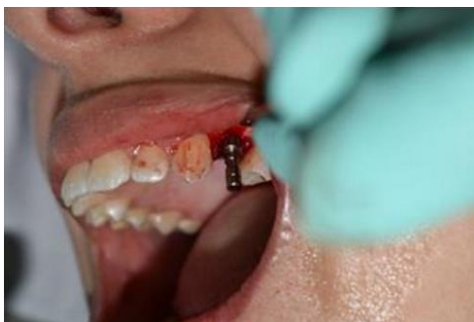

Figure 2: clinical picture of the parallel pin usage to confirm implant position

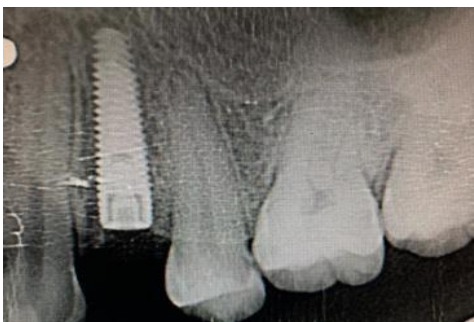

Figure 3: post-operative periapical radiograph

Postoperative care and instructions were followed as routinely done; antibiotics, anti-inflammatory medication, oral hygiene maintenance was instructed to preserve an inflammation/infection free surgical site. 10 days after surgery the patients were recalled for checkup and suture removal. For intervention group patients received Rutin , RutinC 100 mg,(Pharco pharma A.R.E) once daily for 3 months+ C Retard 500 mg,(Hikma pharma S.A.E., 6th of October City - Egypt) once daily for 3 months.

Postoperative assessment:

Soft tissue evaluation:

Landry index was assessed at 3, 7, and 14 day's post-surgery [6] . The healing tissues were clinically evaluated for specific features, including gingival color, response to palpation, presence of granulation tissues, and epithelialization status of the incision margin the sulcus bleeding index (SBI) reported the clinical picture and bleeding on probing; scores were 0-5. 0 being healthy looking without bleeding on probing, 1: healthy looking with bleeding on probing, 2: different colour with bleeding on probing, 3: different color, bleeding on probing and slight oedema. Score 4 was noted in case of bleeding on probing, obvious oedema and different colour and 5 reported for different colored gingiva, spontaneous bleeding and marked oedema.

Bone density evaluation

Postoperative digital panoramas were taken immediately after surgery, 3 months and 6 months, 9months and 12 months postoperatively. Changes in bone density along the bone-implant interface at the mesial, distal and apical sides were assessed using the Digora software (Figure 4a&b). Final prosthetics (cemented zirconia crowns) were then delivered successfully (figure 5)

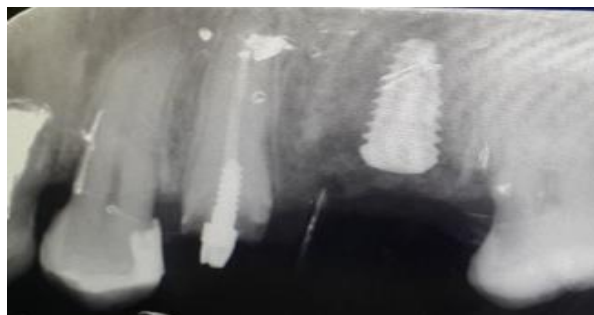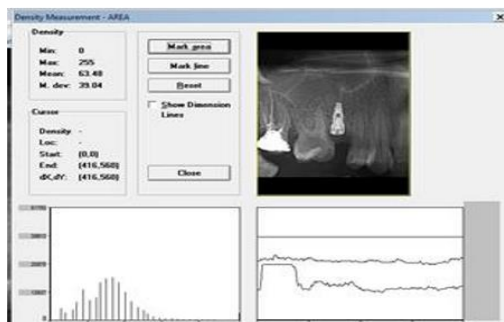


Figure 4a: Digora measurement for bone density Figure 4b: periapical radiograph used in Digora measurement

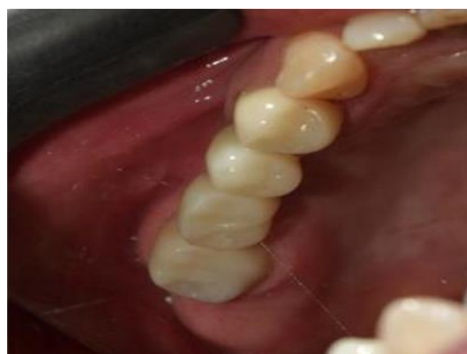

Figure 5 : Final crown cemented in place

Statistical analysis:

The mean and standard deviation values were calculated for each group in each test. Data were explored for normality using Kolmogorov-Smirnov and Shapiro-Wilk tests, Bone density data showed parametric (normal) distribution.

Repeated measure ANOVA was used to compare between more two groups in related samples. Paired sample t-test was used to compare between two groups in related samples. Independent sample t-test was used to compare between two groups in non-related samples. Two-way ANOVA was used to test the interactions between different variables.

The significance level was set at $P \leq 0.05$. Statistical analysis was performed with IBM® SPSS® Statistics Version 20 for Windows.

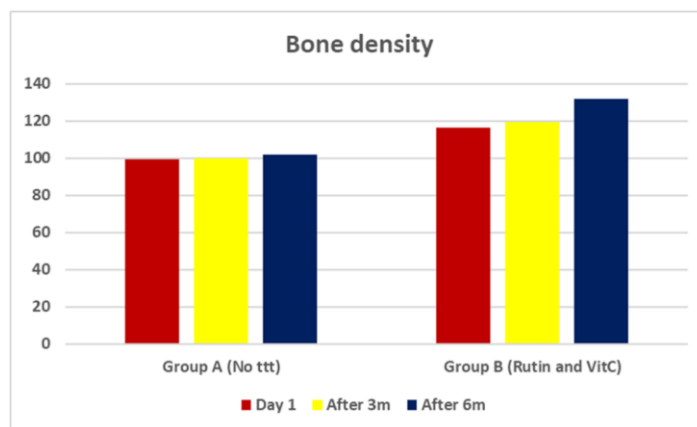


Figure 6:

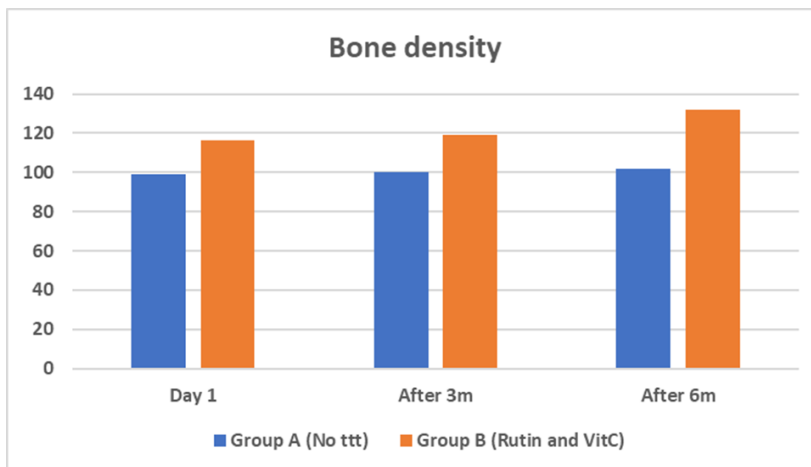


Figure (7): Bar chart representing bone density for different groups and at the different time periods

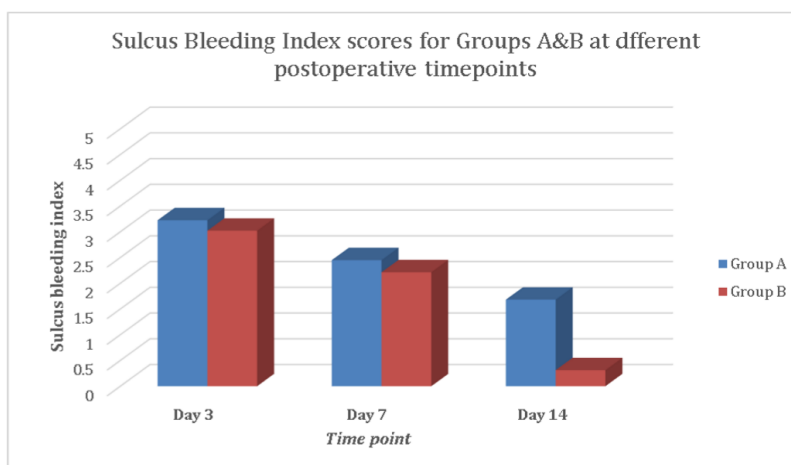


Figure 8: Bar chart representing the clinical picture of the healing sites at days 3, 7 and 14 for groups A & B using SBI.

Results

The results of the study are presented in terms of bone density within the groups and between them.

Along the different time periods in Group A there was no statistically significant difference between day 1, 3 months and 6 month time stops where $p=0.743$. The highest mean value within the group was found after 6 months, while the least mean value was found at day 1.

On the other hand group B results were quite different. There was a statistically significant difference between the day 1, 3 month and 6 month time stops with a p value of <0.001 . A statistically significant difference was found between the 6 month reading and both the day 1 and 3 month readings. (After 6m) and each of (Day 1) and (After 3m) where ($p<0.001$). The highest and lowest mean values were found at 6 months and day 1 respectively.

Soft tissue

Regarding the soft tissue results; the SBI values were recorded at the different time periods ; days 3,7 and 14 postoperatively and compared. The results showed a statistically significant difference at 14 days postoperatively where group A showed a mean score 1.682 of while that of group B was 0.312. Although the scores at days 3 and 7 for group B were also lower; the differences were not statistically significant (figure 8).

Discussion:

In the current study, the effects of vitamin C and rutin on bone density and wound healing were examined. This study's main discovery was that providing rutin+vitamin C to patients after surgery improved dental implant osseointegration and healing capability. Yet, rutin+Vitamin C supplementation had little impact on the discomfort felt following surgery.

Artificial teeth are substituted for lost ones through dental implant surgery. Many research have focused heavily on the effects of minerals and vitamins on periodontal health, wound healing, and osseointegration of dental implants. [6] [8]

Rutin, a naturally occurring bioflavonoid, was suggested by the authors of earlier studies to encourage the creation of Periodontal ligament stem cell sheets and bone regeneration, which is anticipated to become a key instrument in the advancement and optimisation of cell sheet technology. The co-treatment strategy based on rutin and vitamin C is efficient and maybe beneficial.. [9]

Based on earlier research where the authors evaluated the radio-densitometric impact of low-intensity laser therapy on the osseointegration of dental implants that were immediately loaded in patients receiving vitamin C, omega-3, and calcium therapy, the amount of vitamin C used in the current study was (C Retard 500 mg).. [10]

In 2008, a study proved that rutin plays an important role in inhibition of osteoclast formation induced by (RANKL) receptor activator of NF- κ B ligand in bone marrow-derived macrophages. It reduces reactive oxygen species produced by RANKL and its inhibitory effect results from reduced levels of TNF- α . Rutin also lowers NF- κ B activation in response to RANKL [11]

Healing process involves a series of events, including the creation of blood clots, neutrophil adhesion, and granulation tissue, which is followed by connective tissue re-epithelialization and the formation of mature tissues. The wound healing process is typically composed of three sequential and overlapping stages, including inflammation, new tissue formation, and remodeling [12] [13]

.Mohammed et al, [14] showed that vitamin C could promote wound healing through a variety of mechanisms. For example, vitamin C protects the function of vascular endothelium, increasing the expression of vascular endothelial growth factor (VEGF), which promotes cell division and

secretion of matrix proteins. VEGF also promotes angiogenesis, which is an essential element for the regeneration of damaged tissues [10] [15] [16] finally, vitamin C has been shown to promote wound healing in both small animal studies and human trials. The results of our study strongly

supports this theory as it was noted that the soft tissue healing was enhanced with the Rutin C supplementation; this was noted at the 14 day evaluation where the mean SBI score in group B was significantly lower than that in group A.

Conclusions

Results of our study show that the intake of Rutin and Vitamin C with placement of dental implants in the maxillary posterior region improves bone density and tissue healing. This was proven clinically and radiographically. The intake of Vit C + RTN can further be used to improve healing in other surgical procedures.

Abbreviation list: Not applicable

Declarations

Ethics approval and consent to participate:

- The authors proclaim no conflicts of interest and have received no funding for this research.
- Ethics approval and consent to participate: the following research proposal has been revised and approved by the research ethics committee, Faculty of Dentistry ,Cairo University
- Ethical approval was achieved REC-FDCU : 32922 and available.

Consent for publication: Not applicable

Availability of data and material - Datasets are available for sharing

Competing interests – Not applicable

Funding – Not applicable

Authors' contributions: N.A & N.A designed and carried out the procedures, W.Y was responsible for the blinding, assessment and statistical analysis, W.Y & A.E for write up and reviewing, N.A was responsible for proof reading, N.A for submission.

All authors have read and approved the manuscript

Acknowledgements – Authorship for this manuscript was based on participation in design, write-up, review and/ or clinical work for this manuscript

References

- [1] "Block MS. Dental Implants: The Last 100 Years.," *J Oral Maxillofac Surg.* , vol. 1, no. 76, pp. 11-26, 2018.
- [2] S. L. D. B. H. Buser D, "Modern implant dentistry based on osseointegration: 50 years of progress, current trends and open questions.," *Periodontol 2000.*, vol. 1, no. 73, pp. 7-21, 2017.
- [3] M. M. M. G. P. U. M. M. N. M. Merli M, "Immediate versus early non-occlusal loading of dental implants placed flapless in partially edentulous patients: A 10-year randomized clinical trial.," *J Clin Periodontol.* , vol. 5, no. 47, p. 62, 2020.
- [4] P. J. J. V. T. I. R. S. S. M. R. I. K. S. Jayasinghe RM, " Awareness, attitudes, need and demand on replacement of missing teeth among a group of partially dentate patients," *attending a University Dental Hospital*, vol. 10, no. 1, p. 334, 2017.
- [5] S. K. a. S. M., " Vitamin C and Skin.," *J Clin Exp Dermatol Res.*, vol. 9, no. 2, p. 444, 2018.
- [6] Z. M. K. Z. S. F. Najeeb S, " Applications of polyetheretherketone (PEEK) in oral implantology and prosthodontics.," *J. Prosthodont. Res.* , vol. 60, pp. 12-19, 2016.
- [7] A. Ganeshpurkar and A. Saluja, "" The Pharmacological Potential of Rutin.,"" *in Saudi Pharm. J.*, vol. 25, p. 149–164., 2017.
- [8] S. J. A.-S. K. W. H. Neiva RF, "Effects of specific nutrients on periodontal disease onset, progression and treatment.," *J Clin Periodontol.*, vol. 30, no. 7, pp. 579-89, 2003.
- [9] Z. Y. X. Y. X. X. Zhao B, "Rutin promotes the formation and osteogenic differentiation of human periodontal ligament stem cell sheets in vitro.," *Int J Mol Med.*, vol. 44, no. 6, pp. 2289-2297, 2019.
- [10] E.-D. M. I. T. Z. K. N. A. N. S. Mikhail FF, "Effect of Laser Therapy on the Osseointegration of Immediately Loaded Dental Implants in Patients under Vitamin C, Omega-3 and Calcium Therapy. ," *Open Access Maced J Med Sci*, vol. 8, no. 6, pp. 1468-1474, 2018.
- [11] C. J. F. L. L. K. Z. N. L. S. Z. H. G. H. Wu F, " Analysis of the effect of rutin on GSK-3 β and TNF- α expression in lung cancer.," *Exp Ther Med.* , vol. 14, no. 1, pp. 127-130, 2017.
- [12] T. L. J. S. H. e. a. Kyung, " Rutin inhibits osteoclast formation by decreasing reactive oxygen species and TNF- α by inhibiting activation of NF- κ B.," *Exp Mol Med* 40, pp. 52-58, 2008.
- [13] G. W. S. B. Y. e. a. Gurtner, "Wound repair and regeneration. ," *Nature* 453, pp. 314-321, 2008.
- [14] F. B. K. D. W. S. W. J. B. D. F. A. 3. Y. D. N. R. Mohammed BM, " Vitamin C promotes wound healing through novel pleiotropic mechanisms.," *Int Wound J.* , vol. 13, no. 4, pp. 572-84, 2016.
- [15] C. J. F. L. L. K. Z. N. L. S. Z. H. G. H. Wu F, " Analysis of the effect of rutin on GSK-3 β and TNF- α expression in lung cancer.," *Exp Ther Med.*, vol. 14, no. 1, pp. 127-130, 2017.
- [16] G. W. S. B. Y. e. a. Gurtner, "Wound repair and regeneration.," *Nature* 453, pp. 314-321, 2008.